



MYOMATA

OF THE

UTERUS

BY

HOWARD A. KELLY AND THOMAS S. CULLEN

PROFESSOR OF GYNECOLOGY IN THE JOHNS
HOPKINS UNIVERSITY; GYNECOLOGIST-IN-
CHIEF TO THE JOHNS HOPKINS HOSPITAL

ASSOCIATE PROFESSOR OF GYNECOLOGY, JOHNS
HOPKINS UNIVERSITY; ASSOCIATE GYNECOLO-
GIST TO THE JOHNS HOPKINS HOSPITAL

ILLUSTRATED

BY

AUGUST HORN and HERMANN BECKER

PHILADELPHIA AND LONDON

W. B. SAUNDERS COMPANY

1909

Copyright, 1909, by W. B. Saunders Company

PRINTED IN AMERICA

TO THE MEMORY OF
Leslie Matthew Sweetnam

OF THE UNIVERSITY OF TORONTO,

A MAN OF RARE SURGICAL JUDGMENT AND A TRUE FRIEND



PREFACE

IN 1894 we commenced a careful study of uterine myomata and contemplated publishing the results of our findings. A year later, however, the work was temporarily laid aside, as it was deemed wiser to take up the subject of carcinoma of the uterus. After the publication of that work in 1900 we again turned our attention to uterine myomata, and since that time we have been continually gathering data on that subject.

Our material has been drawn from (1) the cases operated upon at the Johns Hopkins Hospital from the opening of the institution in 1889 to January 1, 1909; (2) those that have come under the care of Dr. Kelly at his private hospital; and (3) those operated upon by me at the Church Home and Infirmary, at the Cambridge (Maryland) Hospital, and at the Emergency Hospital in Frederick. The total number of cases examined was 1674. After obtaining complete abstracts of the histories, the tumors were again examined, and many new and interesting changes were found that had been overlooked in the regular routine laboratory examinations. Descriptions of the gross and histological appearances of the myomata were made, and these descriptions were then attached to their respective histories.

After carefully surveying the great wealth of material, the question arose as to the advisability of reviewing the vast amount of current literature on myomata, and it was found that to adequately cover it, and at the same time fully discuss our own material, would necessitate the publication of three or more volumes. Under these circumstances, we felt that no one would wish to read so much on one subject, and that it would be wiser to confine our efforts to a thorough study of our own material, with which we were thoroughly familiar. The present volume, therefore, deals almost exclusively with the work done by those connected with the gynecological department of the Johns Hopkins Hospital and of the Johns Hopkins University.

It may be of interest briefly to detail the method adopted in correlating the many points of interest contained in the large amount of material. We started off without any preconceived theories and determined to carefully analyze the cases at our disposal. After several months of indecision as to the best method of handling the subject, we finally adopted the card system. Every history and pathological description was read and each point of importance was underscored. Then a card was made of each point. This card also had the case number and the pathological number. Some cases contained little or nothing of interest;

for other cases, from five to ten cards were necessary. As a result we had several thousand cards. These naturally fell under certain main headings. This gave us a more concrete idea of the material and clearly indicated the chapter classification. The card-index was of the greatest assistance; in the first place, because it enabled us to get every point of interest, and, secondly, because when a given subject was under discussion it was only necessary to pick out the cards of that group and then select the ten or twenty histories, as the case might be, instead of each time going through sixteen hundred histories, with a strong likelihood of overlooking several cases. We fully realize the important part played by the many assistant residents and the residents of the Gynecological Department since the opening of the Hospital; had it not been for their careful and conscientious histories and descriptions of the various operations performed, this work would have been impossible.

On account of the great importance of sarcomatous changes occurring in or associated with myomata and the by no means infrequent association of carcinoma of the fundus with myomata, we have considered both of these subjects at unusual length.

The chapter on adenomyoma reached such large proportions that we found it necessary to deal with the subject in a separate volume.* On the other hand, the chapter on myoma and pregnancy is rather fragmentary, as we do no obstetrical work.

We have not discussed the history of the development of the surgical procedures appropriate to uterine myomata. This has been so well handled by Dr. Charles P. Noble† that nothing would be gained by duplicating the account. Only the various operative procedures that we personally have used are described. Dr. Kelly being out of the city, it devolved upon me to briefly outline the scope of the book, and although I know he would be averse to any personal mention of his work, I feel it my duty to say a few words relative to his share in the development of operations for myomata. It was my good fortune to come to Baltimore in 1891, shortly after the hospital opened. At that time many cases of myoma were considered inoperable, and even when hysterectomy was undertaken it was only in the cases in which a stout rubber ligature could be temporarily tied around the cervix; and when, as happened in some cases, this ligature slipped, alarming hemorrhage followed. Then came the systematic controlling of each of the cardinal vessels; later the bisection, and finally the transverse severance of the cervix as a preliminary feature of the operation in exceptionally difficult cases, until at present a myomatous uterus that cannot be removed is almost unheard of. I have watched the gradual simplifications of the surgical procedures with the greatest interest. Many American surgeons have had much to do with the wonderful advance in this direction, but I know of no other man,

* Thomas S. Cullen, *Adenomyoma of the Uterus*, W. B. Saunders Co., 1908.

† In Kelly-Noble, *Gynecology and Abdominal Surgery*, vol. i, p. 660. W. B. Saunders Co., 1908.

either here or abroad, who has done as much toward this advancement as Howard A. Kelly.

We have purposely laid much stress on the mistakes and mishaps that have occurred, and have given our deaths in full, as we feel that much more can often be learned from failures than from successes. Moreover, we felt that a frank statement of our mishaps might help other surgeons to avoid the unpleasant complications that we have occasionally encountered.

Our mortality, taking all the cases from 1889 to July 1, 1906, was rather high—between 5 and 6 per cent. It included all the early cases, but also embraced many of the desperate cases and also many cases of myoma associated with malignancy. Just before going to press we have gone over the histories from July 1, 1906, to January 1, 1909, and find that in 238 myoma operations the death-rate has been less than 1 per cent.—an evidence of a continued improvement in our operative technique.

The work would not have been complete without some reference to the autopsy findings in a large number of cases. Professor William H. Welch kindly placed his valuable records at our disposal. We are also deeply indebted to him for the sympathetic co-operation he has always accorded us in the laboratory studies.

To the casual observer the preservation of myomatous material to the extent of several tons would seem unnecessary, but Dr. Henry M. Hurd has assisted us in every way. This foresight has been of the greatest value in many instances, notably in those cases in which sarcoma had been overlooked at the first examination, or in which subsequently to a supposedly simple hysteromyectomy, a sarcoma developed in the stump. We also owe much to Dr. Hurd for his advice.

The illustrations have been made with wonderful accuracy in detail by Mr. August Horn and Mr. Hermann Becker. Further comment is unnecessary, as the pictures speak for themselves. We are also fortunate in having several examples of Mr. Max Brödel's work. When it is said that a drawing has been reduced one-half, linear measurement is intended. In reality the flat surface of the picture is only one-fourth the natural size. It is well to bear this point in mind, otherwise the reader will not get an adequate conception of the actual size. With few exceptions the illustrations are original. We wish to thank Dr. George H. Simmons for allowing us to use several of the illustrations which we have already published in the "Journal of the American Medical Association."

To Mr. Harry Hall and Mr. Hardy, of the Surgeon-General's Library, we are indebted for their kind assistance rendered while we were verifying the literature.

Dr. Herbert I. Cole, of Mobile, Ala., rendered much assistance in the preparation of the chapter dealing with the findings at autopsy.

Mr. Benjamin O. McCleary made most of the slides from which the histological pictures have been drawn. He also rendered most valuable aid in controlling the many numbers scattered throughout the book and also in checking off all measurements.

Our thanks are due Dr. Frank R. Smith, not only for his correction of the proof-sheets, but also for his kind criticism of their contents. In numerous places he has indicated that the original text, while satisfactory to the specialist, might not have conveyed the proper meaning to the general practitioner.

Dr. Ernest K. Cullen spent his entire time for over a year in locating former patients, in filling in missing data, and in analyzing the cases from numerous standpoints. He has also devoted much time to the book in the last two years, and during the progress of the work has made many valuable suggestions. He has carefully followed the proof-sheets through the press, paying especial attention to the accuracy of the numbers. It is impossible for us to adequately thank him for the large share he has had in the making of this volume.

Miss Cora Reik has been of the greatest assistance to us in the gathering of the histories and laboratory abstracts and in the preparation of the manuscript.

Our thanks are also due to the W. B. Saunders Company, who have done all in their power to procure the best possible reproductions of the illustrations and to facilitate the progress of the book through the press.

In conclusion we can only say that if the reader gets a tittle of the pleasure from the perusal of this volume that we did in gathering the material its function will have been fulfilled.

THOMAS S. CULLEN.

BALTIMORE, MD.,
June, 1909.

CONTENTS

CHAPTER	PAGE
I. UTERINE MYOMATA.....	1
II. PARASITIC UTERINE MYOMATA.....	13
III. CERVICAL MYOMATA.....	53
IV. SUBMUCOUS MYOMATA.....	59
V. DILATATION OF THE UTERINE LYMPHATICS ASSOCIATED WITH MYOMATA.....	72
VI. TORSION OF THE UTERUS.....	77
VII. HYALINE AND CYSTIC DEGENERATION.....	83
VIII. CALCIFICATION OF UTERINE MYOMATA.....	126
IX. SUPPURATING UTERINE MYOMATA.....	134
X. MYOMATA ASSOCIATED WITH MALFORMATIONS OF THE UTERUS.....	155
XI. ANGIOMYOMA.....	158
XII. LIPOMYOMA OF THE UTERUS.....	162
XIII. ADENOMYOMA OF THE UTERUS.....	167
XIV. MYOSARCOMA OF THE UTERUS.....	169
XV. CARCINOMA OF THE CERVIX ASSOCIATED WITH UTERINE MYOMATA.....	262
XVI. ADENOCARCINOMA OF THE BODY OF THE UTERUS ASSOCIATED WITH UTERINE MYOMATA.....	274
XVII. THE CONDITION OF THE UTERINE MUCOSA IN CASES OF MYOMA.....	297
XVIII. CONDITIONS OF THE TUBES AND OVARIES WHEN UTERINE MYOMATA ARE PRESENT.....	337
XIX. CONDITIONS FOUND IN THE LIGAMENTS PASSING TO AND FROM THE UTERUS IN CASES OF UTERINE MYOMATA.....	354
XX. THE BLADDER IN CASES OF UTERINE MYOMATA.....	365
XXI. THE URETERS IN CASES OF UTERINE MYOMATA.....	378
XXII. THE RECTAL FINDINGS IN CASES OF UTERINE MYOMATA.....	386
XXIII. ANALYSIS OF THE CASES OF UTERINE MYOMATA FOUND AT AUTOPSY IN THE PATHOLOGICAL LABORATORY OF THE JOHNS HOPKINS HOSPITAL FROM THE OPENING OF THE HOSPITAL IN 1889 TO JULY 1, 1906.....	394
XXIV. THE CAUSE OF UTERINE MYOMATA.....	430
XXV. THE SYMPTOMS ASSOCIATED WITH UTERINE MYOMATA.....	434
XXVI. OTHER PATHOLOGIC CONDITIONS IN SOME OF OUR MYOMA CASES.....	460
XXVII. DIFFERENTIAL DIAGNOSIS.....	467
XXVIII. THE EFFECT OF REMOVAL OF THE OVARIES ON UTERINE MYOMATA.....	504
XXIX. ABDOMINAL MYOMECTOMY.....	506
XXX. VAGINAL MYOMECTOMY.....	571
XXXI. ABDOMINAL HYSTEROMYOMECTOMY.....	588
XXXII. DIFFICULT ABDOMINAL HYSTERECTOMIES.....	630
XXXIII. PREGNANCY AND UTERINE MYOMATA.....	643
XXXIV. COMPLICATIONS FOLLOWING ABDOMINAL HYSTEROMYOMECTOMY.....	654
XXXV. RESULTS OF OPERATIONS FOR UTERINE MYOMATA.....	671
.....	
INDEX OF CASES ARRANGED ACCORDING TO THEIR GYNECOLOGICAL NUMBERS.....	689
PATHOLOGICAL NUMBERS.....	697
AUTOPSY NUMBERS.....	701
INDEX.....	703



LIST OF ILLUSTRATIONS

FIG.	PAGE
1. SESSILE AND PEDUNCULATED MYOMATA	2
2. MULBERRY-SHAPED AND SESSILE MYOMA.....	2
3. AN ORDINARY MYOMATOUS UTERUS ON SECTION	3
4. A GENERAL "MYOMATOUS TENDENCY".....	4
5. INJECTION OF A MYOMATOUS UTERUS.....	6
6. TYPICAL MYOMATOUS TISSUE.....	7
7. THE LINE OF CLEAVAGE BETWEEN A MYOMA AND THE UTERINE MUSCLE	8
8. BLENDING OF A MYOMA WITH THE UTERINE MUSCLE.....	9
9. THE IRREGULAR EXTENSION OF A MYOMA INTO THE UTERINE MUSCLE.....	10
10. A TRANSVERSE SECTION THROUGH A MYOMATOUS UTERUS.....	11
11. THE MYOMATOUS UTERUS AS VIEWED ON TRANSVERSE SECTION THROUGH THE CERVIX ...	11
12. OMENTAL BLOOD-VESSELS THAT ARE KEEPING ALIVE THE OUTER LAYERS OF A MYOMA WHICH SHOWS ALMOST TOTAL HYALINE DEGENERATION.....	15
13. A PARTIALLY PARASITIC MYOMA RECEIVING MOST OF ITS BLOOD-SUPPLY FROM THE OMENTUM.....	17
14. A PARTIALLY PARASITIC MYOMA RECEIVING A LARGE BLOOD-SUPPLY FROM THE OMENTUM.....	17
15. A LARGE PEDUNCULATED MYOMA RECEIVING NEARLY ALL OF ITS BLOOD-SUPPLY FROM THE OMENTUM.....	18
16. A VERY LARGE SUPERPERITONEAL AND PEDUNCULATED MYOMA, RECEIVING MOST OF ITS NOURISHMENT FROM THE OMENTUM.....	19
17. A VERY LARGE PEDUNCULATED AND PARTIALLY NECROTIC MYOMA RECEIVING A RICH BLOOD-SUPPLY FROM THE OMENTUM.....	20
18. A PARASITIC MYOMA RECEIVING A LARGE BLOOD-SUPPLY FROM THE OMENTUM. PARTIAL ATROPHY OF THE OMENTAL FAT.....	22
19. MARKED DISAPPEARANCE OF THE FAT IN AN ADHERENT OMENTUM.....	23
20. THE GRADUAL DISAPPEARANCE OF OMENTAL FAT WHEN THE OMENTUM SENDS MANY VESSELS TO A PARASITIC MYOMA.....	25
21. A LARGE PARASITIC MYOMA WITH HUGE VESSELS COMING FROM THE OMENTUM.....	26
22. LARGE CONGERIES OF OMENTAL VESSELS SUPPLYING NOURISHMENT TO A MYOMATOUS UTERUS; ALSO VESSELS PASSING UP FROM THE BLADDER TO THE TUMOR.....	28
23. A LARGE MYOMA ENTIRELY SEPARATED FROM THE UTERUS AND LYING FREE IN THE OMENTUM.....	29
24. OMENTAL VESSELS SUPPLYING A SUPERPERITONEAL PEDUNCULATED MYOMA, AND ASSOCIATED WITH 7000 C.C. OF ASCITIC FLUID.....	34
25. A PARTIALLY PARASITIC UTERINE MYOMA ASSOCIATED WITH 51 LITERS OF ASCITIC FLUID.....	36
26. A PARTIALLY PARASITIC MYOMA RECEIVING PART OF ITS NOURISHMENT FROM THE FALLOPIAN TUBES.....	37
27. A PARASITIC MYOMA IN NO WAY CONNECTED WITH THE UTERUS.....	39
28. MULTINODULAR MYOMATOUS UTERUS WITH A LEFT PUS-TUBE.....	40
29. A MYOMA RECEIVING MUCH OF ITS NOURISHMENT FROM THE RECTUM AND APPARENTLY FROM THE RIGHT OVARY AND TUBE.....	42
30. A LARGE SUPERPERITONEAL PEDUNCULATED MYOMA, RECEIVING MUCH OF ITS NOURISHMENT FROM THE INTESTINES.....	43
31. A SPLEEN-SHAPED MYOMA.....	45
32. A SUPPURATING SUPERPERITONEAL MYOMA COMMUNICATING WITH THE LUMEN OF THE CECUM.....	46

Fig.	Page
33. A MYOMA RECEIVING ITS NOURISHMENT FROM THE MESENTERY OF THE SMALL BOWEL AND CONTAINING AN ABSCESS CAVITY WHICH COMMUNICATED WITH THE LUMEN OF THE INTESTINE.....	47
34. PEDUNCULATED MYOMATA RECEIVING A LARGE PART OF THEIR NOURISHMENT FROM THE BLADDER.....	50
35. A MULTINODULAR MYOMATOUS UTERUS WITH VESSELS PASSING FROM THE RIGHT ABDOMINAL WALL AND APPENDIX TO A LARGE PEDUNCULATED MYOMA.....	52
36. MYOMA OF THE BROAD LIGAMENT AND CERVIX.....	53
37. A MYOMA OF THE BROAD LIGAMENT AND CERVIX.....	54
38. A CERVICAL MYOMA.....	55
39. CERVICAL DEVELOPMENT OF MYOMATA.....	56
40. A VERY LARGE CERVICAL MYOMA.....	57
41. EXTENSIVE CERVICAL DEVELOPMENT OF A MYOMA.....	58
42. A SUBMUCOUS MYOMA FILLING THE UTERINE CAVITY.....	59
43. MARKED SUBMUCOUS DEVELOPMENT OF UTERINE MYOMATA.....	60
44. EXTENSIVE SUBMUCOUS DEVELOPMENT OF UTERINE MYOMATA.....	60
45. A LARGE PEDUNCULATED SUBMUCOUS MYOMA.....	61
46. A LARGE PEDUNCULATED SUBMUCOUS MYOMA.....	62
47. A PORTION OF A LARGE INTERSTITIAL MYOMA THAT HAS BECOME SUBMUCOUS AND SHOWS EARLY SIGNS OF BREAKING DOWN.....	63
48. A LARGE PEDUNCULATED SUBMUCOUS MYOMA.....	64
49. A LOBULATED SUBMUCOUS MYOMA PROJECTING THROUGH THE CERVIX.....	64
50. A GANGLIENOUS SUBMUCOUS MYOMA.....	64
51. A SLOUGHING SUBMUCOUS MYOMA.....	65
52. A VERY LARGE SUBMUCOUS MYOMA WHICH HAD BEEN EXTRUDED FROM THE UTERUS.....	66
53. A SLOUGHING SUBMUCOUS MYOMA.....	67
54. THE SURFACE OF A SLOUGHING SUBMUCOUS MYOMA.....	68
55. THE SUPERFICIAL PORTIONS OF A SLOUGHING SUBMUCOUS MYOMA.....	69
56. THE SURFACE OF A SLOUGHING SUBMUCOUS MYOMA.....	69
57. ENORMOUS DILATATION OF THE LYMPHATICS ON THE SURFACE OF A MYOMATOUS UTERUS.....	73
58. DILATED LYMPHATIC SPACES IN THE UTERINE WALL IN THE NEIGHBORHOOD OF THE RIGHT TUBE AND OVARY.....	74
59. DILATED LYMPHATIC CHANNELS AT THE LEFT UTERINE HORN BETWEEN THE TUBE AND OVARY AND BETWEEN THE TUBE AND LEFT ROUND LIGAMENT.....	75
60. ROTATION OF A MYOMATOUS UTERUS ON ITS CERVIX.....	77
61. ATROPHY OF THE CERVIX ASSOCIATED WITH A LARGE GLOBULAR MYOMATOUS UTERUS.....	78
62. MARKED TORSION OF A MYOMATOUS UTERUS.....	78
63. TORSION OF A LARGE GLOBULAR MYOMATOUS UTERUS.....	79
64. SPONTANEOUS AMPUTATION OF A MYOMATOUS UTERUS.....	80
65. TORSION OF A SUPERPERITONEAL PEDUNCULATED MYOMA.....	81
66. SUDDEN TORSION OF A SUPERPERITONEAL PEDUNCULATED MYOMA WITH COMPLETE SHUTTING OFF OF ITS BLOOD-SUPPLY.....	82
67. ABRUPT TRANSFORMATION OF MYOMATOUS INTO HYALINE TISSUE.....	84
68. FOCAL HYALINE DEGENERATION IN MUSCLE-BUNDLES.....	85
69. MARKED HYALINE DEGENERATION OF THE WALLS OF THE BLOOD-VESSELS IN A MYOMA.....	86
70. HYALINE DEGENERATION IN THE CENTER OF AN INTERSTITIAL MYOMA.....	87
71. EDEMA OF A MYOMA.....	88
72. HYALINE DEGENERATION WITH CYSTIC FORMATION IN A SMALL SUPERPERITONEAL PEDUNCULATED MYOMA.....	89
73. EXTENSIVE AND SHARPLY DEFINED HYALINE DEGENERATION IN A SUPERPERITONEAL MYOMA.....	93
74. MARKED HYALINE DEGENERATION WITH LIQUEFACTION IN AN INTERSTITIAL MYOMA.....	95
75. CYSTIC DEGENERATION OF A PORTION OF A PEDUNCULATED SUPERPERITONEAL MYOMA.....	96
76. CYSTIC DEGENERATION IN A LARGE SUPERPERITONEAL PEDUNCULATED MYOMA.....	98

FIG.	PAGE
77. MARKED PROLIFERATION OF THE ENDOTHELIUM OF THE CAPILLARIES DIVIDING THE MYOMATOUS TISSUE INTO ALVEOLI.....	99
78. COAGULATION NECROSIS AND HYALINE DEGENERATION IN AN INTERSTITIAL MYOMA.....	100
79. GENERAL AND DIFFUSE CYSTIC FORMATION IN A MYOMA.....	101
80. THE GENERAL CONTOUR AND RELATIONS OF THE MYOMA SEEN IN FIG. 81.....	102
81. COMPLETE CYSTIC DEGENERATION OF PORTIONS OF A MYOMA THAT HAD UNDERGONE HYALINE DEGENERATION.....	102-103
82. GRADUAL LIQUEFACTION OF A MYOMA.....	103
83. LIQUEFIED AND HYALINE AREAS IN A MYOMA.....	104
84. LIQUEFACTION AND HYALINE AREAS IN A MYOMA.....	106
85. HYALINE DEGENERATION WITH LIQUEFACTION OF AN INTERSTITIAL UTERINE MYOMA.....	107
86. MASSIVE HYALINE DEGENERATION AND LIQUEFACTION OF A LARGE UTERINE MYOMA.....	109
87. A CYSTIC SUPRAPERITONEAL PEDUNCULATED MYOMA.....	110
88. A MULTILOCULAR CYSTIC MYOMA.....	111
89. A LARGE CYSTIC MYOMA GROWING FROM THE POSTERIOR SURFACE OF THE UTERUS.....	113
90. A LARGE SUPRAPERITONEAL CYSTIC MYOMA.....	114
91. A CYSTIC MYOMA.....	115
92. A LARGE MULTICYSTIC MYOMA.....	117
93. A CYSTIC MYOMA WEIGHING 39 POUNDS AND CLOSELY RESEMBLING A MULTILOCULAR OVARIAN CYST.....	119
94. A CYSTIC UTERINE MYOMA.....	120
95. A CYSTIC MYOMA OCCUPYING THE ANTERIOR UTERINE WALL.....	121
96. A CYSTIC MYOMA WITH A CAVITY RESEMBLING SOMEWHAT THE INTERIOR OF A HEART.....	122
97. IRREGULAR CYSTIC SPACES IN A MYOMA.....	123
98. A UTERINE MYOMA WITH CYSTIC SPACES CONTAINING MATERIAL RESEMBLING MELTED BUTTER.....	124
99. A DEGENERATED PARTLY CALCIFIED MYOMA.....	126
100. MYOMATA REPRESENTING VARIOUS STAGES OF DEGENERATION.....	127
101. PARTIAL CALCIFICATION OF A MYOMA.....	128
102. CALCAREOUS PLATES IN THE WALL OF AN ARTERY.....	129
103. A COMPLETELY CALCIFIED SUPRAPERITONEAL MYOMA.....	131
104. A SUPPURATING SUPRAPERITONEAL MYOMA.....	136
105. AN INTRALIGAMENTARY SUPPURATING MYOMA.....	138
106. A SUPPURATING INTRALIGAMENTARY MYOMA.....	139
107. A SUPPURATING SUPRAPERITONEAL MYOMA.....	140
108. A SUPPURATING SUPRAPERITONEAL MYOMA.....	141
109. A SUPPURATING MYOMA OPENING INTO THE COLON.....	143
110. A SUPPURATING INTERSTITIAL MYOMA.....	145
111. SLIGHT SUPPURATION OF AN INTERSTITIAL MYOMA WITH PERFORATION INTO THE UTERINE CAVITY.....	146
112. A SUPPURATING INTERSTITIAL MYOMA OPENING INTO THE UTERINE CAVITY.....	148
113. A LARGE SUPPURATING INTERSTITIAL MYOMA OPENING INTO AND INFECTING THE PERITONEAL CAVITY AND ALSO DRAINING INTO THE CAVITY OF THE UTERUS.....	151
114. A DOUBLE UTERUS CONTAINING SUPRAPERITONEAL, INTERSTITIAL, AND SUBMUCOSAL MYOMATA.....	156
115. ANGIOMYOMA.....	159
116. MULTIPLE ANGIOMYOMATOUS FOCI IN A MYOMA.....	159-160
117. ANGIOMYOMA.....	160
118. LIPOMYOMA.....	162
119. LIPOMYOMA.....	163
120. LIPOMYOMA.....	164
121. LIPOMYOMA.....	165
122. A SARCOMATOUS NODULE IN A LARGE PELVIC BLOOD-VESSEL.....	175
123. SARCOMATOUS TRANSFORMATION OF A SUPRAPERITONEAL MYOMA WITH DENSE ADHESIONS TO THE RECTUM AND PELVIC WALLS.....	181

FIG.	PAGE
124. TRANSITION OF MYOMATOUS INTO SARCOMATOUS TISSUE.....	182
125. SARCOMATOUS TRANSFORMATION OF A MYOMA WITH A SECONDARY GROWTH ON THE POSTERIOR SURFACE OF THE UTERUS.....	185
126. MYOSARCOMA OF THE BODY OF THE UTERUS WITH A SECONDARY AND PURE SARCOMA- TOUS COCKSCOMB-LIKE GROWTH ON THE POSTERIOR SURFACE.....	186
127. THE LOBULATED AND MYOMATOUS NODULE REMOVED FROM THE LEFT BROAD LIGAMENT IN FIG. 125.....	187
128. COMMENCING SARCOMATOUS TRANSFORMATION OF MYOMATOUS TISSUE.....	188
129. A SARCOMA THAT HAS DEVELOPED FROM AN INTERSTITIAL MYOMA.....	189
130. SARCOMA DEVELOPING IN THE CERVICAL STUMP.....	191
131. SARCOMATOUS TRANSFORMATION OF A UTERINE MYOMA. SUPRAVAGINAL AMPUTATION WITH RETURN OF THE GROWTH IN THE CERVICAL STUMP.....	193
132. SARCOMA OF THE ANTERIOR UTERINE WALL.....	197
133. A LARGE SARCOMATOUS NODULE CONTAINING AN IRREGULAR, SMOOTH-WALLED CAVITY IN ITS CENTER.....	198
134. PROBABLE SARCOMATOUS TRANSFORMATION OF BUNDLES OF MYOMATOUS TISSUE.....	199
135. SARCOMA DEVELOPING IN THE CENTER OF A SUPERITONEAL MYOMA.....	202
136. SARCOMA DEVELOPING, IN PART AT LEAST, FROM A SUBMUCOUS MYOMA.....	205
137. A MYOMA SITUATED TO THE RIGHT OF THE CERVIX AND SHOWING EARLY SARCOMATOUS CHANGES.....	206
138. SARCOMA DEVELOPING IN THE CENTER OF A LARGE INTERSTITIAL UTERINE MYOMA.....	209
139. SARCOMA DEVELOPING IN THE INTERIOR OF A MYOMA.....	211
140. PROBABLE SARCOMATOUS TRANSFORMATION OF A MYOMA; ALSO DISCRETE MYOMATOUS AND SARCOMATOUS NODULES IN THE SAME UTERUS.....	213
141. ASSOCIATION OF MYOMA AND SARCOMA IN THE SAME UTERUS.....	214
142. A SARCOMATOUS UTERUS CONFORMING IN CONTOUR TO A GLOBULAR MYOMATOUS UTERUS.....	216
143. SARCOMA AND MYOMA IN THE SAME UTERUS.....	217
144. MIXED-CELLED SARCOMA OF THE UTERUS ASSOCIATED WITH MYOMATA OF THE UTERUS.....	218
145. SARCOMA OF THE POSTERIOR UTERINE WALL, ORIGINATING IN A MYOMA.....	220
146. SARCOMATOUS TRANSFORMATION OF A MULTINODULAR PEDUNCULATED, SUPERITONEAL MYOMA.....	224
147. SUSPICIOUS CELL CHANGES IN A MYOMA.....	225
148. EARLY SARCOMATOUS CHANGES IN A MYOMA.....	225
149. SARCOMATOUS TRANSFORMATION OF MYOMATOUS TISSUE.....	226
150. GRADUAL BUT DIRECT TRANSITION OF MYOMATOUS INTO SARCOMATOUS TISSUE.....	227
151. SARCOMATOUS TRANSFORMATION OF MYOMATOUS TISSUE.....	228
152. SARCOMATOUS TRANSFORMATION OF MYOMATOUS TISSUE.....	228
153. SARCOMATOUS TRANSFORMATION OF MYOMATOUS TISSUE.....	228
154. SARCOMATOUS TRANSFORMATION OF MYOMATOUS TISSUE.....	228
155. JUNCTION OF MYOMATOUS AND SARCOMATOUS TISSUE.....	229
156. A RAPIDLY GROWING SUPERITONEAL MYOMA WITH SMALL PAPILLE-LIKE OUTGROWTHS SPRINGING FROM ITS SURFACE.....	238
157. DIFFUSE MYOMATOUS THICKENING OF THE UTERINE WALL. DISCRETE SUBMUCOUS MYOMA AND A SUBMUCOUS MYOMA PRESENTING AN APPEARANCE SUGGESTIVE OF SARCOMA.....	241
158. SUGGESTION OF SARCOMA IN A SMALL SUBMUCOUS MYOMA.....	242
159. SUSPICIOUS CELL CHANGES IN A SMALL SUBMUCOUS MYOMA.....	243
160. SUSPICIOUS CELL CHANGES IN A SMALL SUBMUCOUS MYOMA.....	243
161. SUSPICIOUS CELL CHANGES IN A SMALL SUBMUCOUS MYOMA.....	243
162. LARGE CELLS OCCURRING IN A SIMPLE INTERSTITIAL MYOMA.....	248
163. GIANT-CELLS IN AN EDEMATOUS MYOMA.....	250
164. SUSPICIOUS CELL CHANGES IN AN EDEMATOUS AND PARTLY SUPERITONEAL MYOMA.....	251
165. GIANT-CELLS FROM AN EDEMATOUS MYOMA.....	252
166. A LARGE NUCLEUS IN A MYOMA.....	253

FIG.	PAGE
167. SUSPICIOUS CELL CHANGES IN A SLOUGHING SUBMUCOUS MYOMA.....	253
168. CELL CHANGES IN A MYOMA UNDERGOING PARTIAL COAGULATION NECROSIS.....	256
169. SQUAMOUS-CELLED CARCINOMA OF THE CERVIX; SUBPERITONEAL AND INTERSTITIAL MYOMATA; DOUBLE PYOSALPINX; CYST OF LEFT OVARY.....	263
170. SQUAMOUS-CELLED CARCINOMA OF THE CERVIX AND SUBMUCOUS MYOMA OF THE BODY OF THE UTERUS.....	265
171. SQUAMOUS-CELLED CARCINOMA OF THE CERVIX; PARTIALLY CALCIFIED INTERSTITIAL MYOMA IN THE BODY OF THE UTERUS.....	268
172. MULTIPLE SMALL UTERINE MYOMATA; PRIMARY CARCINOMA OF THE OVARY; PRIMARY CARCINOMA OF THE UTERUS.....	272
173. ADENOCARCINOMA OF THE BODY OF THE UTERUS ASSOCIATED WITH MYOMATA.....	276
174. CARCINOMA OF THE LOWER PART OF THE BODY AND UPPER PART OF THE CERVIX; UTERINE MYOMATA.....	277
175. MYOMA OF THE CERVIX AND CARCINOMA OF THE BODY OF THE UTERUS.....	278
176. MULTIPLE UTERINE MYOMATA: CARCINOMA OF THE LOWER PART OF THE BODY AND UPPER PORTION OF THE CERVIX.....	280
177. MULTIPLE UTERINE MYOMATA; CARCINOMA OF THE BODY OF THE UTERUS.....	282
178. ADENOCARCINOMA OF THE BODY OF THE UTERUS ASSOCIATED WITH INTERSTITIAL MYOMATA.....	283
179. A LARGE MYOMATOUS UTERUS, SHOWING ALSO AN ADENOCARCINOMA OF THE BODY.....	285
180. MULTIPLE UTERINE MYOMATA; ADENOCARCINOMA OF THE BODY WITH EXTENSION TO THE PERITONEAL SURFACE.....	286
181. MYOMATA AND ADENOCARCINOMA OF THE BODY OF THE UTERUS.....	288
182. A LARGE MYOMA OF THE CERVIX; ADENOCARCINOMA OF THE BODY OF THE UTERUS.....	290
183. SUBPERITONEAL, INTERSTITIAL AND SUBMUCOUS MYOMATA; ADVANCED ADENOCARCINOMA INVOLVING CERVIX AND BODY.....	292
184. AN ADENOCARCINOMA OF THE BODY OF THE UTERUS, SO SMALL THAT IT COULD NOT BE RECOGNIZED EXCEPT WITH THE AID OF THE MICROSCOPE.....	295
185. MARKED DILATATION OF THE CERVICAL GLANDS, WITH A TENDENCY TOWARD THE FORMATION OF A POLYP.....	298
186. A CERVICAL POLYP.....	299
187. A CERVICAL POLYP.....	299
188. A RARE FORM OF CERVICAL POLYP.....	300
189. A RARE FORM OF CERVICAL POLYP.....	301
190. SUSPICIOUS EPITHELIAL CHANGES IN A GLAND FROM THE CERVIX, ASSOCIATED WITH A LARGE MYOMATOUS UTERUS.....	303
191. SUSPICIOUS EPITHELIAL CHANGES IN THE MUCOSA OF THE CERVIX, FROM A LARGE MYOMATOUS UTERUS.....	304
192. SUSPICIOUS PROLIFERATION OF THE CYLINDRIC SURFACE EPITHELIUM OF THE CERVIX, ASSOCIATED WITH A LARGE MYOMATOUS UTERUS.....	305
193. A SLIT-LIKE TORTUOUS UTERINE CAVITY.....	306
194. A VERY SMALL UTERINE CAVITY WITH A LARGE MYOMA OF THE FUNDUS.....	307
195. PARTIAL OBLITERATION OF THE UTERINE CAVITY WITH DISAPPEARANCE OF THE MUCOSA.....	308
196. PARTIAL OBLITERATION OF THE UTERINE CAVITY CAUSED BY A SUBMUCOUS MYOMA.....	309
197. A LARGE CLOT IN THE UTERINE CAVITY.....	310
198. THICKENING OF THE UTERINE MUCOSA.....	311
199. THICKENING OF THE MUCOSA IN A MYOMATOUS UTERUS.....	312
200. MODERATE THINNING-OUT OF THE MUCOSA OVER A SUBMUCOUS MYOMA.....	312
201. A SMALL MYOMA PUSHING THROUGH THE MUCOSA.....	313
202. THINNING-OUT OF THE MUCOSA OVER A SUBMUCOUS MYOMA.....	313
203. ATROPHY OF THE MUCOSA OVER A SUBMUCOUS MYOMA.....	314
204. MARKED THINNING-OUT OF THE MUCOSA OVER A SUBMUCOUS MYOMA.....	314
205. A SUBMUCOUS MYOMA ALMOST DEVOID OF MUCOSA.....	315
206. MARKED THICKENING OF THE UTERINE MUCOSA IN A DEPRESSION BETWEEN MYOMATOUS NODULES.....	315

FIG.	Page
207. GLAND HYPERTROPHY IN A CLEFT BETWEEN MYOMATOUS NODULES	316
208. MARKED DILATATION OF THE VEINS OF THE UTERINE MUCOSA	318
209. HEMORRHAGE INTO THE UTERINE MUCOSA	319
210. HEMORRHAGE INTO THE MUCOSA	319
211. RUPTURE WITH SUBSEQUENT THROMBOSIS OF A VEIN OF THE UTERINE MUCOSA OVER A SUBMUCOUS MYOMA	319
212. BRANCHING OF A UTERINE GLAND	320
213. AN ATYPICAL UTERINE GLAND	320
214. AN UNUSUAL UTERINE GLAND	320
215. MARKED BRANCHING OF A UTERINE GLAND	321
216. MARKED BRANCHING OF A UTERINE GLAND	321
217. EDEMA OF THE UTERINE MUCOSA	322
218. DILATED UTERINE GLANDS OVER A SUBMUCOUS MYOMA	323
219. MARKED DILATATION OF THE UTERINE GLANDS OVER A SUBMUCOUS MYOMA	323 324
220. MARKEDLY DILATED UTERINE GLANDS	324
221. A MODERATE GRADE OF DILATATION OF THE GLANDS	325
222. THREE SMALL POLYPI	326
223. SMALL UTERINE POLYPI	326
224. POLYPI ASSOCIATED WITH UTERINE MYOMATA	327
225. A VERY EARLY STAGE OF A UTERINE POLYP	328
226. THE BEGINNING OF A UTERINE POLYP	328
227. A UTERINE POLYP	329
228. CROSS-SECTION OF A LARGE UTERINE POLYP IN A CASE OF MULTIPLE MYOMATA	330
229. CROSS-SECTION OF VERY LARGE UTERINE POLYP IN A CASE OF MYOMA	330
230. A VERY LARGE UTERINE POLYP	331
231. A MYOMA ORIGINATING IN THE UTERINE MUCOSA	333
232. POLYPOID ENDOMETRITIS AND DOUBLE PUS-TUBES ASSOCIATED WITH A MYOMA OF THE FUNDUS	334
233. TUBERCULOSIS OF THE ENDOMETRIUM AND FALLOPIAN TUBES ASSOCIATED WITH A MYOMATOUS UTERUS	336
234. A MYOMATOUS UTERUS ASSOCIATED WITH PYOSALPINX	338
235. A TURO-OVARIAN CYST ASSOCIATED WITH A MYOMATOUS UTERUS	339
236. A TURO-OVARIAN CYST AND DENSE ADHESIONS COMPLICATING A MYOMATOUS UTERUS	339
237. A MYOMA OF THE RIGHT FALLOPIAN TUBE	340
238. RUPTURED TUBAL PREGNANCY COMPLICATING UTERINE MYOMATA	341
239. THE MEDIAN END OF A FALLOPIAN TUBE APPARENTLY TERMINATING IN A MYOMA	343
240. A MULTIFOCULAR OVARIAN CYSTADENOMA ASSOCIATED WITH A MULTINODULAR MYO- MATOUS UTERUS	345
241. A MULTIPLICITY OF PATHOLOGIC CONDITIONS	346
242. AN OVARIAN CYST WITH EARLY PAPILLARY MASSES ASSOCIATED WITH MULTIPLE UTER- INE MYOMATA	347
243. A DERMOID CYST ASSOCIATED WITH A MYOMATOUS UTERUS	349
244. A MULTINODULAR MYOMATOUS UTERUS WITH A PAROVARIAN CYST ON THE RIGHT AND A DERMOID OF THE LEFT OVARY	350
245. A VERY LARGE LEFT OVARY ASSOCIATED WITH A MYOMATOUS UTERUS	351
246. A GREATLY LENGTHENED-OUT OVARY ASSOCIATED WITH UTERINE MYOMATA	352
247. THE COALESCENCE OF A SUBPERITONEAL PEDUNCULATED MYOMA WITH AN OVARY	353
248. CYST OF THE UTERO-OVARIAN LIGAMENT	356
249. CYSTS IN THE UTERO-OVARIAN LIGAMENT	357
250. MYOMA OF THE UTERO-OVARIAN LIGAMENT	359
251. MYOMA OF THE RIGHT UTERO-OVARIAN LIGAMENT	360
252. MYOMA OF THE UTERO-OVARIAN LIGAMENT	361
253. MYOMA OF THE ROUND LIGAMENT	362
254. A MYOMA LYING FREE FROM THE UTERUS AND SITUATED BETWEEN THE TUBE AND OVARY	363

FIG.	PAGE
255. A SUBVESICAL MYOMA.....	365
256. A BLADDER FORCED OUT OF THE PELVIS BY AN INCARCERATED MYOMATOUS UTERUS.....	365
257. A BLADDER CARRIED AS HIGH AS THE UMBILICUS BY A LARGE MYOMATOUS UTERUS.....	366
258. A BLADDER ADHERENT TO TWO MYOMATOUS NODULES.....	367
259. ADHESIONS BETWEEN THE BLADDER AND A MYOMATOUS UTERUS.....	367
260. ADHESIONS BETWEEN THE BLADDER AND THE MYOMATOUS UTERUS.....	368
261. MARKED UPWARD DISPLACEMENT OF THE BLADDER.....	369
262. THE BLADDER LIFTED HIGH INTO THE ABDOMEN BY A MYOMATOUS UTERUS.....	369
263. DISLOCATION AND DILATATION OF A URETER DUE TO A LARGE MYOMATOUS UTERUS.....	378
264. MYOMA IN THE BROAD LIGAMENT DISPLACING THE RIGHT URETER UPWARD AND FORWARD.....	379
265. DISLOCATION UPWARD AND FORWARD OF THE LEFT URETER BY A MYOMATOUS UTERUS.....	379
266. MARKED DISLOCATION OF THE URETERS WHERE THE ABDOMEN WAS FILLED WITH A MYOMATOUS UTERUS.....	380
267. HYDROURETER DUE TO PRESSURE.....	381
268. DISPLACED RIGHT URETER MISTAKEN FOR A DILATED VEIN; LIGATED AND CUT; SUCCESSFUL END-TO-SIDE ANASTOMOSIS.....	383
269. DENSE ADHESIONS BETWEEN THE SIGMOID AND A MYOMATOUS UTERUS.....	386
270. DENSE ADHESIONS OF THE SIGMOID FLEXURE AND OF A LOOP OF SMALL BOWEL TO A TUBO-OVARIAN ABSCESS.....	387
271. AN EXTENSIVE RECTAL TEAR.....	388
272. A MULTINODULAR MYOMATOUS UTERUS, COMPLICATED BY AN OVARIAN CYST ON THE RIGHT AND A DENSELY ADHERENT TUBO-OVARIAN ABSCESS ON THE LEFT.....	389
273. A TUBO-OVARIAN ABSCESS, DENSELY ADHERENT TO THE SIGMOID FLEXURE.....	389
274. CARCINOMA OF THE SIGMOID FLEXURE ASSOCIATED WITH A MYOMATOUS UTERUS.....	393
275. MYOMATA IN OLD AGE.....	395
276. SQUAMOUS-CELLED CARCINOMA OF THE CERVIX ASSOCIATED WITH MULTIPLE UTERINE MYOMATA.....	399
277. CARCINOMA OF THE BLADDER SECONDARY TO SQUAMOUS-CELLED CARCINOMA OF THE CERVIX.....	401
278. INVASION OF A MYOMA BY A SQUAMOUS-CELLED CARCINOMA OF THE CERVIX.....	403
279. ADENOCARCINOMA IN A MYOMA, SECONDARY TO ADENOCARCINOMA OF THE BODY OF THE UTERUS.....	407
280. A LARGE MYOMATOUS UTERUS CHOKING THE PELVIS; SMALL OVARIAN CYSTS ON BOTH SIDES; THICKENING AND RETRACTION OF THE OMENTUM. METASTASES IN THE LIVER SECONDARY TO AN ADENOCARCINOMA IN THE BODY OF THE UTERUS.....	409
281. AN ENLARGED MYOMATOUS UTERUS. ADENOCARCINOMA OF THE BODY OF THE UTERUS, PAPILLOCYSTOMATA OF BOTH OVARIES, WITH EXTENSION BY CONTINUITY TO THE INGUINAL GLANDS.....	412
282. CALCIFICATION OF THE HEART MUSCLE ASSOCIATED WITH UTERINE MYOMATA.....	424
283. HYALINE DEGENERATION OF HEART MUSCLE, ASSOCIATED WITH UTERINE MYOMATA.....	425
284. A VERY EARLY MYOMA.....	431
285. AN EARLY MYOMA.....	432
286. AN EARLY MYOMA.....	433
287. THE ABDOMINAL CONTOUR CAUSED BY A GLOBULAR MYOMATOUS UTERUS.....	437
288. THE ABDOMINAL CONTOUR CAUSED BY A MULTINODULAR MYOMATOUS UTERUS.....	438
289. MARKED ELONGATION OF THE SUPRAVAGINAL PORTION OF THE CERVIX.....	442
290. A MYOMATOUS UTERUS CLOSELY RESEMBLING A PREGNANT UTERUS IN ITS GENERAL CONTOUR.....	468
291. A MYOMATOUS UTERUS RESEMBLING A FETUS IN ITS CONTOUR.....	469
292. THE PERFORATED PREGNANT UTERUS AS SEEN ON REMOVAL.....	471
293. A PREGNANT UTERUS, WITH THE FETUS AND PLACENTA INTACT.....	472
294. ABDOMINAL PREGNANCY OF FOUR YEARS' DURATION.....	476
295. A RUPTURED CORNUAL PREGNANCY.....	479
296. RUPTURE OF THE RIGHT CORNU OF A BICORNATE UTERUS WITH ESCAPE OF THE FETUS.....	481

FIG.	PAGE
297. A SMALL FRAGMENT OF A HYDATIDIFORM MOLE.....	482
298. CHORIO-EPITHELIOMA.....	484
299. CARCINOMA OF THE CERVIX AND LOWER PART OF THE BODY OF THE UTERUS CLINICALLY RESEMBLING A MYOMATOUS ORGAN.....	486
300. A SUBMUCOUS MYOMA CLINICALLY SUGGESTING CARCINOMA OF THE CERVIX.....	487
301. ADENOCARCINOMA OF THE BODY OF THE UTERUS WITH SUPERITONEAL NODULES.....	488
302. A RAHE FORM OF ADENOCARCINOMA OF THE UTERUS.....	490
303. A PECULIAR ARRANGEMENT OF MUSCLE-FIBERS SUGGESTIVE OF CARCINOMA.....	491
304. SARCOMA OF THE BODY OF THE UTERUS.....	492
305. SARCOMA OF THE BODY OF THE UTERUS.....	493
306. FIBROMA OF THE OVARY.....	494
307. A MYOMATOUS UTERUS MISTAKEN FOR AN OVARIAN CYST.....	496
308. A MULTILOCULAR OVARIAN CYST IN FORM RESEMBLING A CYSTIC MYOMA.....	497
309. BILATERAL OVARIAN CYSTS WITH PAPILLARY MASSES ON THEIR SURFACES.....	498
310. SMALL UTERINE MYOMATA; CARCINOMA OF THE OVARY WITH VERY LARGE OMENTAL METASTASES.....	499
311. TUMOR OF THE SIGMOID FLEXURE DUE TO RUPTURE OF RECTAL DIVERTICULA INTO THE SURROUNDING ADIPOSE TISSUE; SMALL PELVIC ABSCESS.....	501
312. RETROPERITONEAL SARCOMA.....	502
313. A PEDUNCULATED SUPERITONEAL MYOMA.....	508
314. A LARGE SUPERITONEAL MYOMA.....	508
315. A DIFFICULT MYOMECTOMY.....	511
316. ABDOMINAL ENLARGEMENT DUE TO A CYSTIC MYOMA.....	513
317. CROSS-SECTION OF A CYSTIC MYOMA WEIGHING 89 POUNDS.....	515
318. MULTIPLE MYOMECTOMY.....	516
319. MYOMECTOMY OR HYSTERECTOMY.....	519
320. THE FIRST STEPS IN ABDOMINAL MYOMECTOMY.....	520
321. KELLY-CULLEN MYOMA ENUCLEATOR.....	521
322. SHELLING THE TUMOR OUT OF THE UTERINE WALL.....	522
323. OBLITERATION OF THE SPACE IN THE UTERINE WALL AFTER REMOVAL OF THE MYOMA.....	523
324. APPEARANCE OF THE UTERUS AFTER ABDOMINAL MYOMECTOMY.....	524
325. UTERINE MYOMA COMPLICATED BY A THREE AND ONE-HALF MONTHS' PREGNANCY.....	530
326. MULTIPLE MYOMECTOMY ON A WOMAN THREE MONTHS PREGNANT.....	530
327. A SUPERITONEAL MYOMA COMPLICATING PREGNANCY.....	531
328. MYOMA OF THE CERVIX OBSTRUCTING THE VAGINA AND COMPLICATING A FOUR MONTHS' PREGNANCY.....	532
329. A MYOMA OF THE BROAD LIGAMENT.....	554
330. PELVIC ADHESIONS FOLLOWING ABDOMINAL MYOMECTOMY.....	557
331. APPEARANCE OF A UTERUS FIVE YEARS AFTER REMOVAL OF A LARGE INTERSTITIAL MYOMA.....	562
332. MYOMATA REMOVED BY ABDOMINAL MYOMECTOMY.....	563
333. A UTERUS ABOUT SIX YEARS AFTER ABDOMINAL REMOVAL OF ALL MYOMATA THAT COULD BE DETECTED.....	564
334. A LARGE SUBMUCOUS MYOMA.....	573
335. A SUBMUCOUS MYOMA GREATLY DISTENDING THE VAGINA.....	573
336. VAGINAL BISECTION OF A SUBMUCOUS MYOMA.....	574
337. METHOD OF REMOVING A VERY LARGE SUBMUCOUS MYOMA.....	574
338. METHOD OF DELIVERING A VERY LARGE SUBMUCOUS MYOMA.....	575
339. SUTURE OF THE CERVIX AFTER REMOVAL OF A SUBMUCOUS MYOMA.....	575
340. APPEARANCE OF THE CERVIX AFTER REMOVAL OF A SUBMUCOUS MYOMA THAT HAD BEEN ATTACHED TO THE VAGINAL PORTION OF THE CERVIX.....	576
341. A VERY VASCULAR SLOUGHING SUBMUCOUS MYOMA.....	583
342. A GAUZE SWAB FOUND IN THE CAVITY OF A MYOMATOUS UTERUS.....	588
343. A MYOMATOUS UTERUS AFTER YEARS OF ELECTRIC TREATMENT.....	589
344. THE MYOMATOUS UTERUS PRIOR TO REMOVAL.....	591

FIG.	PAGE
345. AMPUTATION THROUGH THE CERVIX.....	592
346. THE APPEARANCE OF THE PELVIS WHEN ALL THE CARDINAL VESSELS HAVE BEEN CLAMPED AND THE TUMOR REMOVED.....	593
347. THE UTERUS AS IT APPEARS ON REMOVAL WHEN ALL THE VESSELS HAVE BEEN CONTROLLED WITH CLAMPS AND CUT.....	595
348. APPEARANCE OF THE PELVIS AFTER ALL THE CARDINAL VESSELS HAVE BEEN CONTROLLED.....	596
349. DRAWING THE UTERINE VESSELS INTO THE CERVICAL STUMP.....	597
350. INSERTION OF THE END OF THE ROUND LIGAMENT INTO THE CERVICAL STUMP.....	598
351. APPEARANCE OF THE PELVIS AFTER SUPRAVAGINAL HYSTERECTOMY.....	599
352. APPEARANCE OF THE PELVIS AFTER INSERTION OF THE ROUND LIGAMENT INTO THE CERVICAL STUMP.....	600
353. EXTENSIVE REMOVAL OF THE CERVICAL MUCOSA WHERE SUPRAVAGINAL HYSTERECTOMY IS PERFORMED.....	601
354. EXTENSIVE REMOVAL OF CERVICAL MUCOSA.....	602
355. A DIAGRAMMATIC REPRESENTATION OF THE LEFT TO RIGHT OPERATION.....	606
356. BISECTION OF THE UTERUS.....	609
357. FIRST STEPS IN BISECTION OF THE UTERUS.....	610
358. BISECTION OF THE UTERUS.....	611
359. BISECTION OF THE UTERUS.....	612
360. BISECTION OF THE UTERUS.....	613
361. BISECTION WHERE THE UTERUS COMPLETELY FILLS THE PELVIS.....	614
362. THE VALUE OF BISECTION OF THE UTERUS.....	615
363. TRANSVERSE SECTION OF THE CERVIX AS THE FIRST STEP IN HYSTEROMYOMECTOMY.....	616
364. ABDOMINAL HYSTEROMYOMECTOMY "FROM BELOW UPWARD".....	617
365. APPEARANCE OF THE PELVIS AFTER COMPLETE HYSTERECTOMY.....	618
366. A LARGE RAW AREA LEFT AFTER REMOVAL OF A CYSTIC MYOMA.....	619
367. METHOD OF CONTROLLING A BLEEDING AREA WHERE A NEEDLE CANNOT BE SAFELY EMPLOYED.....	620
368. TEMPORARY CONTROL OF BLEEDING FROM A SUBPERITONEAL PEDUNCULATED MYOMA.....	621
369. METHOD OF ESTABLISHING VAGINAL DRAINAGE.....	624
370. AN INDICATION FOR ABDOMINAL INSTEAD OF VAGINAL HYSTEROMYOMECTOMY.....	628
371. A MYOMATOUS UTERUS ACCURATELY FILLING THE PELVIS.....	630
372. AN INSCARERATED MYOMATOUS UTERUS.....	630
373. RETROPERITONEAL DEVELOPMENT OF MYOMATA.....	631
374. A VERY DIFFICULT HYSTEROMYOMECTOMY.....	632
375. A MYOMATOUS UTERUS BLOCKING THE PELVIS.....	633
376. A MYOMATOUS UTERUS THAT TENDED TO SAG DOWN AND COMPLETELY FILL THE PELVIS.....	634
377. LEAVING THE OUTER LAYERS OF THE MYOMA ATTACHED TO THE BOWEL.....	635
378. METHOD OF DEALING WITH EXTENSIVE INTESTINAL ADHESIONS.....	635
379. A LARGE ABSCESS LYING ANTERIOR TO A MYOMATOUS UTERUS.....	636
380. CIRCUMSCRIBED ABSCESS IN THE OMENTUM ASSOCIATED WITH A DENSELY ADHERENT MYOMATOUS UTERUS AND AN OVARIAN ABSCESS.....	638
381. A LONGITUDINAL SECTION OF THE ABDOMEN SHOWING AN UMBILICAL HERNIA, A LARGE, DENSELY ADHERENT, MYOMATOUS UTERUS, AND AN OVARIAN ABSCESS.....	640
382. A LARGE PEDUNCULATED SUBPERITONEAL MYOMA COMPLICATING PREGNANCY.....	643
383. A NORMAL PREGNANCY ASSOCIATED WITH A LARGE SUBPERITONEAL MYOMA.....	644
384. A PREGNANT MULTINODULAR MYOMATOUS UTERUS.....	645
385. PREGNANCY IN A MULTINODULAR UTERUS.....	647
386. AN EARLY PREGNANCY IN A MYOMATOUS UTERUS.....	651
387. A PURULENT ACCUMULATION IN THE CERVICAL STUMP FOLLOWING SUPRAVAGINAL HYSTERECTOMY.....	664
388. DILATING A CERVIX TO REMOVE AN ACCUMULATION OF PUS BETWEEN THE CERVICAL STUMP AND THE PELVIC PERITONEUM.....	664



MYOMATA OF THE UTERUS.

CHAPTER I.

UTERINE MYOMATA.*

Uterine myomata in the beginning are usually interstitial, but in time tend to force their way to the outer surface, becoming subperitoneal, or toward the uterine cavity, eventually becoming submucous. Should they pass out between the folds of the broad ligament, they develop into intraligamentary myomata, and those starting near the cervix may become essentially cervical myomata.

When the nodule passes to the outer surface of the uterus it may remain firmly fixed and is spoken of as a sessile myoma, in contradistinction to one that has become pedunculated. In Fig. 1 is represented a sessile myoma projecting from the right of the uterus, and attached to the fundus is a pedunculated myoma. The pedicle of the myoma consists of uterine muscle and carries the blood-vessels for the tumor. The myoma itself may be enveloped in a thin covering of uterine muscle, or the normal muscle may cover it only in the vicinity of the pedicle.

The subperitoneal myomata may reach almost any size and may be lobulated or smooth. The smaller ones are usually smooth. Occasionally we find a myoma presenting a particularly rough, volcanic-looking appearance and very hard on pressure. Such a myoma has no outer capsule of normal muscle and is very dense. Fig. 2 shows an excellent example of a mulberry-shaped myoma. It is pedunculated and very nodular, while the remaining myomata are sessile and more or less spheric.

On section, the myomata are very firm. They are glistening white or whitish yellow in appearance, and are composed of bundles of fibers running in all directions. As a rule, they can be easily shelled out from the surrounding muscle, a fact that renders a myomectomy the operation of choice in suitable cases. The myomata stand out in sharp contrast to the surrounding uterine muscle, as seen in Fig. 3. The contrast between the myoma and the muscle is very sharp in the cut specimen, as the myoma remains the same, while the uterine muscle contracts, leaving the tumor standing out in relief.

* Myomata, fibromyomata, fibromata, and fibroids of the uterus are used as synonymous terms and mean precisely the same thing. Of course, in some myomata the muscular tissue predominates, in others, the fibrous tissue. We have never seen a true fibroma of the uterus, that is, a uterine tumor consisting entirely of fibrous tissue. From the pathologist's standpoint the term myoma seems the preferable one. Clinically, each of these terms is so firmly fixed that it is hardly necessary to make any change in the designation.

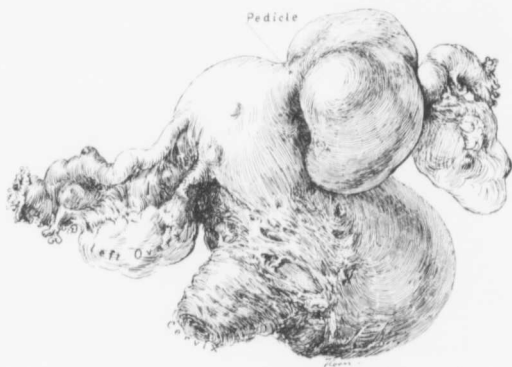


FIG. 1.—SESSILE AND PEDICULATED MYOMATA. ($\frac{1}{2}$ nat. size.)

San. No. 1539. Path. No. 6479. The uterus has been amputated through the cervix. Toward the right, at the junction of the cervix and body, is a broad-based sessile myoma. Springing from the fundus near the origin of the right tube is a pedunculated and slightly subperitoneal myoma. The appendages are normal. With our present knowledge the ovaries would have been left.

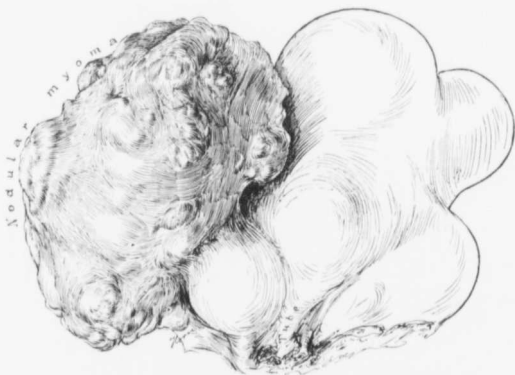

FIG. 2.—MULBERRY-SHAPED AND SESSILE MYOMA. ($\frac{1}{2}$ nat. size.)

Gyn. No. 10403. Path. No. 6618. Occupying the fundus are several globular sessile nodules. Projecting toward the posterior surface is a markedly nodular, mulberry-shaped myoma, which was devoid of muscular covering and was excessively hard.

Usually myomata are discrete and sharply defined, but in some instances we have not only well-outlined nodules, but also a general myomatous tendency. Such a condition is well shown in Fig. 4. The surface of the uterus is uneven, owing to the presence of numerous small subperitoneal myomata. Near the cervix, and also at the fundus, are discrete myomata, while the outer layers of uterine muscle from cervix to fundus are composed of myomatous tissue only imperfectly divided into definite myomata.

Number of Myomata.—Before operation it is usually impossible to tell just how many myomata the uterus contains. Sometimes it may be the seat of one small or large tumor, but very frequently it contains several, and in a few cases the uterus may be literally riddled with tumors, as in Gyn. No. 12849.

In Case 4903 the myomatous uterus filled the lower two-thirds of the abdomen and 32 myomata were counted. The uterus in Case 8354 contained between 30 and 40 nodules. Such large numbers are the exception. The uterus, as a rule, contains less than ten myomata and often only one or two.

Size of Myomata.—The tumor may consist of the uterus riddled with myomata, or the enlargement may be due to one or more interstitial or subperitoneal nodules.*

In a few of our cases the uterus was relatively small and operation was indicated for the loss of blood, not for the size of the myomata. Small submucous tumors at times give rise to alarming hemorrhage.

In the vast majority of our cases the tumor filled the pelvis and extended into the lower abdomen. During the early days of the hospital many myomata of large proportions were encountered. For example, in Case 3394 the tumor weighed 22 pounds; in Case 6418, 29 pounds; and in Case 3440, 30 pounds. The myomatous tumors may not only fill the abdomen, but occasionally are so

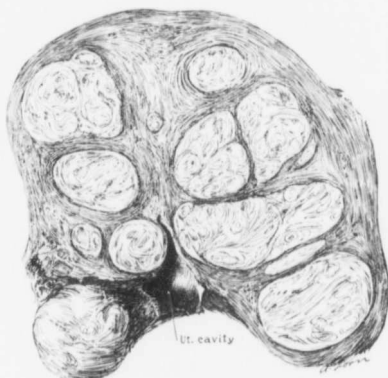


FIG. 3.—AN ORDINARY MYOMATOUS UTERUS ON SECTION.
($\frac{2}{3}$ nat. size.)

GYN. NO. 3985. PATH. NO. 986. The uterine cavity is relatively small and has been encroached upon. Occupying the upper part of the body are numerous myomata of various sizes and shapes, and with the muscle bundles arranged in whorls or passing in almost any direction. The myomata stand out in sharp contrast to the normal muscle, which is much darker in color.

* In a few cases the myomatous uterus apparently increases perceptibly in size at the menstrual period. This was particularly noticeable in Cases 4617 and 9221.

large that they extend upward beneath the costal margins, as in Cases 4285 and 6324.

Myomata may reach tremendous proportions, as in Case McA. (p. 512). This patient was operated upon by one of us* in 1906. The myoma was attached to the uterus by a small pedicle, and weighed 89 pounds. It had received the greater part of its nourishment from the omentum. As far as we can learn from

the literature, it was the largest myoma ever successfully removed.

Shape of the Myomata.—When we remember that myomata may be single or multiple, that they may be situated in any part of the uterus, and may be small or reach very large proportions, it is clearly evident that the uterus or the myomatous masses, as a result of the abnormal enlargement, may assume a great variety of shapes.

Pear-shaped Myomata.—When the uterus contains one large interstitial myoma it may be pear-shaped, and resemble in contour a pregnant uterus. (See p. 468.) Case 2881 (Path. No. 359) offered a very good example of such a condition. The uterus was pear-shaped and measured 31 x 28 x 21 cm. The enlargement was caused chiefly by an interstitial myoma, 19 x 20 x 23 cm. Pear-shaped enlargement of the uterus is relatively common.

Kidney-shaped myomata are not infrequently met with; they are usually subperitoneal and pedunculated, and are

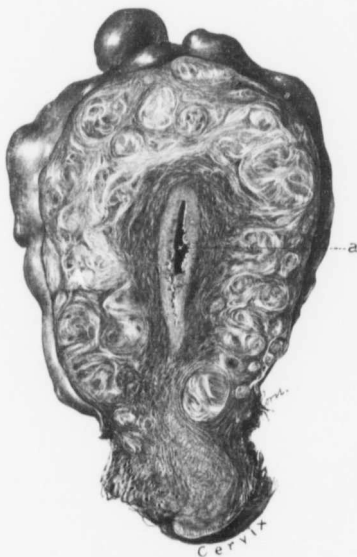

FIG. 4.—A GENERAL "MYOMATOUS TENDENCY." (Nat. size.)

Path. No. 3601. The uterus is not much enlarged, but its surface is nodular, owing to the presence of numerous small subperitoneal myomata. Nearly all the uterine muscle is occupied by small myomata, or its fibers show a definite diffuse myomatous tendency. a is the uterine cavity.

generally associated with interstitial and submucous nodules. In Case 3281 the uterus contained interstitial and submucous myomata, while projecting from the right side of the uterus was a kidney-shaped tumor, 9 x 10 x 18 cm. On the left side of the uterus was an irregular, kidney-shaped mass, 16 x 18 x 29 cm. The concavity of this mass was directed toward the uterus.

* Thomas S. Cullen, A Series of Interesting Gynecologic and Obstetric Cases, Jour. A. M. A., May 4, 1907.

In Case 3340 (Path. No. 607) the uterus was 10 x 11 x 12 cm. and studded with small subperitoneal, interstitial, and submucous myomata. In addition there were three large pedunculated submucous nodules, a mulberry-shaped tumor 13 cm. in diameter, and two kidney-shaped masses, each averaging 13 cm. in its longest diameter. One was situated to the left, the other to the right, of the uterus. Kidney-shaped subperitoneal myomata are fairly common.

Heart-shaped myomata may be interstitial or subperitoneal. In Case 3111 (Path. No. 479) the uterus was 9 x 9 x 10 cm., the enlargement being caused by small myomata. Springing from the right cornu was a pedunculated myoma, 4.5 x 5 x 7 cm., and from the left cornu a heart-shaped, slightly lobulated mass, 5.5 x 8 x 10 cm.

In Case 3199 (Path. No. 524) the uterus contained several myomata. The anterior wall was occupied by a heart-shaped myoma, 11 x 12 x 14 cm.

The pelvic tumor in Case 3320 (Path. No. 589) was 13 x 21 x 28 cm. and heart-shaped. Lying on its anterior surface were the uterus and appendages intact.

Mulberry-shaped myomata are subperitoneal and pedunculated and may be small or large. They are easily recognized by their globular form and rough nodular surface. They are not very common.

Projecting from the myomatous uterus in Case 2800 (Path. No. 312) was a large, mulberry-like tumor, 12 x 19 x 19 cm. This was covered with dense adhesions, and was attached by a pedicle 2 x 3 cm.

The uterus in Case 3340 (Path. No. 607) contained subperitoneal, interstitial, and submucous myomata. One of the three pedunculated subperitoneal myomata had a mulberry-like surface and was 13 cm. in diameter.

In Case 3942 (Path. No. 964) the pedunculated, subperitoneal, mulberry-like myoma, 8.5 x 11.5 x 12.5 cm., was removed and the uterus saved.

Three-leaf-clover-shaped Myomata.—In Case 2718 (Path. No. 259) the uterus viewed from the front resembled in form an immense three-leafed clover. The hilum corresponded to the sacrum.

Saddle-bag Myomata.—Occasionally, when a myoma is present on either side of the uterus, the picture suggests a saddle-bag. In Case 4845 there were two large myomatous masses, one on either side of the uterus, "giving it a saddle-bag appearance." Similar pictures were noted in Cases 3689 and 6542.

Sacral Markings.—Occasionally, where the tumor reaches large proportions and still lies in the pelvis, it may rest firmly on the sacrum. It will then show a concavity where it has come in contact with the sacral promontory. In Case 3130 (Path. No. 499) the uterus contained a few small myomata. Springing from the right side was a subperitoneal myoma, 14 x 18 x 25 cm. Its posterior surface presented a deep depression, corresponding to the promontory of the sacrum. On either side of this depression were prominent lobulations.

In Case 3440 (Path. No. 674) a myoma weighing 30 pounds was attached to the small myomatous uterus by a pedicle 4 cm. in diameter. The under surface

of the tumor presented a depression which was an exact counterpart of the sacral prominence.

Pelvic Molds.—Where the tumors are firmly fixed in the pelvis and continue to enlarge, they may finally become molded to the form of the pelvis. In Case 1767 the uterus contained at least 30 myomata, and filling the pelvis was a tumor which was a "true cast of the pelvis." This myoma seemed to be made up of a great mass of nodules pressed together.

This process of molding was also noted in Cases 8882 and F., C. H. I., August 10, 1902.

Resembling a Fetus.—The resemblance of a myomatous uterus to a fetus is described on page 469.

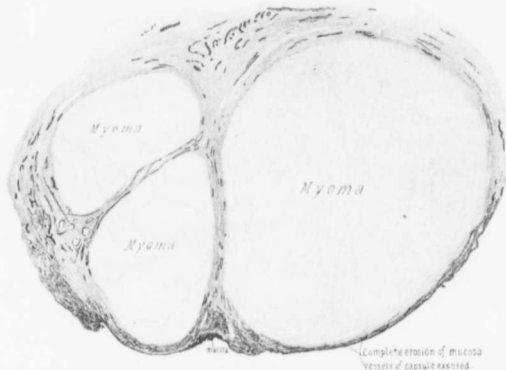


FIG. 5.—INJECTION OF A MYOMATOUS UTERUS. ($\times 12$ diam.)

The uterus after injection has been cut in two. The uterine walls are very vascular, but the myomata in this particular case show practically no blood-supply. The uterine mucosa is in places intact, but over a wide area shows a definite erosion. (After John G. Clark.)

The Blood-supply of Myomata.—This subject has been very satisfactorily worked out by John G. Clark,* who injected a large number of myomatous uteri. He found that, taken as a whole, the uterine muscle was much more vascular than the myomata.

The blood-supply of the myomata is, of course, derived from the uterine muscle. If the nodules are small, the blood-vessels surrounding them are correspondingly small, but where the myomata reach very large proportions, very large blood-vessels are seen passing from the muscle and ramifying over the surface of the tumor. The veins may reach 7 mm. or more in diameter. The arteries are much less in evidence.

* John G. Clark, The Cause and Significance of Uterine Hemorrhages in Cases of Myoma Uteri, Johns Hopkins Hosp. Bulletin, 1899, vol. x, page 11.

If the myoma is a very large tumor with a thin outer covering of uterine muscle, two definite vascular systems can at times be made out, the one supplying the muscle, the other forming the network over the surface of the tumor.

When an injected myomatous uterus is cut in two, the contrast between the uterine muscle and myomatous tissue is very sharply defined. In practically all cases the uterine muscle is richly supplied with blood. In some the myomata are almost devoid of vessels, as seen in Fig. 5, but not infrequently many vessels are scattered throughout the tumors.

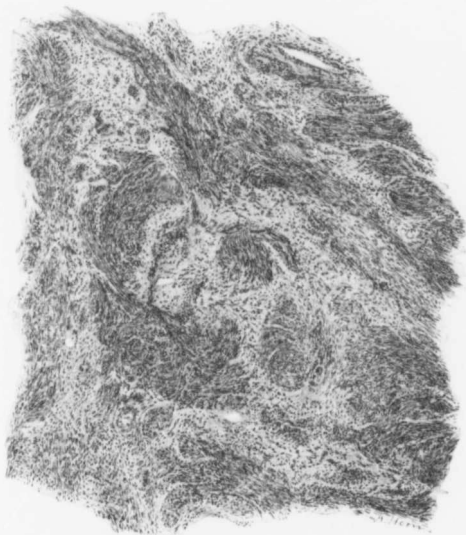

FIG. 6.—TYPICAL MYOMATOUS TISSUE. ($\times 100$ diam.)

Gyn. No. 2691. Path. No. 265]. Scattered throughout the fibrous-tissue matrix are bundles of non-striated muscle-fibers cut longitudinally and transversely. The muscle bundles present a wavy appearance. The nuclei of the muscle-fibers are spindle-shaped.

When the myomata are very large, veins of exceptional size may be seen scattered throughout the tumor. In Case 2881 (Path. No. 359), the myoma measured 19 x 20 x 23, and thin-walled veins fully 8 mm. in diameter were found in the tumor. Again, in Case 3440 (Path. No. 674), the tumor weighed 30 pounds, and there were slit-like openings, 5 to 7 mm. in diameter, in its substance. These veins closely resembled the veins of a liver.

Histologic Appearances of Myomata.—Sections from myomata are remarkably uniform in their appearance. The tissue is made up of bundles of non-

striped muscle-fibers cut lengthwise and transversely. These bundles may form graceful curves, be perfectly circular, or run in and out in all directions. When the myomata are young, the circular arrangement is often very clearly seen, as in Fig. 286 (p. 433). In the very small myomata the tumor consists almost entirely of muscle, but when it reaches 1 cm. or more in diameter, there is an admixture of muscle and fibrous tissue. Fig. 6 shows the characteristic myomatous picture. Here longitudinal and cross-sections of non-striped muscle are found scattered irregularly throughout a matrix of fibrous tissue.

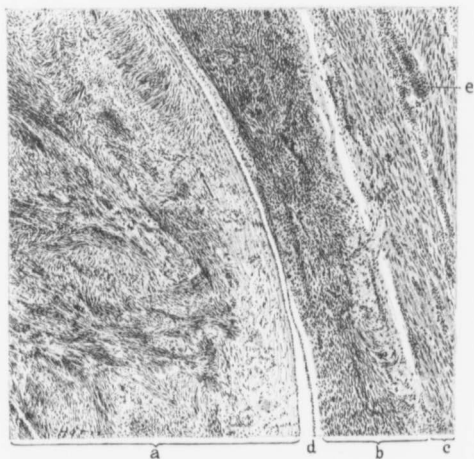


FIG. 7.—THE LINE OF CLEAVAGE BETWEEN A MYOMA AND THE UTERINE MUSCLE. (X 55 diam.)

Gyb. No. 3008. Path. No. 435. a is myomatous tissue; b an outer and rough capsule also composed of myomatous tissue; c is uterine muscle. At d is a definite point of cleavage, the myoma being separated from its outer myomatous capsule by a well-defined space. At e the uterine muscle shows a definite inflammatory reaction.

In practically all myomata that reach any appreciable size hyaline degeneration is noted in the fibrous tissue, in the muscle, or in both. As a rule, the muscle-fibers in the myoma are closely packed together and stain somewhat more deeply than the surrounding uterine muscle.

The line of junction between the growth and the uterine muscle is usually not only sharply defined, but there is a definite cleavage. In Fig. 7, for example, there is a space separating the myoma from the uterine wall. There are, of course, exceptions to this rule. In Fig. 8 the myoma is sharply differentiated from the muscle, and yet they are so inseparably united that it would be impossible to shell this tumor out. Occasionally the myoma, instead of forming a

globular nodule, may grow out irregularly into the surrounding muscle. Such a picture is presented in Fig. 9.

Individual Cells.—The individual muscle-fibers are spindle-shaped. The nuclei are long and narrow. When the muscle-fiber is cut through at its center, we see a small spherical mass of protoplasm and a central small round nucleus. If the cell is cut obliquely, it may appear oval, and the nucleus also ovoid, in shape. A cross-section of a muscle-fiber near the end will yield a small mass of protoplasm, devoid at this point, of course, of a nucleus. Many such little masses of protoplasm are seen in the muscle bundles. When the muscle nuclei are very closely packed together, the tissue naturally stains more deeply. Nuclear figures are rarely, if ever, seen in the ordinary myoma stained in the routine manner.

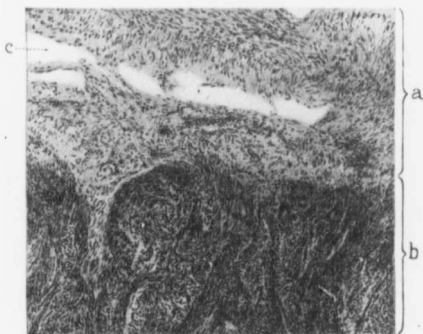


FIG. 8.—BLENDING OF A MYOMA WITH THE UTERINE MUSCLE. ($\times 100$ diam.)

Gyr. No. 2570. Path. No. 162. a is uterine muscle; b very cellular myomatous tissue. The line of junction is very sharply defined, but there is no point of cleavage, the myoma merging directly into the uterine muscle. c is a blood-vessel.

Professor Mallory,* of Harvard University, in 1904 described several new stains by means of which he was able, in appropriately preserved material, to bring out clearly the neuroglia, myoglia, and fibrogia of the various tumors. In speaking of myoglia he says: "The study of a series of leiomyomata obtained chiefly from the uterus shows that while, in general, the smooth-muscle cells closely resemble those found in normal tissues, they may vary considerably in form from the normal type. For example, a leiomyoma occasionally occurs in which the cells are very long and thin and the nuclei are the slenderest of rods. In still other cases the cells are short and thick and the nuclei have a long or short oval form. This difference in the shape of the cells depends, in part at

* F. B. Mallory, A Contribution to the Classification of Tumors, *Journal of Medical Research*, vol. xiii, January, 1905. See also F. B. Mallory, The Results of the Application of Special Histological Methods to the Study of Tumors, *Jour. Exper. Medicine*, vol. x, No. 5, September 5, 1908.

least, on the rapidity of growth of the tumor. In general it may be said that the slowest growing smooth-muscle cells are the most slender."

"The myoglia fibrils in the tumors vary somewhat in number and coarseness, but always form a well-marked and characteristic feature of the cells. As in normal tissues, they remain closely applied to the cell columns; so far as can be determined, they do not leave the surface of cell protoplasm and mix with the intercellular connective-tissue fibrils surrounding the smooth-muscle cells. The myoglia fibrils show a certain tendency to twine together, especially in tissue

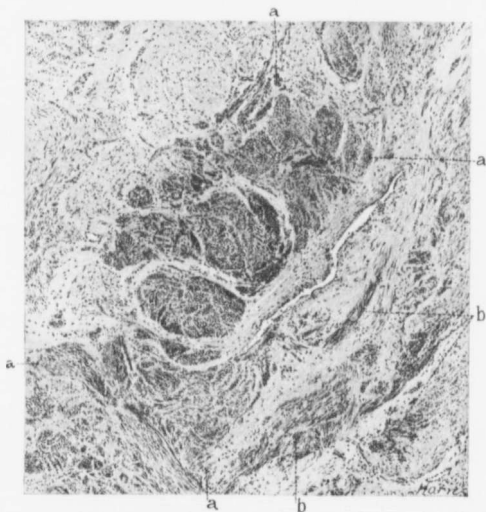


FIG. 9.—THE IRREGULAR EXTENSION OF A MYOMA INTO THE UTERINE MUSCLE. ($\times 70$ diam.)

Gyn. No. 2010. Path. No. 1536. Projecting into the field from the left lower corner and occupying the middle is myomatous tissue, recognized by the dark stain. Its confines are indicated by a. At b are a few isolated myomatous bundles. The remaining tissue, which stains palely, is uterine muscle.

which is somewhat edematous, so as to form what seem to be unusually coarse fibrils. This appearance is most marked at the ends of cells, where they are drawn out thin, so that the fibrils running from one cell to the next are brought into close apposition."

In order that the myoglia may be carefully studied, small pieces must be immediately placed in Zenker's fluid. In the ordinary routine laboratory examination, as usually carried out, it is impossible to detect the finer structures of the muscle-fiber.

Position of the Body of the Uterus.—The position will depend upon the size and situation of the myomata. If they are of small size and scattered uniformly throughout it, the organ retains its normal position (Fig. 10). If a myoma develops from the upper part of the uterus, the normal relations of the uterus may still be maintained. If a myoma develops in the posterior wall, the fundus may be pushed forward toward the symphysis; if the myoma originates in the anterior wall, the fundus may be forced back into Douglas' sac.

When a myoma develops in the lateral wall and spreads out into the broad ligament, the uterus will usually be forced to the opposite side (Fig. 11).

When the myomata are multiple and reach large proportions, the uterus may rest like a cap on the top of the tumor, as noted in Cases 3133 and 8344. Sometimes the uterus is so hidden between myomata that it is difficult to find, as in Case 10403. In Case McA., in which

an 89-pound subperitoneal, pedunculated myoma was removed, the uterus lay behind the tumor and near the liver.

Condition of the Uterine Muscle.—If the myomata are small, or if the tumors are subperitoneal and pedunculated, the uterus is usually normal in size, but when it contains several myomata, there is commonly an increase in size. This increase is undoubtedly caused by the myomata, as evidenced by the fact that the enlarged uterus, after the myomata have been removed, gradually undergoes involution until it becomes normal in size. The following cases clearly illustrate the increase in size of the uterus.

In Case 5021 a myoma, 7 x 11 x 11 cm., was removed *per abdomen* from the posterior wall. The uterus, immediately after removal of the tumor, was two and one-half times its natural size.

The smooth-walled uterus in Case 9221 reached nearly to the umbilicus. An interstitial myoma, 9 x 10 cm., was removed from the right cornu. The uterus, after removal of the tumor, was between two and three times its natural size. At the end of three weeks it was little larger than normal.

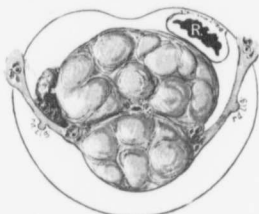


FIG. 10.—A TRANSVERSE SECTION THROUGH A MYOMATOUS UTERUS.

Gyn. No. 2881. The uterus was pear-shaped, 31 x 28 x 21 cm. The transverse section has been made just above the ovaries. The uterine cavity is surrounded by myomatous tissue. The greater part of the uterine muscle is spread out over the surface of the myoma in the posterior wall.

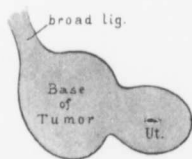


FIG. 11.—THE MYOMATOUS UTERUS AS VIEWED ON TRANSVERSE SECTION THROUGH THE CERVIX.

Gyn. No. 701. The cervix on section looks normal. Attached to it on the right is a portion of the myoma, which extends out into the broad ligament. From the sketch it is seen that the myoma projected deeper into the pelvis than did the cervix.

With a myoma in this position the left to right operation would yield the best results. Much care would be necessary to avoid injury to the right ureter.

When the myomatous uterus is very large, the blood-vessels are naturally much increased in size and the uterine muscle is very vascular.

Occasionally the uterine muscle may undergo partial hyaline degeneration, as noted in Case 2852. The globular uterus was 13 x 13 x 14 cm., the chief increase in size being due to the presence of a degenerated and interstitial myoma 12 cm. in diameter. The uterine muscle was considerably altered. The muscle-bundles were separated from one another by hyaline material containing only a few nuclei. The individual muscle-fibers appeared to have undergone this hyaline change. In other portions the muscle appeared normal.

CHAPTER II.

PARASITIC UTERINE MYOMATA.

Myomata that have for some reason become partially or almost completely separated from the uterus and receive their main blood-supply from another source may be termed parasitic.

Uterine myomata at first obtain their entire nourishment from the uterus, but may in time derive the greater part of it from (1) the omentum; (2) the Fallopian tubes; (3) the mesenteric vessels; (4) the large or small intestine; (5) the bladder; (6) the abdominal wall; (7) the broad ligament; (8) several of these sources at the same time.

We are here chiefly interested in the rôle that the omentum plays when the myoma gradually changes its source of blood-supply. Our own observations have satisfied us that the omentum is the guardian of the abdominal organs. In many cases, when myomata exist, the omental adhesions are associated with dense pelvic adhesions or with pus-tubes. Here it is perfectly natural that the omentum should become firmly adherent. Of special interest is that group of cases in which the tubes and ovaries are comparatively normal and offer no particular incentive for the omental adhesions, and yet in which, for some reason, the omentum manifests a certain affinity for the subperitoneal and usually pedunculated nodule, becomes adherent to it, and soon furnishes a large part of its sustenance. Sometimes only a few vessels pass from the omentum to the myoma, as in Fig. 24 (p. 34), where four vessels are seen entering a pedunculated nodule. As the pedicle of the tumor becomes smaller and its original source of nourishment diminishes, the omentum sends in more and more vessels, as seen in Fig. 13 (p. 17), Fig. 14 (p. 17), Fig. 15 (p. 18), and Fig. 16 (p. 19). These vessels may spread out over the surface, divide into smaller branches, and then enter the tumor, as shown in Fig. 18 (p. 22) and Fig. 20 (p. 25); or they may plunge at once into the depth, as is shown in Fig. 24 (p. 34). As a rule, we have found large arteries accompanied by two veins. The veins in some instances reach tremendous proportions. In Case C., Hagerstown, for instance, some of them were more than 1 cm. in diameter and looked like small snakes.

CHANGES IN THE OMENTUM.

The function of the omentum can be most beautifully followed in these cases. If it be called upon for a small blood-supply, a few vessels are at once sent in and but little change is noted in the omentum. But when the tumor is large and

much is required of the omentum, the vessels rapidly increase in size and the omental fat gradually disappears. This gradual absorption of fat is well followed in Fig. 17 (p. 20), Fig. 18 (p. 22), Fig. 20 (p. 25), Fig. 21 (p. 26), Fig. 23 (p. 29), and Fig. 24 (p. 34). The first change noted is that the vessels in the vicinity of the tumor stand out clearly, and that the tissue between the vessels is becoming rarefied. Later, the vessels near the tumor are merely supported by the peritoneal folds of the omentum. The fat continues to be absorbed until little or no trace of omentum remains, and the vessels are only recognized as omental on account of their relation to the transverse colon. This is strikingly well shown in Fig. 25 (p. 36), in which a small fringe of fat, 1 cm. broad and lying against the transverse colon, was all that remained of the omental adipose tissue.

The omental vessels seem to have an unlimited capacity, as in Case C. (p. 24), in which a very large myoma with a small pedicle existed. Here not only was there a liberal supply of omental nourishment for the upper surface of the tumor, but the omentum had sent down a bunch of vessels to its lower pole. These vessels formed a cord 6 cm. in diameter. They were held together by peritoneum, but were free, the only fixed points being their points of origin at the transverse colon and their disappearance into the lower end of the tumor. At operation we lifted this cord up, completely encircling it with the hand. It looked just like a bunch of small snakes. One isolated omental vessel lay absolutely free for a distance of 18 cm. The function of the omentum is certainly marvelous, as can be seen on reference to Case McA. (p. 512). Here the subperitoneal tumor weighed 89 pounds and was attached to the uterus by a pedicle 1 x 1.5 cm. in diameter. The chief nourishment had come from the omentum.

In rare instances the myoma becomes completely separated from the uterus and receives its entire nourishment from the omentum. Such an example is furnished by Case 14709 (see Fig. 23, p. 29).

Lymphatics.—When large myomata exist, dilated lymphatics are often found in the broad ligaments. It is but natural that with the increased activity of the omentum its lymphatics also should be increased in size.

In Fig. 17 (p. 20) there is marked dilatation in the broad ligament lymphatics, as is indicated at *a*, and coursing down the omentum, which is densely adherent to the pedunculated myoma, are markedly dilated and tortuous lymph-channels.

In Fig. 18 (p. 22) the omentum is rapidly losing its fat, and its peritoneum is disappearing, leaving oval clear spaces. At *e* is a very large tortuous lymph-channel. As a rule, these large lymph-vessels collapse soon after removal and, therefore, frequently escape observation in the laboratory.

Etiology.—The cause seems inherent in the myomata and not in the surrounding organs. The uterus is naturally trying to get rid of its interstitial nodules, and they consequently become submucous and subperitoneal. Now, when a myoma becomes subperitoneal, the continued uterine contraction grad-

ual
tract
bloo
hyal
roug
I
fart/
Fig.
Fig.

Fig.

by
de
fir
ad
by

tl
e
u
a
t
I
f

ually renders it pedunculated, and finally the mere weight of the nodule making traction on the pedicle will still further attenuate it. Owing to the diminished blood-supply, these nodules are usually prone to degenerate, and often show hyaline degeneration or necrosis. The peritoneal surface develops a slight roughening, and the omentum at once becomes adherent.

If this reasoning be true, we would naturally expect the part of the tumor farthest away from the pedicle to suffer first. A reference to Fig. 13 (p. 17), Fig. 14 (p. 17), Fig. 15 (p. 18), Fig. 16 (p. 19), Fig. 17 (p. 20), Fig. 18 (p. 22), Fig. 20 (p. 25), and Fig. 25 (p. 36) will show that in each of these cases

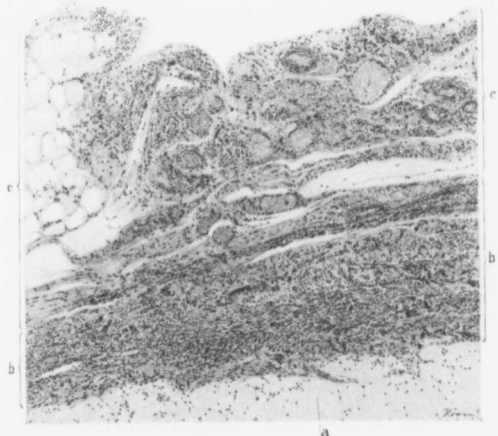

FIG. 12.—OMENTAL BLOOD-VESSELS THAT ARE KEEPING ALIVE THE OUTER LAYERS OF A MYOMA WHICH SHOWS ALMOST TOTAL HYALINE DEGENERATION. ($\times 80$ diameters.)

Gyn. No. 11898. Path. No. 8284. The myoma was enveloped in omentum and was attached to the uterus by a pedicle 1 cm. in diameter. The appendages were normal. Microscopically, the tumor showed marked hyaline degeneration and coagulation necrosis, as well as areas of calcification (Fig. 101, p. 128). a indicates the outer confines of the hyaline degeneration; b, the remaining outer zone of myomatous tissue; and c, the limits of the adherent omentum. To the left the omental fat is still seen, but toward the right it has been entirely replaced by fibrous tissue and many new and relatively large blood-vessels.

the omental vessels entered the tumor at the point most distant from its connection with the uterus. The omentum appears to be fulfilling its normal useful function of guarding other abdominal organs from danger. If the omentum does not furnish the myoma with the necessary nourishment, the latter may develop an abscess in its interior and open into the intestine (as seen in Fig. 32, p. 46), or else it may become a parasite upon the intestines or bladder for its sustenance.

Special Points in the Operative Treatment when Large Omental Adhesions Exist.

—Naturally, the first thing to do after opening the abdomen will be to control the

omental vessels. We always make it a point to tie off the omental vessels twice on the proximal and once on the distal or tumor side. These vessels are so delicate and tear so easily that we invariably tie instead of clamping and then tying. The mere weight of the artery forceps is at times sufficient to tear them, and serious hemorrhage may follow.

Since it is of the greatest importance to always tie under sight, the incision must be sufficiently long to enable the operator to see all the vessels clearly. When the omental adhesions extend over a wide area, the incision may be gradually lengthened as is found necessary, but an attempt should never be made to liberate adhesions far up under the abdominal wall, as they may contain large veins or arteries.

In Case McA. (p. 512), in which the tumor weighed 89 pounds, these precautions were strictly observed, and yet the tumor was everywhere so intimately attached that, notwithstanding our care, a small piece of liver came away with it. If a careful and methodic tying of the omental vessels be practised, even the largest tumors may often be removed with a loss of not over two ounces of blood.

Fig. 22 (p. 28) gives a very good idea of the huge congeries of omental vessels that the operator will occasionally encounter.

Cases in which the Omentum Affords Part of the Blood-supply to Parasitic Myomata.—This condition is relatively common.* We have picked out a number of the more characteristic cases, so that the various and progressive changes in the omentum can be clearly followed.

Gyn. No. 694.

A multinodular myomatous uterus with a partially parasitic myoma, receiving much of its blood-supply from the omentum (Fig. 13).

E. P., white, single, aged thirty-six. Admitted April 23; discharged June 20, 1891. This tumor had grown rapidly and had almost completely filled the ab-

* All the following 37 cases showed very extensive omental adhesions. In the 25 designated by an asterisk the myomata were partially parasitic.

Gyn. No. 515*	Gyn. No. 3974*	Gyn. No. 12139
" " 660*	" " 4293	" " 12155*
" " 694*	" " 4869	" " 12216
" " 1151*	" " 5392	" " 12696*
" " 13833*	" " 5784*	" " 12738*
" " 2800*	" " 6367	" " 12864
" " 3216	" " 6432	" " 13023*
" " 3296*	" " 7220	" " 13039*
" " 3387*	" " 7549*	" " C. H. I. (P.).*
" " 3440	" " 7739*	Hagerstown (C.).*
" " 3558*	" " 9027*	Frederick (B.).*
" " 3842	" " 9078*	
" " 3950*	" " 11898*	

domen after one year. It had been first noticed two years previously. Operation, May 2, 1891. Supravaginal hysterectomy. The omental adhesions were tied off and the uterus was removed. The patient made an uninterrupted recovery. The chief interest centered in the large subperitoneal and pedunculated myoma, which had several omental vessels entering through its upper surface.

Gyn. No. 3950.

Double hydrosalpinx; left ovarian abscess, with dense adhesions. A pedunculated and partially parasitic myoma, receiving most of its blood-supply from the omentum (Fig. 14).

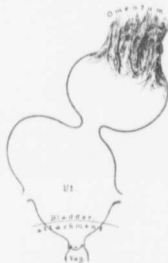

FIG. 13.—A PARTIALLY PARASITIC MYOMA RECEIVING MOST OF ITS BLOOD-SUPPLY FROM THE OMENTUM.

Gyn. No. 694. This sketch represents the appearance at operation. The uterus is much enlarged. Above the right tube is a globular tumor, and above and to the left is a pedunculated nodule receiving the greater part of its nourishment from the omentum. The parasitic vessels are relatively very large and the omental fat has disappeared.

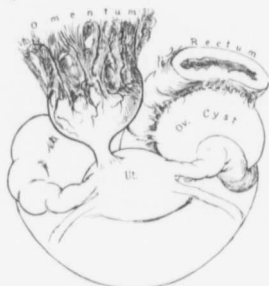

FIG. 14.—A PARTIALLY PARASITIC MYOMA RECEIVING A LARGE BLOOD-SUPPLY FROM THE OMENTUM.

Gyn. No. 3950. The uterus is relatively normal in form. Attached to its posterior surface by a narrow pedicle is a globular calcified nodule. Its entire upper surface is covered by omental vessels, which spread out over its peritoneal covering. Both Fallopian tubes are the seat of a hydrosalpinx and the left ovary has been converted into a large abscess which is densely adherent to the rectum.

M. E., colored, married, aged thirty-seven. Admitted November 9; discharged December 18, 1895. The patient has had two children, the youngest seven, also one miscarriage. Five years ago she noticed a small tumor in the right inguinal region. Only for the past year has it been painful and tender; it was movable at first, but has been adherent for the last five months. She has a constant dull aching pain at the umbilicus.

Operation, November 14, 1895. Hysteromyomectomy. There were general pelvic adhesions. Attached to the posterior surface of the uterus by a small pedicle was a calcified myoma, receiving much of its nutrition from the adherent omentum (Fig. 14). Each tube was the seat of a hydrosalpinx and the left ovary had been converted into a large abscess. The patient made a satisfactory recovery.

Gyn. No. 3558. Path. No. 742.

A partially parasitic myoma, receiving most of its nourishment from the omentum; normal uterus and appendages (Fig. 15).

E. B., white, single, aged thirty-two. Admitted June 3; discharged June 29, 1895. Five years ago her menstrual flow began to be profuse and her physician told her that she had a tumor. The abdomen is tender and she has sharp pains throughout it.

Operation, June 6, 1895. Myomectomy. Attached to the right cornu by a long slender pedicle was a myoma, 9 x 9 cm., movable, non-adherent except posteriorly to the vermiform appendix, to which it was attached by light velamentous adhesions, and anteriorly to the omentum, which sent in several large vessels (Fig. 15). The patient made an uninterrupted recovery.

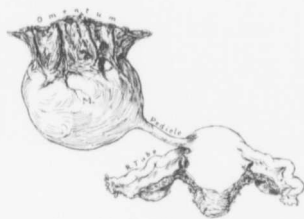


FIG. 15.—A LARGE PEDUNCULATED MYOMA RECEIVING NEARLY ALL OF ITS BLOOD-SUPPLY FROM THE OMENTUM.

Gyn. No. 3558. The sketch represents the appearance as seen at operation. The uterus and appendages are normal. Attached to the right cornu by an unusually long and slender pedicle is a myoma which has received nearly all its blood-supply from the omentum. As seen from the history, the myoma showed considerable degeneration. In a short time the tumor would probably have entirely lost its connection with the uterus.

the surrounding tissue. The pedicle of the tumor is 1.5 cm. in diameter.

Gyn. No. 3974. Path. No. 980.

Subperitoneal and interstitial uterine myomata; large subperitoneal nodule, partially parasitic and receiving its main blood-supply from the omentum (Fig. 16).

M. W., colored, single, aged thirty. Admitted November 19; discharged December 28, 1895. Three years ago the patient noticed an abdominal enlargement, first on the left side. The tumor apparently disappeared for six months, evidently because it had been dislodged. It reappeared and gradually increased in size.

Operation, November 26, 1895. Hysteromyectomy. Through an incision 20 cm. in length a large myoma, springing from the left horn, was delivered. The highest post-operative temperature was 101.5° on the second day. Recovery was complete.

Path. No. 980. The specimen comprises the uterus with its appendages and two large pedunculated tumors. The uterus is irregular and nodular, approximately $7 \times 5.5 \times 5$ cm. Its surface is covered with a few vascular adhesions, and presents numerous bosses and pedunculated nodules, varying from 1 to 3 cm. in diameter. Springing from the left cornu is a pedunculated tumor 9 cm. in diameter, and from the right side of the wall a tumor, 25 cm. in diameter, and attached by a pedicle 3 cm. broad (Fig. 16). The larger tumor for the most part is smooth and glistening, but presents an area of omental adhesions, 12×8 cm. These adhesions consist of a large number of blood-vessels surrounded by a small amount of connective tissue. The uterine walls are occupied by numerous firm nodules, varying from 0.5 to 3 cm. in diameter. All the nodules, both interstitial and subperitoneal, present the typical myomatous appearance. The uterine cavity is 6 cm. in length, 3 cm. in breadth at the fundus, and is distorted. The mucosa varies from 1 to 4 mm. in thickness. It is smooth and glistening, but shows some hemorrhage.

Gyn. No. 3296. Path. No. 580.

A large subperitoneal pedunculated and parasitic myoma, showing much degeneration and receiving most of its nourishment from the omentum (Fig. 17).

M. W., white, married, aged forty-one. Admitted January 28; discharged March 6, 1895. The patient has been married fifteen years, has had two children and one miscarriage. The menses began at eighteen and were regular every four weeks until recently. Now the periods occur every two weeks. For two years the abdomen has been steadily increasing in size, and at present a large hard mass can be readily felt through the abdominal wall.

Operation, January 30, 1895. Hysteromyectomy. On section of the abdomen a large sessile, subserous myoma with a pedicle, 6×4 cm., was found.

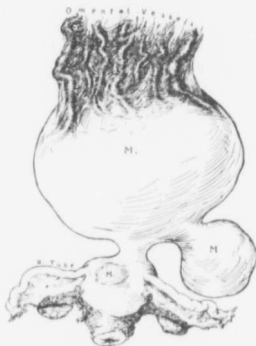

FIG. 16.—A VERY LARGE SUBPERITONEAL AND PEDUNCULATED MYOMA, RECEIVING MOST OF ITS NOURISHMENT FROM THE OMENTUM.

GYN. NO. 3974. The sketch was made at operation. The uterus contains several small myomata, and the appendages are normal. Attached to the fundus by a short pedicle is a myoma 25 cm. in diameter. Over an area 12×8 cm. the omentum is densely adherent. The omental vessels are large and tortuous, and are so intimately blended with the myoma that they might readily be mistaken for normal instead of adventitious vessels.

The whole transverse breadth of the omentum was adherent to the tumor and sent large vessels into it (Fig. 17). The omentum was tied off and the uterus removed. For the first two days the patient presented an almost typical picture of hemorrhage, although neither dressings nor incision showed any oozing. The temperature rose to 102.6° on the second day, the pulse to 118. She then commenced to improve, the temperature dropping to normal. After removal

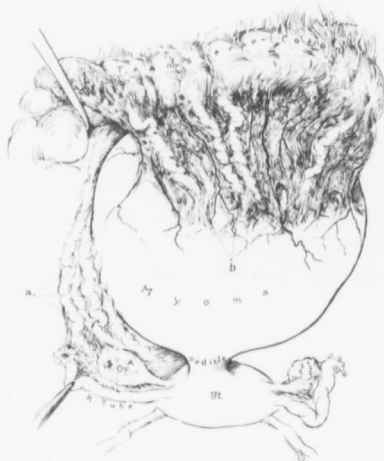


FIG. 17.—A VERY LARGE PEDUNCULATED AND PARTIALLY NECROTIC MYOMA, RECEIVING A RICH BLOOD-SUPPLY FROM THE OMENTUM.

Gyb. No. 3296. The sketch indicates the appearance at operation. The uterus itself is normal. In the right broad ligament are large and tortuous vessels (a), filled with clear or milky fluid. These are markedly dilated lymph-channels.

The large pedunculated myoma attached to the posterior surface of the uterus is $27 \times 23 \times 16$ cm. in its various diameters. Attached to its entire upper surface is omentum which distributes numerous blood-vessels to the tumor. The large tortuous and white vessels (b) projecting from the transverse colon are dilated lymph-channels.

These divide the tissue up into large and small lobules. In a few places are circumscribed masses of bright yellow material resembling fat, and in some portions of the tumor are spaces reaching 3×2 cm., which are divided up into smaller ones by delicate trabeculae and contain a clear transparent fluid. Scattered throughout the tumor are many blood-vessels which have very delicate walls. The uterus presents nothing of interest. On the right side the vessels of the parovarium are greatly enlarged, and the parovarian tissue is edematous. The ovary is normal. On the left side the appendages are unaltered.

of the stitches for some unaccountable reason, the temperature rose to 104.2° and the pulse to 120, but on the fifteenth day the former dropped to 100° and reached normal on the twenty-second day.

Path. No. 580. The specimen consists of the uterus, tubes, and ovaries and a large mass springing from the posterior surface. The tumor is irregularly oval in shape, $27 \times 23 \times 16$ cm. Its surface is smooth and glistening, except along its upper portion, where the omentum is adherent over an area measuring 16×8 cm. The tumor presents numerous bosses, is pinkish in color, and along its surface many large veins are seen, the largest of these being 6 mm. in diameter. The tumor is firm, but somewhat yielding, and on section is dirty grayish yellow in color and has whitish bands traversing it in all directions.

Hi
gland
ing fr
and tr
out it
macro
chang
altere
lated
necro
is her
made
absce

A
myo
fro
E
Octo
She
The
C
sions
patie
mad
I
in sl
hesic
hesic
cont
tum
diar
grou
con
und
sep
tair
my
cha
pla

Histologic Examination.—The mucosa is edematous, and in some places the glands can be traced a short distance into the muscle. The large tumor springing from the uterus is composed of non-stripped muscle-fibers cut longitudinally and transversely. It has a fairly abundant blood-supply, and scattered throughout it are irregular patches of hyaline degeneration. The yellow patches seen macroscopically are nothing more than large areas showing typical hyaline change. In the vicinity of these the non-stripped muscle-fibers often appear unaltered or may stain deeply; they end abruptly, being replaced by finely fibrillated hyaline material. In other portions the tissue has undergone coagulation necrosis and there is considerable nuclear fragmentation. At such points there is hemorrhage into the tissue and rows of resistant muscle-fibers can still be made out. There is a moderate polymorphonuclear infiltration. In this case abscess formation would certainly have occurred in a short time.

Gyn. No. 7220. Path. No. 3476.

A large pedunculated parasitic and partially cystic myoma, deriving its blood-supply almost entirely from the omentum (Fig. 18).

E. C., white, aged fifty, married. Admitted September 20; discharged October 14, 1899. The patient has had four children and two miscarriages. She ceased to menstruate one year ago. The abdomen is obliquely distended. The tumor takes up the entire right half and lower left half of the abdomen.

Operation, September 25, 1899. Myomectomy. After the omental adhesions had been freed, the tumor was readily separated from the uterus. The patient had a postoperative temperature of 102.8° on the sixth day. She made a satisfactory recovery.

Path. No. 3476. The specimen consists of a large subperitoneal myoma, ovoid in shape, 19 x 14 x 12 cm. Its surface for the most part is covered with adhesions. The anterior and upper surface presents a large area of omental adhesions, covering about half the anterior surface (Fig. 18). These adhesions contain numerous large blood-vessels, which branch over the surface of the tumor. There are also large lymph-vessels. One of these is dilated (7 mm. in diameter), and filled with clear fluid. It is very tortuous, and resembles a ground-worm in its convolutions. On pressure the tumor is in part firm, but contains an area of fluctuation. On section, it is found that the entire mass has undergone more or less cystic degeneration. In some parts small delicate septa divide up the cystic spaces. The pedicle is 1.1 cm. in diameter, and contains very large vessels. The specimen is a typical example of a parasitic myoma.

On histologic examination the myoma presents large areas of marked cystic change. In places there are muscle-fibers separating the alveoli. In other places the tissue is structureless and is liquefying.

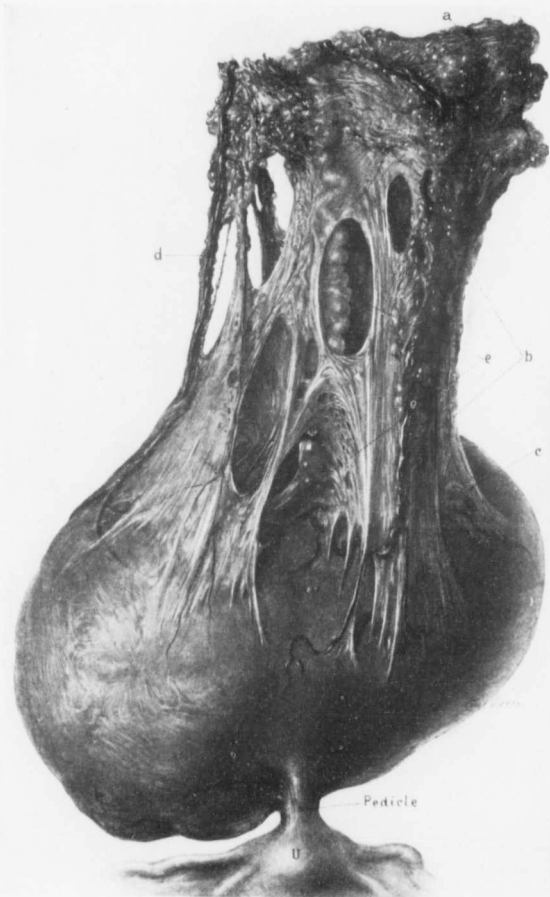


FIG. 18.—A PARASITIC MYOMA RECEIVING A LARGE BLOOD-SUPPLY FROM THE OMENTUM. PARTIAL ATROPHY OF THE OMENTAL FAT

Gyn. No. 7220. The sketch was made immediately after operation. The uterus is normal in size. Attached to the fundus by a short slender pedicle is a myoma 19 x 14 cm. Covering the entire upper surface of the tumor are omental adhesions, and, as seen from the pathologic report, the greater part of the myoma has undergone hyaline and cystic degeneration.

The picture well depicts the gradual atrophy of the adipose tissue that follows when many omental vessels are connected with a tumor. At a, normal omentum is seen; at b the blood-vessel has lost its adipose covering and stands out clearly. In the lower part of the omentum all trace of fat has disappeared (c), and nothing but the peritoneal layers of omentum and the vessels remain. At d the vessel is very clearly seen. At numerous points even the peritoneum is giving way, clear spaces resulting. In one of these is a large tortuous vessel (e) filled with clear fluid. It is a much dilated lymph-vessel.

Gyn. No. 13039. Path. No. 10039.

Subperitoneal, interstitial, and submucous uterine myomata; marked atrophy of the omentum as a result of the nourishment it has had to supply to the uterus (Fig. 19).

H. H., colored, aged twenty-seven, married. Admitted June 24; discharged July 17, 1906.

Operation, hysteromyomectomy; left salpingo-oöphorectomy; right salpingectomy. The highest postoperative temperature was 103.2°, twenty-four hours after operation. The patient made a perfect recovery.

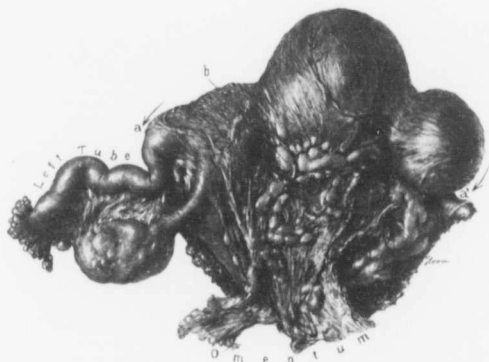

FIG. 19.—MARKED DISAPPEARANCE OF THE FAT IN AN ADHERENT OMENTUM. (½ NAT. SIZE.)

Gyn. No. 13039. Path. No. 10039. The left tube and ovary are normal. The omentum forms a mantle over the posterior surface of the nodular myomatous uterus, between *a* and *a'*. In most places nothing but the peritoneal folds of the omentum remain, giving the surface of the uterus a rather wrinkled appearance. Immediately around the blood-vessels, however, the adipose tissue still persists, as is well seen at *b*.

Path. No. 10039. The uterus has been amputated through the cervix. It is 9 cm. in length, 7 cm. in breadth, and 7 cm. in its anteroposterior diameter. It is everywhere covered with adhesions, and has a lacework of omentum attached to it. The omentum is atrophic to a certain extent, and the fat has almost entirely disappeared, but still persists on the surface of the uterus, along the course of the blood-vessels (Fig. 19). This fat would in time certainly disappear. Scattered throughout the uterus are numerous nodules, some of them not over 2 mm. in diameter, others reaching 2.5 cm. The uterine cavity is 4 cm. in length. The mucosa is here and there gathered up into little domes; in other words, it shows a tendency toward polypoid formation. It varies from 2 to 4 mm. in thickness.

Histologic examination shows that the mucosa is practically normal. In sections from one of the myomata a good deal of hyaline transformation is evident.

This case exemplifies how the omentum atrophies when it becomes adherent to the uterus. We have the fat disappearing almost entirely except in the immediate vicinity of the blood-vessels.

Path. No. 7925.

A parasitic myoma receiving most of its blood-supply from the omentum; marked disappearance of the omental fat (Fig. 20).

Mrs. B., Frederick Emergency Hospital, October 30, 1904. The patient was forty-five years of age, and had been under observation six months. On opening the abdomen I found a subperitoneal myoma attached to the anterior surface of the uterus. It had received the greater part of its blood-supply from the omentum. After the omental vessels had been tied off the uterus, which contained several myomata, was amputated through the cervix. The patient made an uninterrupted recovery.

Path. No. 7925. The specimen consists of a myomatous uterus with a pedunculated myoma attached to its anterior wall. The uterus is enlarged, measuring 7.5 x 7 x 5 cm. Its outer surface is smooth. At the fundus is a subperitoneal nodule, 6 mm. in diameter, and another on the posterior wall, 2.7 x 2 cm. Projecting from the anterior wall and attached by a delicate pedicle is a large myoma. Attached to the upper surface of this, over a wide area, is omentum. In places this is perfectly normal; in other places it shows marked diminution in the amount of fat, and at numerous points the omental vessels, now absolutely devoid of fat, are seen plunging into the tumor (Fig. 20). This is one of the most interesting specimens that we have ever seen, as it clearly shows the various stages of atrophy of the omental fat when the omentum furnishes a parasitic myoma with nourishment.

Case C. (Hagerstown, Md.).

A large parasitic myoma with marked development of the omental vessels, some reaching 1 cm. in diameter (Fig. 21).*

C., colored. Seen in consultation with Dr. Scheller at the Washington County Hospital, Hagerstown, on August 4, 1906. The patient had had an abdominal tumor for five years. The tumor rose abruptly, and projected fully 18 inches from the general abdominal contour. The vagina posteriorly was greatly encroached upon.

Operation. On opening the abdomen the tumor encountered was everywhere adherent to the anterior abdominal wall and also laterally. Running into

* Thomas S. Cullen, A Series of Interesting Gynecologic and Obstetric Cases, Jour. Amer. Med. Assoc., May 4, 1907.

the anterior surface of the tumor from its upper end were blood-vessels, some of them nearly 1 cm. in diameter. They were spread out over an area 16 cm. in

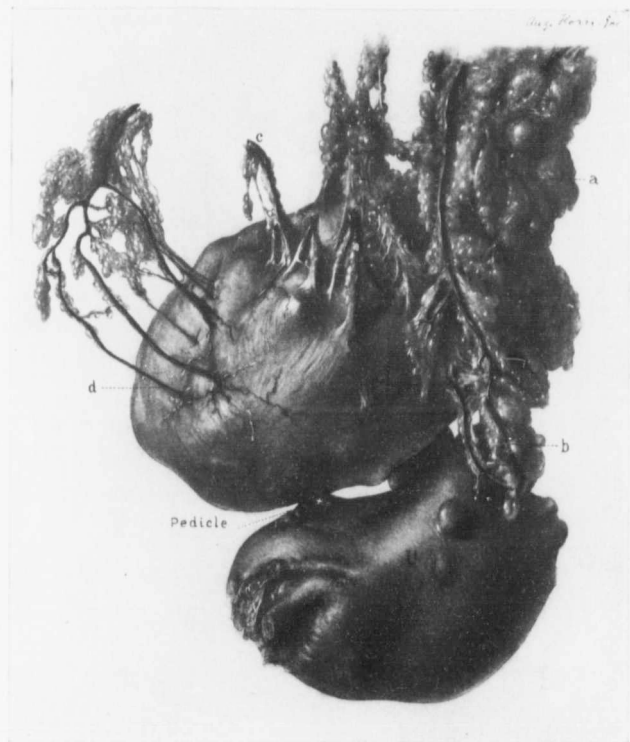

FIG. 20.—THE GRADUAL DISAPPEARANCE OF OMENTAL FAT WHEN THE OMENTUM SENDS MANY VESSELS TO A PARASITIC MYOMA. (Nat. size.)

Path. No. 7925. The uterus is about twice the natural size and contains several myomata. Attached to its anterior surface by a short slender pedicle is a slightly lobulated myoma, and attached to the myoma over a wide area is omentum. At a the omental fat still presents the usual appearance. At b there is atrophy of the fat and the vessels stand out clearly. At c there is still further atrophy of the omentum, as only immediately around the vessels does the fat still persist. At d all semblance of fat has disappeared and we see the omental vessels spreading out over the surface of the tumor or plunging directly into the depths.

breadth. Passing down the right side of the tumor, and lying beneath it, was a regular rope of blood-vessels (Fig. 21, b'). These lay perfectly free from the sur-

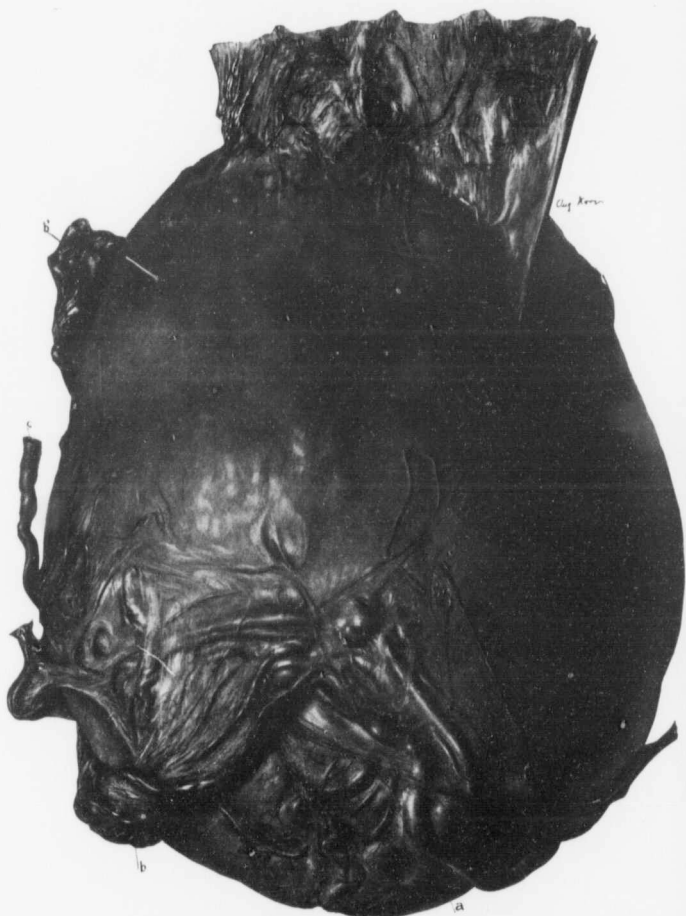


FIG. 21.—A LARGE PARASITIC MYOMA WITH HUGE VESSELS COMING FROM THE OMENTUM (½ nat. size.)

The tumor weighed 18 pounds, and was attached to the uterus by a pedicle, 5 mm. x 3 cm. At the top is a broad, omental adhesion carrying vessels to the tumor. At b' is a cross-section of a portion of the "rope of omental vessels," which passed down beneath the tumor to b, and then turned upward again, plunging into the tumor. a represents one of the largest blood-vessels, which stand out prominently. Crossing these large vessels are numerous adhesions. c is a portion of a vessel which passed down, perfectly free from the omentum, to the under surface of the tumor.

rounding structures, could be lifted up, were covered with peritoneum, and were evidently omental, but no fat was present. These vessels formed a mass 6 cm. in diameter, and looked and felt like small snakes. They could be traced down to the lower end of the tumor, where they spread out over its surface and plunged into its substance. One of the vessels, 5 mm. in diameter, passed down by itself and lay absolutely free (Fig. 21, c). It was isolated for a distance of 18 cm., being devoid of any attachment whatsoever. It had originated in the omentum, extended downward, and plunged into the tumor.

After liberating the vascular supply I found that the tumor was attached to a small myomatous uterus. The pedicle was 3 cm. in breadth, 5 mm. in thickness, and contained only one blood-vessel of any size. The pedicle was cut and the tumor delivered. Of the vessels passing from the omentum, as a rule there was one artery to two veins. The artery was about one-third the size of the vein.

As the patient's condition became rather serious, although she had not lost more than two ounces of blood, we stopped the operation, leaving the myomatous uterus and a second myoma, fully 25 cm. across. This also had vessels from the omentum plunging into its upper part, and was attached to the uterus by a pedicle 2 cm. in diameter.

The patient promised to return to the hospital for removal of the uterus as soon as she was in good condition. She kept putting it off, however, until finally, at the end of one and one-half years, she entered the hospital with the abdomen as distended as when first seen. The abdominal scar had given way, and purulent fluid was escaping from the abdominal cavity. There was marked sepsis, and hysterectomy was out of the question. She got somewhat better, but died after a few months.

The hardened specimen measured 23 cm. in length, 25 cm. in breadth, and 20 cm. in its anteroposterior diameter. It was markedly nodular, very hard, and weighed 18 pounds. Even in the hardened specimen some of the blood-vessels were nearly 1 cm. in diameter.

Gyn. No. 5784.

A very large myomatous uterus, with large congeries of omental vessels covering its surface; dense adhesions to the bladder and numerous vessels from the bladder supplying nourishment to the tumor (Fig. 22).

A. L., colored, aged forty-five, married. Admitted January 11; discharged February 19, 1898. The menses were regular until a year ago. Since then they have been diminishing in amount, and have occurred at longer intervals. On vaginal examination the cervix is found to be small, pressed down by a hard pelvic mass, evidently connected with a large tumor, which almost completely fills the entire abdomen, extending upward to within two inches of the epigastrie

notch. The tumor is firm, hard and immobile, and tender only over the symphysis.

Operation, January 15, 1898. Hysteromyomectomy; right oöphorectomy. On making the incision I found a large tumor filling the entire abdomen. The uterus had rotated 180° from right to left. Attached to the entire anterior surface of the tumor was the omentum, which sent in numerous vessels (Fig. 22). There were also extensive adhesions to the bladder. These contained large

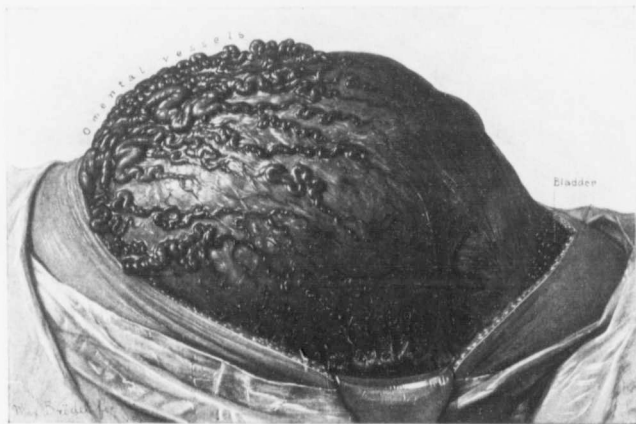

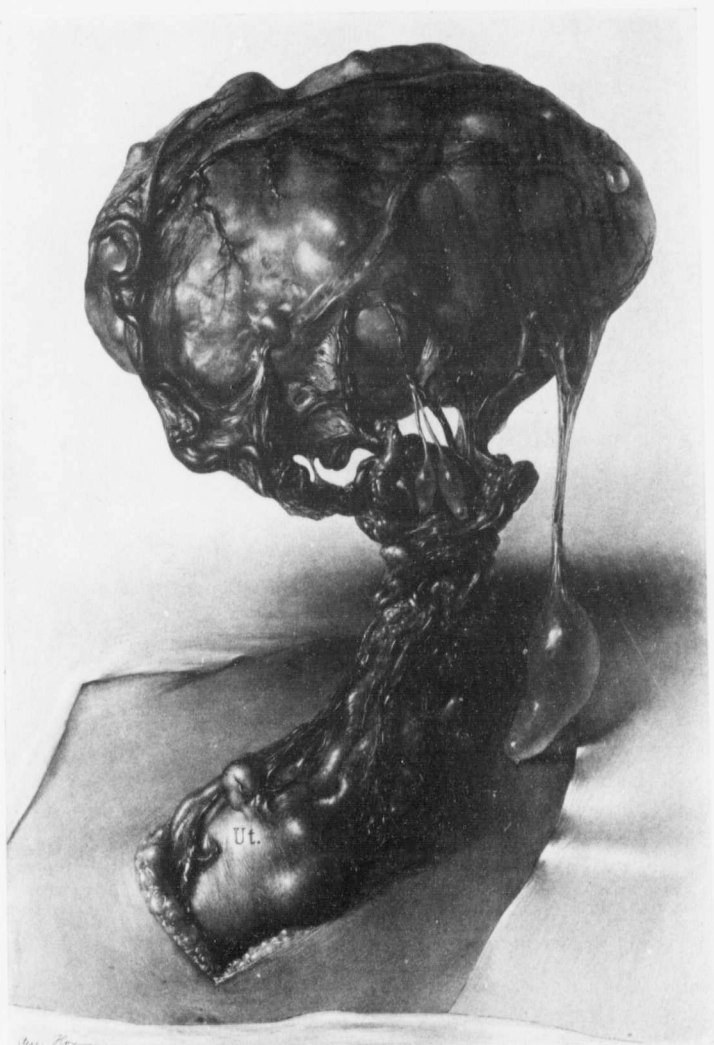
FIG. 22.—LARGE CONGREGIES OF OMENTAL VESSELS SUPPLYING NOURISHMENT TO A MYOMATOUS UTERUS; ALSO VESSELS PASSING UP FROM THE BLADDER TO THE TUMOR.

GYN. No. 5784. This picture demonstrates one of the difficult hysterectomies that frequently confront the surgeon. In such a case the incision should be continued upward until free omentum is encountered, and then the vessels should be tied twice on the proximal or colon side and once on the distal side. It is better not to use artery forceps, as the vessels are so friable. In such cases the ureters are often drawn up in festoon fashion along the sides of the tumor by adhesions, and may readily be tied accidentally or cut if extreme care is not exercised. (After Howard A. Kelly.)

vessels. The uterus was amputated through the cervix. Convalescence was interrupted by a mild attack of salivation after taking calomel. Her highest postoperative temperature was 100.8°. She made a satisfactory recovery.

FIG. 23.—A LARGE MYOMA ENTIRELY SEPARATED FROM THE UTERUS AND LYING FREE IN THE OMENTUM.

GYN. No. 14709. Path. No. 12618. On opening the abdomen the large myoma, seen in the upper part of the picture, presented. It measured 10 x 13 x 17 cm., and had large numbers of omental vessels coursing over its surface. The omental fat had here to a great extent disappeared, allowing the blood-vessels to stand out sharply. To the right is a long adhesion, to the lower end of which an elongated subperitoneal cyst is attached. Two similar and smaller cysts are attached to the lower and anterior surface of the tumor. All of them are in reality small subperitoneal cysts, similar to those so frequently associated with pelvic adhesions. Protruding from the abdominal incision is a small myomatous uterus. Partially enveloping the uterus and the right tube and ovary is the omentum, which is continued upward and envelops the myoma. The large myoma has entirely lost its connection with the uterus.



Das. Koenig.

FIG. 23.

Gyn. No. 14709. Path. No. 12618.

A myoma lying free in the omentum (Fig. 23).

One of the most interesting examples of a parasitic myoma that we have ever encountered was furnished by Case 14709. The uterus contained several small myomata, while lying enveloped in omentum was a large myoma which had entirely lost its connection with the uterus.

Gyn. No. 14709. A. C., colored, aged thirty-seven. Admitted April 9; discharged May 2, 1908. On opening the abdomen one of us (Cullen) found a large myoma presenting. On drawing this out he found it enveloped in omentum and entirely separated from the uterus (Fig. 23). The tumor was removed with the utmost care, the large omental vessels being doubly tied and cut. The small and densely adherent myomatous uterus was then removed.

Path. No. 12618. The uterus measures 2 x 5.5 x 7 cm. and contains several small myomata. The large parasitic myoma measures 10 x 13 x 17 cm. Its surface is uneven and nodular. It is firm in consistency and covered over with omentum. The central portion of the myoma has undergone hyaline degeneration, with some liquefaction, and there is extravasation of blood.

ASCITIC FLUID ACCOMPANYING UTERINE MYOMATA.

Ascitic fluid is frequently associated with fibroma of the ovary, but only rarely is there any appreciable amount of free serous fluid accompanying uterine myomata. In seven of our cases a considerable amount of ascitic fluid was detected at operation.*

In Gyn. No. 9786, in which the rounded myomatous tumor reached to within 5 cm. of the umbilicus, the abdomen contained 200 c.c. of free fluid. A glance at the history will show, however, that other factors were in all probability responsible for the ascites. The patient had a loud apical systolic murmur. There was marked edema of the feet and ankles, and the hemoglobin on admission was only 20 per cent., but reached 43 per cent. just before the operation.

In Case 6272 the uterus contained several subperitoneal myomata and was densely adherent. About three months before operation 1550 c.c. of fluid had been aspirated from one pleural cavity. About eleven days prior to the operation 8050 c.c. of ascitic fluid had been withdrawn from the abdomen. In this case the cardiac lesion and the accompanying nephritis were probably responsible for the accumulation of fluid.

The free fluid in the abdomen in Cases 6418, 3387, 1383½, 12155, and P., C. H. I. was undoubtedly caused by the presence of the tumor and not by any constitutional impairment.

In Case 12155 a large pedunculated myoma had made a three-quarter turn on itself, and the omentum was adherent over an area 14 cm. in extent. Some

* In Cases 12166, 12185, 12678, 12871, a small amount of ascitic fluid was also found. In Case 12348, as a result of a mild peritonitis, the abdomen contained a small amount of free turbid fluid with flakes of fibrin.

of its vessels entering the tumor were only 1 mm. in diameter. The abdomen in this case contained two ounces of clear yellow serum. For a full description of the case see p. 200.

In Case 6418 the subperitoneal pedunculated myoma weighed 29 pounds and the abdomen contained about 500 c.c. of ascitic fluid.

In Case 3387, in which a partially parasitic myoma existed (Fig. 24, p. 34), marked ascites was present, 7000 c.c. of free fluid being found.

In Gyn. No. 1383½ the omentum was densely adherent to the tumor, and the abdomen contained 14,500 c.c. of straw-colored fluid, and about 2000 c.c. of a clear, jelly-like material, that was scooped out with the hand. The urine contained albumin, but no casts. After removal of the tumor the albumin disappeared.

Undoubtedly one of the most remarkable cases of the intimate association of uterine myomata and extensive ascites is furnished by case P. In this case (p. 35) the subperitoneal myoma had been almost completely weaned away from the uterus, and was receiving its chief blood-supply from the posterior surface of the bladder and from huge omental vessels (Fig. 25). The abdomen contained 51,000 c.c. of clear ascitic fluid.

Cause of the Ascites.—The fluid is clear, straw-colored, and usually limpid, but may coagulate, forming a loose, clear, jelly-like mass.

As previously mentioned, fibromata of the ovary are usually accompanied by ascites. In these cases the large vessels in the loose pedicle are undoubtedly twisted, causing a transudation of serum. That the fibroma is undoubtedly responsible for the fluid is clearly proved by the total absence of free abdominal fluid after removal of the tumor.

In four of our cases the condition has been an analogous one. The myomata have been pedunculated, and have received a large part of their blood-supply from the omentum. Partial rotation of the tumor, with twisting of the vessels, had from time to time undoubtedly occurred, and transudation of serum into the abdomen was the natural result. A reference to Fig. 25 will show the slender attachment of the pedunculated myoma, and any lateral movement of the patient was undoubtedly accompanied by a partial twisting of the tumor, shutting off the blood-supply of the huge omental vessels and favoring the pouring out of serum. It is now four and one-half years since the tumor was removed, and although the abdomen, prior to operation, contained 51 liters of fluid, there has never been any return of the ascites.

Cases in which the Myomata were Accompanied by Ascites.—In the following cases the reader can determine for himself the probable cause of the free abdominal fluid:

Gyn. No. 9786.

Ascitic fluid associated with a myomatous uterus.
M. B., colored, aged forty. Admitted July 15; discharged September 20,

1902. The patient complains of the presence of an abdominal tumor and of general weakness. For the last two years she has suffered from weakness, and has had numerous fainting spells, shortness of breath, and swelling of the feet. Her weakness she attributes to a profuse menstrual flow. The tumor was first noticed about a year ago. At this time it was the size of a baseball. The patient is exceedingly anemic, and shows puffiness around the eyes, a loud systolic murmur, marked edema of the feet and ankles, and a hemoglobin of 20 per cent.

She was at once put to bed, given iron and strychnin, and kept as much as possible in the open air. She improved rapidly. On August 14th she had her usual period, which was profuse. At this time the edema of the ankles and puffiness of the eyes had entirely disappeared. Her hemoglobin reached 43 per cent.

Operation, hysteromyomectomy, August 26, 1902. When the abdomen was opened, about 200 c.c. of free fluid were found and a rounded soft tumor about the size of a fetal head. Hysteromyomectomy was done, and the patient made a satisfactory recovery. At the time of her discharge, on September 20, 1902, her hemoglobin had reached 52 per cent. She had recovered almost entirely from her weakness and had no further symptoms.

The ascitic fluid in this case was apparently due directly to the general weakened condition and to the low hemoglobin. Of course, indirectly, the weakness had been produced to a great extent by the continued loss of blood occasioned by the myoma.

Gyn. No. 6272. Path. No. 2530.

Ascitic fluid associated with uterine myomata. Chronic nephritis; mitral insufficiency.

B. S., colored, aged thirty-six, single. Admitted July 27; discharged August 28, 1898. This patient was admitted to the gynecologic department from the medical service on July 27th. In April 1850 c.c. had been withdrawn from the pleural cavity, and on July 16th, 8050 c.c. of ascitic fluid from the abdomen. The patient's last menstrual period had occurred in November, 1897. On admission to the gynecologic service a diagnosis of uterine myomata, chronic nephritis, and mitral insufficiency was made.

Operation, July 27, 1898. Hysteromyomectomy with removal of the appendages. The posterior surface of the uterus was densely adherent to the broad ligament and pelvic floor, and both tubes and ovaries were buried in adhesions. The bladder on the left side was adherent to the uterus, and there was a considerable amount of cystic pelvic peritonitis in the cul-de-sac. The appendix was adherent to the right ovary, lying under the tumor. The highest postoperative temperature was 103.2°. The patient made a satisfactory recovery.

Path. No. 2530. The specimen consists of the enlarged uterus, with the tubes and ovaries intact. The uterus is approximately 18 x 14 x 15 cm.

The increase in size is due to the presence of subperitoneal interstitial and submucous myomata. Covering the anterior and posterior surfaces are numerous adhesions. The uterine cavity is 6 cm. in length and its mucosa is much atrophied. The chief interest in this specimen is centered in the subperitoneal myoma, 7 cm. in diameter. This, on section, presents the usual myomatous appearance, save over an area measuring 3.5 x 2.5 cm. Here large, irregular, cyst-like spaces are present, the walls of which are very delicate. Extending across them are fine trabeculae. Clinging to the walls, and partly filling the cavity, are quantities of blood. The appendages are covered with adhesions.

Histologic Examination.—The walls of the cyst-like spaces are composed of hyaline myomatous tissue, totally devoid of nuclei. The inner surface of the cysts have no lining. They are covered with blood. These cyst-like spaces, therefore, are nothing more than areas in which the hyaline myomatous tissue has undergone liquefaction, followed by hemorrhage.

In this case the myoma may have had a causal relation to the development of ascitic fluid, but the nephritis and the mitral insufficiency were undoubtedly directly responsible for the pouring out of the fluid into the abdominal and pleural cavities.

Gyn. No. 6418.

Ascitic fluid associated with a uterine myoma.

M. W., colored, aged thirty-nine, married. Admitted October 9; discharged November 7, 1898. The patient has never been pregnant. Her menses began at seventeen, were regular, lasting five or six days, and associated with considerable pain until the last three or four months. The tumor was noticed three years ago. Latterly she has had shortness of breath. The abdomen is greatly and irregularly distended.

Operation, October 12, 1898. Hysteromyomectomy. The large dense mass was liberated and brought out. It was attached to the uterus by a pedicle 2 cm. broad. As the tumor was drawn out, about 500 c.c. of ascitic fluid escaped. The tumor was liberated from left to right in the usual way. It weighed 29 pounds. The free oozing in the pelvic floor was checked with numerous sutures. The right ureter was about twice the natural size. The highest postoperative temperature was 100.2°. The patient made a satisfactory recovery.

In this case the myoma seems to have been the cause of the ascitic fluid.

Gyn. No. 3387. Path. No. 641.

Ascitic fluid associated with a large myomatous uterus. One pedunculated myoma received part of its nourishment from the omentum (Fig. 24).

M. S., white, aged thirty-two, married. Admitted March 20; discharged April 27, 1895. The patient has been married twelve years and has had two children; no miscarriages. The menses were regular until an attack of typhoid

fever, one year ago. Since then they have been somewhat irregular and the flow is free.

Soon after the birth of the youngest child, five years ago, she noticed a lump the size of a hen's egg in the midline of the lower abdomen. About eighteen months ago her abdomen began to increase in size, and has been gradually enlarging up to the present time. When she turns, the mass seems to move from side to side, and there is present a constant dragging sensation, with occasional sharp pains, especially on the right side.

The abdomen is distended by several distinctly palpable tumors. Some of

these give a definite ballottement and there is marked distention of the abdomen with ascitic fluid. The ballottement is easily obtainable with two large masses. The cervix is jammed down to the pelvic floor by the tumor. The urine is normal.

Operation, March 23, 1895. Hysteromyomectomy. After the incision, 7 liters of ascitic fluid were evacuated. One of the large pedunculated nodules had four large ommental vessels entering it (Fig. 24). These were tied and separated. The highest postoperative temperature was 100.3° on the second day.

Path. No. 641. The uterus measures 14×17 cm. It is smooth and glistening. Springing from its anterior surface is a globular nodule, $9 \times 9 \times 8$ cm. It is attached by a pedicle 1.5 cm. in length, 3 cm. in breadth. Springing from the fundus is another pedunculated nodule, irregularly oval, and measuring 10×8

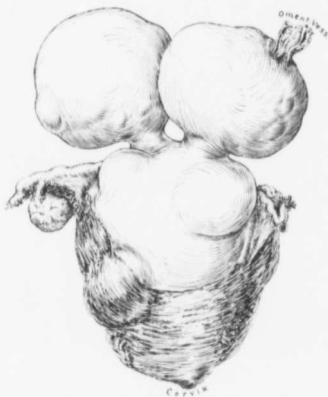

FIG. 24.—OMENTAL VESSELS SUPPLYING A SUBPERITONEAL PEDUNCULATED MYOMA, AND ASSOCIATED WITH 7000 C.C. OF ASCITIC FLUID.

Gyn. No. 3387. Path. No. 641. The uterus measured 14×17 cm. Attached to the fundus are two pedunculated myomata, one of which has several ommental vessels entering it. On palpation one of the vessels gave a definite ballottement. The abdomen contained 7000 c.c. of clear fluid.

$\times 6$ cm. The entire left lateral wall of the uterus is occupied by a tumor $10 \times 7.5 \times 6$ cm. It is oval in shape, regular in outline, and has a secondary nodule, $2 \times 2 \times 2.1$ cm., springing from its under surface. The uterus, on section, is found to contain numerous interstitial and some submucous nodules. The uterine mucosa is smooth and glistening, and apparently much atrophied. The tubes and ovaries on both sides are normal.

Histologic Examination.—The uterine mucosa is atrophic, but otherwise normal. All the tumors consist of fibers, most of which are cut transversely. The tissue is rather lax and shows a slight amount of hyaline degeneration.

In this case the omental vessels growing into the subperitoneal and pedunculated myoma were apparently the source of the ascitic fluid.

Gyn. No. 1383½.

A large quantity of ascitic fluid associated with a partially parasitic uterine myoma.

R. G., colored, aged thirty-four, married. Admitted May 12; discharged July 5, 1892. The patient has been married eighteen years, but has never been pregnant. For the past two years she has had pain in the left ovarian region, steadily growing worse. In December, 1891, her abdomen commenced to swell. About two years ago she noticed that her feet and ankles were edematous. The abdomen is uniformly distended. The urine contains albumin, but no casts.

Operation, May 16, 1892. Hysteromyomectomy. When the abdomen was opened, about 14,500 c.c. of clear straw-colored fluid escaped, and later about 2000 c.c. of clear, jelly-like material were removed with the hand. The myomatous uterus rose from the pelvis and extended about 8 cm. above the umbilicus. The omentum was intimately adherent to the upper and anterior surface of the tumor. Hysterectomy was performed. The temperature gradually rose to 102° by the tenth day, and then fell to normal. It again reached 102.6° by the twenty-seventh day, when there was some pulmonic dullness. The albumin disappeared entirely after operation. The patient left the hospital on July 8th, but she still had some fever.

P. C. H. I.*

A partially parasitic myoma, associated with 51 liters of ascitic fluid (Fig. 25).

P., aged fifty-four, white, single. Admitted October 29, 1902, complaining of marked abdominal enlargement. Her face was drawn and pinched. She was exceedingly thin; the abdomen was tremendously and uniformly distended. From the pubes to the sternum in the midline there was dullness, and on percussion a very distinct wave of fluctuation was easily detected.

A diagnosis of ovarian cyst was made, and after a delay of a few days on account of a slight bronchitis, the abdomen was opened. The peritoneum was much thickened. The great distention was due to ascitic fluid, 51 liters being removed. Attached to the fundus by a very small pedicle was a myomatous nodule 16 cm. long (Fig. 25). Plunging into the upper or free surface of this nodule, were numerous blood-vessels, each about 3 or 4 mm. in diameter, tortuous, and closely resembling angle-worms. On being traced upward, they proved to be the large omental vessels. The omentum as such was recognized as a fringe, not more than 5 mm. long, projecting from the lower edge of the trans-

* Thomas S. Cullen, J. A. M. A., November 19, 1904, p. 1512. A Partially Parasitic Uterine Myoma, Associated with 51 Liters of Ascitic Fluid.

verse colon. The altered omental vessels were exceedingly friable, and ruptured on the slightest manipulation. The parasitic myoma derived part of its blood-supply from the bladder, to which it had become intimately attached. After tying off the blood-supply of the myoma the growth was easily removed and the patient made a satisfactory recovery.

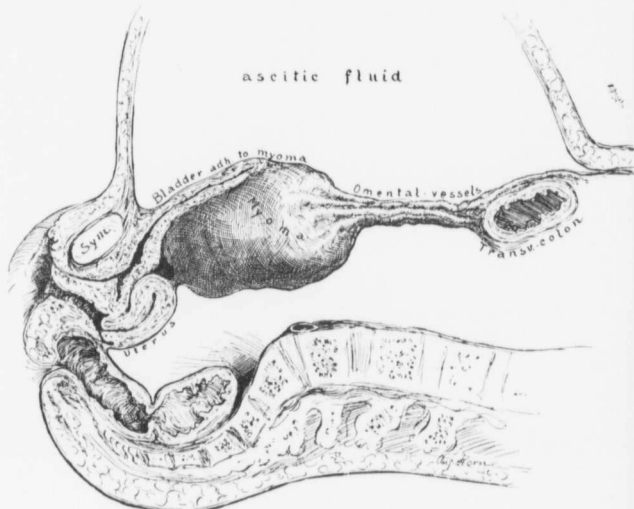


FIG. 25.—A PARTIALLY PARASITIC UTERINE MYOMA ASSOCIATED WITH 5 LITERS OF ASCITIC FLUID.

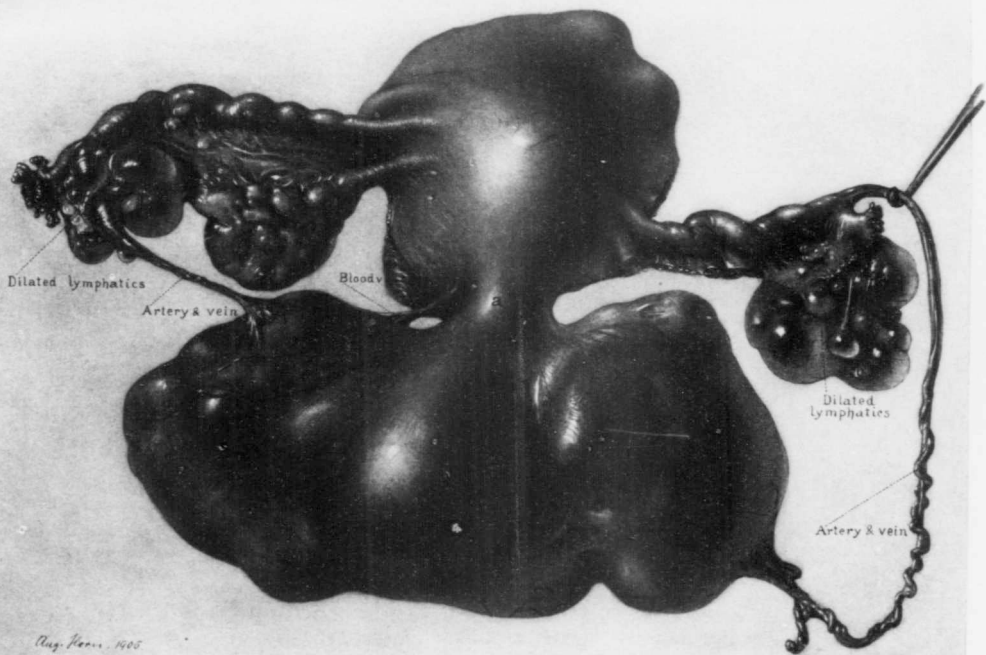
Attached to the fundus by a narrow pedicle is a subperitoneal myoma. Plunging into the edge of the myoma are the omental vessels. The omental fat has almost entirely disappeared. The myoma was intimately blended with the posterior surface of the bladder, from which it received a good deal of nourishment. The abdomen is markedly distended with ascitic fluid. The small intestines were effectually held back by the tumor and the omental vessels. (After Thomas S. Cullen.)

March 1, 1907: The patient is at the present time in good health, and there has never been any return of the ascitic fluid.

In this case we had to rely entirely on the physical signs, as the patient was of

FIG. 26.—A PARTIALLY PARASITIC MYOMA, RECEIVING PART OF ITS NOURISHMENT FROM THE FALLOPIAN TUBES. (1 NAT. SIZE.)

C. H. I. No. 495. The uterus contains several interstitial myomata. Attached to the posterior surface of the uterus by a short pedicle is a broad, lobulated myoma. On the left side an artery and vein pass from the outer end of the tube to the anterior surface of the tumor. The branches of the artery spread out over the tumor. On the right side is what might be termed an unnecessarily long adventitious artery, passing from the outer end of the tube to the posterior surface of the tumor, where it plunges into the depth. The accompanying vein clings like a vine to the artery, taking a very tortuous course. The fimbriated ends of both tubes are patent. The left ovary is normal. The right was not removed. The cystic spaces near the outer ends of both tubes are probably dilated lymph-spaces. There is no evidence of pelvic peritonitis.



Aug. Poirer, 1605

FIG. 26.

unsound mind, and up to the day of operation no history could be obtained. The facial expression and the abdominal signs tallied in every particular with those referable to an ovarian cyst, and without the clinical history a correct diagnosis was impossible. The tympany in the flanks is, on first thought, difficult of explanation, but when we remember that this myoma, with the omental vessels attached, stretched almost the entire length of the abdomen, it is readily seen that the small intestines were held back and at the same time forced out laterally. Under any circumstances there would have been dulness over the entire anterior abdomen, as the intestines, even if not held back by the tumor and omental vessels, could not have reached the surface, their mesentery not being long enough. We know of no instance in the literature in which such a large quantity of ascitic fluid was associated with a myoma.

**A PARTIALLY PARASITIC MYOMA, RECEIVING PART OF ITS BLOOD-SUPPLY
FROM THE FALLOPIAN TUBES.**

In this case (Fig. 26) the uterus was slightly enlarged and contained several small myomatous nodules. Projecting from the posterior surface was a broad, lobulated subperitoneal myoma attached by a small pedicle (a). Passing into the anterior surface of the myoma was a small artery from the left tube, and into the posterior surface of the tumor a large artery from the right tube. This artery was very long, and lay perfectly free in the abdomen. Coiled around it was the accompanying vein. There were no omental adhesions. The fimbriated ends of both tubes were normal, hence it is at first glance difficult to explain how the tubal vessels ever reached the myoma. While the myoma formed an integral part of the uterus, delicate adhesions evidently formed between the outer ends of the tubes and the myoma and, as the myoma became more and more pedunculated, the uterine blood-supply diminished and the tubes gradually sent in vessels to the myoma through the existing adhesions.

From a clinical standpoint, the case is interesting because if the pedicle had become still more attenuated and had been finally severed, the myoma would have been entirely supported by the large tubal vessels; then any sudden jolting might readily have caused a rupture of one of the adventitious vessels and a fatal hemorrhage have followed.

C. H. I. No. 495.

L. C. B., aged thirty-six, married. Seen in consultation with Dr. R. B. Norment, and admitted March 12; discharged April 2, 1905. The patient has never been pregnant. For the past month there has been dull pain down the right side of the abdomen. Otherwise the patient feels perfectly well, and it was not until eight days ago that she noticed the tumor.

Operation, March 13th, hysteromyomectomy, with removal of the uterus, both tubes, and the left ovary. When the abdomen was opened, a most unusual picture was seen (Fig. 26). Several greatly twisted blood-vessels lay perfectly free on the surface of the tumor and between the tubes and ovaries on both

side
The
post

A Pz

sepe

G
had r
meser
see F

and
uret
from

com
the
tiss

sides were cysts with very thin walls, which appeared to be dilated lymphatics. The uterus was removed in the usual way from left to right. The highest postoperative temperature was 100.4° F.

A PARASITIC MYOMA SITUATED AT THE PELVIC BRIM (FIG. 27) AND RECEIVING ITS ENTIRE BLOOD-SUPPLY FROM THE SUPERIOR MESENTERIC VESSELS, FROM THE PERITONEUM, AND FROM APPENDICEAL ADHESIONS.

This is the second case in our series in which the myoma had become entirely separated from the uterus. (See Fig. 23, p. 29.) It lay just above the pelvic brim,

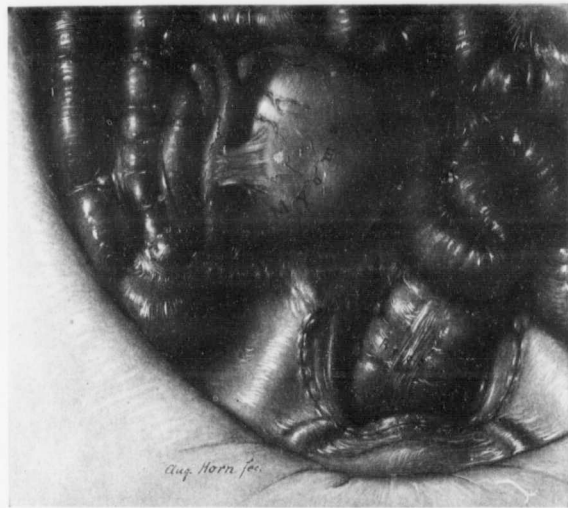


FIG. 27.—A PARASITIC MYOMA IN NO WAY CONNECTED WITH THE UTERUS.

GYN. NO. 9540. This myoma was attached to the peritoneum over the right ureter and the large vessels. It had received the greater part of its nourishment from vessels which appeared to be derived from the superior mesenteric artery; it was also firmly adherent to the appendix. For the appearance of the myomatous uterus see Fig. 28.

and great care had to be exercised during its removal to avoid injury to the ureter and the neighboring vessels. The nourishment appeared to have come from the arteries supplying the small bowel.

In this case the uterus was about three times the natural size (Fig. 28) and contained several myomata. All the appearances at operation indicated that the myoma had originated in the uterus and had later engrafted itself on to the tissue at the pelvic brim.

Gyn. No. 9540.

V. B., colored, aged forty-one. Admitted April 7; discharged May 8, 1902. The patient complains of pain in the abdomen toward the end of the menses, and of an abdominal tumor. She has had two children, the youngest twenty-two years of age. Fifteen years ago she first began to have dysmenorrhœa and cramps. Two years ago a vaginal section was done for a double pyosalpinx (Gyn. No. 6226). Further operation was advised, but refused. For six months the patient was free from pain, but after that the pain returned and during the last two months has been very severe, so that the patient has been confined to bed most of the time. For three weeks she has had difficulty in urination and severe bearing-down pains at the same time.

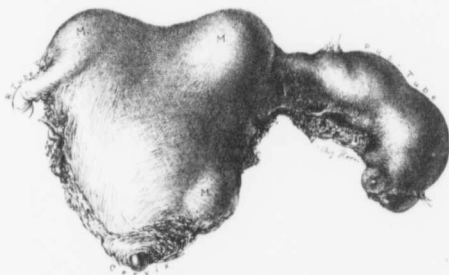


FIG. 28.—MULTINODULAR MYOMATOUS UTERUS WITH A LEFT PEDICULE. (4 nat. size.)

GYN. No. 9540. The specimen is of interest only as forming the key to Fig. 27. One of the myomatous nodules had evidently become completely separated from the uterus and engrafted itself on to the peritoneum just above the pelvic brim.

Operation. Hysteromyomectomy and appendectomy. When the abdomen was opened, a myoma was seen lying just above the pelvic brim, absolutely independent of the uterus, and attached to the mesentery at the inner side of the cecum (Fig. 27). The uterus was irregularly nodular (Fig. 28) and about three times its natural size. It was amputated through the cervix and removed. The appendix was adherent to the parasitic myoma and was also removed. The parasitic myoma had obtained most of its blood-supply from the superior mesenteric vessels. It was entirely outside the pelvis and in no way connected with the uterus. The patient made a rather tardy recovery. She was extremely constipated and had vesical irritability.

On histologic examination the parasitic myoma showed extensive hyaline changes, but there were no further evidences of necrosis.

ADVENTITIOUS INTESTINAL VESSELS FURNISHING NOURISHMENT TO UTERINE MYOMATA.

Uterine myomata, whether complicated with pathologic lesions in the appendages or not, are prone to develop adhesions, and naturally, where adhesions exist, the intestines may be implicated. As a rule, these adhesions consist chiefly of fibrous tissue, but should the uterine nourishment to the myoma diminish, arteries will occasionally be sent from the intestines to the tumor along the already existing adhesions.

In the accompanying group we mention only the more pronounced cases.

In Case 6324 (Fig. 30) a large pedunculated myoma sprang from the posterior surface of the uterus and attached to over half of the anterior surface were dense intestinal adhesions containing many blood-vessels. The intestines furnished a liberal blood-supply to the myoma.

In Case 9027 a multinodular myomatous uterus received much nourishment from the omental vessels. The intestines were adherent to one of the tumors. These adhesions consisted almost entirely of blood-vessels. The main tumor in this case weighed 29 pounds.

The multinodular myomatous uterus in Case 6774 was wedged in the pelvis by adhesions. The sigmoid flexure was densely adherent to the uterus and furnished the tumor with large adventitious vessels.

In Case 7226 the patient was in a precarious condition, due to partial intestinal obstruction caused by the adherent multinodular myomatous uterus. One of the pedunculated myomata was becoming strangulated, through torsion of the pedicle. On exposure the sigmoid flexure was found adherent to the tumor and sending numerous well-developed vessels to the myoma.

In Fig. 29 we see numerous vessels passing from the rectum to the myoma. The right tube and ovary also seem to furnish their quota of blood to the tumor.

In some instances the relation between the pedunculated myoma and the intestine becomes very close, and if the myoma undergoes degeneration, with cavity formation, an opening may be established between the cavernous myoma and the intestine. Such a condition existed in Case 9078 (Fig. 32). The pedunculated myoma had received part of its nourishment from the omentum, part from the uterus, and the remainder from the cecum. A direct communication existed between the interior of the degenerated myoma and the lumen of the cecum.

An even more advanced case, somewhat similar in character, came under the care of Dr. J. Mason Hundley, of the University of Maryland. The patient had been under the observation of another physician for over two years and a diagnosis of uterine myoma had been made. At operation a uterus practically normal in size was found. It contained a small subperitoneal myoma. Filling the pelvis was the parasitic cystic myoma seen in Fig. 33. It had received its entire nourishment from the small bowel, and had a broken-down cavity in its center. This communicated directly with the lumen of the gut, allowing the

free passage of fecal matter from the bowel into the parasitic nodule. The myoma was attached to the uterus by a few slender adhesions.

Such a condition is exceedingly rare, and yet the possibility of so serious a complication should not be overlooked.

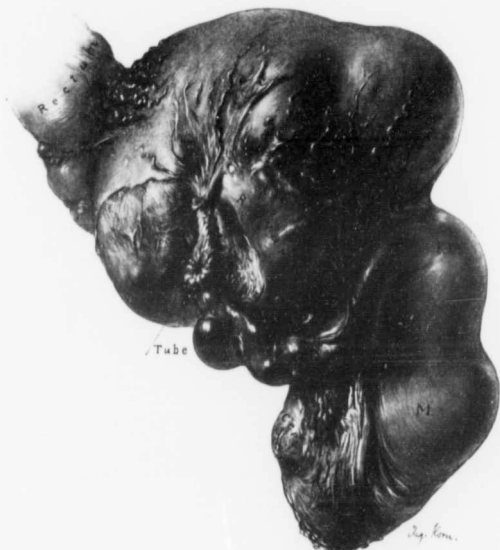

FIG. 29.—A MYOMA RECEIVING MUCH OF ITS NOURISHMENT FROM THE RECTUM AND APPARENTLY FROM THE RIGHT OVARY AND TUBE. ($\frac{1}{2}$ nat. size.)

C. H. I. No. 1844. The uterus contained several myomata. The largest is posterior to the uterus and was firmly fixed on the pelvic floor. From the fimbriated end of the right tube and from the inner end of the right ovary many vessels pass to the myoma. Numerous vessels are also seen extending from the rectum to the tumor.

Gyn. No. 6324.

A large subperitoneal pedunculated myoma, receiving much of its nourishment from the intestines (Fig. 30).

N. R., colored, aged thirty-six, married. Admitted August 26; discharged October 1, 1898. The patient has had an abdominal enlargement for the past six years. She has had two children, but no miscarriages.

Operation, August 29, 1898. Hysteromyectomy. An incision 15 cm. in length was made through thick abdominal walls and a large pedunculated myoma found. The upper portion of the tumor and part of its posterior surface were

densely adherent to the intestines. The large tumor extended well up under the costal margin. The enucleation was begun in the pelvis, by tying off the pedicle of the large tumor and of a smaller one on the left side. The tumor was next lifted out of the abdomen, the intestines were covered with warm gauze, and the separation of the tumor and intestines was effected. The intestinal adhesions were very dense, and contained numerous quite large blood-vessels. The tumor had evidently received a considerable part of its blood-supply from the adherent intestines. The raw areas were brought together with catgut and the abdomen was closed. The highest post-operative temperature was 101.4° F. The patient made a satisfactory recovery.

Gyn. No. 9027.

A multinodular myomatous uterus receiving part of its blood-supply from the intestines.

E. S., colored, aged thirty-nine. Admitted August 30; discharged October 5, 1901. The patient has been married twenty-two years and has had one child. For ten years she has thought that she had an abdominal tumor, but this was only definitely determined three weeks ago. During the last year it has grown considerably and she has lost a good deal in weight. At present she is rather pale, but fairly well nourished.

Operation. Hysteromyomectomy. When the abdomen was opened, a multinodular myoma was immediately seen. A large portion of its surface was covered with adherent omentum and many of the omental vessels entered directly into the tumor, instead of spreading out on the surface. The intestines were adherent in several places, and these adhesions consisted almost entirely of blood-vessels. After the adhesions had been separated, the uterus was removed without difficulty. It weighed 29 pounds. The patient was discharged in good condition.

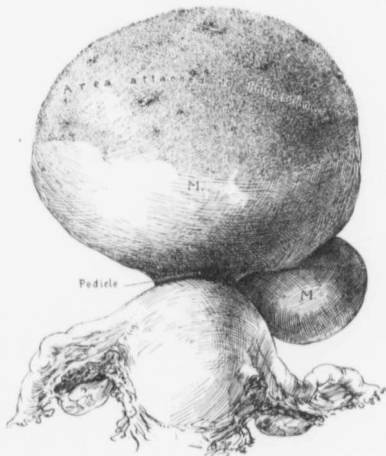


FIG. 30.—A LARGE SUBPERITONEAL PEDUNCULATED MYOMA, RECEIVING MUCH OF ITS NOURISHMENT FROM THE INTESTINES.

Gyn. No. 6324. The large pedunculated subperitoneal nodule shows a raw area over its upper and anterior surface. Here it was completely covered by intestinal loops, which were densely adherent to it. The intestines had sent large vessels into the tumor, as is seen by the cross-sections of arteries and veins scattered throughout the roughened raw area.

Gyn. No. 6774.

A myomatous uterus receiving a large adventitious vessel from the sigmoid flexure.

H. R., white, aged forty-two, single. Admitted March 18; discharged April 22, 1899. One sister had had uterine myomata, another sister an ovarian cyst. The patient had a soft systolic murmur in the pulmonic area and at the apex, which was probably hemic.

Operation, March 20, 1899. A large tumor was found wedged in the pelvis. The mass was gradually lifted and enucleation begun on the left side. There was a hematoma containing 120 c.c. of thick, tarry fluid on that side. On reaching the pelvic floor on the left side dense adhesions were discovered between the tumor and the sigmoid. These were freed with scissors. On cutting them across and rolling the tumor out it was found that a large vessel passed directly from the sigmoid into the tumor. The operation was completed in the usual way. The highest postoperative temperature was 100.5° F.

Gyn. No. 7226.

A myomatous uterus receiving well-developed blood-vessels from the sigmoid flexure.

M. J., colored, aged thirty, single. Admitted September 22; discharged November 4, 1899.

Operation. Hysterosalpingo-oöphorectomy. The operation was complicated by dense adhesions requiring a great deal of dissection. There was a cystic myoma, the size of an orange, dark blackish green in color. This lay just in the median line, above the brim, and was attached to the tumor proper by a pedicle 2 cm. long. It had become twisted on itself once and was evidently undergoing necrosis. Firmly adherent to this mass at its upper margin were two separate coils of intestine. The ileum everywhere else above the brim was perfectly free. The bladder was drawn high up over the nodule. The uterus was removed from left to right. The adhesions from the sigmoid flexure to the tumor contained large well-developed vessels. These were tied both ways and separated. The tissues were exceedingly vascular. Great difficulty was experienced in liberating the bladder, and the utmost care was exercised to avoid injuring the ureters. In this case a second operation was necessary on account of kinking of the ileum causing partial obstruction. The patient was in a very weak condition. The tumor weighed 14 pounds. She gradually recovered.

Path. No. 3486. The specimen consists of the enlarged uterus, with its appendages. The uterus is nodular, approximately 13 cm. in diameter. Attached to its surface are numerous vascular adhesions. Springing from it are several pedunculated and sessile nodules. The largest pedunculated tumor, both in shape and size, bears a strong resemblance to a spleen (Fig. 31). It measures 12 x 9 x 7 cm., and is attached to the surface of the uterus by a delicate

pedicle, 1.5 x 0.7 cm. On section, the spleen-shaped nodule presents a dark, reddish-brown, glistening appearance and is traversed by fibrous bands of a pinkish color. The uterus contains interstitial nodules varying from a pea in size to 5 cm. in diameter. The largest of these is undergoing necrosis. The uterine cavity is 8.5 cm. in length. The mucosa is smooth and glistening, but not more than 1 mm. in thickness. The right tube is normal. The left tube and both ovaries are covered with adhesions.

Microscopically, the nodule described as resembling a spleen presents large areas of coagulation necrosis accompanied by hemorrhage. In the degenerated areas the blood-vessels are much dilated. It is only in the outlying portions of the growth—in other words, in the capsular portion—that the typical myomatous tissue is preserved. It was this myoma that had twisted and was undergoing degeneration.

Gyn. No. 9078. Path. No. 5234.

Multinodular myomatous uterus with a subperitoneal pedunculated nodule, partially parasitic, undergoing suppuration and communicating with the cecum (Fig. 32).

E. C., white, aged thirty-six. Admitted September 21; discharged October 30, 1901. (For the patient's former admissions to the hospital see Nos. 7315 and 8992.) Complaint: abdominal tumor and uterine hemorrhage. The patient began to menstruate at fifteen, was always regular, with a profuse flow lasting at least seven days. She had a miscarriage nine weeks before admission, and since that time she has had constant bleeding. She has been married sixteen years and has had two children, fifteen and ten years respectively. Two years ago she was admitted to the hospital and an ether examination was made. At that time three myomata were detected. For some time before this the patient had sharp pains in both groins. Following the ether examination the patient felt very well until she became pregnant in April. Since then she has had bearing-down pains, aching and throbbing. These pains became much more severe at the time of her miscarriage and have continued since. She has lost 30 pounds in weight during the last six months.

On examination she is not very pale, despite the history of hemorrhages. The hemoglobin is 56 per cent.

Operation. Hysteromyectomy, right oöphorectomy, appendectomy, suture of cecum. The patient during the operation was in such a precarious condition that ether had to be discontinued. The fundus was found pushed somewhat to

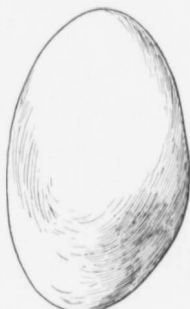

FIG. 31.—A SPLEEN-SHAPED MYOMA.

Gyn. No. 7226. Path. No. 3486. This myoma had undergone torsion. It showed areas of necrosis and had become adherent to the intestinal loops.

the right by an intraligamentary myoma. To the right was a second myoma rising from the cornu, covered by omentum and very adherent. From this a thick fibrous band passed to the small bowel. The myoma attached to the right cornu had a rather pale gray color and looked necrotic. Its pedicle was very long and was easily twisted off from the uterus without any bleeding, the tumor apparently having drawn its blood-supply from the omentum. It rested on the head of the cecum but was not very adherent to it, and during the attempt to separate the adhesions an opening, 5 mm. in diameter, was detected

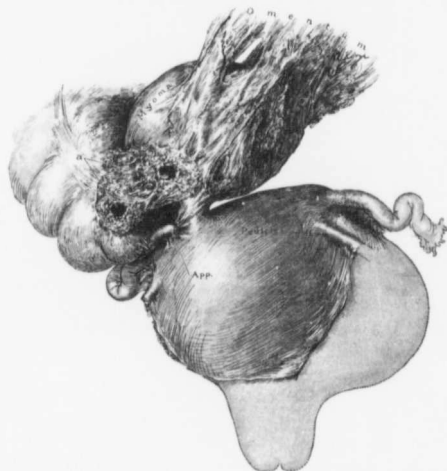


FIG. 32.—A SUPPURATING SUPERFITEOUS MYOMA COMMUNICATING WITH THE LUMEN OF THE CECUM.

GYN. No. 9078. Path. No. 5234. The uterus is somewhat enlarged, owing to the presence of a myoma, which projects into the left broad ligament. Attached to the fundus near the right tube is a pedunculated myoma, which measured 7 x 5 cm. Plastered to its surface and furnishing considerable nourishment is the densely adherent omentum. The center of the myoma contained an abscess cavity which opened directly into the cecum. The myoma has been dissected free from the cecum, so that the opening is clearly seen at a.

reaching from the cecum to a cavity in the tumor (Fig. 32). The remaining adhesions were freed and the myoma was removed. The right tube and ovary and appendix were brought into view. The appendix was buried in more or less necrotic tissue along the head of the cecum. It was gradually dissected out and its stump cut off flush with the wall of the cecum and then this and the fistulous tract were turned in with numerous buried silk sutures. Enucleation of the uterus from left to right was rather easily carried out. A gauze drain was left in and carried down to the head of the cecum. The patient gradually recovered and left the hospital in good condition.

Path. No. 5234. The specimen consists of a subperitoneal myoma, which was partially parasitic and opened into the cecum. The tumor is ovoid in shape, 7 cm. long, 5 cm. in its broadest diameter. Its surface is rough, and shows innumerable small tags of adhesions. At one point the old pedicle can be made out. Attached to the tumor is a considerable amount of omentum, and to the feel the tumor is yielding. On section a firm fibrous capsule, 3 mm. thick, is evident. Inside this the tissue is less firm, yellowish in color, and apparently undergoing degeneration.

Another portion of the specimen consists of the uterus and adherent tumor, both tubes, and the right ovary. The mass measures 11 x 8 cm. The intraligamentary myoma on the left side measures 7 x 7 x 5 cm. The left tube is uniform in diameter, 13 cm. long, and at its distal portion has been converted into a small cyst. On the right side the tube and ovary are closely bound together.

Histologic Examination.—The necrotic myoma which communicated with the bowel has broken down and is infiltrated with polymorphonuclear leukocytes and small round cells. It shows evidence of chronic inflammation. The appendix is the seat of a chronic appendicitis.

Dr. J. Mason Hundley's case of a parasitic myoma undergoing suppuration and opening directly into the small bowel (Fig. 33).

M. E. C., white, aged thirty-nine, single. She was never robust, but had no serious illness until July, 1900. In this year she began to have irregular uterine hemorrhages, which were very profuse. She had a sinking spell and from that time gradually grew weak and lost flesh. In March, 1903, she had a fall, and the injuries sustained necessitated her remaining in bed for several weeks. While in bed she passed a number of large bloody stools, had fever and chills, and suffered with abdominal pain.

A diagnosis of tumor of the uterus had been made in February, 1902, and again in 1904. An operation was not advised, as it was thought that the tumor would

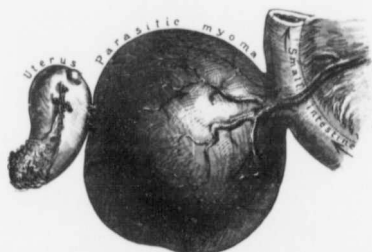


FIG. 33.—A MYOMA RECEIVING ITS NOURISHMENT FROM THE MESENTERY OF THE SMALL BOWEL AND CONTAINING AN ABSCESS CAVITY WHICH COMMUNICATED WITH THE LUMEN OF THE INTESTINE.

Dr. J. Mason Hundley's case. As noted from the history, the myoma at one time was uterine. The uterus was nearly normal in size and projecting from its surface was a small myomatous nodule. The parasitic myoma measured 12 cm. in diameter and was attached to the uterus by a few adhesions. It received nearly all of its blood-supply from the mesentery of the small bowel. Its central portion had been converted into an abscess cavity 10 cm. in diameter, which communicated with the lumen of the bowel by an opening 2 cm. in diameter. The fecal matter passed freely into and from the myoma, as indicated by the arrows.

cease to give trouble. Dr. Hundley saw the patient on December 5, 1904, and advised operation.

Operation, December 12, 1904. The tumor seemed to be adherent everywhere, but in reality it was attached to the uterus merely by a few slender adhesions. It had apparently originated in the posterior wall of the uterus. Its blood-supply was now derived from a portion of the ileum (Fig. 33), which supplied vessels as large as the radial artery. The lumen of the adherent portion of the bowel communicated with the cavity in this tumor, and the cavity in the myoma contained grape-seeds and fecal matter. About five inches of the bowel were resected. The patient died three days later, but at autopsy there was no evidence of infection.

The parasitic cyst is 12 cm. in diameter and the cavity in its longest diameter is 10 cm. The cavity communicated with the lumen of the gut by an opening 2 cm. in diameter. Its walls are soft and ulcerated. The growth received a rich blood-supply from the intestine. Sections from numerous areas of the abscess wall show that it is composed of very dense myomatous tissue. It is vascular and highly inflamed. There is no evidence of sarcomatous transformation. The intestinal walls near the attachment of the growth show an extensive inflammatory process and marked vascularity.

In this case it is difficult to say with absolute certainty how long the myoma had communicated with the bowel, but the passage of a number of large bloody stools in 1903, accompanied by the elevation of temperature and pulse, strongly indicates that there was an opening between the two at this period.

ADVENTITIOUS VESSELS FROM THE BLADDER SUPPLYING NOURISHMENT TO UTERINE MYOMATA.

One of the first questions the surgeon asks himself before making an abdominal incision when a myomatous uterus exists is, "Is the bladder high up?" This dislocation of the bladder is fully dealt with in another chapter, and here we are chiefly interested in the blood-supply that the bladder or its arteries may furnish to a neighboring myoma. In our series only seven myomata derived any appreciable amount of nourishment from the bladder.

In Case 12194 a large multinodular uterus was present. The ovarian and uterine blood-vessels were greatly distended. Rising from the anterior portion of the uterus was a myoma with little or no uterine attachment. It apparently derived its blood-supply from the tissues surrounding the bladder.

In Case 7739 a tumor filled almost the entire abdominal cavity. Much nourishment was furnished by the omentum, but a portion was contributed by very vascular adhesions from the bladder and from the anterior and left lateral abdominal wall.

The bladder in Case 3842 was so intimately attached to the tumor that a piece 1 x 6 cm. was excised with the growth. In this case omental and intestinal adhesions also existed.

Probably the most extensive vesical blood-supply to a myoma that one is likely to encounter was noted in Case P. (Fig. 25, p. 36). Here the bladder was drawn high up into the abdomen, and from its posterior surface many large and tortuous vessels passed to the tumor.

In Case 5784 (Fig. 22, p. 28) the bladder supplied its quota of blood to the myomatous uterus. Here there were large tortuous vessels emerging from the pelvis and entering the tumor.

In Case 6915 the bladder also apparently supplied many vessels to the enlarged uterus. In one of our recent Hagerstown cases (Fig. 34) numerous vessels passed from the bladder to two subperitoneal myomata.

Gyn. No. 12194. Path. No. 8776.

A multinodular myomatous uterus with one of its nodules deriving its chief blood-supply from the tissues surrounding the bladder.

S. C., colored, aged thirty-nine, married. Admitted June 19; discharged July 28, 1905.

Operation, June 21, 1905. Hysterectomy, double salpingo-oöphorectomy, and appendectomy. The large myomatous uterus was easily delivered. One nodule rose from the posterior part of the fundus and was about the size of an adult's head; another had originated from the anterior part of the uterus low down near the cervix. This had drawn the bladder reflection of the peritoneum high up over the tumor mass. All the pelvic vessels were greatly distended. The uterus was removed in the usual way. The tumor arising from the anterior part of the uterus was nearly, if not entirely, parasitic. Its connection with the uterus itself was very slight. It had derived its blood-supply apparently from the tissue surrounding the bladder.

The highest postoperative temperature was 100° F.

Gyn. No. 7739.

A multinodular myomatous uterus with dense omental adhesions, also very vascular adhesions from the bladder and from the anterior and left lateral abdominal walls.

M. R., colored, aged twenty-nine, married. Operation. Hysterosalpingo-oöphorectomy and removal of tumor of the right ovary. The abdomen was nearly filled with a large solid tumor. The omentum was everywhere adherent. Some of the vessels were the size of a little finger and looked just like large worms. The tumor was adherent to the bladder, the anterior and left lateral abdominal walls. These adhesions were exceedingly vascular. The patient was well when discharged.

Gyn. No. 3842.

Dense adhesions between the bladder and a myomatous uterus.

E. W., colored, aged fifty-two, married. Admitted October 2; discharged November 9, 1895. Operation October 10, 1895. Hysteromyomectomy. The large myomatous uterus had drawn the bladder almost to the umbilicus. The adhesions between the tumor and the bladder were so dense that a piece of bladder 1 x 6 cm. was excised, and the wound closed with four mattress sutures. There were also adhesions to the omentum, intestines, and rectum. The patient was well when discharged.

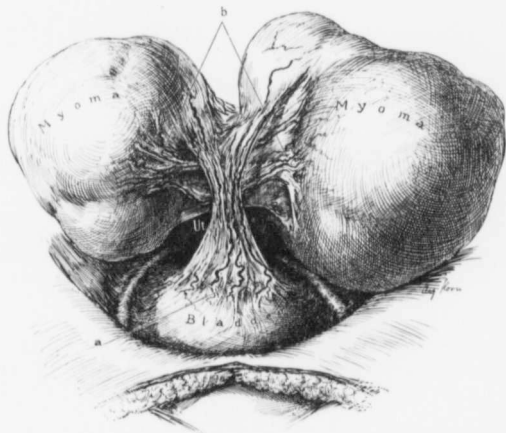


FIG. 34.—PEDUNCULATED MYOMATA RECEIVING A LARGE PART OF THEIR NOURISHMENT FROM THE BLADDER.

C. G., seen in consultation with Drs. Preston and Victor Miller at the Hagerstown Hospital, June 14, 1907. Passing from the bladder to the two myomata, and hiding the fundus, were broad adhesions (a) carrying large blood-vessels. Adhesions and blood-vessels (b) also passed from one tumor to the other. The tumors were attached to the uterus by relatively small pedicles.

C. G. (Hagerstown, Md.).

Pedunculated myomata receiving a large part of their blood-supply from the bladder (Fig. 34).

C. G., colored, aged twenty-eight, seen with Drs. Preston and Victor Miller, of Hagerstown, June 14, 1907. This patient had a large myomatous uterus. On opening the abdomen we immediately encountered large vessels running from the bladder into a subperitoneal myoma. In the adhesions there were at least three or four arteries. The myoma itself was the size of a child's head. Immediately behind the uterus was a nodule similar in size. From this to the

other
ones.
The

VES:

M
nal w
passir
prove

C.
before
On ac
mass
less fi
On
lated
and re
the ap
lateral
vessel-
to the

MYOM.
In
becom
myom
the ut
The fe

M.
20, 190
Recent
or five
but ha
Ope
myome
uterus
depend
tumor

other nodule passed an artery at least 5 mm. in diameter, also several smaller ones. We liberated the bladder adhesions and did a complete hysterectomy. The patient stood the operation well and made a good recovery.

VESSELS FROM THE ABDOMINAL WALL FURNISHING ABUNDANT NOURISHMENT TO A PARTIALLY PARASITIC MYOMA.

Myomata not infrequently become adherent to the lateral or anterior abdominal wall; it is, however, unusual to have blood-vessels of any appreciable size passing between the abdominal parietes and the myoma. The following case proves, however, that such a condition occasionally occurs.

Gyn. No. 15283.

C. B., colored, aged thirty. Admitted November 13, 1908. Four weeks before entering the hospital she first noticed a tumor in the lower abdomen. On admission her abdomen was found distended by an irregularly nodular mass which reached 4 cm. above the umbilicus. The nodules seemed more or less fixed, but there was no unusual abdominal tenderness on palpation.

On opening the abdomen, one of us (Kelly) found several very large pedunculated myomata. One of them had large lymphatics coursing over its surface and received much blood from the omentum. In addition, vessels passed from the appendix to the large myoma and dense adhesions to the right anterior and lateral abdominal walls furnished many vessels to the tumor (Fig. 35). These vessels were very abundant and paralleled each other from the abdominal wall to the tumor.

MYOMATA EXTRUDED FROM THE UTERUS AND LYING FREE IN THE BROAD LIGAMENT.

In the foregoing pages we have described subperitoneal myomata that have become partially or completely separated from the uterus. Occasionally a myoma that has been extruded into the broad ligament loses its connection with the uterus and receives a meager blood-supply from the tissue in which it lies. The following case is a good example of such a condition.

Gyn. No. 9674.

M. McM., white, aged thirty-seven. Admitted May 27; discharged June 20, 1902. Menstruation began at thirteen, was regular and moderate in amount. Recently the periods have become irregular, the patient sometimes going four or five months without any menstrual flow. She has been married eight years, but has never been pregnant.

Operation. Removal of a parasitic myoma, release of adhesions, multiple myomectomy, suspension of the uterus. When the abdomen was opened the uterus was found in retroposition. There were a few adhesions about the left appendages. Beneath the round ligament and in the broad ligament was a hard tumor the size of a small egg. It was slightly movable. The peritoneum was

incised, the tumor shelled out, and the hole left behind closed with catgut. Two small myomata of the fundus were shelled out and the incision was closed.

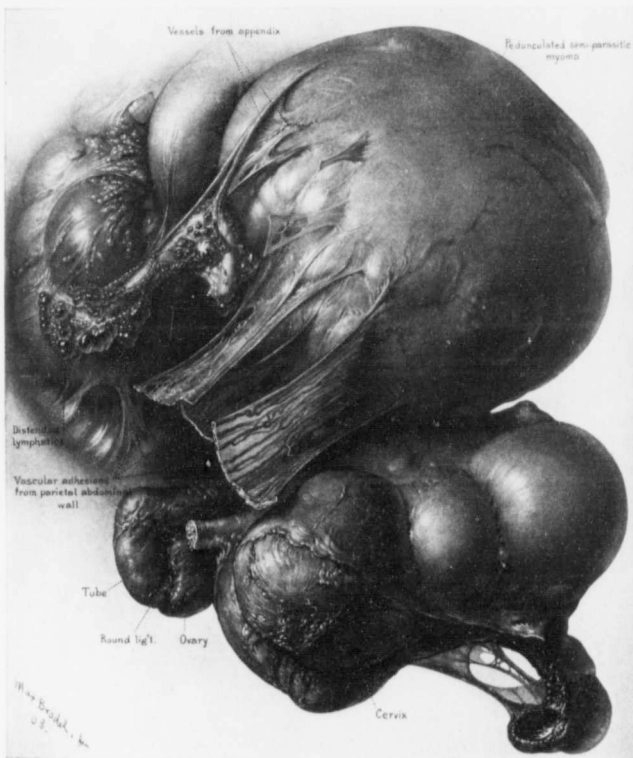


FIG. 35.—A MULTILOBULAR MYOMATOUS UTERUS WITH VESSELS PASSING FROM THE RIGHT ABDOMINAL WALL AND APPENDIX TO A LARGE PEDUNCULATED MYOMA.

Gyn. No. 15283. Path. No. 13199. The multilobular myomatous uterus, with its attached pus-tubes, filled the pelvis. The large globular pedunculated myoma was free from omental adhesions, but was attached to the parietal abdominal wall by broad adhesions. Traversing these were many blood-vessels which passed to the tumor to the abdominal wall. The smaller adhesions also contained vessels, but of less caliber.

The appendix was adherent, and numerous superficial appendiceal vessels passed over to the myoma. Covering the surface of the appendix were clusters of small, smooth-walled cysts, apparently dilated lymphatics. They were particularly abundant near the cecal junction.

The myoma in the broad ligament had no apparent connection with the ligament itself or with the uterus. The patient recovered without incident.

CHAPTER III.

CERVICAL MYOMATA.

In a few of our cases the myomata developed low down in the body of the uterus or in the cervix. Such growths may spread out in front of or behind the cervix,* but are more prone to separate the folds of the broad ligament, thus becoming in part intraligamentary.†

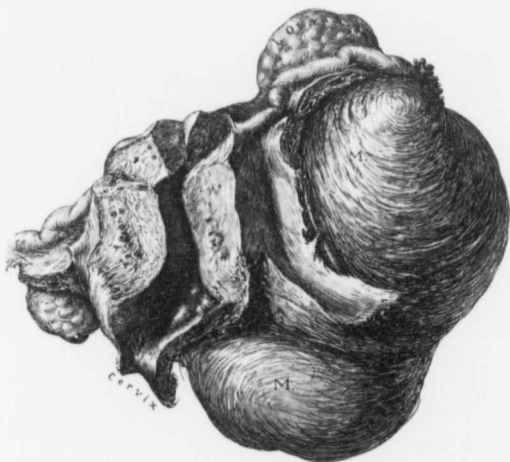


FIG. 36.—MYOMA OF THE BROAD LIGAMENT AND CERVIX. († nat. size.)

Gyn. No. 5732. Path. No. 2055. The irregular myoma, 10 x 13 cm., fills the left broad ligament and is in part cervical. In such a case control of the left uterine vessels is difficult. The cervical canal is considerably distorted. The appendages are normal.

Cervical myomata are of interest chiefly from a clinical standpoint. They may so block the pelvis that, where pregnancy exists, a normal labor is out of the question and operative measures must be undertaken. Thus, in case G., the

* Marked cervical development of myomata was noted in Cases 2434, 3971, 4022, 5752, 7059, 7240, 8866, 9780, 9798, 10056, 10242, and 11243.

† Intraligamentary development was particularly prominent in Cases 3971, 4172, 4370, 4586, 5752, 6915, 7181, and 9823.

pelvis was partly blocked by a myoma that had developed in the anterior wall of the cervix (Fig. 328, p. 532). After abdominal removal of the myoma the patient, who was four months pregnant, proceeded to term and had a normal labor.

Again, when hysterectomy is necessary, the uterus is often found firmly wedged in the pelvis and its removal is fraught with much difficulty. During the shelling out of these tumors exceptional care has to be exercised not to injure or tie one or both ureters, as they are so intimately connected with the tumor. At times it is practically impossible to dislodge cervical myomata without first

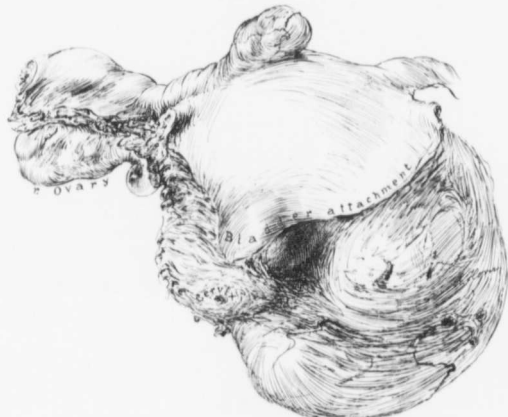

FIG. 37.—A MYOMA OF THE BROAD LIGAMENT AND CERVIX. ($\frac{1}{4}$ nat. size.)

Path. No. 6920. The uterus is somewhat enlarged, owing to the presence of small myomata. Extending far out into the left broad ligament is a globular myoma. Its lower half is cervical and extends quite a distance below the point at which the cervix was amputated. In such a case it would be best to control the right ovarian vessels, the right round ligament, and the right uterine vessels, cut through the cervix, and then catch the left uterine vessels.

bisecting them. The accompanying illustrations will give a clear conception of the various forms of cervical myomata encountered.

In Fig. 36 is represented a myoma which fills the left broad ligament and whose lower portion is cervical. The uterus has been distorted and pushed toward the right.

Fig. 37 also represents a myoma filling the left broad ligament. The lower part is cervical, and extends far below the level at which the cervix has been amputated. Naturally, much difficulty may be encountered in controlling the left uterine vessels in such a case.

The cervical myoma in Fig. 38 occupies the anterior wall and spreads out

slightly into both broad ligaments. The cervical mucosa over the anterior wall had become somewhat atrophied as a result of the tension and it will be readily seen that the cervical stump was much bigger than usual.

In Fig. 39 we have not only a myomatous condition of the fundus, but also a general myomatous condition of the cervix. The various nodules completely surround the small cervix.

Fig. 40 gives an example of the marked cervical development that may occasionally be attained. This patient (Gyn. No. 9798) for a year had had pain in the

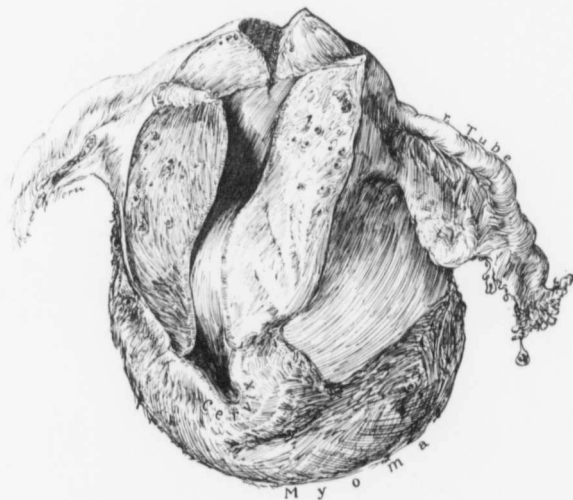


FIG. 38.—A CERVICAL MYOMA. ($\frac{1}{3}$ nat. size.)

Gyn. No. 3971. Path. No. 977. The upper part of the body of the uterus and the appendages are normal. Occupying the anterior portion of the cervix and bulging into the cervical canal is a myoma, 11 cm. in diameter. The cut surface of the cervix was naturally larger than usual, being 4.5 cm. in diameter.

lower abdomen and backache and her periods had been more profuse and of longer duration than before. There was frequency of urination, with almost loss of control. The vaginal vault was occupied by a myomatous cervix and the cervical canal was represented by a small slit. Anteriorly and to the right the mass could be moved about, but not pushed up out of the pelvis. Upward, the tumor extended almost to the umbilicus. A glance at the picture shows that the fundus is enlarged, but the chief increase in size is due to an essentially cervical myoma, which has originated in the posterior wall and literally un-

folded the external os. It was necessary not only to remove the uterus completely, but also to excise with it a portion of the vaginal mucosa.

Fig. 41 represents a myoma that was firmly fixed in the pelvis and required not only much patience, but also rapid work in its removal. The tumor had grown from the anterior surface of the uterus and cervix and filled Douglas' sac almost completely. In this case the bladder occupied the lower angle of

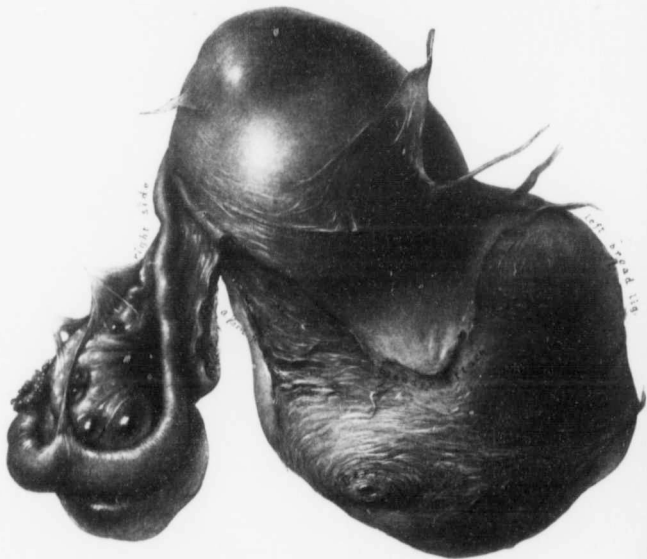


FIG. 39.—CERVICAL DEVELOPMENT OF MYOMATA. (4 RAT. SIZE.)

Gyb. No. 9780. Path. No. 5996. The body of the uterus contained several small myomata and was partially covered with adhesions. The right tube and ovary are adherent. Occupying the lower part of the body, and extending out into the left broad ligament and surrounding the cervix, are myomata. Those on the left side extend below the point at which the cervix was amputated. The uterus was removed from right to left. The left ureter was exposed for a distance of 5 cm.

the incision and extended 16 cm. above the symphysis. The bladder was liberated and pushed down. The left ovarian vessels were ligated, the left round ligament was controlled and cut; the corresponding structures of the right side were then dealt with in a similar manner. The right uterine artery was now found and ligated on the surface of the tumor. The operator, not being able to enucleate further, cut through layer after layer of the uterine tissue until the tumor proper was reached, after which completion of the enucleation was easy.

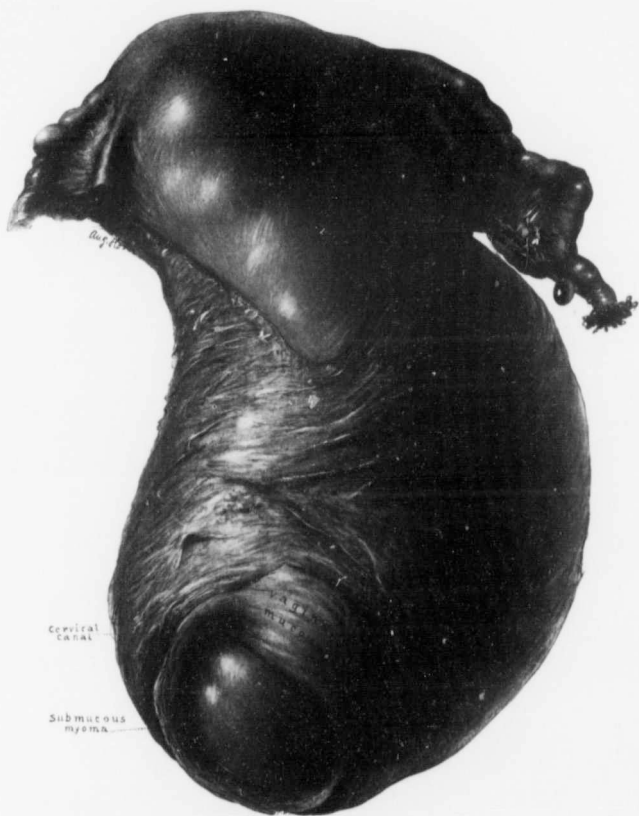

FIG. 40.—A VERY LARGE CERVICAL MYOMA. ($\frac{2}{3}$ nat. size.)

Gyn. No. 9788. Path. No. 6013. The body of the uterus is considerably enlarged. The cervix is occupied by a very large and approximately globular mass, which occupies the anterior wall and bulges into the cervical canal, literally unfolding it. An irregular cuff of vaginal mucosa was removed with the uterus. The uterine vessels were tied high up. The vaginal veins were carefully clamped as encountered and hence little bleeding occurred during the operation.

The vagina was widely opened. On the eighth day the patient had signs of cardiac dilatation with almost complete anuria. Nevertheless, she made a good recovery.

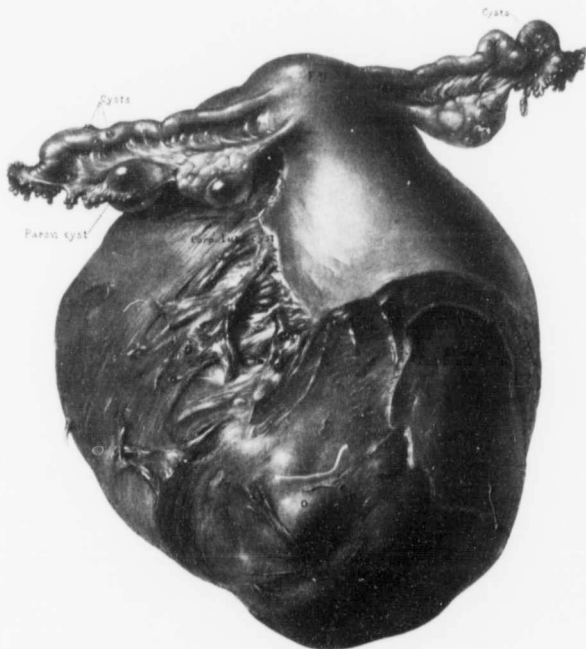


FIG. 41.—EXTENSIVE CERVICAL DEVELOPMENT OF A MYOMA. (2 NAT. SIZE.)

GYN. No. 7240. Path. No. 3502. The normal fundus and the practically normal appendages are perched on the upper surface of a large myoma, which occupies Douglas' pouch and extends out into the broad ligaments. The left uterine vessels are clearly seen on the side of the tumor. Attached to the surface of the tubes are a few small subperitoneal cysts. On the left side is a very small parovarian cyst. The operation was a very difficult one.

(For the description of bisection of the uterus as practised in some of these cases see page 608.)

CHAPTER IV.

SUBMUCOUS MYOMATA.

Nearly all myomata are primarily interstitial and are gradually forced toward the outer or inner surface of the uterus. In some instances the uterus contains only one myoma, in others the myomata are as abundant as potatoes in a potato-hill. As a rule, only one myomatous nodule becomes submucous, but sometimes the entire cavity may be greatly enlarged and literally paved with them.

In Fig. 42 is shown an interstitial myoma which has grown into the uterine cavity and fills it from fundus to cervix. The uterus contained this single myoma.

Fig. 43 shows an enlarged uterus, which contains numerous interstitial myomata, while its cavity is literally paved with small myomatous nodules. In addition, a mass of myomatous tissue consisting of several smaller myomata is pedunculated and partly fills the cavity of the uterus.

The submucous development of the myoma is strikingly shown in Fig. 44. One subperitoneal and several smaller interstitial nodules are seen, but the great increase in the size of the uterus is caused by several large submucous myomata. One can readily see how such an enlarged uterus might in time expel nearly all its myomata, and eventually show little evidence of its previous size.

Size.—The submucous myomata may not reach over 1 cm. in diameter. On the other hand, they may assume very large proportions. In Case 4609, for example, the submucous tumor was so large that the uterine cavity was 24 cm. in length.

Pedunculated Myomata.—Since the submucous myomata act as foreign bodies and the uterus manifests a decided tendency to expel them,

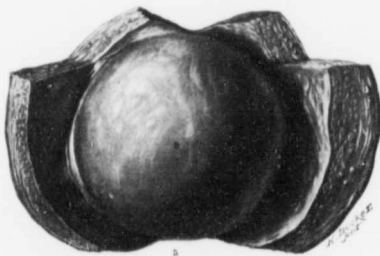


FIG. 42.—A SUBMUCOUS MYOMA FILLING THE UTERINE CAVITY.
($\frac{1}{3}$ nat. size.)

Gyn. No. 6843. Path. No. 3080. The uterus was the size of that of a four months' pregnancy. *a* represents the cervical portion. The uterine walls are of the normal thickness. Projecting into the cavity and filling it is a submucous myoma (*b*). A myoma in such a position invariably causes severe uterine hemorrhage.

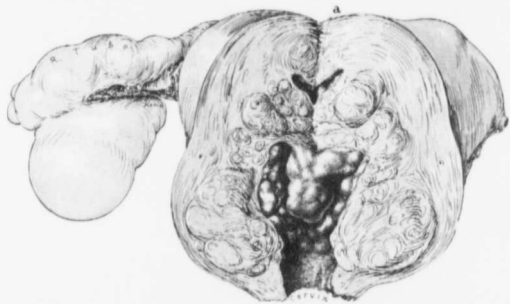


FIG. 43.—MARKED SUBMUCOUS DEVELOPMENT OF UTERINE MYOMATA. (½ nat. size.)

Gyn. Nos. 8936 and 9203. Path. No. 5378. One tube and ovary and a myoma had been removed *per abdomen* five years before. The uterus filled the pelvis and extended 6 cm. above the symphysis. Scattered throughout the walls are numerous interstitial myomata. Lining the uterine cavity are many small round myomatous nodules; in fact, the cavity is literally paved with them. *a* is the upper part of the cavity. Projecting into and partially filling the cavity is a conglomerate mass of small myomata.

When the patient entered the hospital, her hemoglobin was only 15 per cent. She was built up and a successful hysterectomy performed when the hemoglobin had reached 46 per cent.

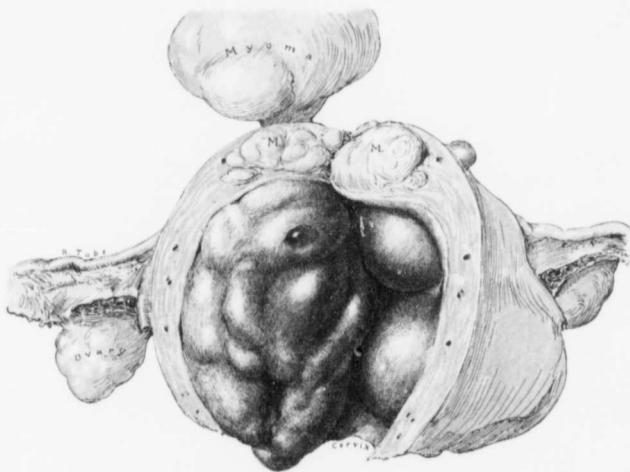


FIG. 44.—EXTENSIVE SUBMUCOUS DEVELOPMENT OF UTERINE MYOMATA. (½ nat. size.)

Gyn. No. 8495. Path. No. 4716. A vaginal myomectomy had been done three years previous to the hysterectomy. Projecting from the fundus is a pedunculated subperitoneal myoma and scattered throughout the walls are a few interstitial nodules.

Greatly distending and completely filling the uterine cavity are three submucous myomata. The largest one is markedly lobulated and sharply outlined from the uterine walls. The two others are sessile and one of them spreads out into the left broad ligament.

It is interesting to note that for the previous four months the flow had been excessive and painful and that between periods the patient had had severe labor-like pains lasting from three to four hours. Marked exertion would bring on the pains. The largest myoma would have undoubtedly soon been expelled, provided the patient had not meanwhile succumbed as a result of the severe hemorrhages.

the myoma will be forced more and more into the cavity and gradually become pedunculated. As a result of the continued uterine contractions it may be forced completely out of the uterus, as seen in Fig. 49. Here the lobulated and

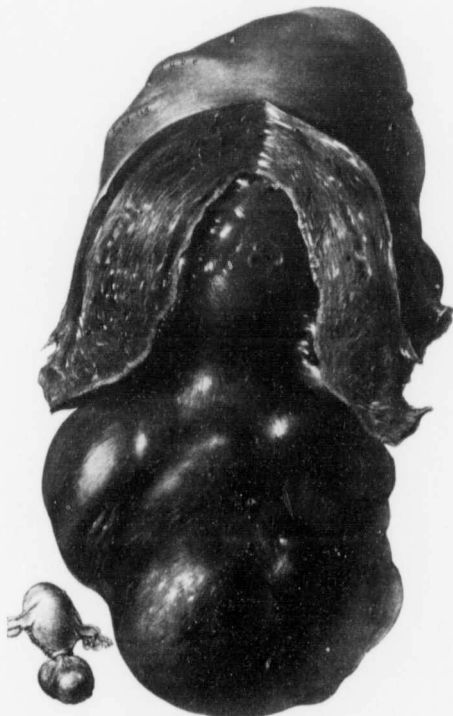

FIG. 45.—A LARGE PEDUNCULATED SUBMUCOUS MYOMA. ($\frac{1}{2}$ nat. size.)

Gyn. No. 6433. Path. No. 2653. The nodular myomatous uterus measured 10 x 11 x 13 cm. Projecting through the cervix and attached by a broad-based pedicle is a lobulated submucous myoma, 8 x 10 x 11 cm. The exact relations are indicated in the small sketch on the left. The myoma showed a good deal of disintegration.

The patient was poorly nourished and very anemic; her face had a drawn expression. She made a good recovery.

roughened myoma projects from the cervical canal and the cervical lips form a collar around its pedicle. The pedicle of such a myoma may be several centimeters in diameter, but is often attenuated, as seen in Fig. 50.

From Fig. 45 we get a good idea of a large myoma which projects from the cervix and fills the vagina, and which is still very firmly fixed as a result of its broad basal attachment. Its pedicle would in time, however, become so attenuated that the submucous growth could be removed with the utmost ease.

In Case 909 the submucous myoma measured 7 x 8 cm., and the pedicle was so delicate that the tumor easily rotated on its axis. In Case 4382 the pedicle was even more attenuated, the myoma becoming completely detached during the preparatory vaginal washing.



FIG. 46.—A LARGE PEDUNCULATED SUBMUCOUS MYOMA. ($\frac{1}{5}$ nat. size.)

C. H. I. R., October 25, 1902. Path. No. 6226. Projecting through the cervix and completely filling the vagina was a large lobulated submucous myoma. It bled so freely, and the patient was so blanched, that operation was at first deemed impossible. The dilated but otherwise normal cervix is clearly seen. The body of the uterus contains numerous small myomata. The uterus was removed *per abdomen* and the patient made a good recovery.

In Fig. 46 we have an example of a submucous, pedunculated myoma, practically as large as the myomatous uterus with its appendages combined. This myoma completely filled the vagina; it bled profusely and was removed with great difficulty.

When the uterus contains but one myoma and this becomes submucous and pedunculated, as in Fig. 48, with the removal of this growth all trace of pelvic disturbances usually disappears.

SLOUGHING SUBMUCOUS MYOMATA.

(For the histologic appearances of the mucosa covering submucous myomata see page 312.)

Many of the submucous nodules undergo partial and occasionally complete



FIG. 47.—A PORTION OF A LARGE INTERSTITIAL MYOMA THAT HAS BECOME SUBMUCOUS AND SHOWS EARLY SIGNS OF BREAKING DOWN. (4 nat. size.)

Gyb. No. 9769, Path. No. 3982. The uterus is pear-shaped and measures 15 x 18 x 20 cm. The general outlines are altered, as the left tube and ovary are on a higher level than the right appendages. The uterine cavity has been split from cervix to fundus. Filling the cavity is the submucous portion of the tumor, which is lobulated and mottled in appearance. At b it shows commencing degeneration.

disintegration. This breaking down may occur while the tumor is still lying in the uterine cavity, or not manifest itself until the myoma has been forced into the vagina or has even emerged from the vagina.

Size.—Sometimes the tumors are very small, not reaching over 1 or 2 cm.

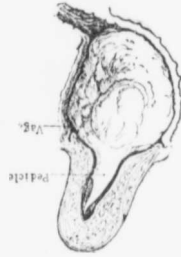

FIG. 48.—A Large Pedunculated Myoma.

FIG. 48.—A Large Pedunculated Myoma. The cervix is only slightly enlarged. The tumor is widely seated and the vagina greatly dilated by a discharge was extremely offensive and brownish in color. Projecting through the cervix is a pedunculated myoma with a markedly lobulated surface. (Case No. 810, Path. No. 4203. The body of Myoma.)

FIG. 48.—A Large Pedunculated Myoma. For details of the pedunculated myoma see Fig. 49.

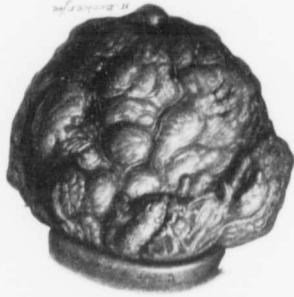

FIG. 49.—A Lobulated Myoma. (From the collection of the University of Michigan.)

FIG. 49.—A Lobulated Myoma. The myoma was grayish in color and rather soft. It was apparently sloughing.

In diameter, but not infrequently are of goodly size and may occasionally

reach the large proportions seen in Fig. 52.

The sloughing usually commences at the most dependent part of the tumor, at some point most remote from the source of blood-supply and where the tumor is most likely to be exposed to the air. In Case 2732 (Path. No. 266) we have an example of the early changes. The submucous tumor was conical in shape, measuring 2 x 3.5 x 7 cm. Near the end was dark brown in color and soft, and here pedicle its surface was pale pink, but its lower and there the surface was eroded. In Case 7237 (Path. No. 3491) the uterus was greatly enlarged, measuring 14 x 20 x 21 cm. (occupying the cavity of the uterus and projecting through the cervix was a submucous myoma, 5 x 7 x 12 cm., with a broad basal attachment. Its surface was slightly lobulated, granular, and somewhat infoliated. Histologically, the surface in places showed necrosis and some polymorphonuclear

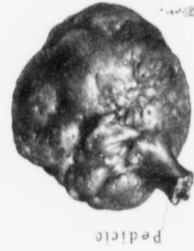

FIG. 50.—A Gascon's Myoma.

FIG. 50.—A Gascon's Myoma. The pedunculated myoma had a slender pedicle and measured 1.5 x 2.5 x 1.5 cm. It was noted in appearance having dark green, gray, and reddish brown centered over its surface. Histologic examination showed that the surface was covered with firm and polymorphonuclear leukocytes, beneath which was typical granulation tissue. The uterus contained another myoma, but smaller submucous in nature.

FIG. 51.—A Gascon's Myoma. The myoma was grayish in color and rather soft. It was apparently sloughing.

FIG. 51.—A Gascon's Myoma. The myoma was grayish in color and rather soft. It was apparently sloughing.

large myoma of the fundus filling the uterine cavity, projecting through the cervix, and showing early signs of disintegration.

When the myoma is extruded into the vagina, it often forms a globular

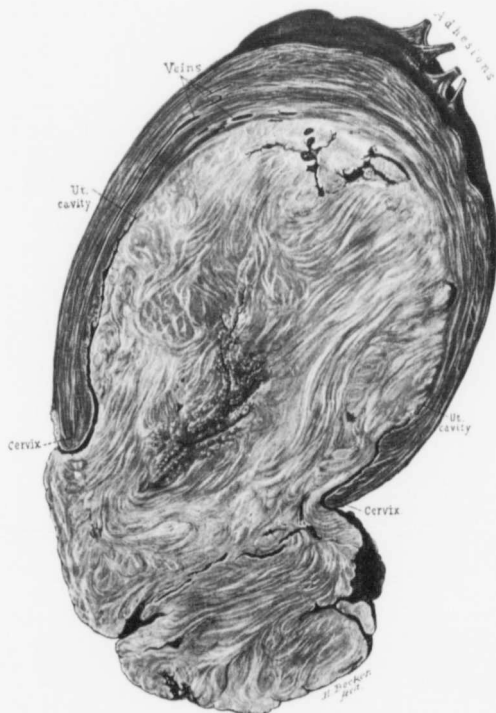


FIG. 51.—A SLOUGHING SUBMUCOUS MYOMA. ($\frac{1}{2}$ nat. size.)

Gyn. No. 7549. Path. No. 3799. The section represents half of the uterus. Attached to the surface are a few adhesions and in the neighborhood are two small myomata. Occupying the fundus and completely filling the uterine cavity is a myoma, the lower portion of which has widely dilated the cervix and extended into the vagina. The vaginal portion of the myoma had broken down to a considerable extent, and the central part of the tumor is necrotic. In time the greater part of the myoma would be extruded into the vagina if the patient did not meanwhile succumb to sepsis.

mass with a roughened surface and partially covered with a pyogenic membrane, as in Figs. 49 and 50.

In Case 1551 a submucous myoma had been removed four years before.

On admission to the hospital the myomatous uterus reached the umbilicus, while projecting from the vagina and directly continuous with the uterine tumor was a gangrenous mass.

The gangrenous submucous myoma in Case 4663 (Path. No. 1327) was 18 cm. long, and from 1 to 7 cm. in diameter. It was mottled in color, being green or reddish yellow, and necrotic.

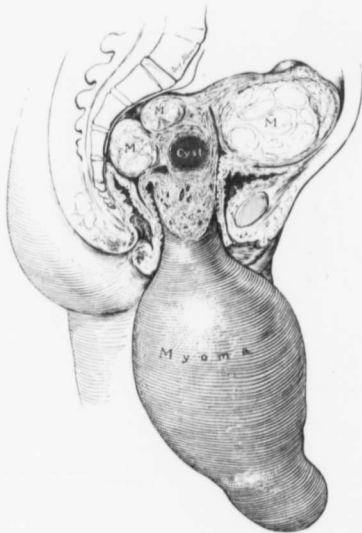


FIG. 52.—A VERY LARGE SUBMUCOUS MYOMA WHICH HAD BEEN EXTRACTED FROM THE UTERUS.

B. Aut. No. 2987. The patient entered the hospital in a desperate condition. Operation was out of the question, and she died in a few days. During the interim the submucous myoma, which protruded slightly, was forced out of the vagina. The myomatous uterus still fills the pelvis, but the tumor projecting from the vulva and attached by a broad pedicle is larger than the uterus. This myoma had molded itself to the pelvis, otherwise it could not possibly have escaped through the vagina.

When the process advances still further, we find a grayish, offensive, tough, stringy tissue projecting from the vagina, as in Case 6143. Probably the most pronounced instance of this kind, in our experience, was No. 11889, described in detail on page 577. The patient was almost moribund. Her hemoglobin was 14 per cent.; the temperature was 104.2°. The myomatous uterus reached the umbilicus. Projecting from the dilated cervix was a grayish-white sloughing

The large submucous myoma in Case 6433 projected through the cervix and filled the vagina. It measured 8 x 10 x 11 cm., and was attached to the uterine wall by a pedicle 4 cm. in diameter. The myoma was covered with blood and fibrin and its surface consisted of a greenish pyogenic membrane.

The inflammatory process gradually extends to the underlying myomatous tissue and, if the submucous myoma has a broad basal attachment, portions of the tumor may be gradually sloughed off. In Fig. 51 we have a good illustration of such a condition. Filling the uterine cavity and intimately blended with the walls is a large submucous myoma. Its lower portion has undergone a good deal of disintegration and the center is already necrotic.

submucous myoma. The necrotic portion of the submucous myoma was removed, and the patient was in good health three years later.

It is astonishing what large myomata may be expelled through the vagina. In Fig. 52 the transverse diameter of the myoma is greater than the distance from the symphysis to the sacrum. The myoma was soft and flabby and had readily accommodated itself to the pelvis, again assuming its former shape as soon as it had emerged from the vagina.

In Fig. 53 we see the mottled appearance and the engorgement frequently noted in sloughing submucous nodules. The dark color is due to extravasation of blood, and many of the blood-vessels are dilated and filled with thrombi.

The sloughing submucous myoma in Case 6185 lay between the thighs, and at first suggested a prolapsed uterus. The growth, however, was dark brownish green in color and covered with a bloody, foul-smelling discharge. It measured 15 cm. in length and 8 cm. in diameter. The finger entered the vagina readily, and the pedicle of the tumor was found to spring from within the cervix on the left side.

The odor from a sloughing submucous myoma is often almost unbearable; even after the tumor has been in alcohol for years, the disagreeable smell clings to the hands for hours despite the most careful washing and the use of deodorants.

The vaginal discharge is likewise offensive. Its color naturally depends upon the abundance of polymorphonuclear leukocytes, the amount of disintegration, and the hemorrhage, being watery, dark brown, or greenish in hue.

(For sloughing subperitoneal and interstitial myomata see page 134.)

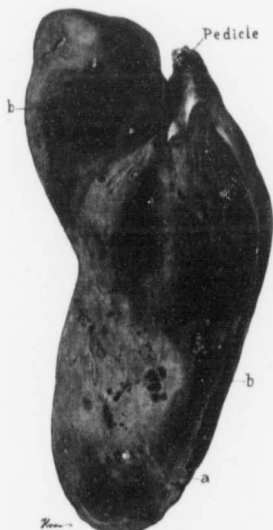

FIG. 53.—A SLOUGHING SUBMUCOUS MYOMA (1 nat. size.)

Gyn. No. 7313. Path. No. 3673. The myoma was 15 cm. long and varied from 3 to 5 cm. in diameter. Its lower end appeared gangrenous, and the tumor had a very foul odor. The picture represents a longitudinal section of the growth. The small pedicle is seen at the top. At *a* is a small polypoid projection of the myoma. The tumor presents a mottled appearance, and many of its blood-vessels are dilated (*b*). Histologic examination showed that the surface of the myoma was entirely necrotic.

The uterus was removed shortly afterward and sarcoma found (p. 195). The patient died of pulmonary metastases.

HISTOLOGIC APPEARANCES OF SLOUGHING SUBMUCOUS MYOMATA.

As the myoma is forced more and more into the uterine cavity, its pedicle naturally becomes more attenuated; and when the tumor is extruded into the vagina, it is more liable to become bruised, so that the likelihood of infection becomes greater. The breaking down of the tumor usually starts on the surface and gradually travels inward. The more prominent parts of the tumor

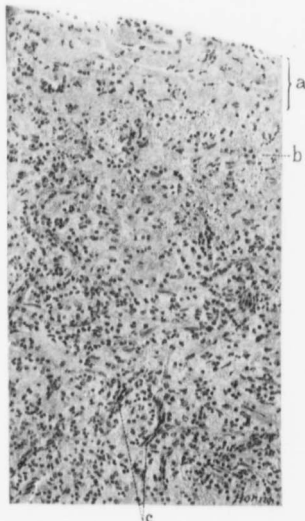


FIG. 54.—THE SURFACE OF A SLOUGHING SUBMUCOUS MYOMA. ($\times 170$ diam.)

Gyn. No. 6855. Path. No. 3177. *a* is the surface of the growth, consisting of tissue which is partly necrotic. It contains a few distorted polymorphonuclear leukocytes and small round cells. In the underlying tissue a few muscle-fibers are still visible, and there is much hemorrhage (*b*). In the depth are numerous capillaries (*c*). The tissue shows considerable small-round-celled and some polymorphonuclear infiltration.

and 3673), and Case 11889 (Path. No. 8297).

As the inflammation becomes more chronic the surface will be found covered with fibrin, polymorphonuclear leukocytes, and blood, while the underlying part consists essentially of granulation tissue (Fig. 56). The increased vascularity diminishes and the vessels may show organizing thrombi, as in Case 6185 (Path. No. 2441); or the vessels may be already obliterated, as in Case 7237.

may have a thin covering of mucosa, or this may have already entirely disappeared. First the tissue immediately beneath the surface shows some small-round-celled and polymorphonuclear infiltration (Fig. 54). Occasionally there may also be edema, as in Case 2593 (Path. No. 178). This, however, is uncommon, as the tumor is subjected to pressure from all sides. The number of polymorphonuclear leukocytes and small round cells rapidly increases, and the surface soon shows signs of disintegration. The tissue in the vicinity undergoes complete coagulation necrosis, the colorless fibers still being visible. Occasionally there is fragmentation of nuclei, as noted particularly in Cases 6143 (Path. No. 2413) and Gyn. No. 7237 (Path. No. 3491). The blood-vessels near the surface may be much dilated, as in Case 2732 (Path. No. 266) and Case 3066 (Path. No. 460). In the very foul sloughing growths the blood-vessels in the necrotic muscle may be filled with organisms (Fig. 55), as in Case 2732 (Path. No. 266), Case 4663 (Path. No. 1327), Case 5296 (Path. No. 1750), Case 7313 (Path. Nos. 3576

Occasionally a myoma that has already shown marked hyaline degeneration, as it becomes submucous, will disintegrate very rapidly without showing much

Necrotic surface

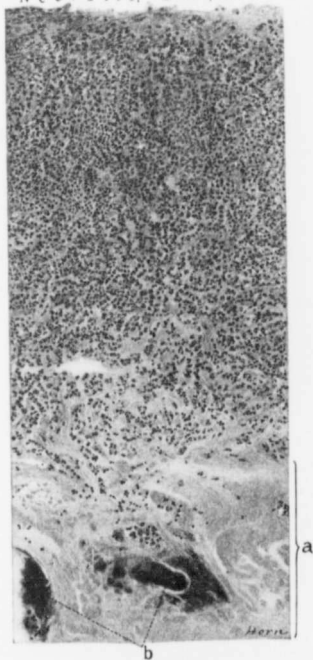


FIG. 55.—THE SUPERFICIAL PORTIONS OF A SLOUGHING SUBMUCOUS MYOMA. ($\times 140$ diam.)

Gyn. No. 7549. Path. No. 3799. The myoma was approximately 15 cm. in length, 9 cm. in breadth. The lower portion was sloughing, and projected through the cervix.

The surface is entirely necrotic; then comes a necrotic zone densely infiltrated with small round cells and polymorphonuclear leukocytes; beneath this the necrotic character of the tissue is clearly seen, as indicated by the area *a*. At *b* are blood-vessels almost completely choked with organisms.

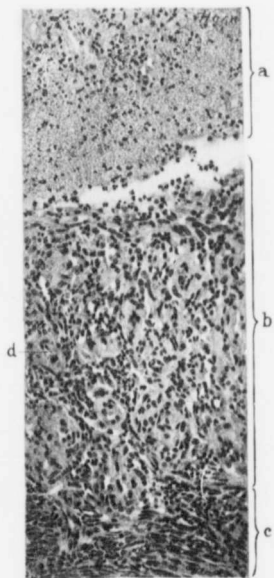


FIG. 56.—THE SURFACE OF A SLOUGHING SUBMUCOUS MYOMA. ($\times 150$ diam.)

Gyn. No. 7383. Path. No. 3635. The submucous myoma was 6 cm. long, 4 cm. broad. In protected places the mucosa was intact, but at some points had entirely disappeared.

At the surface is covered with fibrin containing blood and polymorphonuclear leukocytes in its meshes. The underlying tissue (*b*) consists of typical granulation tissue. Scattered throughout this are numerous capillaries (*d*). *c* is the unaltered underlying myomatous tissue.

inflammatory reaction. This was particularly noticeable in Case 7237 (Path. No. 3491).

A SAUSAGE-SHAPED SLOUGHING SUBMUCOUS MYOMA, THREE FEET IN LENGTH.

The accompanying case is unique, and demonstrates the amount of pressure that can be exerted by the uterine muscle. For five years the patient had been aware that a uterine tumor existed, but only toward the end of this period was there evidence of a submucous growth. With the rapid necrosis of the tumor a large portion of it was speedily expelled by the uterus, being molded in its exit by the cervix until it formed a sausage-like mass over three feet in length.

F. J. H., aged thirty-eight, colored, admitted to the Cambridge Hospital, Md., January 13, 1907. The patient had always been well and strong, but five years before had been told that she had an abdominal tumor. Three days before admission to the hospital she was seen by Dr. E. E. Wolff. She had at that time a temperature slightly over 101° F. A large nodular mass occupied the lower part of the abdomen and there was some abdominal tenderness. The foul vaginal discharge still continued. Filling the vagina was a rope-like structure over three feet in length. This was attached within the uterine cavity. On its lower end was a knob-like, lobulated mass, 3 x 5 inches. After the vagina had been cleaned up as thoroughly as possible the uterus was removed from above by Dr. Curtis Burnam.

After operation there was a good deal of vaginal discharge and some pelvic inflammation. The patient improved greatly and was ready to leave the hospital, when she suddenly dropped dead without any warning.

Path. No. 11044. The uterus measures approximately 8 x 9 x 10 cm. It is everywhere covered with dense adhesions. Projecting from the right lateral wall, but intimately connected with the fundus and filling the uterine cavity, is a necrotic looking, foul-smelling, grayish-black tumor mass. It appears to be a sloughing submucous myoma. On section, it is grayish or reddish-black in color and soft in consistency.

At one or two points small interstitial nodules are seen scattered throughout the uterine walls. Accompanying this specimen is a twisted rope of tissue, about three feet in length, grayish-black in color, and on section presenting the same appearance as the necrotic submucous myoma.

Histologic Examination.—Sections from the submucous myoma showed that it was undergoing necrosis and that there was marked suppuration. Where the tissue was preserved, it was rather cellular. Blood-vessels were numerous and markedly engorged. Cross-sections of the rope of tissue showed that it likewise consisted of myomatous tissue. In most places it had undergone almost complete necrosis. At a few points the necrotic muscle showed typical calcareous deposits.

We had in this case a submucous myoma, which had in part undergone necrosis and had been gradually extruded, forming a tumor three feet in length.

INVERSION OF THE UTERUS ASSOCIATED WITH SUBMUCOUS MYOMATA.

In our series of uterine myomata we have had four cases in which partial inversion of the uterus was noted and in each of these the myoma was submucous. When the uterus is the seat of a single tumor which becomes submucous and pedunculated and is being gradually extruded into the vagina, it is but natural that the traction of the pedicle on the uterine wall in a few cases will produce partial inversion of the uterus.

In Case 1716 the vagina was filled with a round, firm myomatous tumor, about 11 cm. in diameter, and attached in the uterine cavity by a pedicle 2.5 cm. in diameter. Bimanual examination revealed a slight cupping of the fundus.

The uterus in Case 7133 contained a submucous myoma. After the cervix had been split and the tumor divided into four pieces it was removed. The uterus was partially inverted on account of the traction of the myoma.

A smooth, glistening, pedunculated, submucous myoma protruded from the enlarged and edematous cervix in Case 1610; at the site of the fundus was a cup-shaped depression.

In Case 2873 the patient was very pale and had a very rapid pulse. A submucous myoma, 11 x 15 cm., protruded from the vulva. It was attached to the uterus by a pedicle 4.5 cm. in diameter. The fundus was nodular, about the size of that of a three months' pregnancy, and partially inverted.

After removal of the submucous growth the inversion, as a rule, can be readily rectified. The dangers of vaginal myomectomy or vaginal hysterectomy when partial inversion exists are considered on page 575.

CHAPTER V.

DILATATION OF THE UTERINE LYMPHATICS ASSOCIATED WITH MYOMATA.

For convenience two divisions may be made: (1) Dilatation of the superficial lymphatics; (2) dilatation of the deep lymphatics.

By the superficial lymphatics we mean those that are so near the surface that they are readily seen as soon as the abdomen is opened. Naturally, the condition of the deep lymphatics cannot, as a rule, be made out until the tumor is studied at leisure in the laboratory.

DILATATION OF THE SUPERFICIAL LYMPHATICS.

In the chapter on Parasitic Myomata two cases are mentioned in which the omentum furnished abundant nourishment to pedunculated myomata, and large lymph-channels coursed down the omentum to the tumors. In one of these cases (Gyn. No. 7220, Fig. 18, p. 22) a single large, tortuous, thin-walled lymphatic, several millimeters in diameter, is seen passing down the omentum to the tumor. In Case 3296 (Fig. 17, p. 20) several large, tortuous, pale lymphatic vessels are seen extending down from the omentum to the tumor.

Probably one of the most striking examples of a large lymphatic coursing over the surface of a myomatous uterus is found in Gyn. No. 13067 (Fig. 57). Emerging from the uterine muscle, several centimeters to the median side of the uterine horn, is a markedly lobulated and tortuous lymphatic vessel. This in places reaches over 1 cm. in diameter and rises nearly 1 cm. from the surface of the uterus. It passes downward and outward between the tube and ovary and is lost near the hilum of the ovary. Anterior to the tube is a much dilated lymphatic vessel.

Another remarkable example of dilatation of the lymphatics is furnished by Gyn. No. 11224 (Path. No. 7448). At the origin of the left tube, between the left tube and ovary and between the tube and the neighboring round ligament, were cystic spaces. They varied from 1 to 2 cm. in diameter and their muscular covering was so attenuated that their clear fluid contents were readily seen. Some of the spaces on section were found to be made up of numerous smaller ones. The spaces were filled with serous fluid. In sections they were lined in places with one layer of flat cells; at other points no endothelial lining could be detected. Similar spaces were present in the vicinity of the right uterine horn. In neither of these cases were there adhesions, which sometimes give rise to superficial, subperitoneal spaces—an encysted peritonitis.

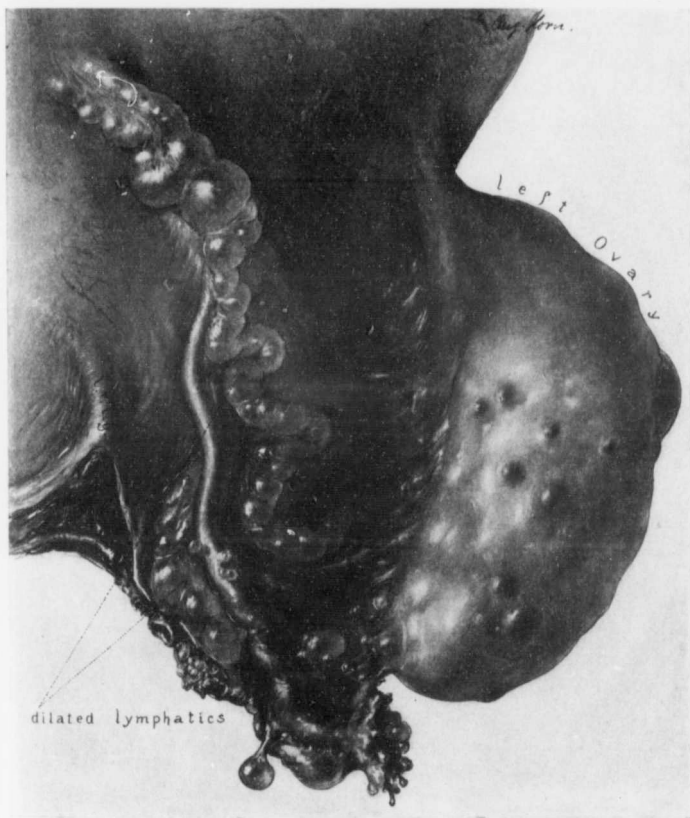


FIG. 57.—ENORMOUS DILATATION OF THE LYMPHATICS ON THE SURFACE OF A MYOMATOUS UTERUS. (Nat. size.)

Gyn. No. 13067. Path No. 10076. Emerging from the surface of the uterus, a few centimeters above and anterior to the left tube, is a tortuous lymphatic vessel which in places is over 1.5 cm. in diameter. It passes over the tube down between the tube and ovary and is lost in the depth, near the hilum of the ovary. This lymphatic vessel was filled with clear fluid. Anterior to the tube is a large lymphatic vessel. On the surface of the tube are a few subperitoneal spaces. The tumor is free from adhesions. The great increase in size of the ovary is due in a large measure to dilated lymphatics, in part, to many cystic follicles.

Gyn. No. 13067. Path. No. 10076.

Enormous dilatation of the superficial lymphatics and much edema of the left ovary, associated with a myomatous uterus (Fig. 57).

S. G., white, aged forty-one, married. Admitted July 9, 1906. Operation. Hysteromyomectomy. The specimen consists of a large myomatous uterus

with the appendages attached. The uterus is soft and boggy, and on section the increase in size is found to be caused by a large degenerated and cystic myoma, which arises from the posterior wall and is partly submucous. The right ovary is apparently normal. The left ovary measures 10 cm. in length, is correspondingly broad, and very soft and edematous. Emerging from the uterus just to the anterior and inner side of the left uterine horn is a markedly dilated and superficial lymphatic, which in places reaches nearly 2 cm. in diameter. It passes down behind the tube and is lost in the tissue between it and the ovary (Fig. 57). There are also dilated lymphatics between the left tube and the left round ligament.

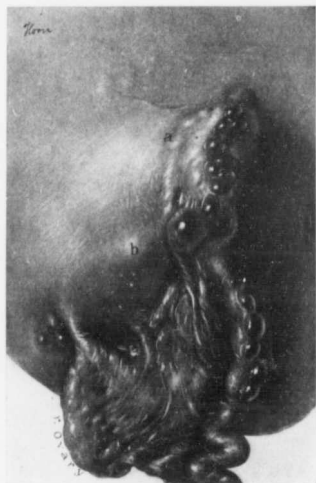

FIG. 58.—DILATED LYMPHATIC SPACES IN THE UTERINE WALL IN THE NEIGHBORHOOD OF THE RIGHT TUBE AND OVARY. (4 BRIT. SIZE.)

Gyn. No. 11224. Path. No. 7448. Covering the surface of a portion of the right tube are numerous subperitoneal cysts. At the cornu is a raised cystic area extending anteroposteriorly *a'* from *a* to *g*. This, on section, was found to be made up of numerous cystic spaces. *b* and *c* are other dilated cystic spaces in the uterine wall. All were filled with clear fluid. In many an endothelial lining could be made out.

Increase in size of the left ovary is due to marked dilatation of the lymphatics. These have given rise to the apparent edema noted macroscopically.

Gyn. No. 11224. Path. No. 7448.

A myomatous uterus with marked dilatation of the lymphatics in the region of both uterine horns (Figs. 58 and 59).

C. H., white, aged forty-six, married. Admitted April 25; discharged

May 22, 1904. Her family history is not good. Her mother died in diabetic coma; a paternal aunt also died of diabetes. Her father died of cardiac asthma, one brother of pericarditis, another brother of aneurysm, and a paternal aunt of tuberculosis. The patient has been married twenty-six years and has had two children, twenty-four and twenty-one years old respectively. Ten years ago she began to have slight bleeding between her periods. This has gradually increased, and the periods have also been getting longer and more profuse. For the last two or three years she has had considerable weakness, and has been bleeding almost continuously. One year ago her hemoglobin was 58 per cent.

Operation. Hysteromyomectomy. The highest post-operative temperature was 102.2°, on the fourth day.

Path. No. 7448.

The specimen consists of a roughly spheric myomatous uterus, 15 cm. in diameter. It is free from adhesions. The uterine cavity is much dilated. Just where the right tube joins the uterus is an oval-shaped swelling, 3 cm. x 1.5 cm. (Fig. 58). This is lobulated, covered with peritoneum and evidently cystic. It is composed of numerous smooth-walled spaces, varying from a pinhead to nearly 1 cm. in diameter. The walls are apparently composed of muscle. On the left side, near the point of origin of the left tube, there is a more diffuse swelling (Fig. 59). This measures 4.5 x 2.5 cm. and projects about 1 cm. from the surface. On section it also presents a honey-combed appearance. Between the inner end of the tube and the utero-ovarian ligament is an oval cyst, 4 cm. in diameter. It has thin walls and on section is found to consist of two main cysts and of numerous smaller ones.

On examination of the cystic area in the vicinity of the left uterine horn we

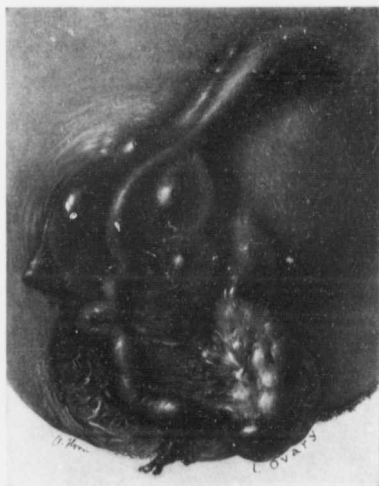

FIG. 59.—DILATED LYMPHATIC CHANNELS AT THE LEFT UTERINE HORN BETWEEN THE TUBE AND OVARY AND BETWEEN THE TUBE AND LEFT ROUND LIGAMENT. (1 nat. size.)

Gyn. No. 11224. Path. No. 7448. At the uterine horn is an elongate cystic dilatation, the anterior and posterior confines of which are indicated by *a* and *a'*. This, on section, was found to be composed of numerous smaller spaces. At the inner end of the utero-ovarian ligament is another cystic space, seen at *b*. Between the tube and ovary and between the tube and round ligament are other cystic spaces at *c*. Some of them had an endothelial lining; in others it could not be made out. They were filled with clear fluid.

find a cross-section of the tube slightly dilated. The uterine muscle surrounding this is perfectly normal. In the outlying portion the tissue is very edematous. The large spaces in places show no definite lining, but at other points have one layer of flat endothelium. The nuclei of the endothelial cells are spindle-shaped. The spaces are partially filled with a homogeneous material and take the eosin. We are undoubtedly dealing with dilated lymphatic spaces.

Sections from the cystic areas near the left utero-ovarian ligament and from the uterine horn on the right side show a similar picture.

DILATATION OF THE DEEP LYMPHATICS.

In Gyn. No. 3133 (Path. No. 494) the uterus, as the result of the myomatous development, had been converted into a pear-shaped tumor, 36 x 32 x 32 cm. The tumor, on section, presented a pearly-white, coarsely striated appearance and had scattered throughout it homogeneous areas, brownish in color. Microscopically, the uterine muscle itself showed much hyaline degeneration and in some places were small round or oval empty spaces which suggested lymph-spaces. Confirmatory of this idea were many channels of a similar shape, filled with hyaline material and lined with endothelium. Fully half of the large tumor had undergone hyaline degeneration, but there was no breaking down of the tumor substance. Its blood-supply was very poor. Surrounding nearly every blood-vessel were round or oval spaces, similar to those seen in the uterine muscle. These, from their arrangement, looked like lymph-spaces.

The lymph-spaces in the uterus in Case 4203 were markedly dilated. The uterus was 9 cm. in diameter and very soft.

In Gyn. No. 3113 (Path. No. 487) the uterus had been converted into a multinodular myomatous tumor, approximately 25 cm. in diameter. Large and small smooth-walled sinuses were scattered everywhere throughout the myomatous tissue. The largest of these was 1.2 cm. in diameter. Many of the larger communicated with the smaller ones. Most of them were filled with serous fluid and a few contained blood. On histologic examination the myomata showed much hyaline degeneration and some edema. The large sinuses that appeared to be lymph-channels in many places showed an endothelial lining; at other points no lining could be detected. As the blood in the arteries and veins had been well preserved in Mueller's fluid and as these spaces were comparatively free from blood, we are inclined to believe that they were lymph-vessels.

Unless careful histologic examinations are made one can never be sure that such spaces are lymphatics, as the majority of clear spaces found in myomata result from the melting away of the tissue following hyaline degeneration. This question is discussed fully in the chapter dealing with hyaline changes in uterine myomata (see p. 92).

CHAPTER VI.

TORSION OF THE UTERUS.

Torsion of the uterus is occasionally met with in myoma cases. It may, for convenience, be divided into—(1) torsion of the cervix; (2) torsion of the body of the uterus; and in addition we may have twisting of a pedunculated sub-peritoneal myoma.

TORSION OF THE CERVIX.

In Case 4925 we have an excellent example of torsion of the cervix. The globular myomatous uterus reached to within 8 cm. of the xiphoid. It was free from adhesions, but had rotated through an angle of 90 degrees to the right. The left round ligament, tube, and ovary, therefore, lay in front (Fig. 60). On referring to Fig. 61, it will be noted that the upper part of the cervix had been greatly thinned out. Whether this was the cause or the effect of the torsion it is impossible to accurately determine, but as the cervix was evidently put on the stretch by the ever-increasing upward growth of the tumor, there has, in all probability, been atrophy of the cervix, facilitating the torsion.

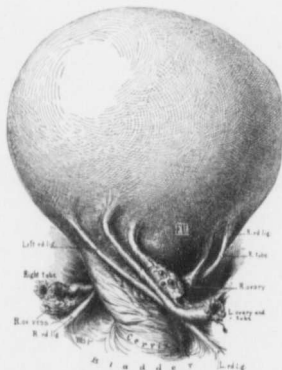


FIG. 60.—ROTATION OF A MYOMATOUS UTERUS ON ITS CERVIX.

Gyn. No. 4925. The globular myomatous uterus is perfectly smooth, but has rotated through an angle of 90 degrees to the right. The right appendages have been carried backward; the left round ligament, tube, and ovary lie just above the bladder. For the unfolded cervix see Fig. 61. A myoma, 12 x 21 x 27 cm., was removed *per abdomen*. For the subsequent development of other myomata see Fig. 331, p. 562. (After Howard A. Kelly.)

TORSION OF THE BODY OF THE UTERUS IN CASES OF UTERINE MYOMATA.

As this condition is comparatively rare, a brief description of the eight instances in our series may be of interest.

In Case 337 the lower abdomen was filled with a multinodular myomatous uterus. The uterus was twisted on its axis.

The irregularly globular myomatous uterus in Case 4314 was as large as that of a six and one half months' pregnancy. It was twisted through an angle of 90

degrees from left to right and the left ovary contained a unilocular cyst 8 cm. in diameter.

In Case 5644 a myoma, 12 x 12 cm., occupied the posterior uterine wall. There was torsion of the uterus through an angle of 90 degrees from right to left.

The myomatous uterus in Case 5784 filled the entire abdomen. The omentum was firmly attached to the tumor over its entire breadth and furnished enormous vessels to the myoma. The uterus had rotated through an angle of 180 degrees from right to left.

The abdomen in Case 5946 was filled with a symmetric and semifluctuant myomatous tumor. The uterus had rotated 90 degrees.

In Case 6570 the myomatous uterus reached the umbilicus. Its pedicle con-

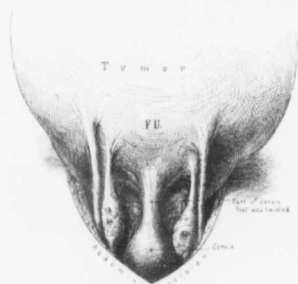


FIG. 61.—ATROPHY OF THE CERVIX ASSOCIATED WITH A LARGE GLOBULAR MYOMATOUS UTERUS.

Gyn. No. 4925. The upper part of the cervix is greatly attenuated, and at operation the uterus was rotated to the right, giving the picture seen in Fig. 60. (After Howard A. Kelly.)

sisted of the middle portion of the uterus. Here there was a definite twist from right to left. The portion of the uterus forming the pedicle had become markedly attenuated, being only 1 cm. in thickness (Fig. 62).

In Case 7695 the myomatous uterus reached the umbilicus. The cervix had made a quarter turn from left to right, the left tube and ovary lying in front. The twist was near the cervix.

In Case 11067 the abdomen was symmetrically distended. There had been definite torsion of the uterus from left to right (Fig. 63).

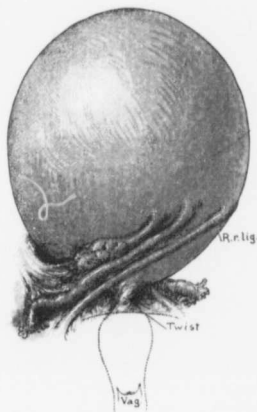


FIG. 62.—MARKED TORSION OF A MYOMATOUS UTERUS.

Gyn. No. 6570. The great enlargement in the upper part of the uterus was caused by a spheric myoma. Near the middle of the uterus proper there is marked torsion from right to left—so much so that the insertion of the right round ligament is carried to the opposite side, while the right tube and ovary lie in the median line. At the point of the twist the diameter of the uterus had been reduced to 1 cm.

In none of these cases had the torsion given rise to any especial clinical symptoms. While it is impossible to tell definitely why torsion took place, it seems probable that the twisting commenced as a result of the attempts of the tumor to accommodate itself to its surroundings. When once twisting starts it often, for some unknown reason, tends to increase in degree.

TORSION OF THE UTERUS WITH COMPLETE SEVERANCE OF THE BODY FROM THE CERVIX.

Professor Raffaele Bastianelli, of Rome, when in Baltimore, related a most interesting case of this character that had come under his observation, and on

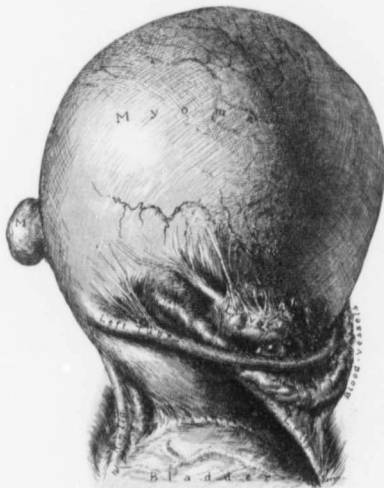

FIG. 63.—TORSION OF A LARGE GLOBULAR MYOMATOUS UTERUS.

Gyn. No. 11067. Path. No. 7285. There is marked torsion of the uterus from left to right, so that the insertions of the left tube and ovary lie in front. The lower surface of the left ovary has become firmly plastered on to the surface of the myomatous uterus. The blood-vessels lying between the tube and ovary are much dilated.

his return to Italy he sent us an explanatory illustration (Fig. 64). In the beginning there was evidently torsion of the uterus. This gradually became more marked until finally the fundus was completely severed from the cervix.

Miss E. J. C., aged fifty-three, seen by Dr. Bastianelli in Rome in 1902. The patient menstruated last eight years previously. For more than twenty-one years a tumor has been noticed in the lower abdomen. This at first was not painful, but in 1881, for one day, she had severe pain throughout the entire

abdomen. In 1890 she had what was supposed to be a severe attack of peritonitis, which lasted more than eight days and was accompanied with moderate fever. In 1895 she had another attack, and two or three others at later intervals. In 1901, after exercise, she had severe abdominal pain for three days and since then, on numerous occasions, has had much abdominal discomfort after exercise. In March, 1902, she had sudden pain during the night. There was little vomiting, some diarrhea, and abdominal distention. She was in bed for a month and suffered a good deal. From that time until the day of operation she has had numerous other attacks of abdominal pain.

May 25, 1902: Occupying the lower abdomen, and extending almost to the umbilicus, is a tumor about the size of a child's head, hard, immovable, rather

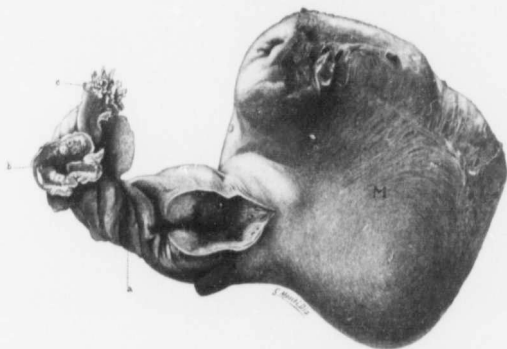


FIG. 64.—SPONTANEOUS AMPUTATION OF A MYOMATOUS UTERUS. ($\frac{1}{2}$ nat. size.)

Illustration sent by Professor R. Bastianelli, of Rome. To the right is a large myoma which had grown fast to the abdominal wall. Toward the left is the small uterine cavity, which has been opened. At *a* is a twisted pedicle consisting of the broad ligament, round ligament, and the tubes and ovaries much atrophied. *c* is the fimbriated end of one of the tubes. The torsion had resulted in complete separation of the uterus from the cervix.

painful, and situated somewhat to the left. On rectal examination the cervix is easily felt. No connection can be made out between the tumor and the cervix.

May 26: On section of the abdomen a myoma was found. This was round, adherent to the abdominal wall on the left side, and was separated with difficulty. The tumor was then freely movable, and was found to be attached to the floor of the right iliac fossa by a large pedicle. This was cut between clamps and the tumor then lay perfectly free in the hands of the operator.

The specimen consists of the body of the uterus, with a round myoma attached to its anterior wall, and also includes both ovaries and tubes and round ligaments twisted many times. In the picture (Fig. 64) one can see easily the cavity of the uterus which has been opened. It is small and has an atrophic mucosa. It ends in the twisted pedicle. Attached to the uterus are the tubes and ovaries.

Professor Bastianelli gives the following explanation of the condition. The body of the uterus was twisted first, and little by little completely severed from the cervix. Then the tubes and broad ligaments became twisted, and finally the tumor became adherent to the abdominal wall. The condition, then, represents a spontaneous supravaginal amputation of the uterus, with secondary twisting of the tubes and the ligaments. Professor Bastianelli thinks that if the uterus had not been removed the twisting of the tubes and ligaments could have advanced still further. The uterus would then have been completely separated from them, and would have remained attached to the parietal peritoneum like a parasitic myoma.

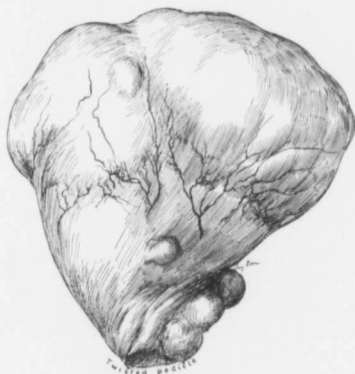

FIG. 65.—TORSION OF A SUBPERITONEAL PEDUNCULATED MYOMA. ($\frac{1}{3}$ nat. size.)

C. H. I. (C), August 12, 1902. The specimen consists of an irregular, fan-shaped, subperitoneal pedunculated myoma. At the pedicle the tumor has twisted from right to left. Near the center of the tumor many vessels are ramifying over its surface.

Torsion of Subperitoneal Myomata.—In Case C. the patient was admitted to the Church Home and Infirmary August 12, 1902. She had a small multinodular uterus and a large subperitoneal pedunculated nodule, which had become twisted through an angle of 90 degrees from right to left (Fig. 65) and was densely adherent to the tissues at the pelvic brim. The pedicle was severed, and the adhesions dealt with from the under side. The uterus was then removed.

In Case 12709, a colored woman, aged forty-two, had complained of sudden cramp-like pains in the right lower abdomen six days before. There was marked dysuria and a moderate elevation in temperature.

On her admission to the hospital Dr. H. T. Hutebins found the lower abdomen tender and detected an indefinite mass in the left iliac fossa. There was a

moderate leukorrhical discharge. The cervix was low down, and the uterus in ante-position and fixed. On both sides were what appeared to be definite tubo-ovarian masses, which were tender.

When the abdomen was opened a myoma, 4.5 x 5 x 8 cm., immediately presented. This was pedunculated, and had made one complete twist, so that the blood-supply had been entirely shut off (Fig. 66). The tumor was of a dark,

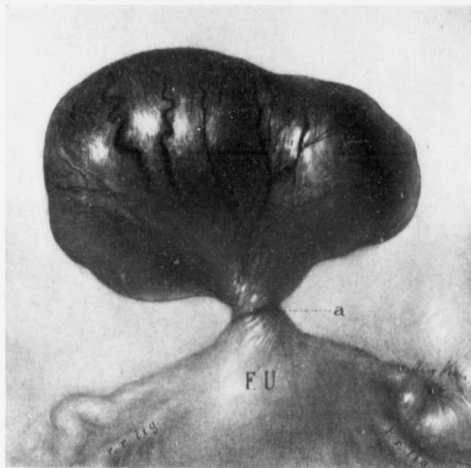


FIG. 66.—SUDDEN TORSION OF A SUBPERITONEAL PEDUNCULATED MYOMA WITH COMPLETE SHUTTING OFF OF ITS BLOOD-SUPPLY.

GYN. No. 12709. Path. No. 9545. The uterus was relatively normal in size. The right appendages were densely adherent. The left tube was dilated, as seen in the drawing, and the ovary contained a cyst.

Attached to the fundus is a subperitoneal pedunculated myoma. This is very dark in color, and its vessels are much dilated, owing to one complete turn of the myoma on its pedicle. The twist is clearly seen at *a*.

reddish-green color, but had not as yet undergone necrosis. The omentum was lightly adherent over its surface. The right appendages were densely adherent. The left ovary contained a cyst, 7 cm. in diameter.

The uterus was removed and the cyst evacuated. The temperature reached 102° F. on the second day, but recovery was speedy.

Path. No. 9545. Sections from the tumor showed that the blood-vessels just beneath the capsule of the strangulated subperitoneal myoma were very much dilated and the myomatous tissue itself had undergone slight cystic change. Had this patient not been promptly operated upon gangrene of the strangulated tumor would have soon taken place and peritonitis followed.

Torsion of the pedicle was also noted in Cases 4485 and 7220.

CHAPTER VII.

HYALINE AND CYSTIC DEGENERATION.

HYALINE DEGENERATION OF UTERINE MYOMATA.

The majority of myomata show either gross or histologic pictures indicative of hyaline degeneration. In order to exclude absolutely the presence of hyaline changes it is, of course, necessary to carefully cut each myoma and also to make slides from innumerable portions of each tumor. In our consideration of the subject we have dealt with only those tumors in which the degeneration was readily recognized. In 114 of our cases early or advanced changes were easily detected.*

A thorough knowledge of the early literature on the subject can be obtained from a study of the comprehensive article on Fibromata and Cystofibromata of the Ovary by H. C. Coe.† Although published more than twenty-five years ago, it deals with the subject of degeneration of solid ovarian and uterine tumors in a clear and succinct manner and is written in a very attractive style.

A careful study of the subject has led us to classify hyaline degeneration of uterine myomata according to the following stages:

* LIST OF CASES OF HYALINE AND CYSTIC MYOMATA.

Gyn. No.	Gyn. No.	Gyn. No.	Gyn. No.	
659	3345	4193	11806	San. 1682
1628	3349	4293	11944	
1672	3385	4415	11984	San. 1868
1909	3394	4441	11989	San. 1924
2606	3408	4485	12139	San. 1925
2672	3437	4635	12185	San. 1973
2691	3440	4828	12225	F. Aug. 10, 1902.
2699	3445	4869	12234	C. H. I. 620
2718	3449	4894	12423	C. H. I. 664
2746	3461	5021	12439	C. H. I. 796
2772	3475	5058	12453	C. H. I. 1019
2777	3485	5141	12488	C. H. I. 1296
2852	3488	5325	12522	
2881	3491	5766	12591	
3038	3493	6002	12696	
3066	3498	6272	12738	
3107	3504½	6432	12779	
3113	3552	7049	12839	
3130	3522	7220	12841	
3199	3661	7511	12849	
3216			12864	
3218	3882	8882	12877	
3232	3960	9030	13423	
	3971	9118	13625	
3296	3991	9924	H. A. K. Feb. 22, 1896.	
3320		10438	San. 941	
3338	4172	11461	San. 1011	

Had all of our cases been carefully examined, the number would have been materially increased.

† Amer. Jour. of Obstetrics, 1882, vol. xv, p. 561.

1. Early hyaline changes recognizable only with the microscope.
 2. Hyaline areas recognizable macroscopically.
 3. Advanced hyaline degeneration with liquefaction and the formation of small cysts.
 4. Hyaline degeneration with the formation of large cysts in the myomata.
- Naturally one stage gradually merges into the succeeding one.




FIG. 67.—ABRUPT TRANSFORMATION OF MYOMATOUS INTO HYALINE TISSUE. ($\times 210$ diameters.)

Gyn. No. 3107. Path. No. 472. In the left upper corner at *a* is typical myomatous tissue, but the greater part of the field, as indicated by *b*, has undergone hyaline degeneration. This can be termed massive hyaline degeneration, the muscle fibers ending abruptly and being almost entirely replaced by hyaline tissue. In a few places colorless fibers of connective tissue are still in evidence. The majority of the free cells, as indicated by *c*, belong to the endothelium of the delicate capillaries. A few polymorphonuclear leukocytes are seen in the hyaline material.

Early Hyaline Changes Recognizable only with the Microscope.*—Only rarely have we made a thorough examination of a myoma without finding areas of hyaline changes. This degeneration is most easily recognized when the specimen is stained with hematoxylin and eosin. The hyaline tissue takes the eosin stain, and is usually recognized as a homogeneous tissue devoid of nuclei. The degeneration may be scattered in patches throughout the field, but is generally sharply

* The following cases showed early histologic changes: 2606, 2672, 2691, 2699, 2746, 3107, 3218, 3338, 3385, 3408, 3437, 3493, 3552, 4441, 6002, 11984, 12139, 12185, 12225, 12423, 12439, 12453, and 12849.

circumscribed, as is well seen in Fig. 67. Here the muscle ends abruptly and is replaced by hyaline tissue, with here and there a muscle-fiber or an endothelial cell of a capillary still persisting. In other sections little masses of muscle-fibers still survive as islands in the sea of hyaline tissue. This was noted in Cases 2772 and 3349. Although the hyaline degeneration occurs frequently *en masse*, it may show a predilection for the muscle-bundles, as in Fig. 68. In this picture, although the stroma between the muscle-bundles shows hyaline degeneration, the muscle-bundles themselves show the most striking change, one

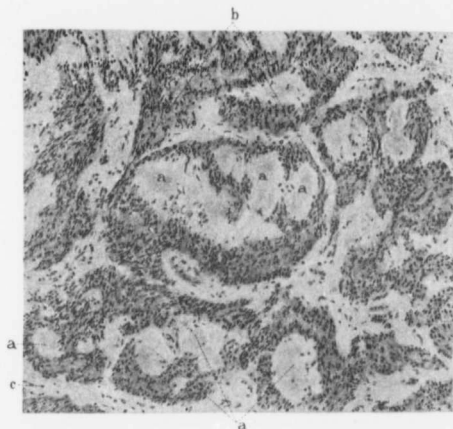


FIG. 68.—FOCAL HYALINE DEGENERATION IN MUSCLE-BUNDLES. (X120 diam.)

Gyn. No. 6002. Path. No. 2275. The tumor was a submucous myoma about 11 cm. in diameter. One is instantly impressed with the small, delicate, discrete areas of hyaline degeneration indicated by *a, a*. This is particularly well seen in the muscle-bundle indicated by *b*, nearly half of which has been converted into hyaline material. The fibrous stroma (*c*) has also undergone some hyaline change. Such a distribution of the hyaline degeneration is most unusual.

bundle containing at least five or six large foci of hyaline degeneration. The picture presented in Fig. 68 is a most unusual one.

The blood-supply in the hyaline area is usually very limited, but the surrounding tissue is often liberally studded with blood-vessels and occasionally there have been hemorrhages into the degenerated tissue.

In a few cases, as in Gyn. Nos. 2772, 3066, 3216, 12877, San. No. 1925, C. H. I. No. 1019, the hyaline degeneration is very pronounced around the blood-vessels. The vessels are usually small and, as shown in Fig. 69, the endothelium of the capillary still persists, but the vessel-walls and the surrounding tissue have been

entirely converted into hyaline material. In only two cases (Nos. 3445 and 3488) did we find any small-round-celled infiltration.

Hyaline Areas Recognized Macroscopically.—Usually such changes are not detected until the specimen has been cut open. They may occur in sub-peritoneal, interstitial, or submucous myomata, and may be limited to one nodule or be present simultaneously in several myomata.

Necrosis was noted macroscopically in cases 2881, 3199, 3296, 3991, 7511, 11461, and 12738.

Some of the tumors, on palpation, are firm and differ in no way from an ordinary myoma. Others are soft and succulent and occasionally the tumor may give a soft, elusive feel, suggesting a lipoma, as was the case in No. 3294.

On cross-section the area of degeneration is usually sharply defined and is whitish yellow in color. In such an area the muscle striation is usually still clearly recognizable. In Fig. 70 we have a very good example of the sharp differentiation from the surrounding myomatous tissue. The center has undergone degeneration. The fibrous arrangement, although somewhat altered, is still

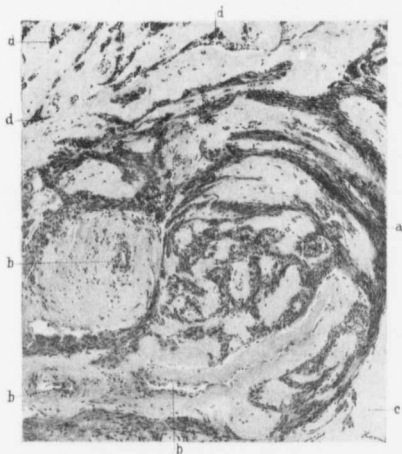

FIG. 69.—MARKED HYALINE DEGENERATION OF THE WALLS OF THE BLOOD-VESSELS IN A MYOMA. (X65 diam.)

Gyn. No. 3216, Path. No. 534. At *a* is the typical myomatous tissue. *b, b, b* are transverse and longitudinal sections of blood-vessels surrounded by a broad zone of hyaline material. All that remains of the normal vessel-wall is the endothelial lining. At *c* the myomatous tissue has undergone complete hyaline degeneration. The upper part of the field has been converted almost entirely into hyaline tissue. The muscle-fibers that remain are gathered into little bunches that stain very deeply at *d, d, d*. They are being gradually crushed out of existence, owing to pressure exerted by a rapidly enlarging abscess in the center of the myoma.

recognized, and in this case the degenerated area is separated from the surrounding myomatous tissue by a zone of hyaline tissue from which all trace of the fibers has disappeared. Fig. 73 (p. 93) represents the extreme hyaline degeneration that may occur in a subperitoneal myoma. Fully three-quarters of the tumor has undergone hyaline transformation and the junction between the unaltered myomatous tissue and the area of degeneration could hardly be sharper. The area of degeneration is in the part furthest from the blood-supply.

The area of hyaline degeneration is usually whitish yellow in color, but occasionally we have seen it yellow,—bright yellow suggesting fat,—grayish blue, grayish red, yellowish brown, pink, dark red, or a reddish blue.

Histologic examination shows that the hyaline areas are almost totally devoid of cell elements. Here and there, however, a few muscle-fibers are still present.

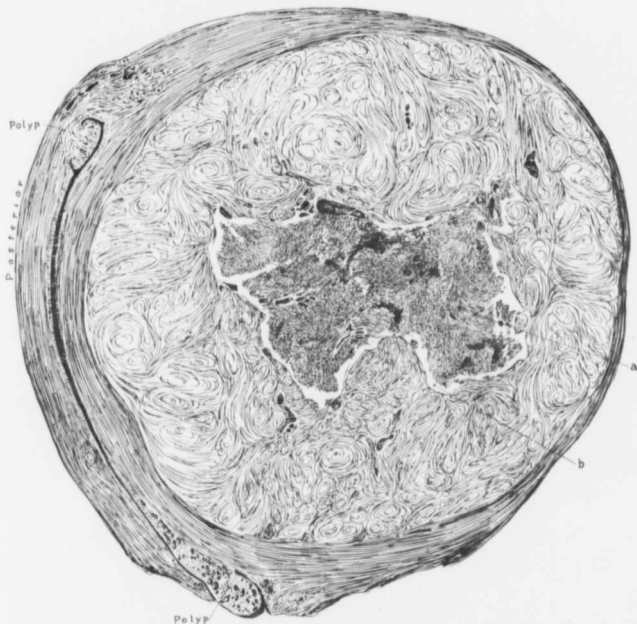


FIG. 70.—HYALINE DEGENERATION IN THE CENTER OF AN INTERSTITIAL MYOMA. ($\frac{1}{4}$ nat. size.)

San. No. 941, Path. No. 4113. The uterine cavity is considerably elongated; situated in the fundus and cervix are polypi. Occupying the anterior wall is an interstitial myoma about 15 cm. in diameter. The center of this (a) has partially disintegrated. Separating this degenerated area from the ordinary myomatous tissue is a ribbon of hyaline material (b).

The bright yellow areas, as a rule, represent a simple hyaline degeneration, but occasionally the color is due to the large deposit of yellow pigment, the result of old hemorrhage.

Where the areas are dark in color, varying amounts of coagulation necrosis are usually present. Here the tissue has undergone complete death. The out-

lines of the muscle-fibers and of the intervening connective tissue still persist. The stain with hematoxylin and eosin is faint and rather indistinct and fragments of nuclei are found. In a few instances a slight degree of infiltration with polymorphonuclear leukocytes can be noted.

Advanced Hyaline Degeneration with Liquefaction and the Formation of Small Cysts.—The gradual merging of the hyaline myomatous tissue presents

the most delicate and beautiful macroscopic and microscopic pictures and is readily followed in nearly all the cases in which the myomata contain cystic spaces.

E d e m a .—Before describing liquefaction in myomata we will briefly refer to those cases in which edema is present. On palpation such a uterus, after its removal, often gives a sensation as if it were fluctuant or semi-fluctuant and at times is so soft that the pathologist may suspect a pregnancy if the uterus is symmetrically enlarged. So suspicious have we been on several occasions that we hesitated to cut into the specimen fearing that the operator had by mistake removed a normal pregnant uterus.

On section, the myoma presents the usual appearance, save for the fact that

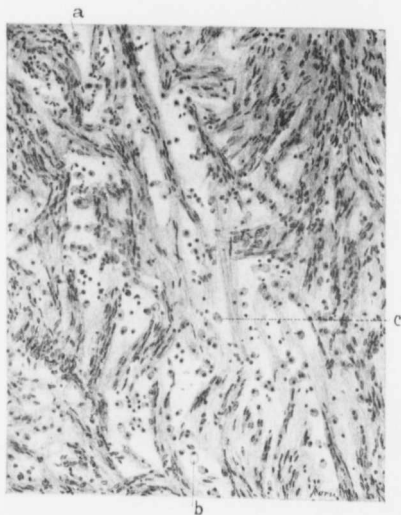


FIG. 71.—EDEMA OF A MYOMA. (X 120 diam.)

Gyn. No. 11989. Path. No. 8445. The entire picture presents a loose appearance, in contrast to the compactness of an ordinary myoma. At *a* is a cross-section of a swollen muscle-fiber. At *b* is a fiber that has imbibed considerable fluid and the nucleus has been pushed to the side of the cell. At *c* are two muscle-fibers which have apparently lost their nuclei. In the transverse sections the swollen muscle-fibers bear a striking resemblance to the exfoliated tubal epithelium found in a hydrosalpinx. The apparently empty spaces are filled with a serum of sufficient density to coagulate *en masse* instead of becoming granular.

it is very juicy and from the cut surface much serum runs off. This edema is usually associated with hyaline degeneration, but may occur at points where none exists.

Histologically, the usual picture of edema is found (Fig. 71). The muscle-bundles, and in some instances the muscle-fibers, are separated from one another by serum, recognized in the section as flocculent or granular material which takes

the eosin stain faintly. Lying in this serum are isolated muscle-fibers cut either transversely or longitudinally. These are much swollen and on cross-section remind one of the swollen exfoliated epithelium often found in a hydrosalpinx. Evidently, as a result of maceration, some of the muscle-fibers have lost their nuclei.

Liquefaction of the Hyaline Tissue with Cyst Formation.—On section, the myoma contains one or more translucent areas, which remind one of an apple containing a "water core." Such areas are well seen in Fig. 74 (p. 95). As the degeneration advances portions of these translucent areas become transparent and are seen to be filled with clear, serous-like fluid. Traversing them are delicate trabeculae. With the continued degeneration the areas containing clear fluid increase and one area may merge gradually into another. Thus in one myoma we may have the ordinary myomatous tissue, translucent areas, filled with clear fluid, and the definite cystic spaces.

This form of degeneration occurs rarely in submucous myomata, more commonly in interstitial nodules, and most frequently in subperitoneal tumors. It may be limited to a small area, as in Fig. 75 (p. 96), or involve nearly half the tumor, as in Fig. 76 (p. 98); or it may be scattered throughout the entire tumor (Fig. 116, p. 160). In Fig. 79 (p. 101) large and small cystic spaces are scattered everywhere throughout the tumor and divided into smaller spaces by trabeculae. Occasionally the tumor may undergo almost complete cystic transformation, as seen in Fig. 81 (p. 102), in which a portion of the tumor was like a ball of jelly having delicate trabeculae running through and dividing it into large and small compartments.

The cyst fluid is usually straw-colored, limpid, and trickles away from the cut surface. In most cases it coagulates on exposure to the air, but occasionally remains liquid.

Histologic Appearances of Myomata Undergoing Liquefaction.—In Fig. 67 (p. 84) we have a good example of diffuse and sharply defined hyaline degeneration. After a time this hyaline tissue undergoes

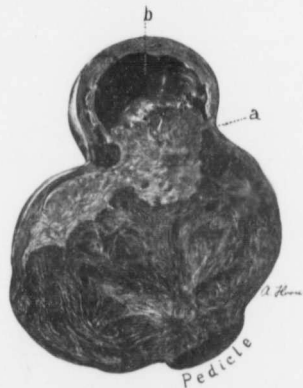

FIG. 72.—HYALINE DEGENERATION WITH CYSTIC FORMATION IN A SMALL SUBPERITONEAL PEDUNCULATED MYOMA. (Nat. size.)

Gyn. No. 4415. Path. No. 1207. The upper part of the myoma has undergone typical hyaline degeneration, as seen at *a*; at *b* this has gone on to cyst formation. Covering the outer surface of the cyst is a well-marked zone of myomatous tissue. It will be noted that the degeneration is at a point most remote from the source of blood-supply.

softening. The softening reminds one very much of the uneven melting of a large sea of ice on a hot spring day. In some places it is still dense, in others fairly thick yet rarefied; and where the heat has been most intense, the ice has almost disappeared. In the hyaline areas the tissue at first takes the eosin stain uniformly. A little later there are certain areas where the eosin stain has faded, owing to the thinning out of the hyaline. Still later the hyaline has entirely disappeared in the rarefied areas, leaving them threadbare, so to speak, and showing the fibrillary arrangement of the remaining fibrous tissue; and finally there remain spaces filled with a fine granular deposit—coagulated serum.

Some of these spaces are traversed by minute trabeculae consisting of minute capillaries, just sufficiently wide to allow one red blood-corpuscle to pass at a time.

In Fig. 82 (p. 103) can be seen extensive hyaline degeneration, although in places the muscle-bundles and individual muscle-fibers are still preserved. Nearly all the hyaline material has vanished, only the fibrillated connective tissue remaining, and at *f* even this has disappeared, nothing but liquid being left. Fig. 83 (p. 104) is even more instructive. A few muscle-fibers and bundles still persist; the majority of the muscle-bundles have been converted into hyaline tissue. They stain with eosin, stand out sharply, and are easily differentiated from the stroma, which has also undergone hyaline degeneration. In the center of the field the tissue has completely melted away and we have an irregular cavity filled with coagulated serum, recognized as granular material.

Probably the most instructive picture in the series is Fig. 84 (p. 106). It is from a degenerated myoma noted during pregnancy. In the upper part of the field are a few bundles of swollen muscle-fibers. The greater part of the picture consists of hyaline material that has undergone liquefaction. The darker areas indicate the amount of albumin held in the solution and all gradations in density can be traced until we have areas in which the fluid contains practically no albumin and the spaces are almost colorless. This process* of liquefaction gradually advances until we have numerous small cysts, limited to one portion or, as is frequently the case, scattered throughout various portions of the tumor.

Hyaline Degeneration with the Formation of Large Cysts in the Myomata.—From the preceding pages we have seen that the hyaline areas in the myomata gradually undergo liquefaction and that small cyst-like spaces are developed. It has further been noted that these are not true cyst spaces, as they are merely the reservoirs of the broken-down tissue and their walls are composed of ragged hyaline tissue. Naturally, such cavity formations have neither an epithelial nor an endothelial lining.

With the gradual disintegration of the tumor it is only natural that the cystic

* In the following cases small cyst-like spaces were noted in the degenerated myomata: Nos. 2718, 3107, 3113, 3488, 3498, 3622, 3661, 3882, 3977, 3991, 4172, 4415, 4635, 4894, 5021, 5058, 5141, 5325, 6272, 7511, 9924, 10573, 11806, 12194, 12779, 12864, C. H. I. Peth., San. 1011, San. 1924, C. H. I. W., C. H. I. 1019

spaces should increase in size, first by the gradual crumbling down of their own walls and, secondly, by the merging into them of other cystic spaces, the process in so far being analogous to that which occurs in a multilocular ovarian cyst.

In Fig. 85 (p. 107) we have an excellent example of an interstitial myoma that has been converted into one large cavity and has trabeculae extending from side to side. Its walls were composed of friable hyaline tissue. It was filled with a clear serous fluid.

The myoma in Fig. 86 (p. 109) measured 23 x 25 x 31 cm. It had been converted into one large cavity, the walls being composed of shaggy tissue, and contained a central core of shaggy tissue held in place by trabeculae extending to the cyst-walls. The core and the trabeculae represented the more resistant portions of the tumor which had not gone on to liquefaction. The cavity was filled with a turbid, greenish-brown fluid.

In Fig. 87 (p. 110) the process has gone on more slowly, there being large and small cyst spaces and much tissue that has undergone only partial disorganization.

In Fig. 89 (p. 113) we have a large subperitoneal myoma that presents a honey-combed appearance and also contains several large cystic cavities. Were the uterus hidden and the outer muscular covering obscured, the tumor might readily be mistaken for a multilocular ovarian cyst.

The cystic tumor seen in Fig. 90 (p. 114) is evidently an old one. The hyaline tissue to a great extent has become liquefied, and there have been numerous secondary cavities, as indicated by the trabeculae which carry blood-vessels (Fig. 91, p. 115).

The multilocular cystic tumor noted in Fig. 92 (p. 117) is a most unusual one and, looking at it casually, one could very readily mistake it for an ovarian cyst.

These tumors* may reach very large proportions. In No. 13625 the myomatous uterus weighed 39 pounds, the greater part of the tumor being made up of one cyst (Fig. 93, p. 119). With the abdomen open we at first felt sure that we were dealing with an ovarian cyst, and it was only when we reached the pedicle that the true nature of the mass was determined. Our largest cystic myoma weighed 89 pounds. It is described in detail on p. 512.

F l u i d .—The cyst fluid is usually straw-colored. In the smaller cysts it usually coagulates on exposure to the air, but in the larger ones often remains liquid. In No. 7049 the fluid was turbid and greenish brown in color. With the disintegration of the tumor there may be hemorrhage into the cavity, and then the fluid is red, reddish brown, or chocolate-colored, according to the length of time that has elapsed since the bleeding. In No. 12234 the cavity was filled with pale clots.

The cystic myoma represented in Fig. 96 (p. 122) is a most unusual one and

* In the following cases hyaline degeneration and large cystic spaces were noted: Nos. 659, 1628, 1672, 1909, 3440, 3445, 3523, 3960, 4485, 4828, 6432, 7049, 8882, 9118, 10461, 12234, 12488, 13423, 13625, San. 1925, C. H. I. F., C. H. I. 1296.

bears a striking resemblance to the interior of a heart. It was lined with myomatous muscle, had no endothelial lining, and was filled with a clear fluid.

On histologic examination we have found that nearly all these cystic spaces are lined with hyaline material. This occasionally bears evidence of an old hemorrhage, as is indicated by the yellow pigment in San. No. 1925 and by the deposit of brown granular pigment in No. 3960.

Cause of Cystic Degeneration of Myomata.—In the vast majority of the cases the hyaline degeneration is the primary factor. Dilatation of the lymphatics, however, may occasionally be partly responsible for some of the cystic spaces, as indicated by the two following cases:

In No. 3113 a tumor, 25 cm. in diameter, had sprung from the posterior wall of the uterus. On section, it was whitish in color, and presented a finely striated appearance. Scattered everywhere throughout the tumor were sinuses, the largest being 1.2 cm. in diameter. These sinuses had smooth walls and communicated with numerous smaller ones. On histologic examination the tumor was found to be edematous in places. Some of the large and small spaces had an endothelial lining. In others no lining could be found. As the blood in the arteries and veins had been well preserved in Müller's fluid, and since these spaces were comparatively free from blood, we were inclined to believe that they were lymph-channels.

In No. 4828 a cystic myoma, 27 cm. in diameter, had sprung from the uterus. There was one large cyst and numerous smaller ones. On histologic examination the cystic spaces were found to be due in part to liquefaction, but others were evidently dilated lymph-spaces, as proved by the lining, which consisted of one layer of endothelium.

Hyaline Degeneration of Myomata with Emulsified Fat in the Cystic Areas.—Almost constantly we find that liquefaction of hyaline material yields spaces filled with a clear yellowish fluid, but in two instances the resultant cavities have contained a material resembling melted butter. In No. 2852 the posterior wall was occupied by a myoma, 12 cm. in diameter. This contained two cavities, one measuring 2 x 2.5 cm., the second 4.5 x 5 x 6 cm. (Fig. 98, p. 124). Both of these spaces had convoluted and smooth walls and were lined with a smooth, butter-like material, which was semisolid; both cavities were filled with a liquid which closely resembled melted butter. Histologic examination showed that the myoma had undergone moderate hyaline degeneration and that the walls of the cavities were composed of hyaline material.

Immediate examination of the fluid from the cavities showed that it contained many cholesterol crystals, large round cells filled with fat-globules, and many muscle-fibers containing fat-droplets. There was much granular detritus. In this case there had been first a hyaline degeneration and then emulsification, or, in other words, fatty degeneration with liquefaction of the hyaline material.

In No. 3475 a nodule, 4.5 cm. in diameter, springing from the right side of the uterus, contained a soft, friable central portion of the consistence of cascain. On

histologic examination nearly the entire tumor was found to be necrotic. The creamy material from the center of the myoma was composed of elongate cells partly filled with fat-droplets. There was much free fat and here and there masses of cholesterol crystals. The changes in this case were analogous to those noted in the preceding one.

Relation of Hyaline Degeneration to Sarcoma.—Hyaline degeneration certainly seems to favor the development of sarcoma. The cells that resist the hyaline change lie free in the hyaline tissue or in the serous fluid and occasionally take on active development. This subject is discussed in detail in the chapter on Sarcomatous Transformation of Myomata (p. 175).

DETAILED REPORT OF CASES SHOWING THE VARIOUS TYPES OF HYALINE DEGENERATION.

In our brief description it has been impossible to describe in detail the various degenerative changes. We, therefore, give *in extenso* the more characteristic cases which portray accurately the various steps in the hyaline degeneration.

Gyn. No. 7511. Path. No. 3757.

Extensive and sharply defined hyaline degeneration in a subperitoneal pedunculated Myoma (Fig. 73).

A. D., aged thirty, married, black. Admitted January 16; discharged February 9, 1900.

Path. No. 3757. The specimen consists of a myomatous uterus with its appendages. The body of the uterus measures 6 cm. in length, 4.5 cm. in breadth, and 3.5 cm. in its anteroposterior diameter. Anteriorly it is smooth and glistening.

Posteriorly it is covered with numerous adhesions.

Studding the uterine walls and also projecting from the surface are several

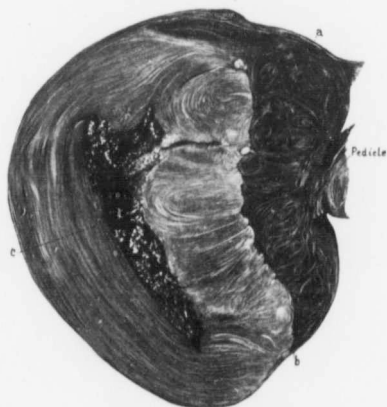

FIG. 73.—EXTENSIVE AND SHARPLY DEFINED HYALINE DEGENERATION IN A SUBPERITONEAL MYOMA. (1/4 nat. size.)

Gyn. No. 7511. Path. No. 3757. The tumor represents a cross-section of a subperitoneal pedunculated myoma, 7 x 9 x 10 cm. The fourth of the tumor nearest the pedicle presents the usual myomatous appearance, as seen at *a*. Fully three-fourths of the tumor is much lighter in color and stands out in sharp contrast with the unaltered myomatous tissue. The line of demarcation is well shown at *b*. In the large hyaline area the fibrous arrangement is still visible. The center of the degenerated area has broken down and contains granular material, as seen at *c*.

small myomata; posteriorly, near the cervix, is a subperitoneal nodule, 4.5 cm. in diameter, enveloped in adhesions. It shows an area of hyaline degeneration, 2.5 cm. in diameter. The chief interest lies in a subperitoneal myoma springing from the left side (Fig. 73). This is covered with a few omental adhesions, and posteriorly is pushing aside the folds of the broad ligament. It measures 7 x 9 x 10 cm. On section it presents a very unusual picture. One-fourth of its substance consists of typical myomatous tissue. The remaining three-fourths is light in color and very sharply defined. In this light-colored area the central portion has melted away and left an irregular, ragged cavity.

Microscopically, the uterine mucosa is normal. The light area in the subperitoneal myoma consists in part of necrotic tissue entirely devoid of nuclei, but containing large and small calcareous deposits. Other portions show some hyaline degeneration. The appendages, apart from adhesions, are normal.

San. 1924. Path. No. 8824.

Marked hyaline degeneration with liquefaction of an interstitial myoma (Fig. 74).

P., aged fifty-two, married. Admitted May 8; discharged June 13, 1905.

Path. No. 8824. The tumor is irregularly heart-shaped. It is 12 cm. in length, 18 cm. in breadth, and 20 cm. in its anteroposterior diameter. It is smooth and glistening. Attached to the side are the tubes and ovaries. The great increase in size of the uterus is due to an interstitial nodule, 11 x 15 cm. It is sharply circumscribed. In some places the myoma is perfectly preserved, but at least two-thirds of it has undergone degeneration (Fig. 74). The spaces are filled with coagulated fluid. At a point most remote from the uterus there has been a slight breaking down and the cystic spaces thus formed vary from 0.5 to 4 cm. in diameter. These have smooth walls. The myoma presents the typical picture of hyaline degeneration, with subsequent cystic formation.

Microscopically the myoma shows marked hyaline degeneration. Scattered throughout this hyaline material are little bundles of muscle-fibers.

Gyn. No. 9924. Path. No. 6118.

Cystic degeneration of a portion of a pedunculated subperitoneal myoma (Fig. 75).

E. S., aged forty-nine, married, white. Admitted September 23; discharged October 18, 1902.

Path. No. 6118. The specimen consists of an irregular, multinodular, myomatous uterus, which is approximately 15 cm. in breadth and 8 cm. in its anteroposterior diameter. Attached to it are the tubes and ovaries.

The uterus contained pedunculated, sessile, interstitial, and submucous nodules. One pedunculated nodule springing from the posterior surface is approximately 6 cm. in diameter and mulberry-shaped, there being little nodules

projecting from its surface everywhere. Attached to the posterior surface of the fundus by a pedicle, 2 cm. in diameter, is an oval subperitoneal nodule, 8 x 12 x 14

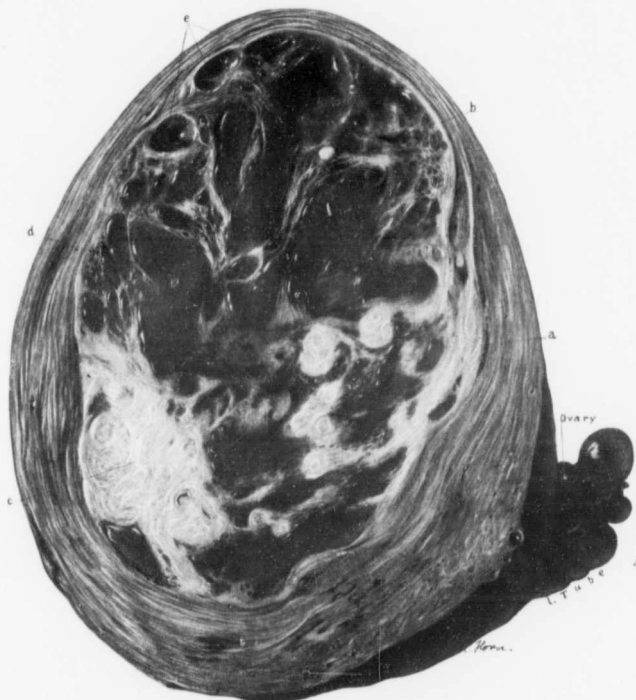

FIG. 74.—MARKED HYALINE DEGENERATION WITH LIQUEFACTION OF AN INTERSTITIAL MYOMA. ($\frac{1}{2}$ nat size.)

San. No. 1924. Path. No. 8824. The picture represents an oblique section through the uterus; the uterine cavity has not been entered.

The interstitial myoma is 11 x 15 cm. *a* indicates the outer covering of uterine muscle; *b* the junction of the myoma with the muscle. The greater part of the myoma has undergone hyaline degeneration with liquefaction, the liquefied areas reminding one of the "water core" occasionally seen in an apple. The liquefied areas are well seen at *d*. Scattered throughout the degenerated areas are irregular patches of typical myomatous tissue, the largest area being at *c*. In some places the liquefied areas have gone on to cyst formation, as designated at *e*.

cm. (Fig. 75). It is partly solid, partly cystic. On section, the portion nearest the uterus seems to be firm, but about one-sixth of the tumor, at a point remote from the pedicle, is soft and cystic and much paler in color. This cystic portion

is filled with clear fluid and differs markedly in color from the ordinary myomatous tissue. The line of demarcation is exceedingly sharp, the tumor presenting a rather porous appearance and being yellowish white in color.

Where the degenerative process is markedly advanced, the tissue is honey-combed and we then have irregular spaces, with delicate trabeculae running

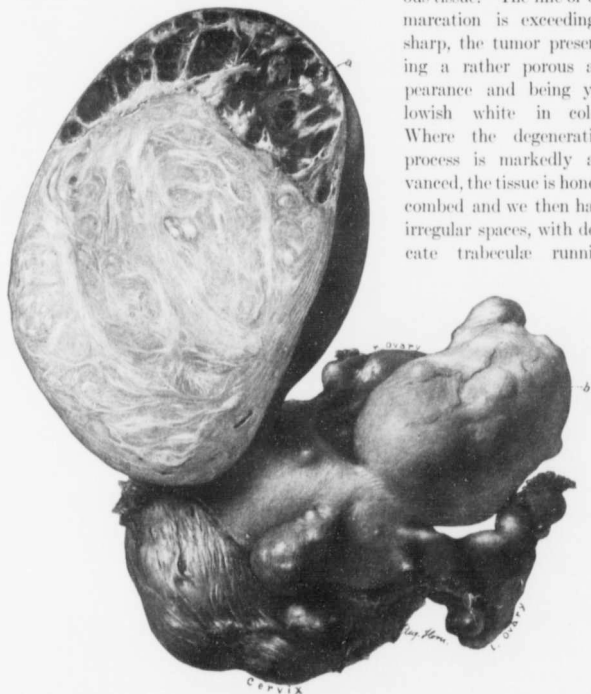


FIG. 75.—CYSTIC DEGENERATION OF A PORTION OF A PEDUNCULATED, SUBPERITONEAL MYOMA. ($\frac{1}{2}$ nat. size.)

GYN. No. 9924. Path. No. 6118. The uterus contains numerous nodules. Springing from the right and anterior aspect of the fundus is a subperitoneal pedunculated myoma, 8 x 12 x 14 cm. The upper portion (a) has undergone hyaline degeneration, with subsequent liquefaction. Traversing the cavity everywhere are large and small trabeculae, dividing the degenerated area into cystic spaces of different sizes. These were filled with a clear, straw-colored fluid.

Histologic Examination.—The walls of the cystic spaces are composed entirely of hyaline tissue, and there is no endothelial lining.

It is interesting to note that the degeneration has occurred at the point farthest removed from the source of blood-supply—the pedicle. Projecting from the surface of the uterus, between the Fallopian tubes, is a small nodule. The upper half is very pale, as indicated by *b*. The pallor is due to hyaline degeneration occurring in this myoma also.

The Fallopian tubes are somewhat thickened. Both fimbriated extremities are free. The tubes were the seat of tuberculosis. The endometrium also showed an early tuberculous process.

across them. The picture is typical of hyaline degeneration with gradual liquefaction.

Microscopically the area of degeneration consists entirely of hyaline tissue. This tissue is devoid of nuclei except for a little rim on the outer surface. Here the muscle-fibers are still preserved. The trabeculae traversing the cavities consist of hyaline tissue that stains a little deeper than that filling some of the spaces. It contains some calcareous plates. Examination of the uterine mucosa shows tuberculosis of the endometrium. There was also tuberculosis of both tubes, and the adhesions around the uterus contained tubercular nodules.

Gyn. No. 12864. Path. No. 10311.

A large multinodular myomatous uterus with a huge subperitoneal pedunculated myoma undergoing cystic degeneration (Figs. 76 and 77).

M. B., married, aged forty-four, black. Admitted April 21; discharged May 23, 1906. In this case the enlargement of the abdomen was first noticed fifteen years ago. The growth has been slow. Seven years later her physician diagnosed a myoma, but advised against operation. The abdominal enlargement steadily increased. For the last five months there has been some pain in the lower part of the back and in the abdomen after exertion. For three months there has been rapid growth of the tumor. The patient has not been incapacitated or inconvenienced seriously until within the last three or four months. During the last few days there has been considerable difficulty in micturition.

At operation the omentum was found to be markedly adherent. The omental vessels were greatly dilated. The tumor was very soft and strongly suggestive of sarcoma. It bled with the utmost readiness. It was so densely adherent that during its removal the left side of the bladder was opened. The patient made a very satisfactory recovery.

Path. No. 10311. The specimen consists of a huge multinodular myomatous uterus, 20 x 25 x 28 cm. The myomata have undergone hyaline degeneration. Attached to the left side of the uterus is a large pedunculated myoma (Fig. 76). Its upper half presents the usual myomatous appearance. The lower half has undergone marked degeneration, is dark in color, and contains numerous cystic spaces.

Histologic Examination.—In the degenerated portion of the myoma there is coagulation necrosis and also a good deal of hyaline degeneration. The cystic spaces are devoid of nuclei, showing neither endothelial nor epithelial lining. In certain parts of the myoma the endothelium of the capillaries has proliferated to such an extent that the muscle-fibers are divided up into alveoli (Fig. 77). At first sight one might very readily diagnose a malignant growth. At other points there is a typical hyaline degeneration.

Gyn. No. 3991. Path. No. 990.

Disintegration of the central portion of an interstitial myoma (Fig. 78).

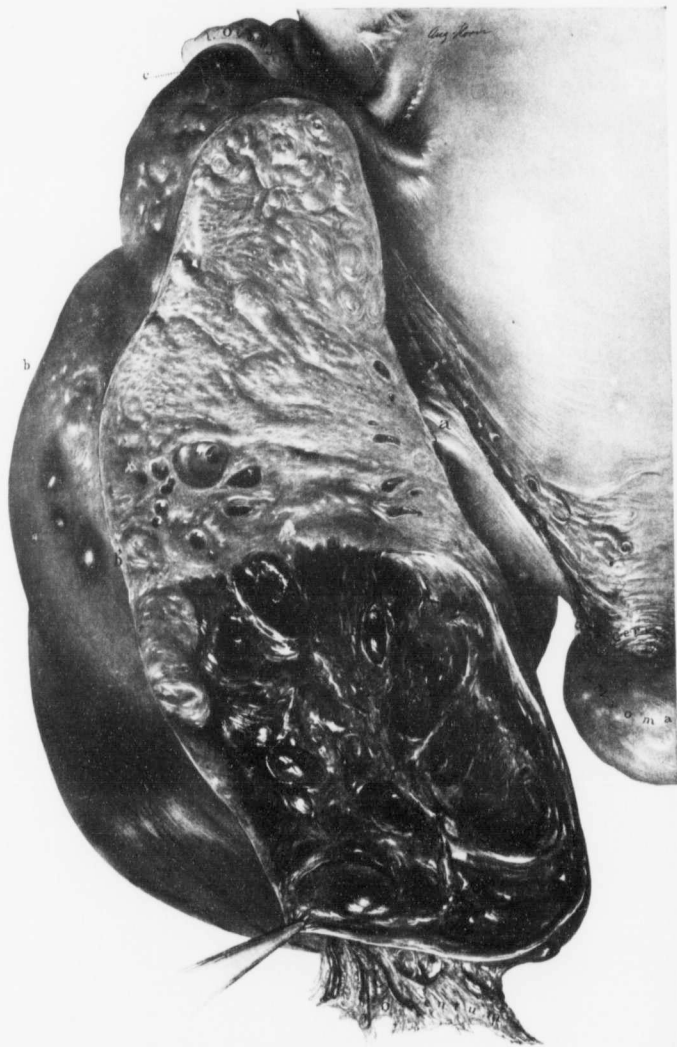


FIG. 76.
98

L. N., single, aged forty-seven, white. Admitted November 29; discharged December 30, 1895.

Path. No. 990. The specimen consists of the uterus with the appendages. The uterus is globular in shape and approximately 10 cm. in its various diameters. Scattered over its surface are several small subperitoneal nodules, varying from 1 to 3 cm. in diameter. The uterus is covered with numerous adhesions,

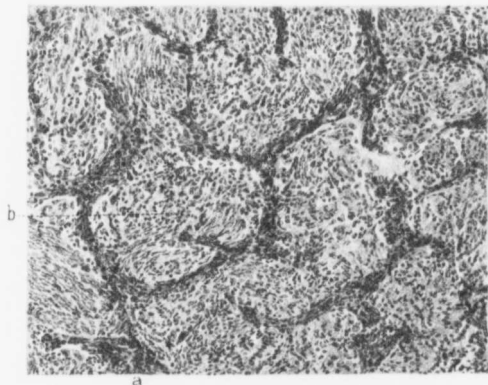


FIG. 77.—MARKED PROLIFERATION OF THE ENDOTHELIUM OF THE CAPILLARIES DIVIDING THE MYOMATOUS TISSUE INTO ALVEOLI. ($\times 120$ diam.)

Gyn. No. 12864. Path. No. 10311. The myomatous tissue presents the usual appearance, but dividing it up into fairly regular alveoli are deeply staining bands of tissue. These dark-staining cells are proliferated and deeply staining endothelial cells of the blood-capillaries. The picture is a most unusual one.

those on the posterior surface being rather dense. On palpation it is rather soft and yielding, giving an indistinct sensation of fluctuation. The uterine cavity is 9 cm. in length, at the fundus 5.5 cm. in breadth; the mucosa is roughened and corrugated in appearance. The portion covering the posterior surface near the right cornu presents an area of thickening 1 cm. in diameter, and contains numerous dilated glands, varying in size from a pin-point to 1 mm. Situated in the anterior uterine wall are several firm white nodules, varying from 0.5 to 3 cm. and

FIG. 76.—CYSTIC DEGENERATION IN A LARGE SUBPERITONEAL PEDUNCULATED MYOMA. ($\frac{1}{2}$ nat. size.)

Gyn. No. 12864. Path. No. 10311. To the right is an enlarged myomatous uterus, recognizable by the left tube and ovary above and the cross-section of the cervix below. *a* is the small pedicle connecting the large tumor with the uterus. Attached to the lower end of the tumor is a broad omental adhesion. Below the line, between *b* and *c*, the peritoneal covering is of a darker hue and the surface is smooth, suggesting degenerative changes in this portion of the tumor. The upper part of the myoma, on section, presents the usual appearance. Near the middle are small, smooth-walled cysts. The lower half of the tumor is much darker in color, owing to the degenerative change, and contains numerous cystic spaces. Histologic examination shows that the chief changes are due to hyaline degeneration of the tumor.

presenting the typical myomatous appearance. The posterior wall is occupied by a tumor 8 cm. in diameter (Fig. 78). This tumor is surrounded by a distinct capsule of uterine muscle, varying from 0.6 to 2.5 cm. in thickness. On section, it is found to be composed of bunches of fibers concentrically and irregularly arranged. Its entire central portion over an area 5 cm. in diameter has degenerated and contains a tenacious, semisolid material.

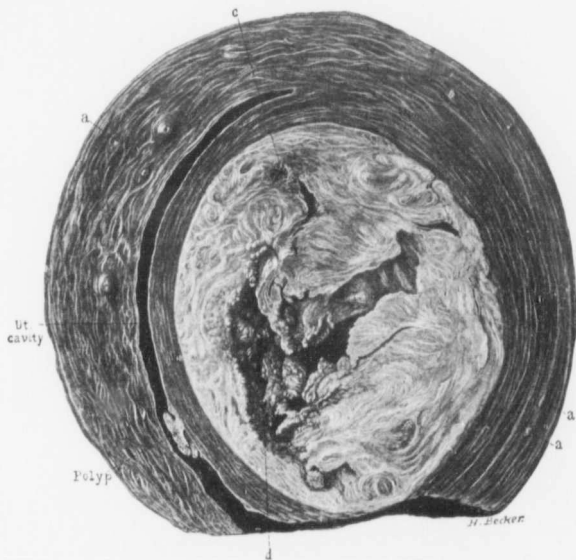


FIG. 78.—COAGULATION NECROSIS AND HYALINE DEGENERATION OF AN INTERSTITIAL MYOMA. ($\frac{1}{2}$ nat. size.)

Gyn. No. 3991. Path. No. 999. *a* is one of several small myomata occupying the anterior wall. In the uterine cavity near the cervix is a small polyp. Occupying the posterior wall is a myoma 8 cm. in diameter. The central portion has broken down, forming an irregular cavity (*d*) filled with a tenacious, semisolid material. At *c* is a colony of small cysts.

On histologic examination the degenerated area was found to consist partly of hyaline material and partly of tissue that had undergone coagulation necrosis, with fragmentation of the nuclei.

Histologic Examination.—The nodules in the uterine walls present the usual appearance, and the degenerated myoma occupying the posterior wall is likewise composed of non-striated muscle-fibers undergoing coagulation necrosis. The central portion is represented by a pale-staining fibrillated or almost homogeneous material from which the nuclei have disappeared, but in other portions

large numbers of fragmented nuclei are seen. On passing toward the uterine muscle the degeneration becomes less marked.

San. No. 1011. Path. No. 4508.

General and diffuse cystic formation in a myoma (Fig. 79).



FIG. 79.—GENERAL AND DIFFUSE CYSTIC FORMATION IN A MYOMA. ($\frac{1}{2}$ nat. size.)

San. No. 1011. Path. No. 4508. *a* indicates the upper limit of the uterine cavity. The great increase in size of the uterus is due to an interstitial and degenerated myoma. Inward it extends to the mucosa; outward it is covered with a zone of normal uterine muscle. The line of junction between the muscle and the myoma is sharply defined, as indicated by *b*. The tissue presents a diffuse, honeycombed appearance. The cysts are of different forms and traversing them are broad and also delicate trabeculae. The cyst-spaces were filled with fluid.

In the solid portions of the tumor the typical myomatous tissue is still preserved, but shows abundant hyaline degeneration. The walls of the cavities consist chiefly of hyaline material. The cavities were devoid of any epithelial or endothelial lining.

J. B. T., aged fifty-three, white, married. Admitted October 15; discharged November 22, 1900. In this case, after doing a hysterectomy, the operator removed several gall-stones.

Path. No. 4508. The specimen consists of a large myomatous uterus with

the tubes and ovaries attached. The tumor measures approximately 18 cm. in diameter. It is everywhere soft and elastic, and is covered with perfectly smooth peritoneum. On section, the tumor is seen to consist of a thin wall, 1 cm. in thickness, with an interior filled with a brain-like substance (Fig. 79). The growth is really a cyst, with remnants of the muscular tissue occurring as a central mass, supported by delicate trabeculae extending to the outer wall. The spaces were filled with a fluid, apparently serous in character, but as the specimen was hardened before being opened, no definite statement can be made.

Histologic Examination.—Sections through the capsule of the tumor show that it is made up of fibrillated connective tissue and non-striped muscle-fibers. Sections from the large cystic myoma show that it consists of myomatous tissue, in most places the seat of a considerable degree of hyaline degeneration. In other places, however, the muscle-bundles present the usual appearance. In some portions of the tumor the tissue has absolutely lost its structure and nothing remains except large, pale-staining areas, which have scattered throughout them groups of large, swollen, spindle-shaped and round cells. These are undoubtedly swollen muscle-fibers which have been cut longitudinally and transversely. At first sight they suggest sarcoma cells, but there is no evidence of any activity. The cyst-spaces show no evidence of any endothelial lining.

Gyn. No. 3345. Path. No. 616.

Marked cystic degeneration of portions of a myoma that had undergone hyaline degeneration (Figs. 80 and 81).

E. Z., married, aged forty-three, colored. Admitted February 25; discharged April 4, 1895. Three years ago the patient noticed a bearing-down feeling in the abdomen and two and a half years later a lump just below the umbilicus. This was approximately 4 x 4.5 x 5.5 cm. It has grown rapidly since its appearance, but has not been associated with any pain.

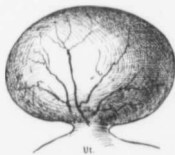


FIG. 80.—Gyn. No. 3345. Path. No. 616. The general contour and relations of the myoma seen in Fig. 81.

Path. No. 616. The specimen comprises the enlarged uterus, with a tumor springing from its right side, and the appendages. The uterus is oval in contour, measuring 10 x 12 x 16 cm. Springing from its anterior and posterior surfaces are several dome-like nodules, the largest of these being 4 cm. in diameter. Projecting from the right side of the uterus is

a kidney-shaped tumor, 12 x 13 x 21 cm. (Figs. 80, 81). This is smooth and glistening, and in many places traversed by numerous blood-vessels. It is attached to the side of the uterus by a short pedicle, 4 cm. in diameter. On palpation the tumor is soft and gives one the impression of being cystic. It has an outer and firm rim, varying from 0.5 to 1 cm. in thickness, but the entire cen-

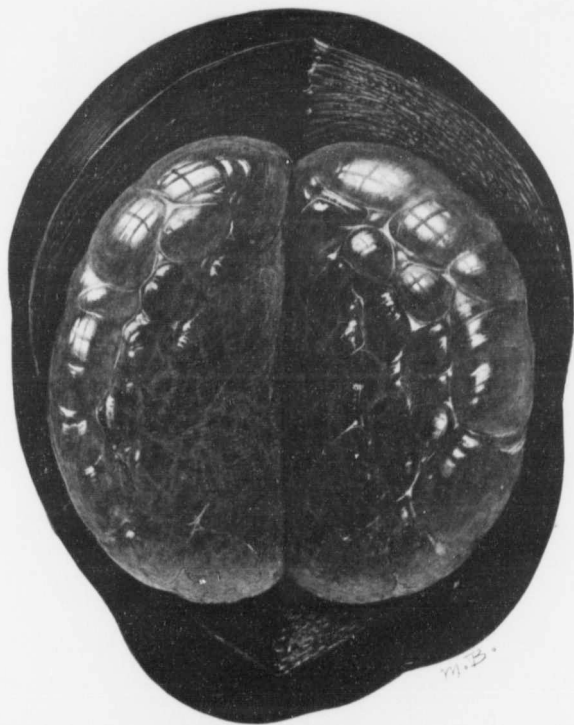


FIG. 81.—COMPLETE CYSTIC DEGENERATION OF PORTIONS OF A MYOMA THAT HAD UNDERGONE HYALINE DEGENERATION. (Nat. size.)

Gyn. No. 3345. Path. No. 616. The relation of the tumor to the uterus is indicated in Fig. 80. The section here depicted was obtained by cutting into one end of the pedunculated nodule.

The outer covering consists of uterine muscle which is much congested. Occupying the entire center of the field is a lemon-colored cystic mass. Dividing the tumor into large and small cysts were delicate trabeculae, many of which carried delicate blood-vessels. On cutting into the mass clear, serous-like fluid escaped and soon coagulated, forming a delicate, jelly-like mass. Other portions of the tumor presented the characteristic hyaline changes.

Unless one has seen such tumors, he might doubt the accuracy of the coloring, but Mr. Brödel was fortunately on hand just as the specimen was cut and caught the various hues perfectly.



tral portion is soft and breaking down. Traversing some portions of the center is an irregular core of solid tissue which is attached to the outer wall in various places. One portion of the section, however, is entirely cystic; it is of a lemon color and is traversed by delicate trabeculae. On cutting into it serous fluid escaped, which soon coagulated (Fig. 81).

Histologic Examination.—The large and degenerated nodule to the right of the uterus is composed of non-striped muscle-fibers. Between the bundles and muscle-fibers are numerous homogeneous areas of hyaline degeneration in which remnants of muscle-fibers are still visible. This hyaline change becomes more marked as one passes toward the center, where the tissue appears as one mass of hyaline material. Scattered throughout it are occasionally small bundles of muscle-fibers. The hyaline material in turn gradually dissolves and is lost, a delicate reticulum remaining. This was the picture obtained in the cystic areas.

Gyn. No. 12522. Path. No. 9233.

Marked hyaline degeneration of a myoma with gradual liquefaction of the hyaline tissue (Fig. 82).

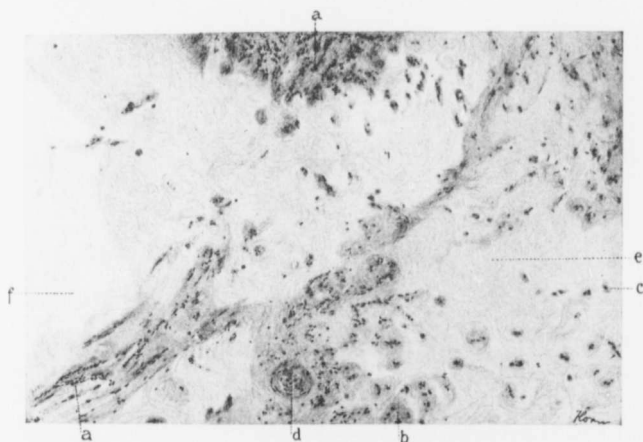


FIG. 82.—GRADUAL LIQUEFACTION OF A MYOMA. ($\times 85$ diam.)

Gyn. No. 12522. Path. No. 9233. At the points indicated by *a* the characteristic myomatous tissue still persists; at *b* is a cross-section of a muscle-bundle and at *c* a cross-section of an individual muscle-fiber. *d* is a blood-vessel. At *e* all trace of the muscle has disappeared, nothing being left but hyaline material and the outline of hyaline connective tissue. At *f* even the hyaline has been replaced by an irregular space filled with coagulated fluid.

S. M., aged thirty-four, admitted November 17, 1905; discharged on the twenty-fifth day. The uterus is approximately 13 cm. in diameter and is

globular; it has a cystic feel and contains a juicy-looking myoma. It is free from adhesions. The myoma is uniformly semisolid and is filled with small cystic areas. From the cut surface a straw-colored fluid escapes.

Microscopically, the myoma shows marked hyaline degeneration. Where the cysts occur, there are clear spaces with only a few muscle-fibers remaining. These stand out clearly. The picture is one of a myoma undergoing hyaline transformation, with gradual liquefaction (Fig. 82).

Gyn. No. 3349. Path. No. 610.

Liquefaction of a hyaline myoma (Fig. 83).

S. R., married, aged forty-eight, white. Admitted February 26; discharged March 26, 1895.

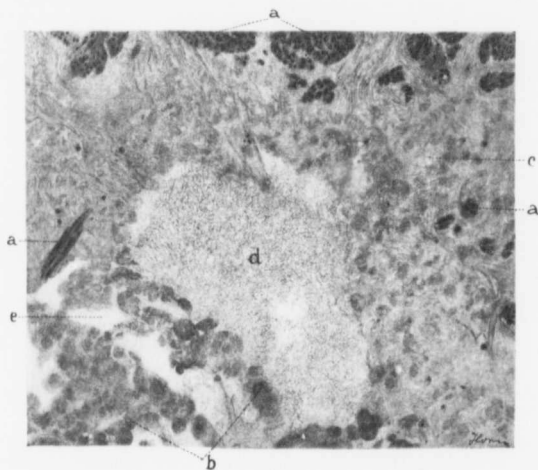


FIG. 83.—LIQUEFIED AND HYALINE AREAS IN A MYOMA. ($\times 95$ diam.)

Gyn. No. 3349. Path. No. 610. At the points indicated by *a* transverse or longitudinal sections of muscle-bundles are still visible. Scattered throughout the field are dark circular or irregular clumps of hyaline, particularly well seen at *b*. These are muscle-bundles that have undergone complete hyaline transformation. The lighter hyaline matrix, as seen at *c*, represents what remains of the fibrous structure. In the center of the picture is an irregular cavity (*d*), lined with hyaline tissue, and filled with a granular material—coagulated serum. At *e* are empty spaces from which all trace of the myoma has disappeared.

This picture gives in detail practically all stages that occur when a myoma undergoes hyaline degeneration.

Path. No. 610. The specimen consists of an enlarged uterus with both tubes and ovaries. The uterus is pear-shaped and measures 10 x 12 x 16 cm. Anteriorly, it is smooth and glistening; posteriorly, it is covered with a few non-

vascular adhesions. On the anterior surface of the uterus is a subperitoneal nodule, 1 cm. in diameter. Situated in the anterior uterine wall is a sharply defined globular tumor, 9 cm. in diameter. In part this is made up of a delicate meshwork of fibers running in all directions, but the greater portion consists of a jelly-like material, yellowish in color, translucent, and from the cut surface of which a large quantity of clear fluid escapes. This fluid coagulates on exposure to the air. The entire tumor might be likened to a ball of jelly everywhere traversed by delicate fibrillae.

Histologic Examination.—The large nodule in the anterior uterine wall is composed of non-stripped muscle-fibers which have undergone diffuse hyaline degeneration, the individual fibers being separated from one another by hyaline material. Where the tissue appears jelly-like the field is almost colorless (Fig. 83), but a fine fibrillated meshwork can be made out, and scattered here and there throughout this colorless material are little islands of muscle-fibers and many delicate blood-vessels. In other portions isolated muscle-fibers can be seen and the tissue also contains hyaline droplets. It looks as if the muscle-fibers had first undergone hyaline degeneration, and that after this the hyaline material had broken up into clumps and had disappeared, leaving a fibrillated network.

C. H. I. 620. Path. No. 8827.

Liquefaction of a myoma (Fig. 84).

E. S., aged thirty-five, married, white. Admitted May 25; discharged June 24, 1905.

Path. No. 8827. The specimen consists of a nodular myomatous uterus, amputated through the cervix, and of a fetus at about the second month. The uterus itself is nodular and is 8 x 8.5 x 16 cm. The largest myoma is approximately 11 cm. in diameter. There is a diffuse myomatous thickening of the uterine walls.

Histologic Examination.—Sections from the endometrium show the usual appearance of pregnancy. Those from the myoma show typical and wide-spread hyaline degeneration, a few fibers remaining here and there throughout the hyaline tissue. Other portions have gone on to liquefaction (Fig. 84). Where such changes have taken place almost the entire field is filled with coagulated serum. The density of the eosin stain depends upon the amount of albumin that the fluid contained. The fluid is divided off into little compartments by delicate strands of either muscle-fibers or connective tissue. The walls of the cyst-spaces are devoid of endothelium.

Gyn. No. 3504½. Path. No. 719.

Marked hyaline and cystic degeneration of an interstitial uterine myoma (Fig. 85).

M. G., single, aged thirty, colored. Admitted May 11; discharged June 18, 1895.

Path. No. 719. The specimen consists of the uterus with the appendages intact. The uterus measures 12 x 16 x 19 cm. and is free from adhesions. Projecting from the lower part of the anterior surface are two small pedunculated nodules, the larger being 1 x 1.2 x 2 cm. Situated in the posterior wall is a tumor, 9 x 13 cm. (Fig. 85). This consists of one large cavity traversed by fibrous

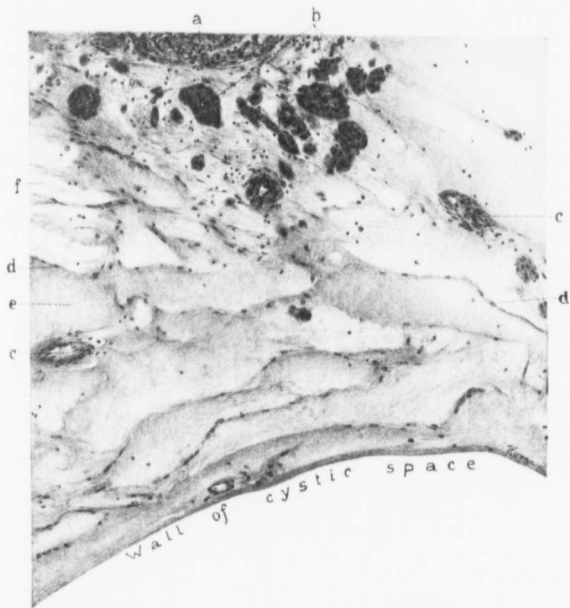


FIG. 85.—LIQUEFACTION AND HYALINE AREAS IN A MYOMA. ($\times 90$ diam.)

C. H. I. 620. Path. No. 8827. The specimen is from a myoma during the early months of pregnancy. *a* indicates the usual myomatous tissue. In the upper part of the field are cross-sections of bundles of swollen muscle-fibers (*b*). *x* indicates blood-vessels. The rest of the field is composed of albuminous fluid divided off into compartments by delicate capillaries, as indicated at *d*. The coagulated fluid in the various compartments differs in density of staining. This depends upon the amount of albumin contained in the fluid—the more albumin, the deeper the stain. At *e* the albuminous contents are abundant, at *f* almost nil, as the fluid stains very faintly. The lower border of the section is a small segment of a cyst-wall. It is totally devoid of an endothelial lining.

trabecula, which partially divide it into several smaller cavities, filled with a yellowish, transparent fluid. The walls of the cavity are composed of a yellowish, erumbly material. The outer rim of the tumor is still intact and varies from 1 to 3 cm. in thickness. The appendages are normal.

Histologic Examination.—The tumor is composed of non-striped muscle-fibers closely packed together. The tissue lining the cyst-like cavities has undergone complete hyaline transformation. This hyaline material in some places presents a homogeneous appearance, but in other places the colorless



FIG. 85.—HYALINE DEGENERATION WITH LIQUEFACTION OF AN INTERSTITIAL UTERINE MYOMA. (2 nat. size.)

GYN. No. 35044. Path. No. 719. Occupying the fundus is a myoma 9 x 13 cm. The center of this consists of one large cavity lined with a shaggy, crumbly material, and traversed with trabeculae. It has contained a clear transparent fluid. The appendages are normal, and the uterine cavity has in no way been encroached upon.

Histologic examination shows that the inner lining of the degenerated myoma consists of hyaline material.

muscle-fibers are still visible. Here and there unaltered muscle-fibers can still be made out. The hyaline material gradually fades away and on the inner surface of the cavities almost entirely disappears. The line of junction between the degenerated and unaltered muscle-fibers is sharply defined, the one ending abruptly where the other begins. The cavity formation in this case is due to hyaline degeneration with subsequent liquefaction. At no point does the cavity show any epithelial or endothelial lining.

Gyn. No. 7049. Path. No. 3318.

Marked hyaline degeneration and liquefaction of a large myoma (Fig. 86).

A. M., married, white, aged fifty-one. Admitted July 6; discharged August 17, 1899.

Path. No. 3318. The specimen consists of a large myomatous uterus, with intact tubes and ovaries. The myomatous mass is markedly nodular, being studded with myriads of small and moderately large nodules. The tumor measures 23 x 25 x 31 cm., and situated in a cleft on its upper and anterior surface is the very small uterus. The myoma has consequently filled the pelvis and spread out the folds of the broad ligament. On section, it is found that almost the entire myomatous mass has been converted into a huge cavity (Fig. 86), the inner surface of which presents a shaggy appearance. Traversing the cavity in all directions are large and small trabeculae that hold together large and firm masses in the center, the trabeculae stretching from side to side. The shaggy masses lining the walls of the cavity are whitish yellow in color. The general impression gained is that the softened portions of the myoma have melted away, leaving the more resistant portions, which remain as trabeculae. The fluid filling the cavity is somewhat turbid and of a greenish-brown color.

Histologic Examination.—The outer portions of the walls of the large and cystic myoma consist of typical myomatous tissue. The shaggy inner surface and the trabeculae represent nothing more than myomatous tissue that has undergone complete hyaline degeneration. This tissue is totally devoid of nuclei of any kind.

San. 1925. Path. No. 8838.

A large multinodular myomatous uterus with a huge subperitoneal and cystic myoma (Fig. 87).

G. S. W., aged thirty-eight, married, white. Admitted May 8; discharged June 13, 1905.

Path. No. 8838. The specimen consists of the uterus, with many myomata, and the appendages. The tumor weighed twenty pounds. The uterus has been crowded down between two myomata. One is irregularly kidney-shaped, 17 cm. in length; the other springs from the posterior surface of the uterus, and is 15 cm. in length. Scattered throughout the uterus are numerous pedunculated, interstitial, and partially submucous myomata. The chief interest is centered in the cystic pedunculated myoma, 30 cm. in its longest diameter (Fig. 87). This is attached to the anterior and right side of the uterus by a short pedicle, 6 cm. in breadth. This tumor is covered with omentum, which is greatly thinned out. On section, it is found to consist of myomatous tissue in the outlying portion; in the central portion is a gelatinous-like tissue, with trabeculae running through and giving rise to many large and small cystic spaces. In the center of the tumor is an oval cystic space, 8 x 10 cm. It has a smooth lining



FIG. 86.—MASSIVE HYALINE DEGENERATION AND LIQUEFACTION OF A LARGE UTERINE MYOMA. (1/2 nat. size.)

Gyb. No. 7049. Path. No. 3318. The tumor measured 23 x 25 x 31 cm. Situated in a cleft on its upper and anterior surface was the very small uterus. Almost the entire tumor has been converted into one huge cavity. The walls are composed of typical myomatous tissue, well seen at a. Near the walls are cross-sections of myomatous tissue that has undergone hyaline change. This is clearly seen at b. The central portion of the cavity is partly filled by a shaggy degenerated material, held in place by trabeculae extending to the outer wall. Some of the finer trabeculae are seen at c. At d is a large space where complete disintegration has taken place. The fluid filling the tumor was somewhat turbid and greenish brown in color. The shaggy inner walls and the masses in the center consisted of hyaline material totally devoid of nuclei.

and in some portions contains a clear fluid; in others, chocolate-colored clots,

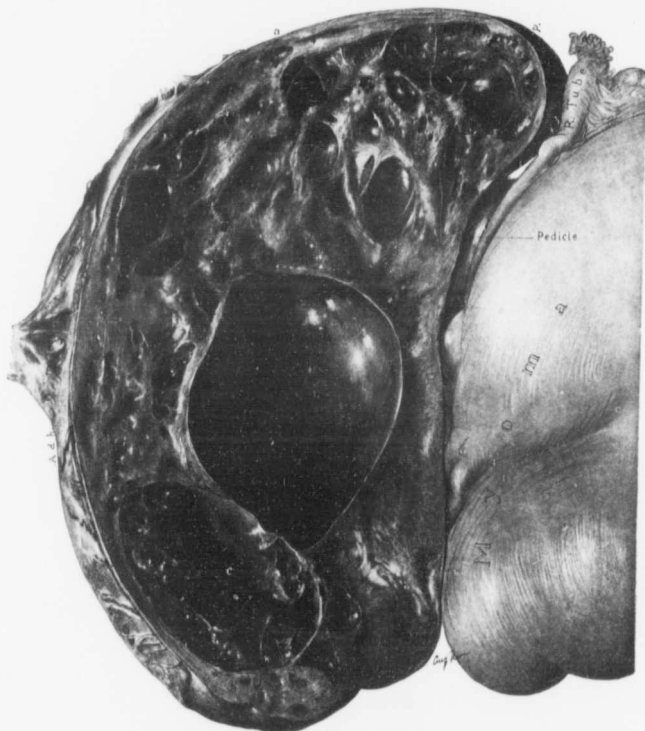


FIG. 87.—A CYSTIC SUBPERITONEAL PEDUNCULATED MYOMA. ($\frac{1}{4}$ nat. size.)

SER. No. 1925. Path. No. 8838. To the right is the enlarged and myomatous uterus. To the left a large and somewhat flattened cystic myoma, 30 cm. in its longest diameter. This is attached to the uterus by a short pedicle, 6 cm. in breadth. Over the greater part of its convexity it is covered with dense omental adhesions. The tumor, to a great extent, has been converted into large and small cystic spaces. Between the points *a* and *a'* the delicate cystic formation with fine trabeculae is particularly well seen. Most of the smaller cysts were filled with clear fluid. The largest cyst is 8 x 10 cm. and has a smooth lining. It was partially filled with clear fluid, partially with clots. The cyst *c* contained remnants of old blood. Sections from various parts of the tumor show marked hyaline degeneration with liquefaction. Clinging to the large cysts are partly organized clots and old blood-pigment. There is no evidence of endothelium.

evidently the remains of old hemorrhages. There is also another oval cystic space, 9 cm. in length and traversed by trabeculae presenting a homogeneous

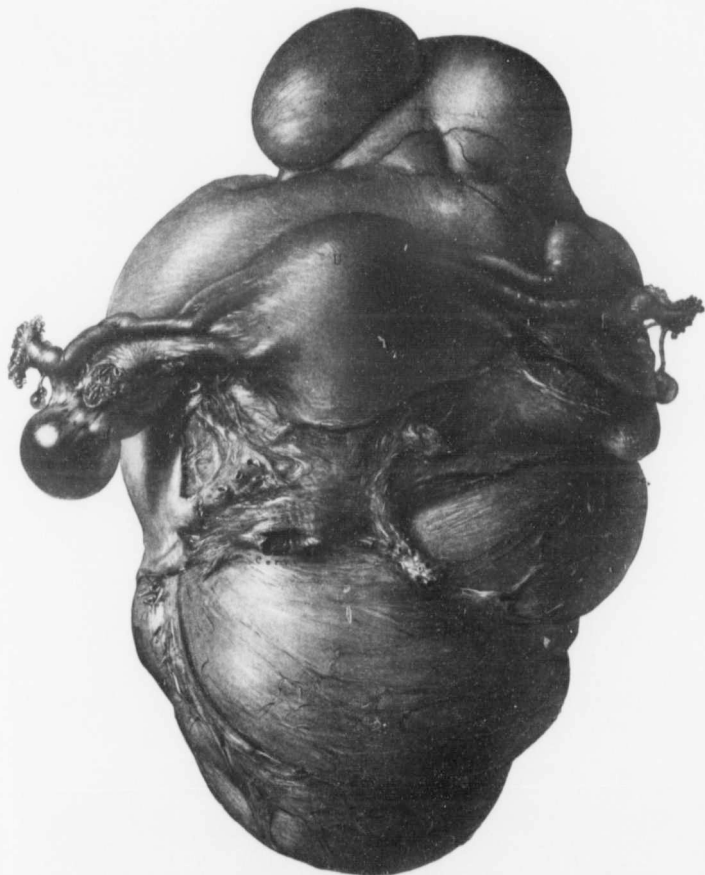


FIG. 88.—A MULTILOCULAR CYSTIC MYOMA. (1 nat. size.)

Gyn. No. 8882. Path No. 5072. The uterus is relatively normal in size. Both tubes and the left ovary are normal, but projecting from the right ovary is a small cyst. Growing from the posterior surface of the uterus is a lobulated cystic tumor. This has been firmly fixed in the pelvis, as is indicated by the wide extraperitoneal portion. In such cases there is great danger of injury to the ureters. Even after the abdomen was opened this tumor was at first supposed to be an ovarian cyst. For the tumor on section see Fig. 89.

appearance. It is evidently filled with a good deal of old blood. These two cystic spaces are very unusual, but the outlying semisolid and cystic portion is characteristic of any case of advanced hyaline transformation of a myoma.

Histologic Examination.—The edematous, cystic areas are the result of a marked hyaline transformation, with subsequent liquefaction. The tissue immediately around the blood-vessels has undergone almost complete hyaline transformation. We have, also, large areas, absolutely devoid of cells and later this hyaline material has become almost transparent and entirely disappears. The line of hyaline transformation is in many places very sharply defined. In some places throughout the hyaline material we have deposits of yellowish pigment, in all probability the result of old hemorrhages. Sections from one of the cystic spaces partially filled with blood show that we have here in the walls also a great deal of hyaline transformation. Clinging to the wall is fibrin, here and there aggregations of small round cells, and occasionally polymorphonuclear leukocytes. Many of the leukocytes have a brownish tinge, showing that they are rather old and have probably imbibed old blood-pigment. Clinging to the inner surface of one of the cysts is blood, which is fairly well preserved.

Gyn. No. 8882. Path. No. 5072.

A large multilocular cystic myoma developing from the posterior surface of the uterus (Figs. 88 and 89).

A. B., aged thirty, white, married. Admitted June 25; discharged July 19, 1901. She has been married eleven years, has had three children, the youngest now twenty months old. The labors were easy and there were no complications. Fourteen years ago she first noticed a small tumor in the abdomen. This has grown steadily since then, but has given rise to no symptoms.

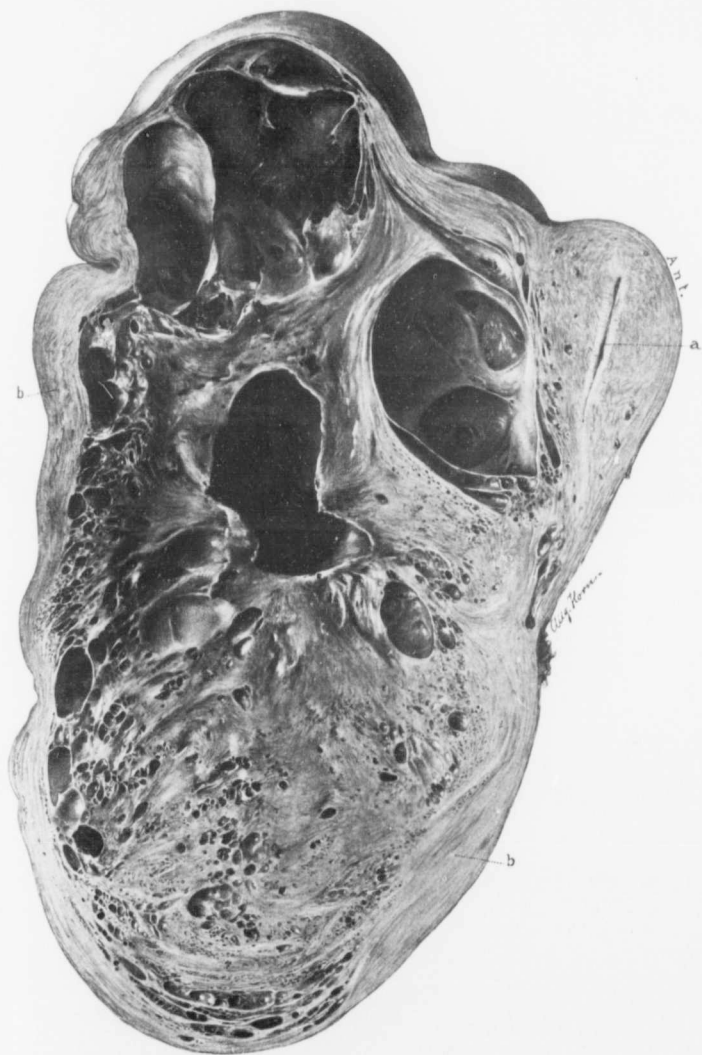Operation. Panhysterectomy. On section of the abdomen the uterus was found resting on the top of a cystic mass. This mass was supposed to be an ovarian cyst and not until it ruptured was the true diagnosis arrived at. Enucleation was carried out in the usual manner from left to right. The procedure took a good deal of time, owing to the dense pelvic adhesions and to free oozing from the vaginal veins. There was a hydro-ureter on the right side.

Path. No. 5072. The specimen consists of the uterus, which is but little altered, and of a large tumor, which has apparently developed in the posterior wall. This tumor measures 9 x 20 x 31 cm., is lobulated, cystic, and is very sug-

FIG. 89.—A LARGE CYSTIC MYOMA GROWING FROM THE POSTERIOR SURFACE OF THE UTERUS.

Gyn. No. 8882. Path. No. 5072. The picture represents a longitudinal section of the tumor seen in Fig. 88. *a* indicates the uterine cavity, which is normal. Springing from the posterior wall of the uterus is the large multilocular myoma, 9 x 20 x 31 cm. Covering the outer surface is a mantle of muscular tissue (*b*). The upper part of the tumor contains large cystic spaces with secondary recesses opening into them. The lower half presents a spongy appearance, due to the presence of many small cysts embedded in the rarefied tissue.

Histologic examination shows that nearly the entire central portion of the tumor is devoid of nuclei. The solid tissue is much rarefied or "threadbare," and the cysts are spaces devoid of any epithelial or endothelial lining.



gestive of an ordinary multilocular ovarian cyst (Fig. 88). On section (Fig. 89) the upper part of the tumor is found to be made up of large cysts with numerous recesses opening into them. These cysts appear to be filled with clear fluid.

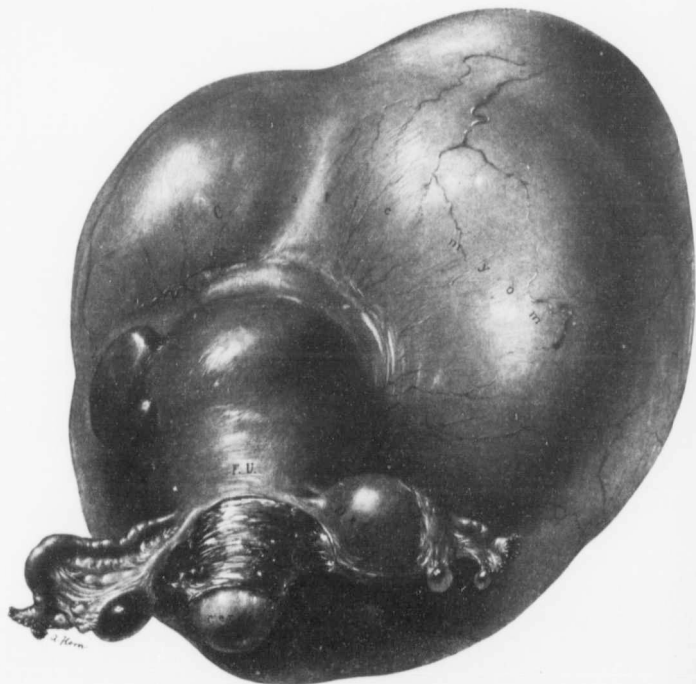

FIG. 90.—A LARGE SUBPERITONEAL CYSTIC MYOMA. (2 nat. size.)

Gyn. No. 6432. Path. No. 2661 Springing from the fundus is a partially pedunculated cystic tumor, 16 x 27 x 30 cm. The fundus itself is somewhat enlarged, from the presence of myomatous nodules. Both tubes and the left ovary are normal. The right ovary contains a small dermoid cyst. For the appearance of the uterus on section see Fig. 91.

The lower half of the tumor is made up of a spongy material containing numerous small cysts in its meshes. Covering the entire outer surface is a mantle of myomatous tissue, in most places reaching 1 cm. in thickness.

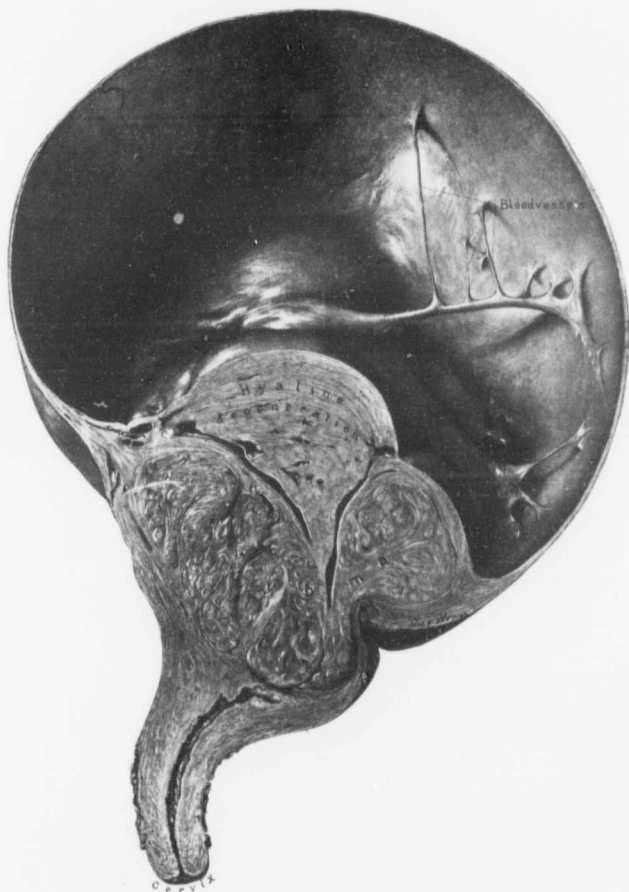


FIG. 91.—A CYSTIC MYOMA.

Gyn. No. 6432. Path. No. 2661. (For the general appearance of the tumor see Fig. 90.) The section has been cut longitudinally through the tumor. The upper part of the tumor has been converted into a large cystic cavity with walls from 1 to 3 mm. thick. The inner surface is smooth and on the right are numerous trabeculae, passing from the outer thin wall to the solid portion of the tumor. These trabeculae carry blood-vessels. A large wedge of the solid portion of the tumor has undergone complete hyaline degeneration, but in the lower part the typical myomatous tissue still persists. The uterine cavity itself is normal. There was no epithelial nor endothelial lining to the cyst.

Histologic Examination.—The outer portions of the tumor present the usual myomatous appearance. The central portion consists of tissue that has undergone hyaline degeneration or is entirely devoid of nuclei. It is gradually becoming rarefied and the empty spaces are totally devoid of any endothelial lining. This is the most remarkable cystic degeneration in a myoma that we have ever noted.

Gyn. No. 6432. Path. No. 2661.

A large cystic myoma springing from the fundus of the uterus (Figs. 90 and 91).

A. B., single, aged forty-four, white. Admitted October 13; discharged November 17, 1898.

Path. No. 2661. The specimen consists of the uterus, attached to which is a large tumor, both tubes, the left ovary, and a dermoid cyst of the right ovary (Fig. 90). The uterus proper is relatively small, measuring 5 x 6 x 6 cm. Springing from the fundus is a large pedunculated tumor, 16 x 27 x 30 cm. On the posterior surface of the tumor is a groove corresponding to the prominence of the sacrum. The surface of the tumor is smooth and glistening, and traversed by numerous blood-vessels. It is fluctuant and its walls are apparently thin. The tumor is attached to the fundus by a broad pedicle, 6 cm. in diameter. Springing from the posterior surface of the large tumor on the left side are two nodules. The large myoma, on section, is found to be composed of two portions, one cystic, the other solid (Fig. 91). The upper part forms one large cavity, with numerous trabecule extending to the wall of the solid portion of the tumor. The wall itself is composed of myomatous tissue of varying thickness. Fully one-third of the solid portion of the tumor has undergone complete hyaline degeneration, as indicated in the figure.

Histologic Examination.—The walls of the large cystic tumor present smooth inner and outer surfaces, the former having no special cell lining. The walls consist of large spindle-shaped fibers that run more or less parallel to the circumference, but in some places interlace. There is considerable fibrillation of the tissue, which is poor in cells and is quite edematous. The picture is a very unusual one.

Gyn. No. 4485. Path. No. 1245.

A multicystic uterine myoma (Fig. 92).

FIG. 92.—A LARGE MULTICYSTIC MYOMA. ($\frac{1}{2}$ nat. size.)

Gyn. No. 4485. Path. No. 1245. This tumor measured 19 cm. in diameter, was lobulated, densely adherent, and attached to the upper surface of the uterus by a twisted pedicle. Bulging from the surface are several large cystic spaces. The cysts are large and small, and even the smallest have smooth walls. Clinging to the inner surface of some of the cysts is old blood. The solid portion of the tumor consists of myomatous tissue, which has in places undergone marked hyaline degeneration. The cysts are devoid of any epithelial or endothelial lining.

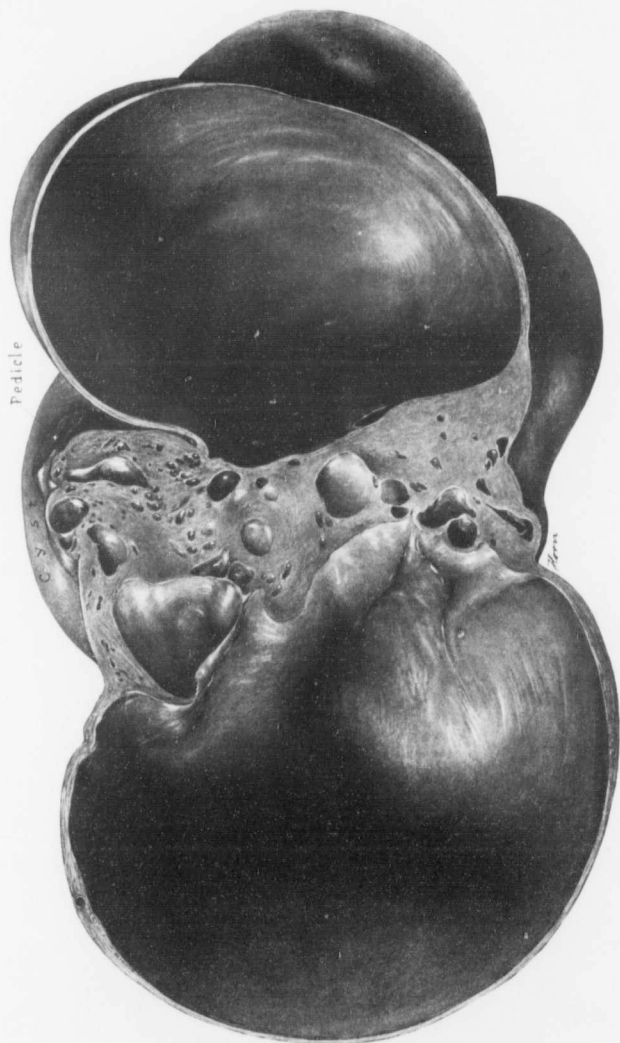


FIG. 92.

A. J., married, aged forty-seven, white. Admitted June 25; discharged August 2, 1896. The patient had one child, twenty-three years ago. She first noticed an abdominal enlargement about six months ago. The increase in size has been gradual.

At the operation the cystic myoma had a twisted pedicle and there were dense adhesions between the tumor and the anterior abdominal wall. The tubes and ovaries were adherent to the pelvic floor.

Path. No. 1245. The specimen consists of the uterus with its appendages and of a large tumor. The uterus is approximately globular, and averages 8 cm. in diameter. It is covered with a few adhesions. The walls are thickened, and contain two small myomatous nodules. Occupying the fundus is a tumor, 5 cm. in diameter, which is becoming cystic. The large tumor (Fig. 92), springing from the upper surface of the uterus where it joins the right tube, is irregular in shape and averages 19 cm. in diameter. Projecting from its surface are numerous bosses and two pedunculated cysts, 8 and 9 cm. in diameter respectively. The large cyst has delicate walls. These, over an area 4 mm., have undergone partial rupture, some of the layers having given way. The tumor is covered with dense adhesions, some of which contain adipose tissue. The walls of the tumor vary from 2 to 4 mm. in thickness. One smaller cyst is hemorrhagic and there are numerous adhesions on the under surface of the tumor. The cysts have smooth inner surfaces.

Histologic Examination.—The solid part of the large tumor consists of non-stripped muscle-fibers, and between the muscle-bundles are wide bands of connective tissue which have undergone hyaline degeneration. The tumor has an abundant blood-supply, but many of its vessels are becoming obliterated and others are filled with recent or partially organized thrombi. The walls of the cyst projecting from the surface of the large tumor are likewise composed of non-stripped muscle-fibers. There is no evidence at any point of an epithelial or endothelial lining.

Gyn. No. 13625. Path. No. 11651.

A very large cystic myoma (Fig. 93).

A. N., married, white, aged forty-eight. Admitted March 1; discharged March 29, 1907. Four years ago the patient began to notice a uniform enlargement in the abdomen. This increase in size has been gradual. The patient states that the girth of the abdomen increases during her menstrual period.

The tumor was densely adherent to the omentum and from it the greater part of the nourishment came.

Path. No. 11651. The specimen consists of the uterus, attached to which is a large cystic myomatous mass, the whole measuring approximately 16 x 35 x 50 cm. (Fig. 93). The uterus, which has been amputated through the cervix, measures approximately 7 x 11 cm. It is multinodular, containing subperitoneal and interstitial myomata. The main tumor springing from the fundus measures approximately 16 x 35 x 39 cm. The surface of the tumor is moderately smooth,

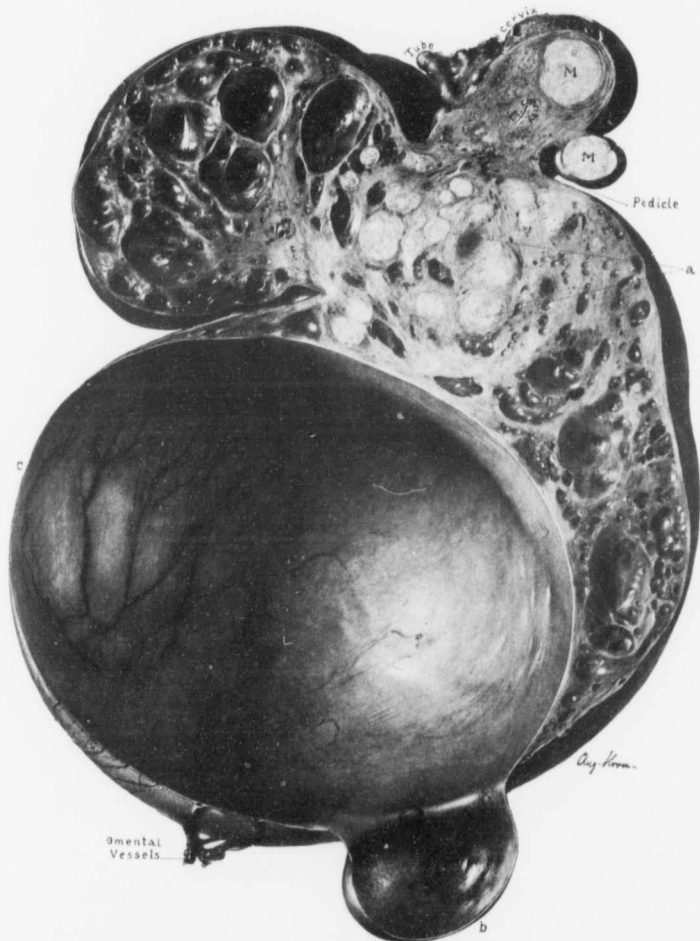


FIG. 93.—A CYSTIC MYOMA WEIGHING 39 POUNDS AND CLOSELY RESEMBLING A MULTICULAR OVARIAN CYST
($\frac{1}{2}$ nat. size.)

Gyn. No. 13625. Path. No. 11651. In the upper part of the picture a cross-section of the uterus is seen. It contains one interstitial and one subperitoneal nodule. Attached to the side of the uterus is a very large multicular cystic myoma. At the points indicated by *a* the myomatous arrangement is still clearly seen. The small cysts have smooth walls, and were filled with clear fluid. The large cyst with its secondary hernial projection (*b*) has very thin walls, so thin that in the vicinity of *c* light was easily transmitted. The large cyst was also filled with clear fluid. The outer surface of the cyst was covered with many omental adhesions.

but toward the upper part anteriorly is a band of omentum approximately 10 cm. in length and 3 cm. in width. At other points over its surface there are also omental adhesions. One large vein in the omental adhesions is fully 3 mm. in diameter and others noted at operation were at least 5 mm.

On section, the large cystic mass is found to be filled with a moderately clear straw-colored fluid. The large cystic space measures approximately 25 cm. in diameter. The walls are perfectly smooth and about the thickness of parchment. Large blood-vessels can be seen coursing in the walls in this cyst. Projecting from the large cyst is a secondary hernial cyst. The middle portion of

the tumor is made up of moderately firm whorls of myomatous tissue, but here also cystic spaces are in evidence, the largest cyst measuring 1.5 cm. in diameter. All these spaces have smooth inner linings and contain clear fluid.

Histologic Examination.—Sections taken from the more solid portions of the large tumor show that it is made up of myomatous tissue, in places moderately well preserved. In most instances, however, there is rather extensive hyaline degeneration. Sections taken from those areas which macroscopically have a soft and gelatinous appearance show typical liquefaction of the muscle-fibers. In some places a few cells are still moderately well preserved. In other places there has been complete disintegration, only a

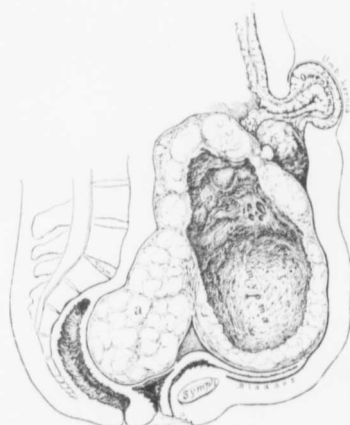


FIG. 94.—A CYSTIC UTERINE MYOMA.

C. H. I. F. Path. No. 6046. In this case there was a strangulated umbilical hernia. Filling the pelvis was the projection *a*, and it was necessary to completely sever the cervix before this could be dislodged. A large part of the main tumor had become converted into a cyst, which on histologic examination was found to be lined with hyaline material.

few swollen cells or shadows of cells remaining. Sections taken through the edge of the large cystic space show that it is lined with typical myomatous tissue. No endothelial lining can be noted. This is one of the most pronounced examples of a cystic myoma that we have ever encountered.

C. H. I. F. Path. No. 6046.

Strangulated umbilical hernia and a large cystic myoma with a portion incarcerated in the pelvis (Fig. 94).

F., about forty-five years of age, was seen in consultation with Dr. A. Trego Shertzer and admitted August 10, 1902. She had had an abdominal tumor for a long period. She came to the hospital hurriedly on account of a strangulated umbilical hernia. The tissues in the hernial sac were almost bluish black. After removal of a wide area at the umbilicus an attempt was made to deliver the tumor. This was exceedingly difficult, because a large portion of it was wedged in the pelvis. Finally, after using a good deal of traction, we were able to expose the tumor and amputate through the cervix. It then became feasible to remove the pelvic portion. The patient made an excellent recovery.

The uterine tumor measures 22.5 x 20 cm. Its central portion over a wide area, as indicated in Fig. 94, has undergone complete cystic transformation. The cystic transformation on microscopic examination was found to be due to hyaline transformation, with subsequent liquefaction.

Gyn. No. 13423. Path. No. 10677.

Extensive cystic degeneration of an interstitial uterine myoma (Figs. 95 and 96).

H. M., aged forty-one, white, married. Admitted December 4, 1906; discharged January 17, 1907. The patient made a perfect recovery.

Path. No. 10677. The specimen consists of a large myomatous uterus. The uterus itself has been opened posteriorly. It is 15 cm. in length, 8 cm. in breadth (Fig. 95). The uterine walls show a considerable thickening, reaching 3 cm. in thickness in the upper portion. Occupying the anterior wall is a growth 11 cm. in diameter. This, on section, is cystic, and at first sight bears a striking resemblance to a heart (Fig. 96). Its walls vary from 0.5 to 2.5 cm. in thickness. Its inner surface is smooth and glistening. Its walls contain numerous depressions and smooth, dome-like elevations; and stretching from depression to depression are little smooth bands which are rounded and bear considerable resemblance to the columnæ carneræ. The depressions sometimes extend for at least 2 cm. into the depth. At *b*, on the anterior surface, is a cyst 2 cm. in diameter, with smooth walls. This cystic space was filled with clear straw-colored fluid, which did not coagulate on exposure.

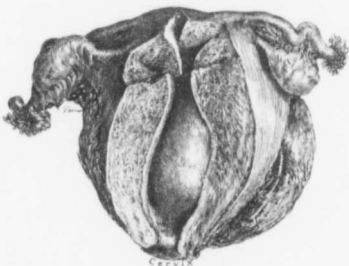


FIG. 95.—A CYSTIC MYOMA OCCUPYING THE ANTERIOR UTERINE WALL.

Gyn. No. 13423. Path. No. 10677. Projecting into the uterine cavity from the anterior wall is a globular tumor. The appendages are normal. For the appearance of the uterus on section see Fig. 96.

Histologic Examination.—Sections from the uterine wall show undoubted beginning adenomyoma. Sections from the growth in the wall of the uterus show that it is composed of myomatous tissue. The muscle-fibers are closely packed together and at first sight strongly suggest sarcoma. The individual cells, however, are perfectly smooth and the muscle-fibers are regularly arranged. Here and there are faint evidences of liquefaction. The muscle ends abruptly at

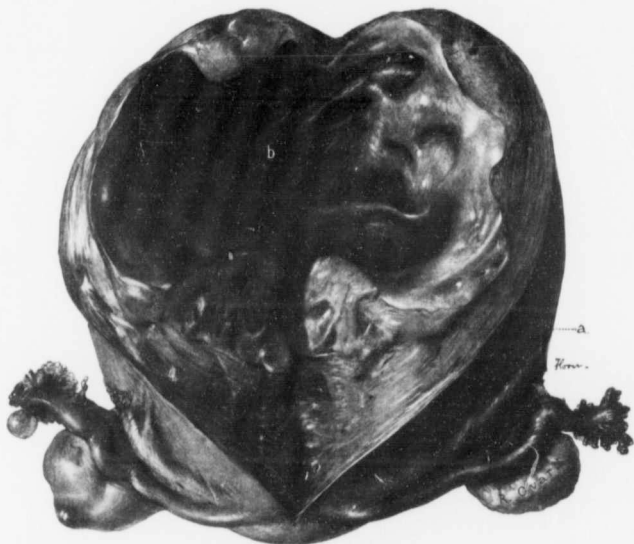


FIG. 96.—A Cystic Myoma with a Cavity Resembling Somewhat the Interior of a Heart. (1 nat. size.)
Gyn. No. 13423. Path. No. 10677. For the general relations of the pelvic organs see Fig. 95. Occupying the anterior uterine wall is a myoma 11 cm. in diameter. Its line of junction with the uterine muscle is indicated by *a*. The entire center of the tumor is cystic. The inner surface is smooth and glistening, but there are numerous recesses corresponding to dome-like elevations, and stretching across the depressions are rounded trabeculae resembling columnar cartilage. *b* is a small cyst with clear contents. The cyst was filled with a straw-colored fluid that coagulated on exposure to the air. The walls of the tumor show some hyaline degeneration, but the inner surface is lined with muscle-fibers. There is no evidence of any endothelial lining.

the inner surface of the cyst. The inner surface is also lined with muscle-fibers, which lie parallel to the cyst cavity and form a layer of cells at least three to six deep. We expected to find a hyaline inner lining, but this is absent on the inner surface, a most unusual picture where large cysts are associated with uterine myomata. This is the only myoma in which we have found such an appearance due to hyaline degeneration.

Gyn. No. 3113. Path. No. 487.

Cystic Spaces in a Myoma Apparently due in Part to Dilatation of Lymph-channels (Fig. 97).

A. V. G., married, aged fifty-two. Admitted October 16; discharged December 6, 1894.

Path. No. 487. The specimen consists of a large globular tumor, in the upper portion of which the uterus is situated. Both tubes and ovaries were intact. The tumor is approximately circular, 25 cm. in diameter. Along its lower and anterior surface are five ill-defined bosses, the largest of which is 3.5 x 5 x 8 cm. The tumor is whitish red in color, smooth, glistening and covered with peritoneum. On the anterior surface of the tumor is a piece of bladder mucosa, 3 x 6 cm. On palpation the tumor is firm and yielding, giving a faint sensation of fluctuation. On section, it is whitish in color and presents a finely striated appearance. Scattered everywhere throughout the tumor are sinuses (Fig. 97), the largest of which is 1.2 cm. in diameter. These have smooth walls and communicate with numerous smaller ones. They contain a serous-like fluid. Some, however, are filled with dark-red blood. Most of these sinuses appear to be lymphatic in origin. On section, the entire tumor mass is found to spring from the posterior uterine wall. It is interstitial and has an outer covering of muscle averaging 2 mm. in thickness. The posterior wall of the uterus is filled with sinuses similar to those noted in the tumor.

Histologic Examination.—The uterine muscle just beneath the mucosa appears to be perfectly normal. In other places it contains numerous small empty spaces, some of which have an endothelial lining. These are probably lymph-spaces. The large tumor situated in the posterior wall is composed of non-striated muscle-fibers and shows diffuse hyaline degeneration. In some places this hyaline degeneration is so marked that the muscle-bundles appear as small islands in the hyaline material. There are many recent hemorrhages, which are chiefly confined to the hyaline areas. In some places the tumor is edematous. The blood-vessels are moderate in number, the veins predominating. Scattered everywhere throughout the tumor are large and small empty spaces, some with, others without an endothelial lining. As the blood in the arteries and veins has been well preserved in Müller's fluid and as these spaces are comparatively free from blood, we are inclined to believe that they are lymph-channels. In this case, as noted on p. 247, there are some very large cells, strongly suggesting a sarcomatous transformation of the myoma.

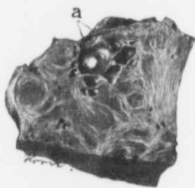


FIG. 97.—IRREGULAR CYSTIC SPACES IN A MYOMA. (NAT. SIZE.)

Gyn. No. 3113. Path. No. 487. At *a* are numerous small cystic spaces, some of which communicate with one another. In this case there were edema and hyaline degeneration. Some of the spaces in the myoma had an endothelial lining and were apparently dilated lymph-channels; others appeared to be due to disintegration of the hyaline tissue.

Gyn. No. 2852. Path. No. 347.

A uterine myoma with cystic spaces containing a material resembling melted butter (Fig. 98).

M. S. D., married, aged forty-three, white. Admitted June 18; discharged July 30, 1894.

Path. No. 347. The specimen consists of an enlarged uterus with its appendages intact (Fig. 98). The uterus is globular in form and measures 13 x 13 x 14 cm. It is smooth, glistening, pinkish in color, and everywhere covered with

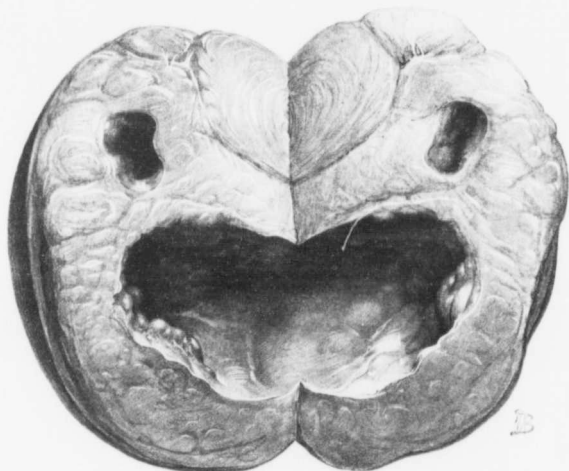


FIG. 98.—A UTERINE MYOMA WITH CYSTIC SPACES CONTAINING MATERIAL RESEMBLING MELTED BUTTER. ($\frac{1}{2}$ nat. size.)

Gyn. No. 2852. Path. No. 347. The globular myoma contains two irregular spaces, the upper one having been cut in two. They are filled with butter-like material, which contains many fat-droplets and cholesterol crystals. We have only had two such cases in a large series of degenerated myomata. (After Howard A. Kelly.)

peritoneum. The posterior wall of the uterus is occupied by an apparently rounded nodule 12 cm. in diameter. This is whitish in appearance, and is made up of smaller nodules composed of concentrically striated fibers. The anterior portion of the tumor contains a cavity, 2 cm. broad and 2.5 cm. in depth. The walls of this are smooth and of a yellowish color. In the posterior portion of this tumor is a second cavity. This measures 4.5 x 5 x 6 cm. and presents a convoluted appearance, has smooth walls and is lined with a yellow, semisolid, butter-like material. Both cavities are filled with a liquid which closely resembles

melted butter. Scattered throughout this material are grayish-red flocculi or streaks of blood.

Histologic Examination.—The large nodule situated in the posterior wall is composed of a hyaline stroma with non-striped muscle-fibers scattered freely throughout it. The muscle in the vicinity of the cavities shows patches of hyaline degeneration, associated with slight lymphoid infiltration, or ends abruptly in a hyaline material. The inner walls of these cavities are composed entirely of this hyaline substance, with a few muscle-fibers scattered here and there. A few blood-vessels are still visible in the hyaline material. The ragged inner surfaces of the cavities are also composed of hyaline material, but the individual fibers are still faintly visible. In no place is there the slightest evidence of polymorphonuclear infiltration. The fresh fluid from the cavities contains many cholesterol crystals, large round cells filled with fat-globules, also many muscle-fibers containing fat-droplets. It also contains much granular debris.

The probable steps in the degeneration of the myoma have been as follows: (1) Hyaline degeneration of the muscle-fibers; (2) emulsification or, in other words, degeneration with liquefaction of the hyaline material.

The most striking point is the fact that the degeneration has occurred without any reaction whatever.

CHAPTER VIII.

CALCIFICATION OF UTERINE MYOMATA.

If one systematically sections all myomata, he will be surprised at the frequency with which gritty particles are found scattered throughout the tumors. On the other hand, it is rare to find a myoma that has been completely transformed, into a calcified nodule. Calcified areas may be found in subperitoneal, interstitial and submucous myomata; though in some cases limited to one nodule, at other times they are present in several myomata in the same uterus.

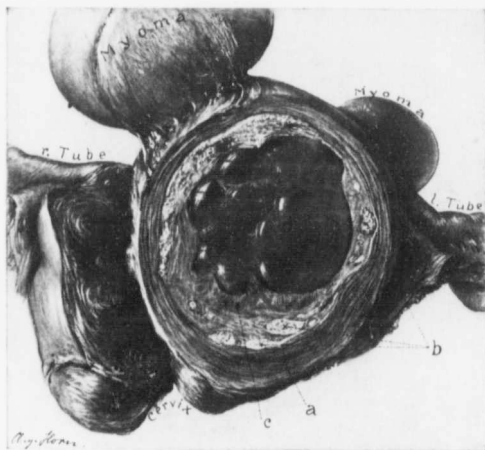


FIG. 99.—A DEGENERATED AND PARTLY CALCIFIED MYOMA. (Nat. size.)

Gyb. No. 3014. Path. No. 443. The uterus contains several myomata. Occupying the greater part of the field is a degenerated interstitial myoma which has a covering of uterine muscle (*a*). In the outlying portions of the myoma are many white calcareous areas, some of which are indicated by *b*. At *c* remnants of myomatous tissue are still in evidence. The entire center was occupied by a pulsatous mass (*d*), which to the examining finger felt like caseous material.

The calcareous areas are usually first recognized when the myoma is cut—the knife at once encountering areas that will not yield or that are gritty. The myomatous tissue in such cases may be dark-red, yellowish-red, or gray, but it is usually yellowish in color, friable, and very like a caseous lymph-gland. Calcareous particles are at times so small that they are scarcely recognizable, but

can be readily detected by rubbing the tissue between the fingers. Where the salts are liberally deposited, it may be necessary to saw portions of the myoma.

In Case 7819 (Fig. 171, p. 268) carcinoma of the cervix was present, and an interstitial and slightly submucous myoma, about 5 cm. in diameter, had undergone necrosis. The entire outer surface of this myoma was encased in a calcified mantle.

Case 3014 (Fig. 99) shows a very good example of partial calcification of a myoma. The central portion has to a great extent undergone softening, suggesting a caseous gland. In the outlying portion the myomatous tissue is still in part preserved, but in many places are found large and small deposits of calcareous material. Surrounding the tumor is a mantle of uterine muscle.

Fig. 100 shows a good example of the various stages in the process of degeneration. The uterus contains three small myomata—one is soft, a second friable, the third calcified.

Histologic Examination.—In the early stages the calcareous deposit may be overlooked macroscopically, especially if the deposit of salts be very scant. In such cases the nuclei of the muscle-fibers have disappeared entirely, but the fibers can still be made out. Scattered throughout the tissue are splotches of dark-staining material, sometimes forming one deeply staining mass with hematoxylin, but often arranged in wavy rows (Fig. 101). On careful study this deeply stained material is found to be finely granular and at numerous points refractive, oblong, or irregular crystals are sometimes seen. Occasionally calcareous plates are found in the outer coats of the blood-vessels, as noted in Fig. 102.

When the calcification is far advanced, it is necessary to remove all the salts before the section can be cut; we then have an essentially necrotic tissue, totally devoid of nuclei, but still retaining its fibrous arrangement.

HOW CALCIUM SALTS ARE DEPOSITED.

It is a well-established fact that in pathologic conditions calcium salts are never deposited in living tissue. The most potent factors in the causation of cell-death are the lack of blood-supply and the injury resulting from the action of toxic substances.

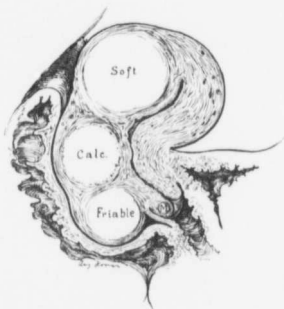


FIG. 100.—MYOMATA REPRESENTING VARIOUS STAGES OF DEGENERATION.

GYN. NO. 8270. In the cervix is a small myoma; lying in Douglas' pouch is a friable, cheesy myoma, which was 5 cm. in diameter; between the two is a partly calcified myoma.

The interesting experiment of Litten* was one of the first important steps in determining the conditions under which deposits of calcium salts in the tissues may occur. When the renal artery of a rabbit was tied for a few hours and

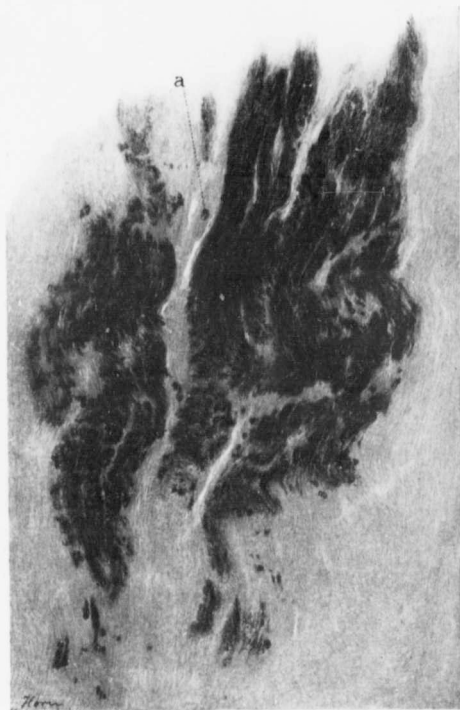

FIG. 101.—PARTIAL CALCIFICATION OF A MYOMA. ($\times 80$ diam.)

GYN. No. 11898. Path. No. 8284. The specimen is from a pedunculated myoma which has undergone hyaline degeneration and coagulation necrosis to a marked degree. In the field from which this picture was taken practically no trace of cells remained, the tissue presenting a fibrillated arrangement and staining a dirty pink with hematoxylin and eosin. The dark wavy areas indicate where salts have been deposited in the necrotic tissue. At numerous points small crystals of the chalky deposit stand out clearly, as is well seen at *a*.

the ligature was then removed and the blood again allowed to circulate, Litten found that at the end of twenty-four hours after such removal the kidney tubules showed the presence of highly refractive granules, which microchemically were

*Litten, *Zeitschr. f. klin. Med.*, 1879, I, 131.

found to consist of calcium salts. He determined the presence of carbonic acid and calcium phosphate and concluded that these substances unite with the ground-substance of the cell to form an insoluble calcium albuminate. By injecting copper sulphate into the circulation of rabbits he obtained similar results. Since that time many observers have found deposits of calcium salts in various tissues following the injection of many irritants, organic and inorganic. Although much has been written on the deposition of calcium salts in the tissues, comparatively little was added to our knowledge of the chemical nature of the process until the recent work of Klotz appeared. The conclusions reached by this observer may be briefly summarized as follows: Preceding the deposit of these calcium salts there are fatty changes in the tissues involved. These in turn are followed by the appearance of soaps or soapy substances, which unite with the albumins of the degenerating cells to form soap albumins. These, with the calcium derived from the blood, form insoluble calcium curds or double calcium soaps. These latter, by the action of substances in the body fluids containing carbonic and phosphoric acids, are then decomposed into phosphate and carbonate of lime and remain as insoluble deposits in the tissue.

For further consideration of this subject the reader is referred to the paper of Klotz* and the comprehensive review of the literature given by Aschoff.†

The findings in one of our cases seem to indicate that electric treatments may

* Klotz, *Jour. Exp. Med.*, 1905, vii, 633-675.

† Aschoff, *Lubarsch-Ostertag, Ergebnisse*, 1902, Wiesbaden, 1904, viii, 561-589.

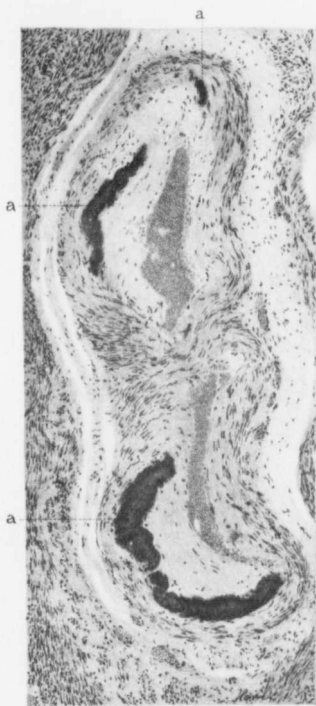

FIG. 102.—CALCAREOUS PLATES IN THE WALL OF AN ARTERY. (X 110 diam.)

Gyn. No. 4364. Path. No. 1170. The uterus was the seat of a diffuse adenomyoma (see Adenomyoma of the Uterus, p. 97). The vessel has been tortuous, as the picture shows two cross-sections of the same lumen. The various areas of calcification are indicated by *a*. This calcareous deposit stains deeply with hematoxylin and has a finely granular appearance. The vessel is embedded in myomatous tissue.

in some way favor the deposition of calcium salts. In this case the myomatous tumor weighed over 40 pounds. The patient had been under electric treatment for a long period, the electrodes having been applied to the opposite sides of the abdomen. On the outer surfaces of the tumor, at the points corresponding to the places at which the electrodes had been applied, were irregular calcareous plaques varying from 4 to 6 cm. in diameter and from 1 to 2 mm. in thickness.

TOTAL CALCIFICATION OF MYOMATA.

We have had several cases in which the myomata formed solid calcareous tumors.

In Case 6479 the uterus contained several myomata and there was an adenocarcinoma of the left ovary. Attached to the right uterine horn was a completely calcified myoma, 1 x 2 cm.

In Case 7889 one myoma had been partly transformed into a caseous material, and projecting from the anterior uterine wall, a little beneath the bladder, was a solid calcified myoma, 6 cm. in diameter.

In Case 8732, in which the uterus contained a large sarcoma apparently springing from a myoma, an almost totally calcified myoma projected from the surface of the uterus.

In Case 4801½ a pedunculated myoma, 8 x 10 x 16 cm., had to a great extent undergone calcification.

The most interesting calcified myoma is described in Path. No. 5816 (Fig. 103). The specimen was sent us by Dr. George E. Holtzapple, of York, Pa. It was as hard as stone, markedly lobulated, and measured 9 x 11 x 15 cm. It had been obtained at autopsy. At *a* is a depression which corresponds to the site of pedicle.

UTERINE STONES.

Our attention was first directed to this subject by a study of Path. No. 161. In this case, during removal of carcinomatous tissue from the uterine cavity, a calculus was brought away. This concretion was about 1.5 cm. in diameter and resembled the half of a hollow sphere. Its outer surface was rough and irregular and at several points presented a mulberry-like appearance. The inner and concave surface was covered with friable tissue. A chip of the concretion was examined by Professor Welch, who failed to find any trace of bone-corpuscles. Chemically, Professor Abel showed that it was composed of Ca_2CO_3 and $\text{Ca}_3(\text{PO}_4)_2$.

It is difficult to explain the origin of the calcareous concretion. The most plausible theory is that it is the remains of a partially calcified myoma. The case is reported in full and illustrated in "Cancer of the Uterus," p. 412.

Thorn,* who has made a statistical study of uterine calculi from the time of

*Thorn, J., "Zur Kasuistik der Uterussteine," Zeit. f. Geb. u. Gyn., 1894, Bd. xxviii, S. 75.

Hippocrates down, reports a similar case. If an interstitial calcified myoma

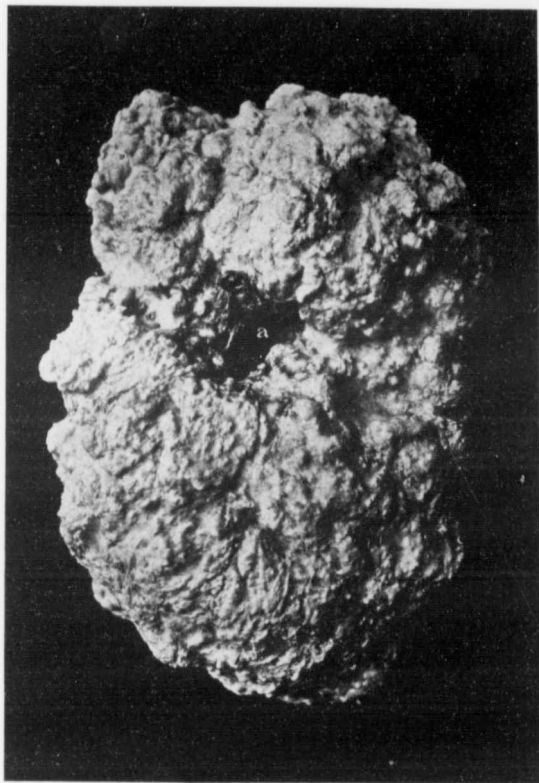


FIG. 103.—A COMPLETELY CALCIFIED SUBPERITONEAL MYOMA. (1 nat size.)

Path. No. 5816. This specimen was removed at autopsy by Dr. George E. Holtzapple, of York, Pa., and sent to us on May 18, 1902. *a* represents the point at which the pedicle was attached. The pedicle did not become calcified, but gradually atrophied, leaving the cavity. The tumor presented a mulberry-like surface. It was perfectly solid and, when dropped on the floor, fell with the thud of a stone.

becomes submucous, it will naturally in time be extruded through the vagina as a so-called uterine stone.

TABULATION OF THE CALCIFIED MYOMATA EXAMINED.

The accompanying table gives a fair idea of the more important partly or completely calcified myomata that have come under our observation.

GYN. NO.	PATH. NO.	UTERUS.	CALCIFIED MYOMATA.
2746	276	Multinodular.	One nodule calcified.
3014	443	Multinodular.	Interstitial nodule, 5 cm. in diam.; outer layers calcareous, center caseous (Fig. 99, p. 126).
3130	499	Multinodular.	Tumor, 25 x 18 x 14 cm. Calcareous areas.
3340	607	Multinodular.	Rough, mulberry-shaped myoma, 13 cm. in diam. Area of calcification 4.5 x 3 cm. on surface. Center soft, grayish yellow.
3778	872	Multinodular.	Several nodules containing calcareous deposits.
3844	910	Multinodular.	Several nodules containing calcareous deposits.
3950	970	Subperitoneal pedunculated myoma.	Dense omental adhesions. Calcified.
3985	986	Multinodular.	Nodule in front of cervix, yellow, surrounded by calcareous deposits.
4160	1084	Two subperitoneal nodules.	Myoma, 7 x 5 x 4.5 cm.; pinkish yellow or bluish; small calcareous deposits beneath peritoneum.
4341	1165	Subperitoneal myoma.	Myoma, 6 x 4.5 cm., yellowish with dark center; calcareous deposits especially near capsule.
4364	1170	Diffuse adenomyoma.	Calcified plates in vessel-walls of uterus (Fig. 102).
4801	1392	Multinodular.	Pedunculated myoma, 8 x 10 x 16 cm.; greater part calcareous.
4975	1500	Multinodular.	Some small interstitial nodules, calcified.
5303	1755	Abdominal myomectomy (single).	Yellow patches; some contain calcified material.
6479	2700	Multinodular.	Calcified myoma, 1 x 2 cm., at right cornu.
6833	3075	Submucous myoma.	Much calcareous deposit.
7775	4043	Multinodular.	Two of nodules calcified.
7795	4055	Multinodular.	Large subperitoneal myoma, partly calcified, partly soft and degenerated.
7880	4136	Multinodular.	Calcified myoma, 6 cm. in diam., under bladder; interfered with bisection.
8270	4453	Multinodular.	Large calcified myoma; near it a cheesy myoma, 5 cm. in diam. (Fig. 100).
8732	4931	Multinodular with sarcomatous degeneration.	Subperitoneal calcified myoma (Fig. 143, p. 217).

GYN. No.	PATH. No.	UTERUS.	CALCIFIED MYOMATA
11792.....	8116.....	Uterus normal in size.	Subperitoneal myoma, 15 x 12 x 8 cm.; hyaline degeneration; areas of complete necrosis; points of calcification.
11898.....	8284.....	Subperitoneal myoma. Adherent omentum.	Microscopic dark-purple areas of calcification (Fig. 101, p. 128).
12779.....	9642.....	Multinodular.	Myomata show hyaline and cystic changes and calcareous deposits.
San. 2189.....	10015.....	Multinodular.	Subperitoneal myoma, 1.5 cm.; small areas of calcification.
Dr. Holtzapfle ..	5816.....		Large subperitoneal myoma completely calcified (Fig. 103).
W., C. H. I.	6421.....	Large, globular.	Interstitial myoma with sarcomatous degeneration. Areas of calcification (Fig. 131, p. 193).

Clinically, these calcified myomata are of little import. A degenerated myoma, when soft, may become infected, but when once calcified, usually gives little or no trouble. It cannot be well diagnosed as calcified prior to operation.

To the surgeon the condition may offer certain obstacles, on account of the difficulty in getting at the uterine vessels, or when, as a result of adhesions, bisection is deemed necessary, since it may be impossible to cut through the calcified nodule. This difficulty may be readily overcome by merely shelling the tumor out and then completing the bisection. We have seen operators in removing myomatous uteri by the vagina have untold difficulty with a large calcified myoma. In fact, we have seen them resorting to the saw and removing the calcified nodule piecemeal.

CHAPTER IX.

SUPPURATING UTERINE MYOMATA.

In this chapter we include only those cases in which the pus formation occurred in myomata situated on the outer surface of the uterus, or located in the musculature. Suppurating myomata are divisible into three definite classes: (1) Subperitoneal; (2) interstitial; (3) submucous. However, inasmuch as the submucous variety has certain characteristics totally different from those of the other two classes, they will be discussed in another place.

SUPPURATING SUBPERITONEAL MYOMATA.

We have had five cases of this character, and two other interesting specimens have been referred to us. In Case 12216 (Fig. 104), on section, a multinodular uterus was found reaching to the umbilicus. The most prominent myoma was densely adherent to the anterior abdominal wall, over an area 4 x 4 cm., and there were also omental adhesions. As soon as the myoma was separated from the abdominal wall, pus trickled down its surface from a cavity situated directly beneath the point at which the abdominal adhesions had existed. This cavity measured 7 x 5 cm. and was filled with pus.

In Case 3216 a myoma, 23 cm. in diameter, was attached to the left side of the uterus (Figs. 105 and 106). On account of the septic temperature pus was suspected. On tapping, 4700 c.c. of creamy pus were evacuated. The tumor was released from the omental adhesions and the uterus and its appendages were removed.

Case 15281 furnished one of the most interesting of our series. The patient, some months prior to her labor, noticed a small abdominal tumor. Her labor was uneventful, but a few weeks later she entered the hospital very ill. At operation a suppurating, pedunculated, subperitoneal myoma was found. This had ruptured and an abscess sac had developed between the myoma, the omentum, loops of small bowel, and the right lateral abdominal wall (Figs. 107 and 108).

In February, 1895, Dr. David W. Houston, of Troy, N. Y., sent us a portion of a subperitoneal myoma which a woman, fifty-five years of age, had carried for thirty years. The central portion of the tumor had been converted into an abscess containing 10½ quarts of pus.

Suppurating subperitoneal myomata communicating with the bowel.

In three of the seven cases of suppurating subperitoneal myoma the abscess had opened into the bowel. In Case 7549 the whole abdomen was filled with a

large myomatous uterus. In the upper part was a large irregular abscess communicating with the colon (Fig. 109).

In Case 9078 a partially parasitic myoma contained an abscess cavity. This communicated freely with the cecum, fecal matter passing from the bowel to the cavity in the myoma. This case is reported in detail on p. 45 (Fig. 32).

In Hundley's case the parasitic myoma had received its nourishment from the small bowel. The interior had been converted into an abscess sac and fecal matter passed directly from the bowel into the myoma and back again to the bowel. This case is likewise reported in detail in the chapter on Parasitic Myomata (p. 47, Fig. 33).

CASES OF SUPPURATING SUBPERITONEAL UTERINE MYOMATA.

Gyn. No. 12216. Path. No. 8825.

Cervical, interstitial, and subperitoneal myomata; necrosis of a large subperitoneal myoma, with abscess formation (Fig. 104); dense adhesions to the abdominal wall and to the omentum.

M. H., colored, aged twenty, married. Admitted July 5; died July 15, 1905. She has never been pregnant. For about ten months she has had definite pain of a sticking character in the right side of the abdomen. Early in the onset of the present trouble she felt a small mass in the right side, which has gradually increased in size. The pain has been associated at times with fever, more marked at the menstrual period. Four months ago the patient had considerable difficulty in getting the bowels to move; the abdomen was swollen for three or four weeks, and there was some vomiting. For the last three weeks the patient has had shortness of breath, dizziness, and night-sweats.

Operation, July 8, 1905. Hysterectomy was done in the usual manner. There was, however, considerable difficulty in liberating the most prominent myoma from the anterior abdominal wall. After liberation of the adhesions, pus commenced to trickle down from the surface of the myoma (Fig. 104). Care was taken to cover in the raw peritoneal area as far as possible by bringing the peritoneal surfaces together with catgut. On the sixth day after operation the patient developed partial intestinal obstruction. The patient did fairly well for two days, when she had a sudden attack of abdominal pain, colicky in character. The bowels had moved, and her temperature was normal. The bowels were moved again two or three times, but the distention increased. The temperature remained about 99° F.

July 15th. Exploratory laparotomy. When the patient was placed under ether, vomiting commenced. This was decidedly fecal in character, although there had been no vomiting in the ward. The abdominal cavity contained a moderate amount of clear serum and the intestines were everywhere distended. In the right quadrant they were fastened to the anterior abdominal wall at the

point at which the suppurating myoma had been adherent. The patient died almost immediately. At autopsy it was found that the intestine at the site of the adhesions was bent upon itself at a sharp angle. The highest postoperative temperature was 100.5° F. In this case it would have been wiser to

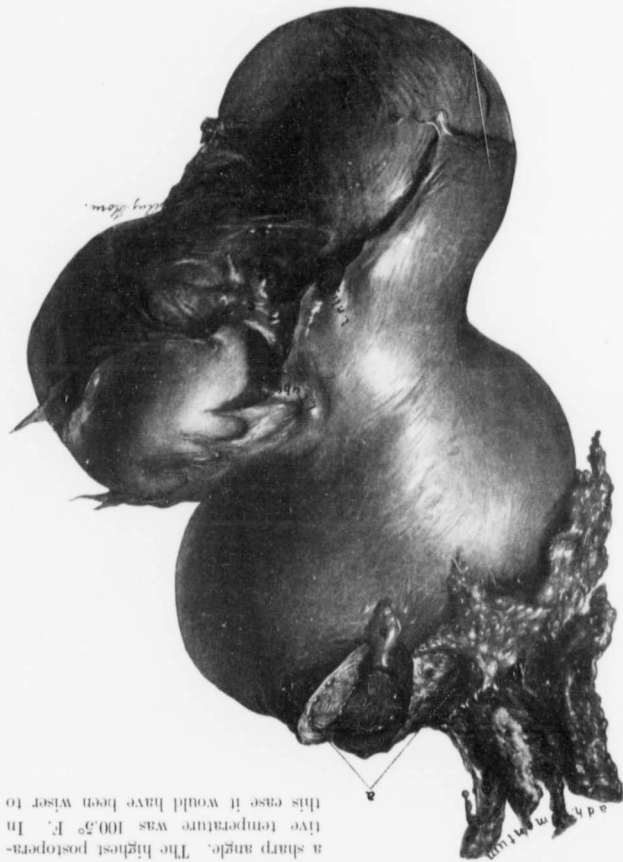

FIG. 104.—A SUPPURATING SERPENTIFORM MYOMA. (nat. size.)

(Gyn. No. 12216. Path. No. 8825. The uterus is seen from the side. The myoma to the left encircled on the bladder. That on the right was densely adherent. Occupying the upper part of the uterus is a large lobular myoma. Over the area indicated by a it was densely adherent to the anterior abdominal wall. At b pus is welling from the interior of the myoma. The omentum is adherent over a wide area.)

have done an exploratory operation earlier, when the patient was in good condition; the chance of success would then have been much greater.

Path. No. 8825. The specimen consists of a myomatous uterus approximately 12 x 12 cm. Projecting from the cervix, and extending down into the broad ligament, is a myoma 7 cm. in diameter. There is also one of smaller size, springing from one horn, and scattered throughout the walls of the uterus are several smaller nodules. The chief interest is centered in the subperitoneal nodule, 10 x 8 x 8 cm. Attached to its surface is a large tag of omentum. Pus flows from a rent in the myoma. On the surface, in the vicinity of the omental adhesions, is a raw area 4 x 4 cm. At this point the growth was adherent to the abdominal wall and had literally to be cut away. This subperitoneal myoma is in part covered with numerous adhesions. On section, it is found to have broken down over a considerable area. The myoma has evidently first undergone necrosis. We have an irregular cavity, 7 x 5 cm., filled with pus.

Histologic Examination.—Sections from the subperitoneal myoma which contained a quantity of pus show that a large portion has undergone hyaline degeneration and coagulation necrosis. Such areas are almost entirely devoid of cell-elements. The inner surface of the abscess wall is bathed in polymorphonuclear leukocytes and necrotic material. The underlying myomatous tissue, where hyaline degeneration has taken place, shows a good deal of small-round-celled infiltration and the formation of many new connective-tissue cells around the blood-vessels. There has, in this case, undoubtedly been a primary necrosis followed by infection.

Gyn. No. 3216. Path. No. 534.

A suppurating intraligamentary myoma (Figs. 105, 106); slight peri-oöphoritis on both sides.

A. S., white, aged forty-four, married. Admitted December 1, 1894; discharged January 1, 1895. The patient has had eight children and one miscarriage. Six years ago she noticed an enlargement of the left lower abdomen and there was some "sticking" pain. The tumor has gradually increased in size, both sides being now involved, and she has a constant dragging pain, occasionally sharp and bearing down in character. She is weak and has been having a septic temperature.

Operation, December 3, 1894. Hysteromyectomy. A densely adherent suppurating intraligamentary myoma was found and tapped, 4700 c.c. of creamy pus being removed. There were dense omental adhesions. The temperature, which was 100.6° F., rose a little, and then fell to normal. It rose again to 103° F. on the nineteenth day, without apparent reason, and after that became normal.

Path. No. 534. The specimen consists of the uterus, with a large tumor springing from its left side, and both tubes and ovaries. The tumor, which is globular, is 23 cm. in diameter. It springs from the left side of the uterus, apparently arising from the left uterine cornu, just beneath the tube (Figs. 105 and

106). It then passes out between the layers of the broad ligament, being covered with peritoneum. It is whitish yellow or pinkish in color, is covered with numerous adhesions, and is adherent to the omentum over an area 8 x 8 cm. On pressure it is somewhat elastic. On section, the tumor is seen in places to be covered with a layer of muscle, 4 mm. in thickness. This covering gradually disappears as the tumor passes toward the broad ligament. The tissue of the tumor is grayish-pink in color and is very edematous. It is divided up into large and small, irregular oval masses. These contain numerous lymph-spaces, the largest of which is 5 mm. in diameter. In the center of the tumor is a cavity, 15 cm. in diameter, and having somewhat irregular and ragged walls. The inner surface is covered with a yellowish membrane, 1.5 mm. in thickness. Attached to this membrane are many whitish-

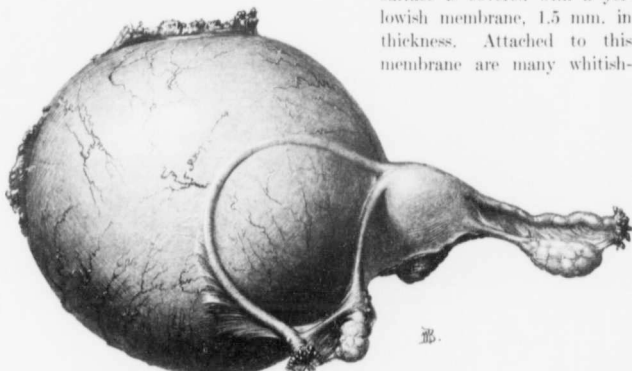


FIG. 105.—AN INTRALIGAMENTARY SUPPURATING MYOMA. ($\frac{1}{2}$ nat. size.)

GYN. No. 3216. Path. No. 534. Springing from the left of the uterus is a large globular myomatous tumor, that shows dense adhesions on its upper and outer surfaces. The uterus and right appendages are normal. The left tube is markedly elongated, as the result of stretching by the tumor, and the left utero-ovarian ligament is much lengthened. For the interior of the myoma see Fig. 106.

yellow flakes, resembling those found in a purulent peritonitis. The cavity contains 3000 c.c. of dirty, bluish-green pus, which microscopically is found to be composed of polymorphonuclear leukocytes and degenerated cells containing fat-droplets and debris. Numerous diplococci are also seen. Coursing over the outer surface of the tumor is the left Fallopian tube, which takes a curve directly outward, backward, and then inward. The uterus and the appendages on the opposite side are of little interest.

Histologic Examination.—The large tumor everywhere shows moderate hyaline degeneration. In the vicinity of the cavity the muscle is very rich in blood-vessels, many of which have undergone complete hyaline degeneration. In some places, however, the endothelium still persists. The muscle-fibers in this

region stain much more deeply than in the outer portion of the tumor. In many places the muscle shows aggregations of newly formed connective-tissue cells. Still farther inward the entire muscular substance has undergone hyaline degeneration, and scattered throughout this hyaline material are a moderate number of polymorphonuclear leukocytes. Just beneath the inner surface the tissue has undergone coagulation necrosis. The inner surface of the cavity at such points is covered with polymorphonuclear leukocytes. In other places the tissue presents a typical granulation surface. Many polymorphonuclear leukocytes, both on the surface and in the depth, are swollen and appear to contain fat-droplets. This is a most striking example of a suppurating intraligamentary myoma.

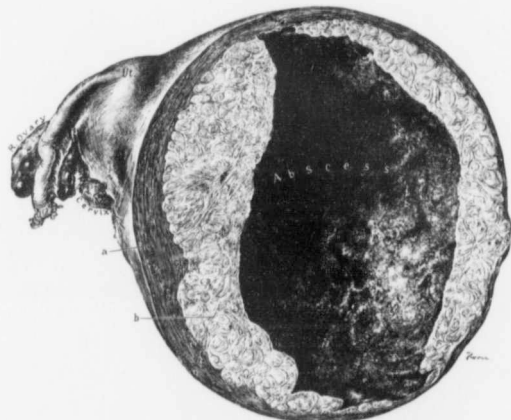


FIG. 106.—A SUPPURATING INTRALIGAMENTARY MYOMA. (3 nat. size.)

Gyn. No. 3216. Path. No. 534. This represents the posterior half of the tumor seen in Fig. 105. The uterus and right appendages are normal. *a* represents the outer covering of normal uterine muscle; *b*, myomatous tissue. Over half the tumor has been converted into an abscess sac.

Gyn. No. 15281. Path. No. 13121.

A suppurating subperitoneal pedunculated myoma, which ruptured and formed an abscess between the omentum, small bowel, and right lateral abdominal wall (Figs. 107, 108).

A. W., married, aged twenty-one, colored. Admitted November 13; discharged December 17, 1908. She complains of a "knot" in the right side of the abdomen. The patient has been married ten months and has one child, a month old. In March, 1908, she experienced sharp bearing-down pain in the right side of the pelvis, and at that time noticed a lump which was apparently about 6 cm. in

diameter occupying the right iliac fossa. The pain was dull, aching in character and constant. Since then the pain has increased more or less and has been aggravated on many occasions by exertion. There was no increase in the size of the tumor until the termination of pregnancy. She has complained of no back-ache, but of much headache. Her labor, one month ago, was perfectly normal. She states that during the early pregnancy there was occasionally fever and during the last few days she has had considerable nausea and vomiting.

On admission she appears to be quite sick. The tongue is brownish in color and coated. The pulse is of fair volume, 136 to the minute.

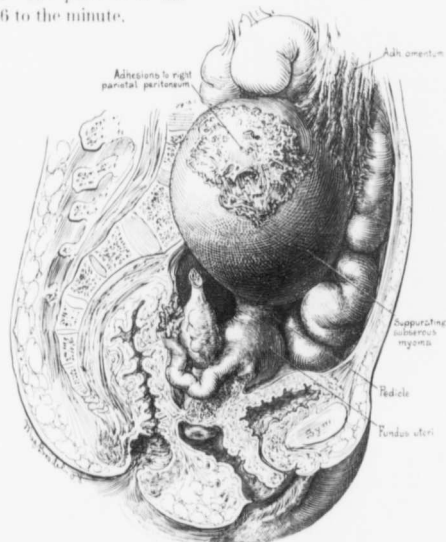


FIG. 107.—A SUPPURATING SUBSEROSAL MYOMA.

GYB. No. 15281. Path. No. 13121. The uterus is normal in size. Attached to the fundus is a pedunculated myoma which had suppurated and ruptured. On the outer side it was adherent to the abdominal wall, on the inner side, to the omentum and small bowel. For the interior of the myoma see Fig. 108.

Abdominal Examination: Over the lower two-thirds, on the right side of the abdomen, is a distinct oval prominence, and on palpation this area is firm, slightly tender, and has a brawny feel. No fluctuation can be made out, but there is a slight yielding of the tumor. This mass is firmly fixed. On vaginal examination nothing can be detected.

Her hemoglobin was 80 per cent.; leukocytes, 24,000. An incision was made through the right rectus and the mass immediately exposed. Over its surface

the omentum was firmly adherent. On its inner side were adherent intestinal loops. On its outer side it was firmly fixed to the lateral abdominal wall. The mass was carefully walled off on all sides and the omentum then gradually withdrawn. There was an immediate escape of very fetid pus. This came from the inner side of the mass and also from the

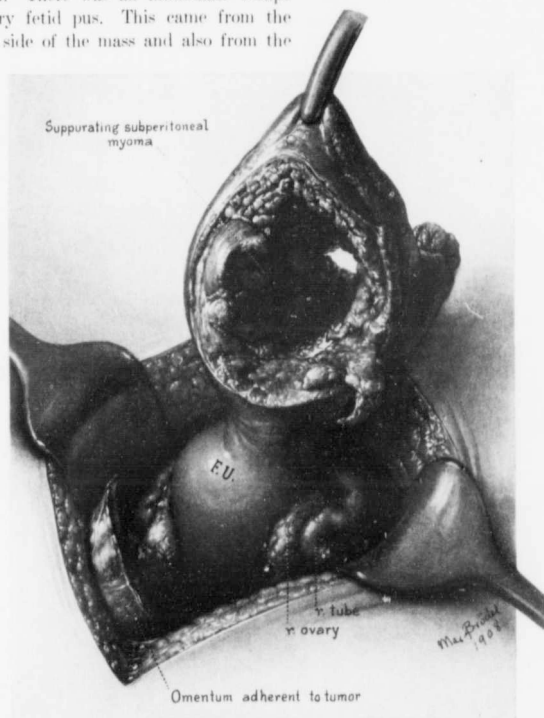


FIG. 108.—A SUPPURATING SUBPERITONEAL MYOMA.

Gyn. No. 15281. Path. No. 13121. The uterus was normal in size, but on palpation a few small myomata could be felt. Attached to the fundus by a broad pedicle was a suppurating myoma. During pregnancy it had been carried upward and lay above and to the right of the umbilicus. Here it had become fixed. Its center was filled with pus and necrotic tissue. It had ruptured, but was walled off on the median and anterior surfaces by the omentum and small bowel; on the outer side, by the lateral abdominal walls. The appendages were normal.

vicinity of the abdominal wall. On being gradually loosened up it was found to be a myoma which was attached to the uterus by a rather broad pedicle (Fig. 107). The tumor was freed above and laterally and then the uterus was drawn

out. The uterus, tubes, and ovaries were perfectly normal. The pedicle of the myoma was cut across, and the raw area closed. A small drain was laid in the pelvis and also in the pocket from which the tumor had been removed. The tissues in all directions were hard and edematous, the omentum was markedly thickened, and the abdominal wall roughened. The intestines were covered with a pyogenic membrane.

November 26th: The patient is in excellent condition. Her temperature and pulse are normal. The abdominal wound has to a great extent closed, but there is considerable discharge, which seems to be fecal in character. We are not at all surprised at this, on account of the implication of the intestinal loops in the abscess wall. The wound closed completely, and the patient was discharged well on December 17, 1908.

Path. No. 13121. The specimen consists of a myoma approximately 8 cm. in length and 7 cm. in diameter. This, on its outer surface, presents a rather worm-eaten appearance, especially where it was adherent to the abdominal wall (Fig. 108). The raw area indicating the site of the pedicle is 4 cm. in length and 2.5 cm. broad. The entire central portion of the tumor is irregular, yellowish-white in appearance, and has trabeculae extending from side to side over a considerable area. The walls vary from 2 cm. to not more than 1 mm. in thickness and in some places have given way entirely. Occupying the central portion are grayish-yellow necrotic masses. The largest of these measures 2.5 x 5 cm. Filling in all the interstices of the center is grayish-yellow, offensive pus. This had trickled out between the tumor and the lateral abdominal wall and likewise between the bowel and the omentum on the inner aspect.

Histologic Examination.—Sections from some portions of the growth show the typical myomatous picture. At other points there is marked hyaline transformation, with liquefaction. The walls of the abscess are composed of typical granulation tissue, which is very vascular and in places hemorrhagic. Scattered throughout the walls are many polymorphonuclear leukocytes and small round cells. The growth is essentially a myoma which has undergone suppuration in its central portion.

Gyn. No. 7549. Path. No. 3799.

Small subperitoneal and interstitial uterine myomata; large sloughing subperitoneal myoma, communicating with the colon (Fig. 109).

K. H., aged thirty-five, white, single. Admitted February 1; discharged March 22, 1900. Occupying the lower and median portions of the abdomen is a large irregular mass. This is smooth, hard, freely movable from side to side, and continuous with a large pelvic growth.

Operation, February 3, 1900. Hysteromyectomy. On section of the abdomen the transverse colon was found so firmly adherent to the tumor that separation was impossible. The cervix was at once located, cut across, and the uterus turned out so that the adhesions were gotten at from the under surface.

The myoma contained an abscess cavity which communicated with the colon. The operation is described in detail on p. 613. The patient had a fecal fistula when she left the hospital. This is hardly to be wondered at, considering the markedly indurated opening noted in the cecum at operation.

Path. No. 3799. The greater part of the myoma lies above the uterus. In its upper part is a large sloughing cavity which opens on the surface and has communicated directly with the bowel.

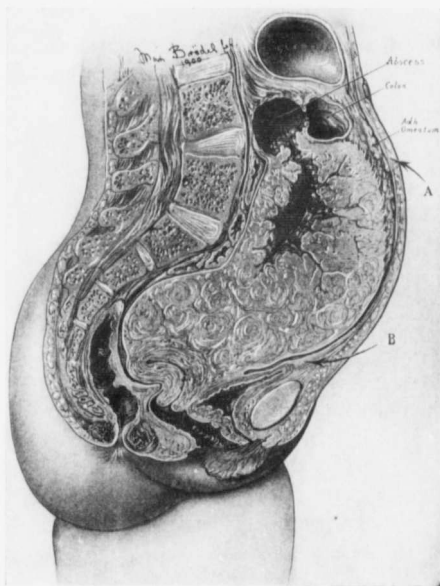


FIG. 109.—A SUPPURATING MYOMA OPENING INTO THE COLON

Gyn. No. 7549. Path. No. 3799. Occupying more than half of the abdomen is a myomatous tumor. Its upper part contains an irregular abscess cavity which empties into the colon. For a full description of the operative difficulties in this case see p. 613. (After Howard A. Kelly.)

On histologic examination portions of the myoma lining the abscess cavity are entirely necrotic. The surface is covered with many polymorphonuclear leukocytes, which also have infiltrated the underlying tissue for a considerable distance. Apart from this no nuclei are anywhere demonstrable. Had we not first cut across the cervix and then attacked the cecal adhesions from behind, the case would have been inoperable.

Path. No. 605.

A suppurating subperitoneal uterine myoma.

Patient of Dr. Houston, Troy, N. Y. The tumor, a subperitoneal myoma that contained 10½ quarts of pus, had been obtained from a woman fifty-five years of age, who had carried it for thirty years. The specimen received by us for examination in February, 1895, consisted of a portion of the wall of this abscess.

Histologic Examination.—The tissue is composed of non-striped muscle-fibers cut longitudinally and transversely. It has a fairly rich blood-supply. Along the outer margins of the tumor the muscular tissue stains poorly. There is a moderate nuclear fragmentation and marked polymorphonuclear infiltration. The inner surface is entirely necrotic and devoid of nuclei. Scattered throughout this necrotic material are masses of micro-organisms which, when stained, prove to be cocci. They are arranged singly or in short chains.

SUPPURATING INTERSTITIAL UTERINE MYOMATA.

In Gyn. No. 8767 the globular uterus was 18 cm. in diameter. The great increase in size of the abdomen was due to an interstitial myoma, 17 cm. in diameter, occupying the posterior wall. The uterine cavity was 15 cm. in length, and its mucosa scarcely 1 mm. in thickness. At one point in the posterior wall the mucosa over an area 7 x 5 cm. had entirely disappeared and the portion of the myoma projecting through was brownish in color, roughened, and disintegrating (Fig. 111). The entire myoma was rather soft.

In Gyn. No. 5093, as soon as the cervix was cut at operation, a stream of brownish, tenacious mucus poured out. The uterus had been converted into a globular tumor 22 cm. in diameter. Occupying the anterior wall was a large myoma which was undergoing necrosis. The uterine cavity was 16 cm. long and at the fundus reached 5 cm. in breadth. At two points over the large myoma the mucosa had disappeared and the underlying myomatous tissue was dark bluish red and necrotic. The larger area, 4 cm. in its longest diameter, had sharply defined rounded margins (Fig. 112).

In Case 5617 the patient gave definite signs of sepsis. The uterus was globular and averaged 22 cm. in diameter. The uterine cavity was greatly enlarged. Occupying the anterior wall was a myoma, 17 cm. in diameter, over which the mucosa was atrophic. Near the center of the cavity the tumor was devoid of mucosa over an area 10 cm. in diameter and here it had been transformed into a ragged, sloughing mass.

In San. No. 1847 the patient, prior to operation, had had chills and fever. The uterus measured 10 x 9 x 8 cm. There was a diffuse myomatous thickening of the uterus, a submucous myoma, 2.5 cm. in diameter, and an interstitial myoma which had undergone almost complete hyaline transformation. The central portion of this had broken down and opened into the uterine cavity. This

cavity on histologic examination presented the typical appearance of an abscess wall.

In Case 14942 an interstitial myoma had been detected three years previously. Shortly before operation the patient lost 26 pounds. Fully one-fourth of the interstitial myoma had been converted into an abscess sac (Fig. 110).

The suppurative changes in Case 7158 were very extensive. The uterus was apparently about the size of that of a five months' pregnancy. As the hand was passed around to the right of the umbilicus there was an escape of several ounces

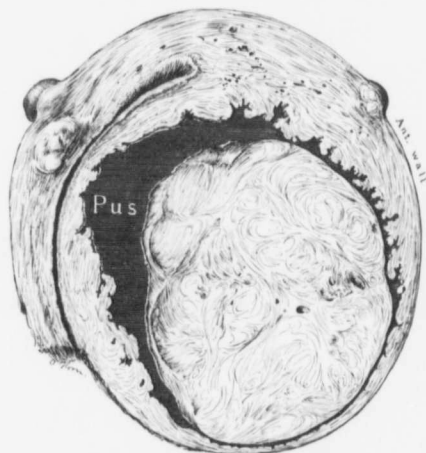


FIG. 110.—A SUPPURATING INTERSTITIAL MYOMA. ($\frac{1}{3}$ nat. size.)

Gyn. No. 14942. Path. No. 12963. The patient, admitted July 2, 1908, was thirty-six years old and had noticed the tumor for three years. Recently she had had much pain in the lower abdomen and had lost 26 pounds. At operation the omentum was densely adherent to the uterus. The myomatous uterus reached 8 cm. above the umbilicus. The enlargement was due chiefly to an interstitial and partly submucous myoma, 9 x 12 x 12.5 cm., occupying the anterior wall. Fully one-fourth of the myoma consisted of an abscess, the margins of which were very irregular. The patient made a good recovery.

of thick green pus with a garlicky odor. The uterus was approximately 19 x 16 x 12 cm. It was everywhere covered with vascular adhesions. On the anterior surface was a necrotic area, 10 x 8 cm., greenish in color, and surrounded by dense adhesions. Its edges were very irregular and the necrotic surface was ulcerated to a depth of 5 mm. It was from this area that the pus escaped. The great increase in size of the uterus was due to a large interstitial myoma situated in the anterior wall. This was dark blue in color, and at the point at which the ulceration was noted had reached the peritoneal surface. The tumor was soft and pultaceous in character and emitted an offensive odor. The uterine cavity

was 11 cm. in length. The anterior wall was perforated over an area 5 x 4.5 cm. (Fig. 113). The margins of this opening were sharply defined, and the floor of the cavity was uneven and covered with greenish-yellow pus. The necrotic material had not only broken through the peritoneal surface, but also into the uterine cavity.

Gyn. No. 8767. Path. No. 4959.

An interstitial uterine myoma at one point projecting into the uterine cavity (Fig. 111), and undergoing disintegration; slight pelvic adhesions.

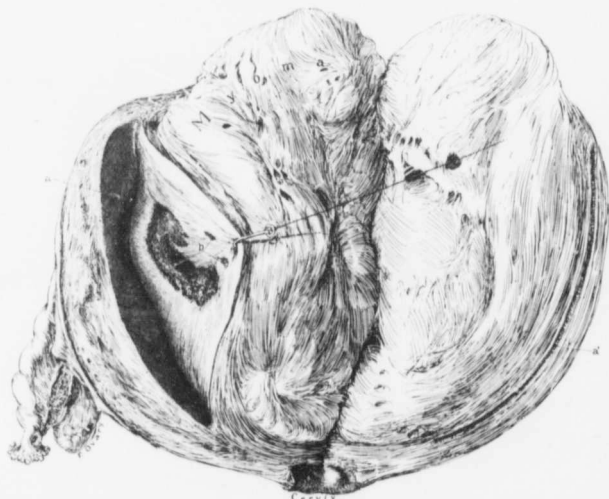


FIG. 111.—SLIGHT SUPPURATION OF AN INTERSTITIAL MYOMA WITH PERFORATION INTO THE UTERINE CAVITY.
($\frac{1}{2}$ nat. size.)

Gyn. No. 8767. Path. No. 4959. Occupying the posterior wall is a myoma 17 cm. in diameter. *a* and *a* indicate the extreme depth of the uterine cavity. At the points indicated by *b* the mucosa had disappeared and here the underlying myomatous tissue was brownish in color, roughened and disintegrating. On microscopic examination this tumor was found to have undergone marked hyaline degeneration and there was considerable polymorphonuclear infiltration.

E. P., aged forty-four, colored. Admitted May 16; discharged June 15, 1901. Complaint: An abdominal tumor and swelling of the legs and ankles. Her menses began at fourteen and were regular up to seven years ago. Since then the periods have been too frequent. At present bleeding comes on three or four times a month and varies from a small amount to a flow lasting from eight to ten days. She has had ten children and two miscarriages. For nine

years there has been a white, non-irritating discharge, more profuse after the menses, and she has noticed that the abdomen has been enlarged. The patient says the tumor at the present time is much smaller than it was two years ago. During the past three months she has had frequent urination and painful defecation. For three years she has had edema of the legs, especially of the left. Hemoglobin, 51 per cent.

Operation. Panhysterectomy. When the patient was discharged, the left leg was still rather edematous and painful, but the hemoglobin had risen to 70 per cent.

Path. No. 4959. The specimen consists of a globular uterus, 18 cm. in diameter, and also of the lateral structures. The great increase in size of the uterus is due to an interstitial myoma, approximately 17 cm. in diameter, occupying the posterior wall. The uterine cavity is 15 cm. in length and its mucosa is scarcely 1 mm. in thickness. The chief point of interest in this case lies in the fact that at one point in the posterior wall the mucosa over an area 7 x 5 cm. has entirely disappeared (Fig. 111), and the portion of the myoma projecting through is brownish in color, somewhat roughened in appearance, and disintegrating. The myoma itself is rather soft. The appendages offer nothing of interest.

Histologic Examination.—The mucosa lining the uterine cavity is perfectly normal, save in the vicinity of the area, where the myoma projects through. As we approach this the mucous membrane becomes thinner and thinner, until it disappears and the myomatous tissue, which has undergone almost complete hyaline degeneration, forms the floor of the cavity. Scattered throughout the hyaline material are quite a number of polymorphonuclear leukocytes. It is astonishing to see such a mild degree of inflammation where so much loss of substance has taken place.

Gyn. No. 5093. Path. No. 1599.

An interstitial uterine myoma suppurating and opening into uterine cavity (Fig. 112).

M. B., aged forty-three, white, single. Admitted March 12; discharged May 3, 1897. The patient first noticed an abdominal tumor six years ago. This has grown steadily. It is slightly sore during the menstrual period, and at these times is increased somewhat in size. On examination under ether the lower part of the abdomen is found filled with a hard, nodular, partly mobile tumor about the size of a uterus in the seventh month of pregnancy.

Operation. Hysteromyomectomy. The tumor was delivered with great difficulty and was extremely vascular. On section into the cervical canal, a stream of brown tenacious mucus poured out. One-fifth of the left ovary was left behind. Convalescence was interrupted by the formation of a pelvic abscess, necessitating drainage through the vagina. There was also slight suppuration from the abdominal incision.

Path. No. 1599. The specimen consists of the enlarged uterus to which the

right tube is attached. The uterus has been converted into a globular tumor, 22 cm. in diameter. The posterior surface is covered with numerous vascular adhesions—the anterior is smooth and glistening. Occupying the anterior uterine wall is a large myoma, which is undergoing necrosis. The uterine cavity has been drawn out by the tumor; it is 16 cm. in length and 5 cm. in breadth at the fundus. The posterior surface of the uterine cavity is smooth and glistening, but is almost entirely devoid of mucosa, the atrophy being evidently due to pressure. On the anterior surface of the uterine cavity are two oval areas with sharply

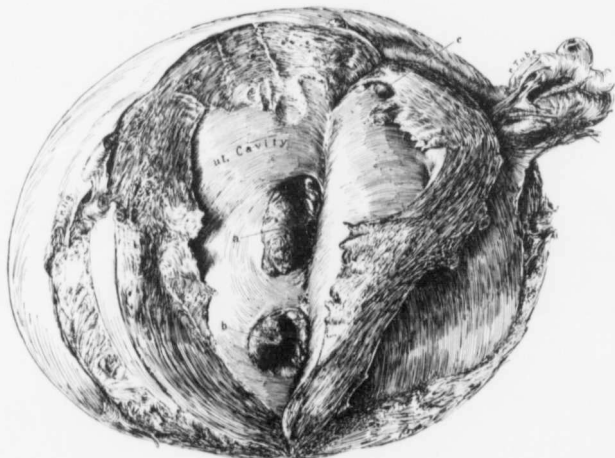

FIG. 112.—A SUPPURATING INTERSTITIAL MYOMA OPENING INTO THE UTERINE CAVITY. ($\frac{1}{3}$ nat. size.)

Gyn. No. 5003. Path. No. 1599. The uterus had been converted into a globular tumor 22 cm. in diameter, the increase in size being due chiefly to a large myoma occupying the anterior wall. At *a* and *b* the myoma, which was partly necrotic, had broken through into the uterine cavity. The myomatous tissue forming the floor of these cavities was dark bluish red and necrotic. *c* is a small polyp.

circumscribed, smooth margins, and a central portion consisting of dark, bluish-red necrotic tissue (Fig. 112). The larger area is 4 cm. in its longest diameter. The mucosa over the remaining portion of the anterior wall is smooth, but much thinned out.

Gyn. No. 5617. Path. No. 1962.

A suppurating interstitial uterine myoma; chronic endometritis; normal appendages.

H. J., colored, aged forty, married. Admitted October 18; died October 21, 1897. The patient has had two children. For the past year she has had

an almost continuous hemorrhage, at times oozing in character, at other times very profuse, with severe pain. The flow has been offensive. Five years ago she began to have pain in the left side and a year later noticed a tumor in the abdomen. This has grown steadily. She is weak, has shortness of breath and occasionally severe abdominal pains.

Operation, October 21, 1897. Hysteromyomectomy. The patient was very weak, the pulse being 130 and feeble before operation. She had had bronchitis. Chloroform was first used, and the respirations stopped. The patient was resuscitated and ether employed. The pulse rose to 168, grew weaker and weaker and the patient died on the table. Her temperature before operation ranged from 99.8° to 104.2° F.

Path. No. 1962. The specimen consists of the uterus and its appendages. The uterus is globular, resembling the pregnant womb, and averages 22 cm. in diameter. Posteriorly, it is covered with numerous vascular adhesions. The under cut surface is 7 cm. in diameter. The uterine cavity is greatly enlarged, being nearly 22 cm. long and 13 cm. broad at the fundus. The posterior wall averages 3 cm. in thickness, but the anterior wall contains a tumor 17 cm. in diameter. This is in part covered with mucous membrane which is thinned out and hemorrhagic. About the center of the cavity the tumor has broken through the mucosa over an area 10 cm. in diameter, and a large, ragged, sloughing mass fills the cavity. The mucosa covering the posterior wall is also atrophic and hemorrhagic.

Histologic Examination.—Cover-slips from the necrotic mass show a few cocci arranged in rows, also short bacilli in clumps and two or three in a row. The surface of the myoma where it projects into the uterine cavity shows disintegration and is completely necrotic, consisting of homogeneous granular and poorly stained material containing polymorphonuclear leukocytes and fragmented nuclei. The deeper portion of the myoma contains areas of coagulation necrosis. The uterine mucosa presents none of the normal elements, but consists of granulation tissue made up of young connective-tissue cells, young blood-vessels, which rise to the surface, and a dense zone of small round cells. The surface is covered with leukocytes embedded in fibrin.

San. No. 1847. Path. No. 8346.

Diffuse thickening of the uterine wall; suppuration of an interstitial myoma.

W. J., white, married, aged thirty-four. Admitted March 1; discharged April 12, 1905. The patient has had eleven children and has had profuse menstruation for the last year. She is very sallow in appearance and has a hemoglobin of 50 per cent. After hysterectomy the patient made a very satisfactory recovery.

Path. No. 8346. The specimen consists of the uterus, which is about twice its natural size. This case is reported in full in "A denomyoma of the

Uterus," p. 230. Briefly, it consists of an interstitial myoma which has undergone almost complete hyaline transformation and then suppuration. On histologic examination the inner surface of this contains many polymorphonuclear leukocytes. The offensive discharge was evidently due to the degeneration.

Gyn. No. 7158. Path. No. 3431.

A large interstitial necrotic myoma; perforation of the uterus anteriorly, formation of abscess on its surface and ulceration into the uterine cavity (Fig. 113), giving rise to a purulent vaginal discharge.

O. S., aged twenty-three, white, married. Admitted August 26; died August 29, 1899. The patient had had one child and no miscarriages. She was profoundly emaciated and had a pulse of from 120 to 130; the temperature varied from 100° to 103° F. She was in a desperate condition when put on the table.

Operation. The uterus was apparently about the size of that of a six months' pregnancy. When the hand was passed around to the right of the umbilicus, there was a free escape of several ounces of thick green pus having a distinctly garlicky odor. This was removed as fast as possible, to prevent general infection. The fundus was drawn out with considerable difficulty, and a large necrotic area surrounded by adhesions was found on the anterior surface. The uterus was removed in the usual way, the abdomen drained, and an infusion of saline solution given. The patient, however, was in a desperate condition, showed but little improvement, and died on the third day.

Path. No. 3431. The specimen consists of a large globular myomatous uterus with its tubes and ovaries. The uterus is approximately 19 x 16 x 12 cm. Over its entire surface it is injected and covered with vascular adhesions. On the anterior surface is a necrotic area, 10 x 8 cm., greenish in color and surrounded by dense adhesions. The edges are irregular and the necrotic surface has ulcerated to a depth of 5 mm. The great increase in size of the uterus is due to a large interstitial myoma situated in the anterior wall. This is dark blue in color and at the point at which ulceration was noted has reached the peritoneal surface. It is soft and pultaceous in consistence and emits an offensive odor. The myomatous arrangement is still visible. The uterine cavity is 11 cm. in length and the mucosa, approximately 2 mm. thick, is deeply injected and in places shows a yellowish-brown mottling. Situated in the anterior uterine wall and opening directly into the cavity is a heart-shaped perforation, 5 x 4.5 cm. (Fig. 113). Its floor is uneven and covered with greenish-yellow pus. Its margins are slightly raised and sharply defined. The right tube is covered with adhesions. Its fimbriated end is patent. The ovary, apart from adhesions, is normal. The appendages on the left side are likewise covered with adhesions, but are otherwise unaltered.

Histologic Examination.—Sections from the uterine mucosa near the opening in the anterior wall show that it is composed almost entirely of granulation

tissue, which is well organized and shows very little polymorphonuclear infiltration. Here and there the surface epithelium is to a slight extent preserved, but at such points has proliferated. A few glands are still visible, but in most of them the gland contour is distorted and the cells stain palely and are swollen. At the edge where the perforation has taken place the surface is covered with polymorphonuclear leukocytes, and the tissue consists essentially of granulation tissue devoid of gland elements and containing many polymorphonuclear leukocytes. The floor of the area of ulceration consists essentially of necrotic myomatous

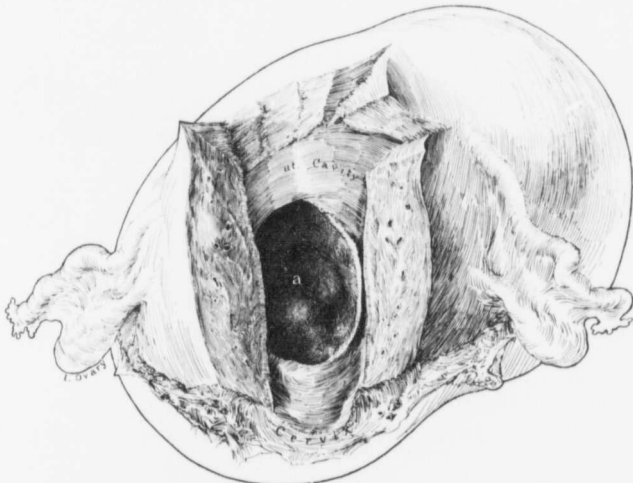


FIG. 113.—A LARGE SUPPURATING INTERSTITIAL MYOMA OPENING INTO AND INFECTING THE PERITONEAL CAVITY AND ALSO DRAINING INTO THE CAVITY OF THE UTERUS. (1 nat. size.)

GYN. No. 7158. Path. No. 3431. The uterus was approximately 19 x 16 x 12 cm. On the anterior surface as seen from the history, was a foul necrotic area 10 x 8 cm., where the myoma had ulcerated through to the surface.

At a the myoma had ulcerated through into the uterine cavity. This cavity measured 4.5 x 5 cm. and its floor was covered with greenish-yellow pus. The entire myoma was dark blue in color, soft and pulsatious in character, and emitted an offensive odor.

tissue containing nothing but fragmented polymorphonuclear leukocytes. Sections from the outer surface of the uterus, where the ulcerated area was noted, show necrotic myomatous tissue containing quantities of polymorphonuclear leukocytes. It is interesting to note that numerous necrotic muscle nuclei contain calcareous plates. Sections from other portions of the myoma show that it has undergone almost complete coagulation necrosis. It is most exceptional to find such a punched-out area of ulceration communicating with the uterine cavity. In brief, we have a large necrotic myoma, with ulceration on its anterior

peritoneal surface and a corresponding area of ulceration on its posterior surface, communicating with the uterine cavity by the large opening above mentioned.

CAUSE OF SUPPURATION IN UTERINE MYOMATA.

It will be seen that suppuration in interstitial and subperitoneal myomata is a rare occurrence. In the majority of the cases hyaline degeneration is present. This is due to a diminished blood-supply. In the subperitoneal variety infection from the intestine was evidently the cause in three of the cases. Here the degenerated myomata had become adherent to the cecum or small bowel. As the intestinal nourishment to the myoma became more and more abundant, the intervening walls gradually became thinner and thinner until the cavity in the myoma opened directly into the bowel. The constant passage of feces into and out of the myoma cavity naturally converted it into an abscess-sac.

In those cases in which the myomata were entirely free from the intestine hyaline degeneration had likewise evidently first taken place, but why they became infected later it is difficult to say.

Interstitial myomata that impinge on the uterine cavity are easily infected when there is focal necrosis or hyaline degeneration in portions of the myoma near the uterine cavity and an infective agent in the uterine mucosa. Infection readily follows on account of the poor blood-supply of the average myoma.

Suppuration in a myoma must not be confused with the condition in such cases as A. W. (Path. No. 8932), where there were tubo-ovarian abscesses, and as a result secondary and encysted abscesses developed in the spaces between contiguous myomata. Here the purulent process was confined almost entirely to the outer surfaces of the tumors and not to their interiors.

The appearance of the myoma that has undergone marked hyaline degeneration very often simulates abscess formation so closely that it is impossible to render an absolute diagnosis without making sections. Where simple hyaline degeneration is present, no nuclei are visible. Where abscess formation has taken place, the characteristic polymorphonuclear leukocytes are in evidence.

SYMPTOMS OF SUPPURATING UTERINE MYOMATA.

With the advent of suppuration in the uterine myomata the symptoms may undergo a marked change. A sticking or lancinating pain is noticed in the lower abdomen, and the patient may have chills and fever, at times accompanied by night-sweats. One of the more important late phenomena is the sallow color. This differs entirely from the pallor that is so frequently noted where there has been great loss of blood from submucous myomata. If such septic absorption has taken place, the patient often grows very weak and the tumor may apparently diminish somewhat in size.* With the septic absorption renal changes may

*Leukocytosis in myoma cases, if there is no offensive uterine discharge, usually indicates either a suppurating myoma or a purulent accumulation involving the tubes, the ovaries, or both. An ordinary myomatous uterus does not give rise to a leukocytosis.

be induced, recognizable by the presence of albumin and casts in the urine. Where the suppurating myomata open into the uterine cavity, there is a profuse foul-smelling vaginal discharge.

TREATMENT.

The patient's resistance is naturally much reduced, and the pulse, just before operation, may be very rapid, as is so often the case when pus is present. Our object should be to remove the uterus just as soon as feasible, as without operation the condition will steadily grow worse. In these cases the purulent process is usually very active, and consequently the dangers of infection are great.

RESULTS AFTER OPERATION FOR SUPPURATING INTERSTITIAL OR SUBPERITONEAL MYOMATA.

Gyn. No.	12216	Died of intestinal obstruction on sixth day
" "	3216	Recovered.
" "	7549	Recovered.
" "	8767	Recovered.
" "	5093	Recovered (postoperative pelvic abscess).
" "	5617	Died on table (desperate condition before operation).
" "	S. 1847	Recovered.
" "	7158	Died on third day (peritonitis before operation).
" "	9078	Recovered.
" "	14942	Recovered.
" "	15281	Recovered.

We have given this table to show the high mortality in such cases. The result in Case 12216 is open to criticism, as the abdomen should have been explored earlier and the obstruction relieved. In Case 5617 the woman was in a desperate condition before operation, and the fatal result in Case 7158 is what might naturally have been expected. In the majority of such cases it is well to drain the pelvis through the vagina, and in some cases also from above, treating the entire pelvic content as a most dangerous area of infection.

NECROTIC MYOMATA.

Necrosis is fairly common; it is liable to occur in subperitoneal, interstitial, or submucous myomata, but more especially in sloughing submucous nodules. In a few instances we have noted it in very small myomata, but it is more prone to develop in large tumors.

The necrotic areas are recognized as dirty gray, grayish-brown, or dark reddish-blue patches in the myoma. Such areas are clearly outlined, but the contrast between the myomatous tissue and the degenerated portion is not nearly as clean cut as in the cases where hyaline degeneration exists. In the necrotic areas the muscular striation is usually still visible, but the tissue is softer than usual. The necrosis is usually in the central portion of the tumor, but is occasionally noted near the surface, as in Case 10883 (Path. No. 7089). It may

be limited to one area, or the myoma may contain several foci of degeneration. Hyaline degeneration and necrosis are often noted side by side in the same tumor.

Histologic Examination.—Where the necrotic area is present, the muscle-fibers usually still persist, but fail to take the stain. As a rule, the field is devoid of any living cells, but occasionally a few muscle nuclei may still be visible around the blood-vessels, as noted in Case 3199 (Path. No. 524). In a few cases fragmented nuclei have been detected in the necrotic area. This was the case in Gyn. No. 3199 (Path. No. 524) and Gyn. No. 3296 (Path. No. 580).

As noted on page 127, lime salts may be deposited in the necrotic areas.

It is exceptional to note any inflammatory reaction in the necrotic areas, except in submucous myomata. Case 3199 (Path. No. 524), however, proved an exception, as some polymorphonuclear leukocytes were noted.

The coagulation necrosis is undoubtedly caused by a partial cutting off of the myoma's blood-supply.

CHAPTER X.

MYOMATA ASSOCIATED WITH MALFORMATIONS OF THE UTERUS.

We have encountered three cases of myoma coming under this category:

1. Numerous discrete myomata in a uterus containing two distinct uterine cavities and two cervical canals.
2. A diffuse adenomyoma in one horn of a bicornate uterus.
3. A submucous adenomyoma developing in a uterus in which there was apparently only one fundus, with a septum dividing the cervix into two canals, and a double vagina.

Gyn. No. 11694. Path. No. 7953.

A large myomatous tumor, on section showing two distinct uterine cavities (Fig. 114).

V. H., aged thirty-seven, white, single. Admitted November 16; discharged December 10, 1904. The patient has always been nervous and subject to constipation and headaches. One year ago she had an attack of vomiting and sharp pain in the region of the appendix. She noticed a lump in the abdomen at that time. This has grown until it has reached its present size. On examination, the pelvis is filled with a large multinodular mass reaching 10 cm. above the umbilicus. At operation dense adhesions were found about the pylorus and gall-bladder and in the region of the appendix. Hysteromyectomy was performed.

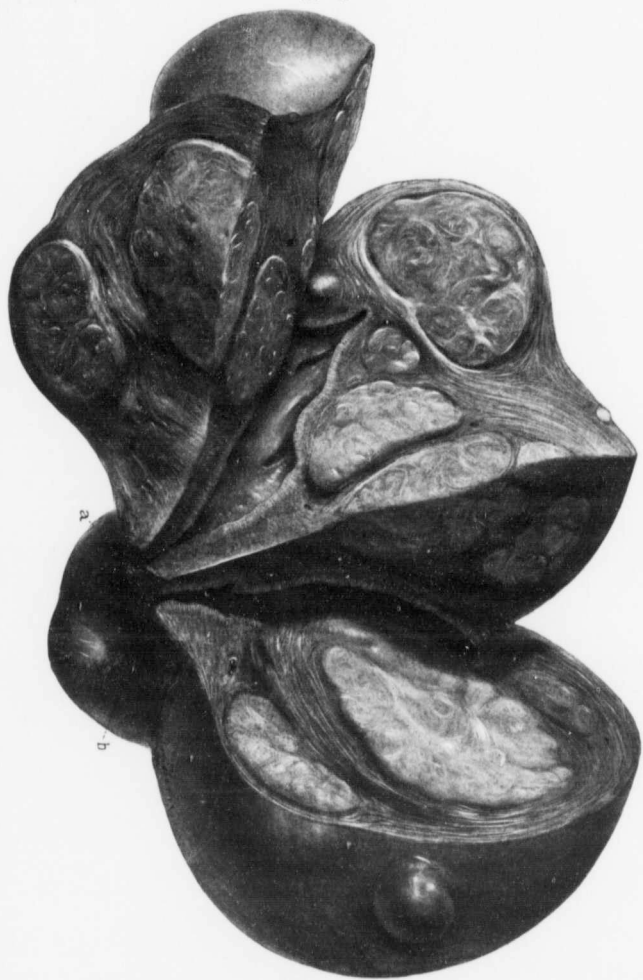
Path. No. 7953. The uterus contains many nodules and measures approximately 15 x 17 cm. On section, two definite uterine cavities are disclosed, as seen in Fig. 114. The mucosa lining each cavity shows little or no change.

Gyn. No. 10314. Path. No. 6531.

Double cervix, double vagina; submucous adenomyoma.

E. K., white, aged fifty, married. Admitted March 7; discharged April 17, 1903. The operation consisted in splitting the vagina and cervical septum and in the removal of a submucous myoma.

Path. No. 6531. The myoma is approximately 7 x 7 x 11 cm. Scattered throughout it are numerous irregular islands of mucosa; at other points are spaces, fully 8 x 2 mm., lined with mucosa which almost completely fills the cavity. These are instantly recognized as miniature uterine cavities. Some of these spaces are pale and filled with chocolate-colored contents—evidently old menstrual blood.



The growth on histologic examination presents the typical adenomyomatous appearance. It is described in detail in "Adenomyoma of the Uterus," p. 162 (Fig. 47).

Gyn. No. 11572. Path. No. 7800.

Diffuse adenomyoma in one horn of a bicornate uterus.

This case is also described in detail in "Adenomyoma of the Uterus," p. 238.

It is interesting to note that in two out of the three cases in which myomata were associated with an abnormal development of the uterus the growths were of the adenomyomatous type.

FIG. 114.—A DOUBLE UTERUS CONTAINING SUBPERITONEAL, INTERSTITIAL, AND SUBMUCOUS MYOMATA.
($\frac{1}{2}$ nat. size.)

Gyn. No. 11694. Path. No. 7953. This tumor reached 10 cm. above the umbilicus, and measured 15 x 17 cm. Two distinct uterine cavities are seen and two separate cervical canals (a, b). Scattered throughout the uterus are many interstitial nodules, and projecting slightly into the cavity is a submucous myoma. Several myomata project from the outer surface of the uterus.

ing from the under surface on the left side is a nodule, 5 x 3 cm. The uterine Path. No. 707. The uterus is 25 x 20 x 15 cm. It is smooth, and spring-

in the lower abdomen. A successful hysterectomy was done. The mass is movable, but not tender. The patient has a dragging sensation accompanied by bearing-down pain. The swelling has gradually increased. Five years ago the patient noticed enlargement of the abdomen. A. D., married, aged forty-five, white. Admitted May 7; discharged June 5, 1895.

A n g i o m y o m a o f t h e u t e r u s (Figs. 116 and 117).
Gyn. No. 3488. Path. No. 707.

In Case 3488 we have a remarkable example of a myoma showing numerous large angiomatous foci.

was preserved. In the degenerated areas the blood-vessels were much dilated (Fig. 115). It showed large areas of coagulation necrosis accompanied by hemorrhage, and sent a dark, reddish-brown, glistening appearance. (On histologic examination to the uterus by a delicate pedicle, 1.5 x 0.7 cm. (On section, the nodule pre- bore a striking resemblance to a spleen. It was 7 x 9 x 12 cm. and attached 13 cm. in diameter. The largest pedunculated tumor, both in shape and color, in diameter. The largest pedunculated uterus was approximately 13 cm. in diameter. It was 7 x 9 x 12 cm. and attached to the uterus by a delicate pedicle, 1.5 x 0.7 cm. (On section, the nodule pre- sented a dark, reddish-brown, glistening appearance. (On histologic examination it showed large areas of coagulation necrosis accompanied by hemorrhage, and was everywhere divided up into small irregular squares by them.

In Case 7226 (Path. No. 3486) the multinodular uterus was approximately 13 cm. in diameter. So abundant were the capillaries that the muscle rich capillary blood-supply. On histologic examination it was found that the tumor had a very dark color was due to the angiomatous character of portions of the myoma. In Case 3357 (Path. No. 618) the uterus contained a myoma 6.5 cm. in diameter. Sections from this tumor showed that the very vascular myoma, 10.5 x 12 cm. Situated in the anterior wall was a dark-red and measured 13 x 13 x 14 cm. In Case 3449 (Path. No. 683) the uterus was irregularly globular and with the blood-supply.

seen the angiomatous appearance totally independent of any interference dependent pedunculated myoma has become twisted. In a few cases we have the dependent portions of submucous myomata; it may also occur when a sub- becomes an angiomatous. This excessive vascularity is occasionally noted in

The blood-supply of a myoma may be so copious that the tumor in reality

A N G I O M Y O M A .

C H A P T E R X I .





FIG. 116.—MULTIPLE ANGIOMATOUS FOCI IN A MYOMA. ($\frac{1}{4}$ nat. size.)

Gyn. No. 3488. Path. No. 707. A section through an interstitial myoma, 15 x 20 x 22 cm. Scattered throughout the tumor are groups of cysts originating in the melting of hyaline material. At numerous points are sharply outlined dark-red or bluish porous areas. These consist almost entirely of blood-vessels, chiefly arteries. This is the only myoma that we have ever seen presenting such pronounced and circumscribed angiomatous areas. For the histologic appearance see Fig. 117. (After Howard A. Kelly.)

cavity is 10 cm. in length; its walls average 2 cm. in thickness; the uterine mucosa is whitish in color, smooth and glistening, and projecting into the uterine cavity from the posterior wall near the cervix is a sessile nodule, 2.5 x 1.5 x 1 cm.

Occupying the left uterine wall is a tumor approximately 15 x 20 x 22 cm. On section this is whitish yellow in color and consists of fibers concentrically arranged. Scattered throughout the tumor, especially in its central portion, are numerous dark-blue vascular areas, composed of blood-vessels (Fig. 116). These vascular areas present a honeycombed appearance and vary from 0.5 to 3.5 cm. in diameter. The individual vessels are closely packed together. Some

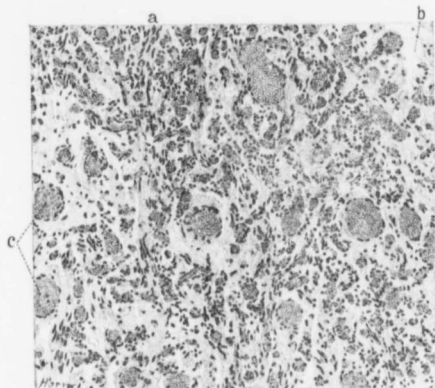


FIG. 115.—ANGIOMYOMA. (X 120 diam.)

Gyn. No. 7226. Path. No. 3486. The section is from a pedunculated, spleen-shaped, dark reddish-brown, sub-peritoneal myoma. At *a* the muscle-fibers are still clearly seen. At *b* the tissue has become rarified. Scattered throughout the field are many dilated veins (*c*).

are not larger than a pin-point, others reach 3 mm. in diameter. The vessel-walls are smooth and glistening. The entire picture suggests an angioma. The tumor has undergone a moderate amount of cystic degeneration. The cysts are scattered irregularly throughout the tissue, and vary from 0.3 to 5 cm. in diameter, have irregular, sharply defined edges, and contain a pale yellow transparent fluid which coagulates on exposure to the air. The smaller cysts are commencing to merge one into the other, and one of the large cavities contains an irregular, yellowish-white mass, 3 cm. in diameter, in its center. This is held in position by delicate bands which are adherent to the margin of the cavity. The walls of this cavity are smooth and glistening, and numerous delicate blood-vessels can be seen ramifying beneath the surface.

The outer surface of the tumor has a delicate capsule, yellowish white in color, and loosely connected with the uterine muscle, thus allowing the tumor to be shelled out with ease.

Histologic Examination.—The uterine mucosa has been imperfectly preserved, but where present, the glands are oval on cross-section and have an intact epithelial lining; some are considerably dilated. The stroma of the mucosa shows small-round-celled infiltration.

The large tumor situated in the uterine wall is composed of non-stripped muscle-

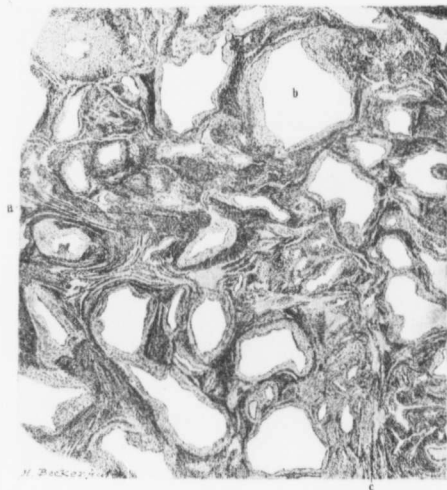


FIG. 117.—ANGIOMYOMA. ($\times 13$ diam.)

Gyn. No. 3488. Path. No. 707. The section is from one of the angiomatous areas in Fig. 116. The ground-work consists of typical myomatous tissue, well seen at *a*. Scattered throughout the field are masses of arteries, some of them large (*b*). The tissue immediately surrounding them shows some hyaline degeneration. The muscle is here and there undergoing liquefaction (*c*).

fibers arranged in bundles and cut both longitudinally and transversely. The tissue has a rich blood-supply. The dark-blue angiomatous areas are composed almost entirely of arteries irregular in contour (Fig. 117). They have an endothelial lining and a thick layer of circular muscle surrounding them, but the greater part of the circular layer has undergone hyaline degeneration, contrasting sharply with the surrounding muscle. Most of the vessels are filled with blood. Scattered throughout the tumor, frequently in the vicinity of the blood-vessels, are irregular areas of hyaline degeneration. In some of these

hyaline areas an isolated small round cell is here and there visible and in a few places aggregations of small round cells can be made out. In the area where the softening has occurred the tissue has undergone practically complete hyaline degeneration, but a muscle-fiber can here and there be seen in the hyaline material.

We have here subperitoneal and submucous myomata and a very large angiomyoma.

CHAPTER XII.

LIPOMYOMA OF THE UTERUS.

A tumor of this character, as the name implies, consists of myomatous muscle interspersed with adipose tissue. Myomata of this nature are exceedingly rare; in our entire series only one typical example was found. This case, San. No. 836, was reported in detail by Dr. J. H. Mason Knox, Jr.,* who also reviewed

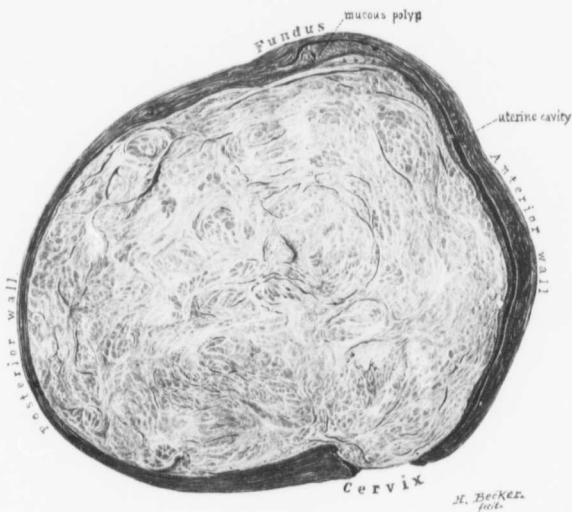


FIG. 118.—LIPOMYOMA. (½ nat. size.)

San. No. 836. Path. No. 3703. The uterus has been amputated through the cervix. Occupying the posterior wall and distorting the uterine cavity is an interstitial myoma. The coarse fibrillated arrangement of the myomatous growth is easily seen, but the interspaces are darker in color and more homogeneous than usual. They consist to a great extent of adipose tissue (Fig. 119). The uterine cavity is much lengthened; at the fundus is a broad-based polyp. (After J. H. Mason Knox, Jr.)

the meager literature on the subject. At first sight the myoma presented the usual appearance, but on careful scrutiny it was found to have a yellowish tinge, and although in many places the coarse fibrous arrangement of the myomatous tissue could be readily seen, in the interspaces the tissue was more homogeneous

* Johns Hop' ins Hosp. Bull., 1901, vol. xii, p. 318.

than usual (Fig. 118) and from the cut surfaces many oil-globules could be brought away with the knife-blade. On pressure the myoma felt very soft, although it showed no areas of degeneration.

The histologic picture is characteristic. The many clear spaces represent adipose tissue, and the framework of the tumor consists essentially of non-stripped muscle-fibers (Fig. 119).

In two other cases in which large myomata were present we also found areas of adipose tissue distributed throughout the tumor (Fig. 120, p. 164; Fig. 121, p. 165).

San. No. 836. Path. No. 3703.

Lipomyoma of the uterus (Figs. 118, 119).

The patient was sixty-two years of age and had had thirteen children. The labors were normal. The menopause had occurred twelve years previous to her admission. Three years later she had noticed a slight serous vaginal discharge, which soon disappeared, but returned after an interval of eight years, only lasting a short time. For two weeks she had been bleeding moderately but continuously. Operation, hysteromyomectomy.

Path. No. 3703. The specimen consists of the enlarged uterus, both Fallopian tubes, a portion of the left ovary, and a cystic right ovary. The uterus is globular in form (Fig. 118), regular in outline, 14 x 15 x 18 cm. in its various diameters. It is perfectly smooth. The uterine cavity is 14 cm. in length. The mucosa of the anterior wall is scarcely 1 mm. in thickness. That covering the posterior wall is considerably altered; in some places minute spaces are scattered throughout the mucosa, some reaching 2 mm. in diameter. Over an area 4 x 4 cm. in the upper part of the cavity the mucosa is excessively thin and the tumor has extended almost through the mucosa. Situated in the upper part of the cavity is a sessile polyp, 5 x 2.5 cm. Occupying the posterior wall is a tumor mass, 10 x 10 x 13 cm. On section, the tumor at first sight presents the usual

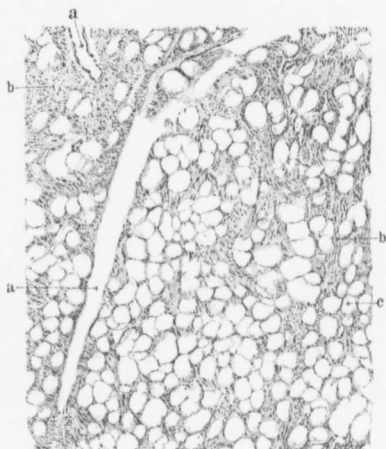


FIG. 119.—LIPOMYOMA. (X 48 diam.)

San. No. 836. Path. No. 3703. The section is from the myoma seen in Fig. 118. *a* indicates large and small blood-vessels. The solid areas (*b*) consist of myomatous tissue, and the many clear spaces (*c*) represent fat-cells. All parts of the tumor that were preserved presented a similar picture. (After J. H. Mason Knox, Jr.)

appearance of myoma, but on careful scrutiny is found to be markedly different. Traversing it in all directions are glistening bands, between which are yellow, soft-looking areas. When the cut surface is scraped, distinct oil-globules can be brought away—which is never possible when an ordinary myoma is examined.

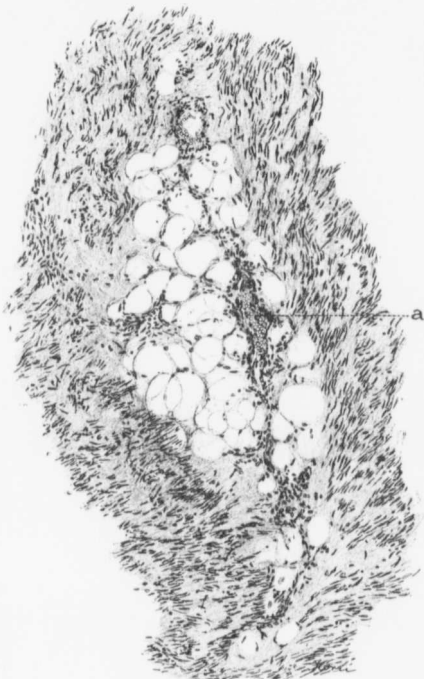


FIG. 120.—LIPOMYOMA. (X 140 diam.)

Gyn. No. 3133. Path. No. 494. *a* is a longitudinal section of a blood-vessel. Surrounding it, and embedded in the myomatous tissue, are many fat-cells indicated by spaces.

It looks very much as if the vessel when it first entered the tumor carried a certain amount of adipose tissue with it.

The tumor presents no areas of breaking down. It is sharply defined from the surrounding uterine muscle. It varies from 3 to 5 mm. in thickness.

Right side: The Fallopian tube is considerably lengthened and covered with adhesions. Its fimbriated extremity is adherent. The ovary has been

converted into a lobulated, partly cystic, mass, which measures 8 x 5 x 4 cm. The outer cystic portion consists of small multilocular cysts.

Left side: The tube presents the same appearance as the right.

Histologic Examination.—The uterine tumor is found to consist of large fat cells inclosed in a supporting substance consisting of smooth muscle and connective tissue in varying proportions (Fig. 119). The fat-cells are generally round (e), oval, or irregular in outline from pressure. They vary in size from five to fifteen times the diameter of a red blood-corpusele and, after hardening

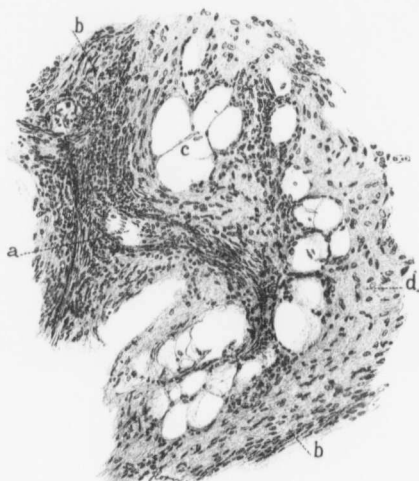

FIG. 121.—LIPOMYOMA. (X 140 diam.)

Gyn. No. 3320. Path. No. 589. The space *a* indicates an oblique section of a blood-vessel. *b* is ordinary myomatous tissue. At numerous points are aggregations of fat-cells (*c*). Surrounding the fat, and separating it from the myomatous tissue, is a varying amount of fibrous tissue (*d*).

by the usual process in which the fat is dissolved, appear as clear spaces. The nuclei of these cells can frequently be made out as oval or rod-shaped bodies pushed to the periphery and often situated in an angle between other cells. The tumor is traversed by numerous bands of firm fibrous tissue which produce the lobulated appearance noted in the gross specimen. The tumor consists essentially of non-stripped muscle-fibers and fat-cells equally intermingled. There is, of course, the ground-work of fibrous tissue. Scattered throughout the tumor are large cells which closely resemble mast-cells.

Gyn. No. 3133. Path. No. 494.

Areas of adipose tissue in a myoma (Fig. 120).

M. R., aged fifty, white. Admitted October 24; discharged November 24, 1894. The specimen consists of a pear-shaped uterus, 32 x 32 x 36 cm. The great increase in size is caused by an interstitial myoma. The mucosa is atrophic and projecting into the cavity is a delicate polyp. Numerous cystic areas are scattered throughout the myoma.

On histologic examination, in addition to much hyaline tissue, small areas of adipose tissue are recognized. In one group may be anywhere from three to eight or more fat-cells, chiefly found in close proximity to the blood-vessels (Fig. 120), and resembling ordinary adipose tissue.

Gyn. No. 3320. Path. No. 589.

Areas of adipose tissue in a myoma (Fig. 121).

M. D., aged twenty-nine, white. Admitted February 8; discharged March 9, 1895. The uterus was large and multinodular. The largest myoma was 13 x 21 x 28 cm. Some of the nodules show much hyaline degeneration and liquefaction. In several sections small groups of fat-cells were found (Fig. 121).

CHAPTER XIII.

ADENOMYOMA OF THE UTERUS.

In 1903, in a review of the literature published in a supplement to Orth's *Festschrift*, one of us (Cullen) reported 22 cases of adenomyoma examined by us up to that time. Since then we have paid especial attention to these growths and have been astonished at the striking frequency with which they occur. Out of a total of 1283 cases of myomata examined from April 1, 1893, until July 1, 1906, 73 (about 5.7 per cent.) were instances of adenomyoma. We have included only interstitial, subperitoneal, and submucous adenomyomata and large adenomyomata of the uterine horns.

Our cases have yielded many interesting histologic and clinical data. It was found impossible to do the subject justice and at the same time keep the present work within a reasonable size. To adenomyoma accordingly a separate volume has been devoted, and we will here merely give the briefest summary of the findings which have been fully elaborated in that publication.*

Summary.—In cases of adenomyoma of the uterus we usually find a diffuse myomatous thickening of the uterine muscle. This thickening may be confined to the inner layers of the anterior, posterior, or lateral walls, but in other cases the myomatous tissue completely encircles the uterine cavity.

This diffuse myomatous tissue contains large or small chinks, and into these the normal uterine mucosa flows. If the chinks are small, there is only room for isolated glands, but where the spaces are of goodly size, large masses of mucosa flow into and fill them. We accordingly have a diffuse myomatous growth with normal mucosa flowing in all directions through it. The mucosa lining the uterine cavity is perfectly normal.

After a time portions of the diffuse myoma may be nipped off and be carried toward either the outer or inner surfaces of the uterus. If they become submucous growths, they are gradually expelled. If they pass toward the outer surface, they become either subperitoneal or intraligamentary. We have accordingly divided adenomyomata into the following groups:

1. Adenomyomata in which the uterus preserves a relatively normal contour.
2. Subperitoneal or intraligamentary adenomyomata.
3. Submucous adenomyomata.

A diffuse adenomyoma presents a very coarse appearance, because the myomatous muscle-bundles run in all directions. In the spaces between bundles, and occasionally surrounded by circular rings of muscle, we find spaces

* Adenomyoma of the Uterus, Thomas Stephen Cullen, p. 270, W. B. Saunders Co., 1908.

filled with translucent and slightly punctiform tissue—areas of uterine mucosa. Sometimes its direct connection with the mucosa of the uterine cavity can be traced. Not infrequently cyst-like spaces are scattered throughout the diffuse myoma. These are filled with a chocolate-colored fluid and are lined with a definite membrane, often 1 to 2 mm. thick. They are miniature uterine cavities, and the chocolate-colored fluid is old menstrual blood that has not been able to escape.

When an adenomyomatous nodule becomes subperitoneal, the menstrual flow in the growth may gain the upper hand and the myoma become cystic, the contents, of course, being formed from the accumulation of old menstrual blood.

Age.—Our youngest patient was nineteen, our oldest sixty. The disease is most prevalent between the thirtieth and sixtieth years; it does not in any way tend to sterility.

Symptoms.—Lengthened menstrual periods are the first symptoms. The flow gradually assumes the proportions of hemorrhages and eventually the periods may become continuous.

At the period there is often discomfort, and occasionally a grinding pain in the uterus, evidently due to the increased tension, since all the islands of mucosa scattered throughout the diffuse myoma naturally swell up at the menstrual period and thus increase the size of the organ.

In over two-thirds of our cases there was no intermenstrual discharge. This is perfectly natural, as in these cases the uterine mucosa is normal and no disintegration of tissue is going on.

Clinically, the diagnosis of diffuse adenomyoma is relatively easy, for the following reasons:

1. The bleeding is usually confined to the period.
2. There is usually much pain, referred to the uterus, at the period.
3. There is usually no intermenstrual discharge of any kind.
4. The uterine mucosa is perfectly normal, and may be rather thick.

No other pathologic condition of the uterus, as a rule, gives this characteristic picture.*

Treatment.—The patient's health is often gradually undermined by the uterine hemorrhages, and the only way to control them is to remove the uterus. A supravaginal hysterectomy is all that is necessary. The ovaries should be saved.

The prognosis is good, as the glands of the adenomyoma are perfectly normal uterine glands and are surrounded by the characteristic stroma of the mucosa.

Origin.—The glands in the adenomyoma originate, in the vast majority of the cases at least, from the uterine mucosa.

Cause.—The cause of adenomyoma is still unsolved.

* Some submucous myomata are accompanied by a train of symptoms closely resembling adenomyoma.

CHAPTER XIV.

MYOSARCOMA OF THE UTERUS.*

That a primary sarcomatous change can take place in a myoma has long been known, and as early as 1863 Virchow† gave a very clear account of the gross and histologic pictures. In 1872 Chrobak‡ again drew attention to this class of cases, and in 1887 Ritter§ gave a full abstract of the literature up to that date. In 1894 the same question was fully discussed by Williams|| and also by Schreher,¶ and in 1895 L. Piek** gave a very clear account of sarcomatous changes in myomata. The article by Gessner†† published in 1899 is most exhaustive and will well repay a thorough study. Among the still more recent and lucid articles are those of Weir,‡‡ published in 1901, and of Jacobi and Wollstein,§§ which appeared in 1902.

Frequency.—Although quite a number of isolated instances of sarcomatous changes in myomata have been recorded, it would appear that the importance of the subject has hardly been fully appreciated. Fehling,||| in 409 myomata, found that 2 per cent. showed malignancy. In eight there was a sarcomatous degeneration and in one case carcinoma was present in the same uterus. Martin¶¶ observed direct sarcomatous transformation four times in a series of 205 cases.

* The term myosarcoma may be objected to on the ground that in some cases it is impossible to say whether the sarcoma has developed from the myomatous muscle or from its connective tissue. We fully appreciate this objection, but since in the great majority of our cases the origin of the sarcoma from the muscle-fibers seemed evident, and as the term myosarcoma is definitely fixed in the literature, and, furthermore, since it clearly indicates to the physician the clinical picture, we have thought it much wiser to stick to this word.

† Virchow: Die Krankhaften Geschwülste, Bd. iii, S. 201.

‡ Chrobak: Arch. f. Gynäk., 1872, Bd. iv, S. 549.

§ Ritter: Dissert. Inaug. Ueber d. Myosarkom des Uterus, Berlin, 1887.

|| Williams, J. Whitridge: Contributions to the Histology and Histogenesis of Sarcoma of the Uterus, Am. Jour. of Obstet., 1894, vol. xxix, No. 6.

¶ Schreher: "Ueber d. Complication von Uterusmyom mit sekundärer sarkomatöser Degeneration," Diss. Inaug., Jena [Strassburg], 1894.

** Piek, L.: Zur Histiogenese und Classification der Gebärmutter-sarcome, Arch. f. Gynäk., 1895, xlviii, S. 24. Arch. f. Gynäk., 1895, S. 33. Zur Lehre vom Myoma sarcomatosum und über die sogenannten Endotheliome der Gebärmutter, Arch. f. Gynäk., 1895, xlix, S. 1.

†† Gessner: Veit's Handbuch der Gynäkologie, 1899, iii, Zweite Hälfte, S. 957.

‡‡ Weir, Wm. H.: Muscle-cell Sarcomata of the Uterus, Am. Jour. of Obstet., 1901, vol. xliii, 618.

§§ Jacobi, Mary Putnam, and Wollstein, Martha: Am. Jour. of Obstet., 1902, vol. xlv, p. 218.

||| Fehling: Centralbl. f. Gyn., 1898, xxii, S. 1118.

¶¶ Martin, A.: Ueber Myome, Verh. d. deutsch. Ges. f. Gyn., ii, S. 125.

In our series, which now embraces over 1400 cases, 17 showed undoubted sarcomata of the uterus occurring in or associated with myomata. In 17 other cases suspicious gross or histologic pictures were present, but the changes in these were not sufficient to warrant a positive diagnosis of sarcoma. Now, since many of our cases were not examined histologically unless they presented suspicious macroscopic pictures, and again, in view of the fact that it would be almost impossible to examine every portion of a myomatous uterus histologically, without doubt some cases have been overlooked. During the last decade hysterectomies and myomectomies for myoma have become much more frequent, and careful clinical histories and pathologic records have been kept. We feel confident that, as a result of these careful studies, in the next few years many cases of sarcomata developing in myomata will be reported, and that this malignant change will be found to be relatively common.

The Gross Appearances of Myosarcomata.—Uterine myomata are usually multiple. Thus, in those cases in which a sarcomatous change takes place several other myomata are almost invariably present. The nodules may be subperitoneal, interstitial, or submucous. As a rule, only one nodule undergoes a malignant change, but, as in von Kahliden's* case, sarcomatous foci may occur simultaneously in several myomata. In the very early stages the macroscopic changes may be totally wanting or, as has been pointed out by Chrobak, they may be so slight as not to be recognized. This was clearly shown in San. No. 1857 (Fig. 137, p. 206). Here, lying to the side of the cervix, was a myoma several centimeters in diameter. Macroscopically it differed in no way from the ordinary myoma, and yet on histological examination the transition of muscle-cells into sarcomatous tissue was perfectly evident. Where the malignant change is present, it is usually readily recognized. The pinkish-white tissue with the coarse fibrous arrangement has been in part replaced by a yellowish-white, homogeneous tissue, almost totally devoid of fibrous elements, and bearing a striking resemblance to raw pork. The sarcomatous is usually sharply differentiated from the myomatous tissue, but now and then gradually merges into it. Sometimes the sarcoma presents a porous appearance, as noted in Fig. 138 (p. 209) and Fig. 131 (p. 193), or it may contain large and small cyst-like spaces, as seen in Fig. 132 (p. 197), Fig. 133 (p. 198), and Fig. 140 (p. 213). These were also noted in Menge's case. They are probably dilated lymph-spaces. The sarcomatous tissue is exceedingly soft, and from its surface a considerable amount of fluid can be squeezed. As exemplified in Case 8732 (p. 215), the growth may be soft—so soft that it resembles brain tissue. With the advance of the sarcoma hemorrhages take place, giving the cut surface a reddish-brown, mottled appearance, which after a time is replaced by a yellowish or yellowish-brown color, due to the deposition of blood-pigment. In a short time the central portions of the tumor undergo coagulation necrosis, followed by liquefaction (see Fig. 138, p. 209). The sarcomatous changes usually commence in the central portions of the myoma,

* Von Kahliden: Ziegler's Beiträge zur path. Anatomie und allg. Pathologie, 1883, xiv, S. 174.

but occasionally occur in the periphery. The latter seems to have been the case in Fig. 143 (p. 217), in which the remnants of a myoma are entirely surrounded by sarcomatous tissue. With the advance of the growth secondary pure sarcomatous nodules become scattered throughout the uterine walls, as is well seen in Fig. 140 (p. 213) and Fig. 143 (p. 217); or sarcomatous polypi may project into the uterine canal, as shown in Fig. 138 at i. (p. 209).

In Figs. 125 (p. 185) and 126 (p. 186) is represented a most unusual secondary nodule in Path. No. 7555. The uterus was small, and its interstitial myomatous nodule showed marked hyaline changes and also sarcomatous transformation of muscle-fibers. Attached to the posterior surface of the uterus was a large, cockscomb-like secondary growth, which on histologic examination was found to consist essentially of tissue that was of even a more pronounced sarcomatous type than that of the primary tumor.

The older writers claimed that myomata that underwent sarcomatous degeneration were almost invariably submucous. Our experience, however, goes to show that the malignant change may equally well start in a subperitoneal or interstitial myoma.

The following table gives the location of the sarcomatous growths in our cases:

Interstitial: Gyn. Nos. 11944, 6724, 7040, 7474, 8610, 8732, 8836, 8, 1879 (partly submucous), Path. No. 6421.....	9 cases
Subperitoneal: Gyn. Nos. 6045, 7604, 9536, 12155.....	4 "
Intraligamentary: 8, 1857.....	1 case
Submucous: Gyn. Nos. 7313, 10376 (uterus not removed), Path. No. 7555.....	3 cases
	17 cases

Uterine myomata are usually at first interstitial and eventually become either submucous or subperitoneal. In former years when few abdominal operations were performed naturally only the submucous sarcomatous nodules were recognized clinically. From a study of our table it will be seen that over half the cases were interstitial, and that the interstitial and subperitoneal myomata undergoing sarcomatous changes were far in excess of those of the submucous group. In only three out of our seventeen cases were the sarcomatous myomata submucous. Of course, at a later date some of these myomata would have undoubtedly migrated into the uterine cavity and have become submucous.

Case 6045 and Case 9536 (Fig. 123, p. 181) are excellent examples of sarcomata commencing in subperitoneal myomata; Fig. 138 (p. 209) shows a sarcoma developing in an interstitial myoma. In the latter case it seems more probable that the growth in time would tend to extend more and more into the uterine cavity. If a myosarcoma projects into the uterine canal, it usually becomes lobulated from the rapid character of the growth, and we have the expulsion through the vagina of a tumor usually supposed to be a submucous myoma. The original growth still continues, but after a short time further portions are expelled in a similar manner.

Histologic Appearances of Myosarcomata.—Sarcomata developing from myomata are divisible into two varieties: (1) Sarcomata developing from the connective tissue of the myomata; (2) sarcomata developing from the myomatous muscle.

Of course, there are undoubted cases in which the sarcoma develops in part from the connective tissue and in part from the transition and multiplication of muscle-fibers. Macroscopically both these varieties present the same appearance and naturally require precisely the same operative interference.

1. *Sarcomata Developing from the Connective Tissue of Myomata.*—Virchow was one of the first to describe this variety, and his description is so good that we cannot do better than quote him directly: "The degeneration, as I have traced it, is as follows. At certain points the intercellular substance commences to grow, the cells increase through division. Thus more and more round cells are formed, at first small, later larger and larger and with bigger nuclei. Meanwhile the intercellular substance becomes less and more rarefied and, while the stroma increases, the muscle disappears entirely in many places. At other points it still persists and even increases. In this manner the trabecular character of the growth develops. The cells grow; many of them become angular and develop processes and their nuclei reach the size of epithelial nuclei. They are, however, usually arranged in rows or groups. With this increase in the cellular elements the original stroma is in part or entirely replaced by the new growth. Such portions become soft, friable, and have a whitish or yellowish appearance. Comparatively large blood-vessels penetrate the softer portions and give rise to hemorrhagic infiltration. In this way a portion of the cyst-like spaces are produced."

Every one must agree fully with Virchow's description. In our own Case 7474 (Fig. 139, p. 211) we have an excellent example of the development of small cells into larger ones. Side by side we have crops of the large and small cells, while in the immediate neighborhood all intermediate sizes are demonstrable. The increase in the cells is due, as Virchow pointed out, to indirect division. Sometimes the entire normal karyokinetic cycle can be traced and usually many cells with atypical forms are present. Now and then direct budding of nuclei is to be seen. Fig. 144 (p. 218) depicts clearly the many cell forms that may be found. Here we have small and large, round or oval, vesicular nuclei; large and small, deeply staining nuclei; large and irregular and partly dividing nuclei, and tremendous clumps of chromatin scattered throughout large plaques of protoplasm. Giant cells are also present, usually with their nuclei arranged in a mulberry-shaped form. Sarcomata originating from the connective-tissue elements of myomata may be either spindle-celled or round-celled. These sarcomata may be in part due to a proliferation of the endothelium of dilated lymph-spaces, as has been pointed out by Chrobak and Menge.* The stroma of this growth at times shows distinct myxomatous degeneration. As the sarcoma increases in

* Menge: *Centralbl. f. Gynäk.*, 1895, Bd. six, S. 453.

size the central portions undergo necrosis, with or without fragmentation of nuclei, and often along the margin of the necrosed area there is a small-round-celled or polymorphonuclear infiltration.

2. *Sarcomata Developing from the Muscular Elements of Myomata*.^{*}—Myosarcomata are usually thought to be derivatives of the connective-tissue portions of myomata. Nevertheless, recent investigations tend to show that a fair proportion are due to a direct transformation of normal muscle-fibers into malignant fibers. As far back as 1860, however, Virchow when describing those of connective-tissue origin said: "The muscle disappears entirely in many places; at other points it still persists, and is even increased," thus indicating that the muscle might take part in the process. Von Kahliden† reported a case in which he was sure he was able to trace the direct transition of myomatous muscle-cells into sarcomatous cells. To Williams we are indebted for the most clear and convincing proof that the muscle-fibers are actually capable of becoming malignant. Similar and confirmatory evidence has been furnished by L. Piek, Morpurgo,‡ Gessner,§ Veit,|| Gebhard,* Weir, and others.

In thirteen of our seventeen cases (S. 1857, S. 1879, Gyn. Nos. 6045, 6724, 7313, 7304, 8836, 9536, 10376, 11944, 12155, Path. Nos. 6421 and 7555) the sarcoma was apparently the result of a transformation of the myomatous muscle-fibers, and in one further case (Gyn. No. 8610) the sarcoma seemed also to have resulted from an alteration in the muscle-fibers. But the proof in the last case, although strongly suggestive, was not sufficient to enable us to make an absolute statement.

Of the remaining cases, Gyn. No. 7474 (Fig. 139, p. 211) seemed to be a round-celled sarcoma. Gyn. No. 7040 was a mixed-cell growth and Gyn. No. 8732 was a very unusual mixed-celled sarcoma (Fig. 144, p. 218), containing areas closely resembling decidua, and others strongly suggestive of syncytium. From the above it will be seen that out of the seventeen cases, in thirteen the sarcoma had resulted apparently from an alteration in the muscle-fibers, and in the remaining cases the presumptive evidence was in favor of a similar origin.

A reference to Case 6045 (p. 223), with its figures (146, 147, 148, 149, 150,

^{*} Mallory has recently drawn attention to the fact that specimens of this character must be cut in small pieces and hardened within a few minutes after removal, otherwise the finer details will be lost. Nearly all of our cases were operated upon before his article appeared, and consequently his technique could not be employed. In this connection a thorough study of Mallory's exhaustive and painstaking articles cannot fail to be profitable. Mallory, F. B.: A Contribution to the Classification of Tumors, Jour. Med. Research, vol. xiii, Jan., 1905. Results of the Application of Histological Methods to the Study of Tumors, Jour. Exper. Med., vol. x, No. 5, Sept. 5, 1908.

† Von Kahliden: Ziegler's Beiträge zur path. Anatomie und allg. Pathologie, 1893, xiv, S. 174.

‡ Morpurgo: Ueber sarkomähnliche und maligne Leiomyome. Ztschr. f. Heilkunde, 1895, 16, S. 157.

§ Gessner: Veit's Handbuch der Gynäkologie, 1899, iii, Zweite Hälfte, S. 957.

|| Veit: Handbuch d. Gynäkologie, 1897, Bd. ii, S. 494.

* Gebhard: Veit's Handbuch der Gynäkologie, 1897, ii, S. 444.

151, 152, 153, 154, and 155), will give the reader a clear idea of the various transition stages of the myoma into sarcoma.

In order to follow these changes satisfactorily it is always necessary to obtain sections at the outer edge of the growth, because in the central portion all trace of the myomatous muscle has disappeared and its place is occupied by spindle-celled sarcoma. In Case 6045 the change had been a very gradual one and many distinct foci could be traced near the border of the growth, indicating that there was a general tendency for the myoma to become malignant. In Fig. 150 (p. 227) we see typical myomatous muscle-fibers. A short distance further on are nuclei twice the size, then four or five times as long, correspondingly broad, and containing a slight increase in chromatin; and finally we encounter bunches of very large nuclei containing great quantities of chromatin. In this picture, then, we have all gradations, from the normal to the unmistakable sarcomatous fiber. Fig. 148 (p. 225), taken from a hyaline area at some distance from the main growth, is even more easily followed, inasmuch as here the cells are further apart. Here also the gradual and yet steady increase in the size of the nuclei is easily followed. In Fig. 149 (p. 226) from the same case, cross-sections and longitudinal sections of muscle-bundles are still clearly visible. Nevertheless, in each of them all stages in the transition, from the slender, spindle-shaped, to the very large elongate and deeply staining nuclei, can be followed. Figs. 151, 152, 153, 154 (p. 228), from the same case, are even more convincing. In Fig. 151, at *a* we have a cross-section of a muscle-bundle with the tips of muscle-fibers still preserved, and yet sufficient changes have taken place in the surrounding muscle-fibers to render a diagnosis of sarcoma certain. Other portions of the same specimen show all transition forms. The cells in Figs. 152, 153, and 154 of the same case illustrate admirably the relatively huge dimensions that these cells may attain, and also show clearly the presence of large numbers of hyaline droplets in the giant nuclei. As we pass toward the center of the growth the sarcoma is found to be composed of a sea of cells, chiefly spindle-shaped, and usually so closely packed together that the cell outlines are hard to differentiate. Traversing the sarcoma are large and small blood-vessels almost totally devoid of stroma. Case 9536 also shows clearly the gradual transition from the myomatous muscle-fibers into the sarcomatous growth. Fig. 124 (p. 182) is taken from the growth seen in Fig. 123 (p. 181) and is at the junction of the sarcoma with the myoma. The left portion of the section contains muscle-fibers slightly swollen but otherwise unaltered. As we pass to the right, however, the nuclei increase rapidly in number, are more spherical, and are somewhat enlarged. Some of them also contain an increased amount of chromatin. Near the right border of the section the nuclei have become clumped together, forming giant-cells. The tissue immediately beyond this was that of a typical sarcomatous growth. The subsequent degeneration in this variety of sarcoma is similar to that occurring in those arising from the connective-tissue portions of myomata.

Thus we have sarcomata developing in uterine myomata. These may be of

connective-tissue origin, and are either spindle-celled or round-celled. We also have sarcomata developing from the muscular elements of the myoma. These are invariably spindle-celled. Of course, it is quite possible that both stroma and muscle may take part simultaneously. This division into the two varieties is of purely pathologic interest, as it can be determined only on careful histologic study. It is of no particular import to the surgeon.

In San. No. 1852, included among the adenomyoma cases ("Adenomyoma of the Uterus," p. 225), we have a very interesting example of adenocarcinoma of the body of the uterus developing in part from a preëxisting adenomyoma. Commencing sarcoma was also present in the body of the uterus.

A careful study of the pathologic description of the cases certainly suggests that in many instances hyaline degeneration has been the forerunner of the malignant change. The muscle-fibers scattered throughout the hyaline and partially liquefied material have a much more favorable opportunity for swelling up or for taking upon themselves increased activity, not being closely packed together, as in the ordinary myoma. The more we study these tumors, the more strongly we become impressed with the apparently predisposing tendency to sarcoma created by the primary hyaline change.

Secondary Growths of Myosarcomata.—As has been noted in the foregoing pages, with sarcomatous degeneration of myomata there is a simultaneous increase in the size of the myoma, and secondary sarcomatous nodules frequently become scattered throughout the uterine walls. If the nodule be subperitoneal, we shall expect the sarcoma to soon reach the outer surface of the myoma, and to then engraft itself upon the surrounding tissues, as in Case 9536 (Fig. 123, p. 181), in which the large subperitoneal tumor has become

intimately attached to the rectum. Again, in Case 7474 there was a large area of necrosis on the anterior surface of the tumor. Finlay* reports an interesting case of a woman, fifty-eight years of age, who had had an abdominal tumor for fifteen years. This had recently increased materially in size. She died eight days after admission with signs of peritonitis. At autopsy a tumor the size of a child's head was found attached to the fundus. The upper portion showed a breaking-

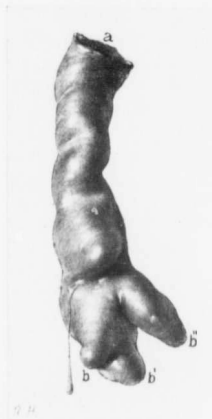


FIG. 122.—A SARCOMATOUS NODULE IN A LARGE PELVIC BLOOD-VESSEL. (Nat. size.)

Path. No. 7903. The original growth started in the uterus. It was a sarcoma that had apparently developed from a myoma. Dr. Hünner, when removing the uterus, felt one of the blood-vessels to be firmer than usual, and on further dissection drew this cast of sarcomatous tissue from the vessel lumen, *a* represents the main vessel; *b, b', b''*, are secondary branches. The sarcoma had grown directly into the vein.

* Finlay: Trans. of the Path. Soc. of London, 1883, vol. xxxiv, p. 177.

down. The lower portion had a firm consistence. The tumor proved to be a spindle-celled sarcoma. In this case the growth had become adherent to and had grown into the bladder, where it formed a fungating mass. Secondary sarcomatous nodules were found in the skin, lungs, and heart muscle. Ritter* reported an instance of myosarcoma with subsequent supravaginal hysterectomy. The patient died six weeks after from a recurrent growth. In this case metastases had taken place into the lymph-glands at the pelvic brim. These glands broke down during enucleation and were found to contain brain-like material. In this case so malignant was the growth that within six weeks after the operation perforation of the anterior abdominal wall had taken place. Schreher† points out that metastases in otherwise operable cases are rare. In the late stages of the growth he mentions metastases in the liver, lungs, pericardium, omentum, heart muscle, and vertebrae. What we have most to fear is the lightning rapidity with which the growth extends to the surrounding pelvic structures rather than the danger of metastases.

In our cases coming to autopsy three showed metastases. In Case 7313 (p. 195) in which a necrotic submucous myoma and a subperitoneal myoma were present, a secondary nodule developed in the broad ligament, and later, as will be seen from Dr. Osler's letter, the patient evidently had metastases in the glands of the neck, in the lungs, and in the pleurae.

The growth in Gyn. No. 12,155 (p. 200) was exceedingly rapid, as within a few months after operation a large secondary tumor was found in the right upper abdominal quadrant. At autopsy this nodule was found to be in the liver. There were also general abdominal metastases, and likewise numerous skin metastases, which were readily recognized clinically.

The secondary growths in Gyn. No. 7604 (p. 220) were particularly interesting, sarcomatous nodules being found in the chordae tendineae of the tricuspid valves as well as in the lungs.

Some of the sarcomatous growths show a decided tendency to remain local, as noted in Path. No. 6421. In this case two years after the supravaginal amputation of a myomatous uterus—the sarcoma being at the time completely overlooked—there was a local return in the cervical stump, and at the second operation no metastases were apparent (Fig. 130, p. 191, and Fig. 131, p. 193).

Condition of the Uterine Mucosa in Cases of Myosarcoma of the Uterus.—In very few of the cases reported has any attention been paid to a description of the mucosa. In those cases in which the interstitial nodules gradually become submucous, as reported by Pick, the overlying mucosa becomes atrophic; the glands are pushed aside or are obliterated, and the nodule soon lies directly beneath the surface epithelium. This soon yields, and eventually the submu-

* Ritter: Dissert. Inaug., Ueber d. Myosarkom des Uterus, Berlin, 1887.

† Schreher: Ueber d. Complication von Uterusmyom mit sekundärer, sarkomatöser Degeneration, Inaug. Diss., Jena [Strassburg], 1894.

eous myoma over its most prominent portion is not only devoid of a covering of mucosa, but shows breaking-down of its superficial portions.

In thirteen of our seventeen cases we have definite data as to the condition of the uterine mucosa. In Gyn. No. 7313 the mucosa here and there showed focal endometritis, but was on the whole normal. Projecting into the uterine cavity, in Gyn. Nos. 7474 and 12,155, were polypi. In a few cases minor changes, such as dilatation of the veins in the mucosa, dilatation of the lymph-channels, or dilatation of a few glands, were detected. In ten out of thirteen cases the mucosa was, however, practically normal.* This is exactly what one might expect when the tubes and ovaries are normal and when a sarcoma is either interstitial or subperitoneal. When the growth becomes submucous and sloughs, the inflammatory process naturally extends to the surrounding mucosa.

Condition of the Tubes and Ovaries.—The appendages seem to be little affected by the development of the sarcomatous growth. In fourteen out of our seventeen cases we have definite data as to the condition of the appendages. In Case 7313 the right tube was the seat of a subacute salpingitis and there was pelvic peritonitis. The left tube was normal. In this case a slight focal endometritis existed. The outer end of the right tube in Case 6045 had become lost on the surface of the tumor, while the ovary was adherent at its outer pole.

In Gyn. Nos. 7604, 8610, and 8836 adhesions were also noted; in the remaining nine the tubes and ovaries were perfectly normal.

On the whole, we can be reasonably certain that the growth exercises little influence on the appendages. Of course, if pelvic adhesions have existed, we usually expect the tubes and ovaries to be implicated in this process.

Clinical History in Cases of Myosarcomata of the Uterus.—These patients usually come with a definite history of uterine myomata of several years' standing. Gessner and Weir both report cases in which a myoma had been detected two years previously; Ritter and Weir observed instances in which the myoma had been recognized at least ten years before operation. Finlay's patient had had a distinct abdominal tumor for fifteen years, and in Langerhans' patient, who was sixty years of age, the tumor had been demonstrable for twenty years. In Case 7212 the myoma was detected four years before admission, and in Case 7474 a period of twelve years had elapsed from the time the myoma was first recognized until operation. In Case 9536 the growth was detected only six months before operation. Here the tumor was posterior to the uterus, was situated low down in the pelvis, and had evidently escaped recognition for a much longer period. Nearly all of the patients give a history of a slow development of the tumor for several years, with a marked increase in growth during the last few months.

* Atrophy of the mucosa is merely a relative term. Where the surface area is four times as great as normal, owing to the presence of a myoma, a mucosa one-quarter of the normal thickness, although apparently atrophic, is in reality normal.

Age.—As seen from the accompanying table, the highest incidence in our cases was between forty and fifty years of age:

Gyn. No. 6,724.....	age 27	San. No. 1,857.....	age 46
Gyn. No. 8,610.....	" 39	Gyn. No. 9,536.....	" 48
San. No. 1,879.....	" 41	Gyn. No. 8,836.....	" 48
Path. No. 6,421.....	" 42	Gyn. No. 12,155.....	" 48
Gyn. No. 7,604.....	" 44	Path. No. 7,555.....	" 50
Gyn. No. 10,376*.....	" 45	Gyn. No. 7,040.....	" 50
		Gyn. No. 7,212.....	
Gyn. No. 7,313.....	" 45	Gyn. No. 7,474.....	" 52
Gyn. No. 8,732.....	" 46	Gyn. No. 6,045.....	" 56
Gyn. No. 11,944.....	" 46		

thus indicating clearly that this malignant degeneration is most frequent at the age at which carcinoma also is prone to develop.

We have seen that sarcomata may develop in subperitoneal, interstitial, or submucous myomata. Hence the clinical picture will vary according to the location of the growth. Where the growth is subperitoneal, there will be a rapid increase in size of the tumor, with or without pressure symptoms, according as the growth becomes jammed in the pelvis or not, and according as it does or does not extend to the rectum (see Case 9536, p. 180). Such cases usually come to operation before the disease advances further; otherwise the growth may extend to the bladder, if that viscus has been drawn upward on the surface of the tumor, and in a short time we shall have a growth projecting into the bladder, as was noted in Finlay's case. The subperitoneal tumor itself will rarely cause uterine hemorrhage, and, if a bloody vaginal discharge is present, it will be due to the existence of interstitial or submucous myomata in the same uterus. Where the sarcomatous myoma is interstitial, there may be a general enlargement of the uterus with extension of a portion of the growth toward the peritoneal surface or, as is more frequent, toward the uterine cavity. When the growth encroaches on the uterine cavity, the patient will have hemorrhages. This portion of the growth is forced more and more into the cavity of the uterus, becomes pedunculated, and then often undergoes partial necrosis. The hemorrhages subsequently increase, and in the interim there is a foul-smelling watery discharge due to disintegration of the sloughing growth. The intra-uterine growth is after a time expelled, and the patient, who has become very anemic and sallow as a result of continual loss of blood, rapidly improves for a time. After a variable period other portions of the growth become submucous and in turn are expelled *per vaginam*. Hence arose the term, "recurrent fibroids." Gessner mentions well-known cases reported by Hutchinson, Callender, Paget, and West, and quite recently many similar cases have been published. In Case 7313 (p. 195) a necrotic submucous nodule was expelled two weeks before the patient's

*The tumor in this case was a submucous sloughing myoma. It is just in this class of cases that the pathologist finds the greatest difficulty in differentiating between simple disintegration of the myoma and sarcomatous transformation. The changes in this case were so pronounced that from the histologic picture we were forced to classify it among the sarcomata.

admission, and others would doubtless have followed had the uterus not been removed. Case 5496 (p. 252) is a typical example of a "recurrent fibroid." The patient was forty years of age. For three months there had been frequent hemorrhages and a large, sloughing, cauliflower-shaped myoma, 10 cm. in diameter, filled the vagina. This was removed and the uterus was packed with gauze. Two months later a similar nodule was expelled into the vagina, and for another two months there was perfect relief. Three months after removal of the second nodule, a third pedunculated myoma, 9 cm. in diameter, was removed *per vaginam*. At the end of a year this patient was perfectly well. From these cases it is evident that some of the "recurrent fibroids" are sarcomatous myomata, others are simple and rapidly growing myomata. It is often exceedingly difficult, and in fact impossible, to determine whether these submucous growths are sarcomatous or simply edematous and necrotic myomata. We found no absolute proof in our case of "recurrent fibroid" that it was malignant, and clinically the patient remained well. Gessner says that Simpson removed seven successive growths through the vagina, and that it was only in the seventh that he was able to detect sarcoma. Of course, if such a nodule as that seen in Fig. 138 (p. 209) were to be expelled from the cervix, the diagnosis would be clear. This nodule, however, is not the primary growth, but a secondary one from the sarcomatous portion of the large myoma.

Pregnancy may occur when myosarcoma exists. Schreher reports a case in which the growth was situated laterally, suggesting an intraligamentary cyst, and in the uterus was a four-months' fetus.

Color.—In the seventeen cases examined by us, fifteen of the patients were white and two colored.

From the foregoing it is seen that sarcomatous myomata present few, if any, distinct clinical features. Myomata which have increased slowly for years often take on a rapid development without becoming malignant, and even when "recurrent fibroids" are present, a good many are simply necrotic myomata showing no malignant changes. Only in rare instances will it be possible to obtain definite evidences of sarcoma from extruded submucous tumors. As seen from a study of our cases, in some instances sarcoma was not for a moment suspected until the uterus had been removed to the laboratory, and even then the growth was occasionally overlooked. In those cases in which the operation is not performed, death may be due to the continuous hemorrhage producing exhaustion, but occasionally to wide-spread metastases.

Treatment.—The only hope of saving these patients' lives lies in a complete removal of the uterus. In nearly all of the cases reported in the literature, and in nearly all of our own, supravaginal hysterectomy was performed, the operator not for a moment having suspected sarcoma even after the abdomen was opened. In every case in which sarcoma is suspected the entire organ must be removed, and also as much as possible of the parametrial tissue. Considering the number of cases showing sarcomatous transformation of myomata, and the possibility

that carcinoma may coexist in a myomatous uterus, we strongly advise that in every case in which a supravaginal hysterectomy is deemed preferable, the uterus be opened immediately after removal, so that if by chance a malignant growth be present, the cervix can be removed without delay.*

No better example of the necessity of carefully examining all myomata at once could be found than in Path. No. 6421 (p. 190). In this case about two years after a supravaginal hysterectomy, the patient had definite signs of intra-abdominal hemorrhage. At operation a large sarcoma was found developing from the cervical stump. Its complete removal was impossible. On examination of the original tumor, sarcoma was readily recognized, even macroscopically. It had been overlooked in the laboratory.

For the various steps in a complete abdominal hysterectomy see page 588. Where the growth has not been entirely removed, operation evidently hastens the end. In Ritter's case thirty days after supravaginal hysterectomy a return of the growth was noted, and six weeks after operation the patient died, the secondary tumor at the cervical stump having reached a diameter of 20 cm. The growth had perforated the abdominal wall. In Case 7212 a movable mass, the size of a walnut, was detected at the cervical stump twenty-six days after operation, and the patient died less than three months from the date of the hysterectomy.

In Case 12,155 a few months after operation a large metastatic nodule developed in the liver, and the patient soon died of wide-spread disseminated abdominal metastases.

It seems to us probable that, when the supravaginal hysterectomy is done, the sarcomatous growth is transplanted in various directions by the knife, and that it commences to grow with increased vigor. As will be seen from our cases, the immediate results following hysterectomy for sarcoma are not very gratifying. In all cases of myosarcoma there seems to be a great danger of infection, and if the utmost care be not exercised, a local or general peritonitis will develop from the necrotic and frequently sloughing sarcomatous growth.

DETAILED REPORT OF CASES IN WHICH MYOMATA BECAME SARCOMATOUS OR WERE ASSOCIATED WITH SARCOMA OF THE UTERUS.

This subject is of such practical importance that each of our cases is given in detail.

Gyn. No. 9536. Path. No. 5730.

Small interstitial uterine myomata; large sub-peritoneal myoma densely adherent and undergoing sarcomatous transformation (Figs. 123 and 124); normal appendages.

* Cullen, Thomas S.: Sarcomatous Transformation of Myomata, Jour. Am. Med. Assoc., Oct. 24, 1903. Immediate Examination of Uterine Mucosa and Myomatous Nodules after Hysterectomy, to Exclude Malignant Disease, Jour. Am. Med. Assoc., March 10, 1906.

E. C., white, married, aged forty-eight. Admitted April 7, 1902, complaining of pain in the lower abdomen. Her family and past history are negative. Her menses commenced at fifteen, were regular, lasting four days. The flow was moderate and unaccompanied by pain. There has been a slight leukorrhœa. She has been married thirty-two years and has had three children, the eldest thirty, the youngest twenty-four.

Six months ago the patient began to suffer from pain in the lower abdomen, back, and rectum, and shortly afterward noticed a tumor. There was increased frequency of micturition, but no other symptoms. On admission the general condition was fair;

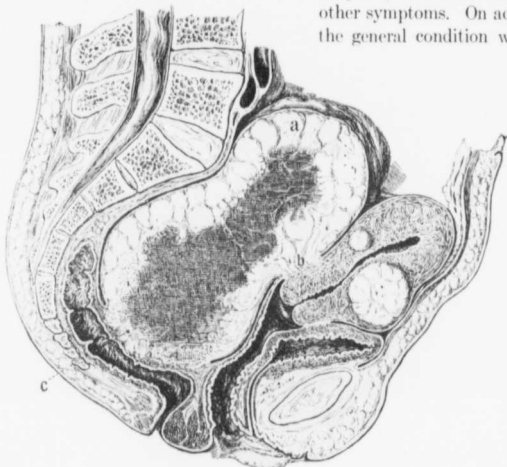


FIG. 123.—SARCOMATOUS TRANSFORMATION OF A SUBPERITONEAL MYOMA WITH DENSE ADHESIONS TO THE RECTUM AND PELVIC WALLS.

Path. No. 5730. The drawing represents the appearances as found at operation. The uterus is somewhat enlarged. Situated in its anterior wall is an interstitial myoma; in the posterior wall a smaller one. Attached to the posterior surface of the uterus at b is a large subperitoneal myoma. This fills the entire pelvis and extends above the pelvic brim. The outlying portions (a) present the typical myomatous appearance, but the entire central portion is broken down. At c the growth is intimately blended with the rectum. From the text it will be seen that the disintegration of the tumor was due to sarcomatous transformation of the myoma.

the temperature was normal. There was a hard mass filling the lower abdomen and extending to within 3 cm. of the umbilicus.

Operation. The uterus was situated anteriorly and above the tumor, which filled the pelvis and was densely adherent. On account of the adhesions the uterus and tumor were bisected. Not all of the tumor could be gotten from the pelvic floor and many bleeding points were left. Two gauze drains were carried down to the pelvic floor. The patient was in good condition on leaving the table.

During the next day she had severe pain in the left lower abdomen. Her pulse was 110, the temperature 101.5°. There were vomiting and distention. The bowels moved on the second day and all the packs were removed. She developed

signs of intestinal obstruction, and on the fourth day, the day of her death, her temperature reached 105°. No autopsy was obtained.

Path. No. 5730. The specimen consists of the uterus with a tumor springing from its posterior surface, and also of the appendages. The uterus has been amputated through the cervix. It is 6 cm. in length and 6 cm. in its antero-posterior diameter. This increase in thickness is due to two myomatous nodules, one situated in the posterior, the other in the anterior, wall. Attached to the left side of the uterus near the cervix is a tumor mass, approximately 15 cm. in its longest diameter (Fig. 123). This nodule presents a distinctly myomatous appearance, and over a wide area is covered with dense adhesions. On section fully one-half of the tumor presents a nodular myomatous picture. The remainder is softer in character, slightly homogenous, and suggests sarcoma. The central portion of this suspicious area has undergone degeneration. Here the tissue is hemorrhagic and very friable and in this area is an irregular cavity, 5 by 4 cm., which has a smooth inner surface. The uterine cavity is of normal length and its mucosa appears to be unaltered. The appendages on both sides are normal.

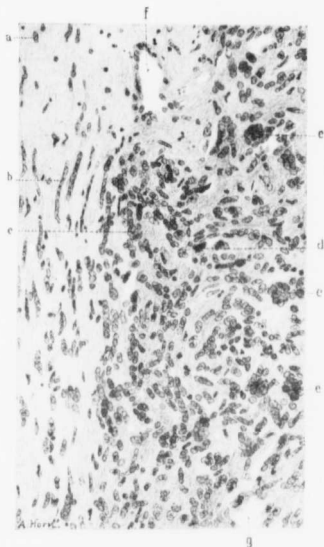


FIG. 124.—TRANSITION OF MYOMATOUS INTO SARCOMATOUS TISSUE. (X 180 diam.)

Path. No. 5730. The section is taken from Fig. 123, where the myoma is undergoing "softening," or, in other words, sarcomatous transformation. At a the myomatous tissue with some hyaline degeneration is seen. At b the nuclei, although still of the same shape, are arranging themselves in a long row, each nucleus overlapping its neighbor. At c the tissue has already become sarcomatous. There is an increased amount of chromatin at d, and at e, e, are large, mulberry-shaped giant-cells. The nuclei composing these giant-cells are similar in size to the isolated ones. f is a blood-vessel; g, one of the irregular clear spaces scattered throughout the tissue. This field is given to show the transition of the myomatous into sarcomatous tissue. Sections near the center of this tumor are the most typical examples of a mixed-cell sarcoma that we have ever seen developing from a myoma.

Histologic Examination.—Sections from the uterine cavity show that the mucosa is practically normal. The more solid portion of the large nodule springing from the posterior wall on the left side consists of typical myomatous tissue.

The softer portion presents an entirely different picture. At the junction of the myomatous tissue with the softer growth the muscle-fibers are increased in size (Fig. 124). Their nuclei are also larger and irregular and stain more deeply. The softer growth consists of spindle-shaped cells closely packed together, and scattered throughout this growth are many plaques of protoplasm containing from two to ten or more large, deeply staining nuclei. These giant-cells are everywhere in evidence. The blood-vessels in the areas above described have very thin walls and lie in direct contact with the tumor cells. A considerable degree of necrosis has taken place, large areas having undergone complete coagulation changes. In such areas the blood-vessels remain intact. In some of the large veins thrombosis has taken place, and cells of the new growth have wandered in and are replacing the blood.

We are dealing with a myoma showing undoubted transformation into sarcoma. In other places we have a large myomatous nodule presenting the typical appearance in many places, and scattered throughout it are softened areas which are clearly sarcomatous. Moreover, the histologic examination shows that there is direct transition from the myoma into sarcoma cells, all gradations being found.

Gyn. No. 10376. Path. No. 6596.

Sloughing submucous myoma undergoing sarcomatous transformation.

M. S., white, married, aged forty-five. Admitted April 1; discharged April 17, 1903. The patient complains of a pelvic tumor. She has always been healthy until the present illness. The menstrual history for five years was painful, but after that she had no discomfort. The flow has been normal up to the present illness. The patient has been married twenty-eight years, has had eight children, the eldest twenty-seven, the youngest five years old. For five years she has had very severe backache and last year rather profuse hemorrhage during the menses, and occasionally some bleeding between times. She has lost a great deal of blood, and for the past two months has been in bed practically all the time. Her strength has greatly diminished, her appetite is poor, and she is much constipated.

The patient is large and fat. The heart is dilated and extends farther to the left than usual; there is a systolic murmur at the apex, which is transmitted to the axilla; there is also a systolic murmur in the pulmonary area and a double murmur in the aortic area. The pulse is typical of aortic insufficiency, and there is probably both mitral and aortic disease. Her hemoglobin is 30 per cent. The vagina is filled with a dull red mass about 12 cm. in diameter. There is a very profuse, foul-smelling discharge. The pelvic landmarks are difficult to outline, but one can feel the edge of the cervix surrounding the pedicle of the growth.

Operation. The tumor was removed in fragments without much hemorrhage. It apparently had a broad pedicle, which was thoroughly everted. Four pieces

of gauze were packed into the uterine cavity. The highest temperature after operation was 101.8°; it dropped to normal by the fifth day. The convalescence was uninterrupted. At the time of her discharge the uterus was considerably enlarged and nodular. The symptoms, however, had been completely relieved.

Path. No. 6596. The specimen consists of fragments of a foul-smelling, friable tissue, amounting in all to about 700 c.c.; the largest piece measured 7 x 4 x 3 cm.

On histologic examination many sections are found to consist almost entirely of blood-clots rich in fibrin and containing quantities of polymorphonuclear leucocytes. In many places what at first sight appears to be blood consists of numerous very much dilated blood-vessels. Further sections show areas of myomatous tissue very rich in cell elements and here and there showing hyaline degeneration. The cells for the most part are fusiform in shape with moderately deeply staining nuclei. Others have more or less oval nuclei. Scattered throughout the tissue are several large, deeply staining, and irregular nuclei, and still other cells containing quantities of coal-black pigment. One is able to trace the transition between the ordinary muscle-fibers and the deeply staining masses. The picture is one of typical sarcomatous transformation of a myoma.

August 27, 1908, more than five years after the operation, the patient's physician, Dr. James Cooper, writes, "She is quite well."

C. H. I. No. 78. Path. No. 7555.

Sarcomatous transformation of an interstitial myoma; secondary and pure sarcomatous nodule on the posterior surface of the uterus. Myomatous nodule with sarcomatous invasion in the left broad ligament (Figs. 125, 126, 127, 128, and 129).

L. T., white, married, aged fifty. Seen in consultation with Dr. Lilian Welsh and admitted May 30, 1904. For several years the patient has suffered from uterine fibroids and also from a growth in the right breast. Recently the growth in the pelvis has materially increased in size. There has been a great deal of pain extending down the left leg. Examination under anesthesia shows the uterus to be considerably enlarged, and extending off from it is a large mass involving the left broad ligament.

Operation. On opening the abdomen we found the uterus considerably enlarged, and attached to its posterior surface was a cockscorn-like growth fully 15 cm. in length (Figs. 125 and 126). To the left of the uterus and attached to it was a mass filling the entire broad ligament (Fig. 127), and extending up to the pelvic brim. This was thought to be malignant, and no attempt was made to remove it. A supravaginal hysterectomy seeming preferable as a palliative procedure.

June 11, 1904. After having carefully examined the uterus macroscopically we came to the conclusion that the growth was benign, and therefore determined

to remove the large mass in the left broad ligament. A long incision was made parallel to the left Poupart's ligament and extending up to the left flank. The peritoneum was pushed upward and forward until we came in contact with the mass. This was dissected out with little or no hemorrhage; in fact, no ligatures were necessary. As the pelvic cavity was accidentally opened low down, a small drain was carried to the bottom of the wound. The patient made a perfectly satisfactory recovery. She was advised to return in a few months to have the breast amputated, but procrastinated. When she came back in March, 1908, there were inoperable carcinomata of both breasts.

Path. No. 7555. The uterus is fully three times the natural size and is somewhat globular. The portion present is 8 cm. in length, 9 cm. in breadth, and 9 cm. in its antero-posterior diameter. Its anterior surface is smooth. Its posterior surface is prominent, apparently owing to the presence of a tumor in its walls. Attached to the posterior surface by a narrow pedicle is a cockscomb-shaped growth, 15 cm. in length. It is sharply differentiated from the uterus. At its upper pole it is adherent and forms a depression on the fundus. Near its middle it is also attached to the uterus by a broad pedicle. The lower

half is separated from the uterus by an interval of fully 5 mm. The lower end has lain deep in Douglas' pouch, and has molded itself to the surface of the sacrum (Fig. 126). This cockscomb-like growth varies from 3 to 5 cm. in breadth and projects from 2 to 3 cm. from the surface of the uterus. It has a lobulated appearance, due to the coarse and fine molding of the surface. On section the growth in places closely resembles a myoma; at other points it is very homogeneous, showing little striation, and has an appearance suggesting sarcoma. On section of the uterus nearly the entire cavity is found filled with a growth 4.5 cm. in diameter and somewhat irregular. It is composed of lobulations

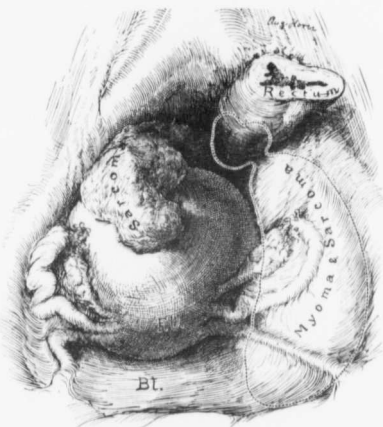


FIG. 125.—SARCOMATOUS TRANSFORMATION OF A MYOMA WITH A SECONDARY GROWTH ON THE POSTERIOR SURFACE OF THE UTERUS.

Path. No. 7555. The uterus is considerably enlarged and on its posterior surface is a growth roughly resembling a cockscomb. Histologic examination showed it to be a pure sarcoma (Fig. 129). The dotted lines indicate the confines of a myosarcoma in the left broad ligament. For the interior of the uterus, see Fig. 126. For the mass in the left broad ligament, see Fig. 127.

which have smooth surfaces and vary from 1 to 5 mm. in diameter. On section this growth might be taken for a degenerating myoma or for a sarcoma.

On examination of the hardened uterus the walls are found everywhere infiltrated by the growth, which in some places suggests myomatous tissue, in others the homogeneous appearance of sarcoma. The appendages offer nothing of interest.

The mass from the left broad ligament, which was removed at the second operation, is 13 cm. in length, 8 cm. in breadth, and approximately 8 cm. in

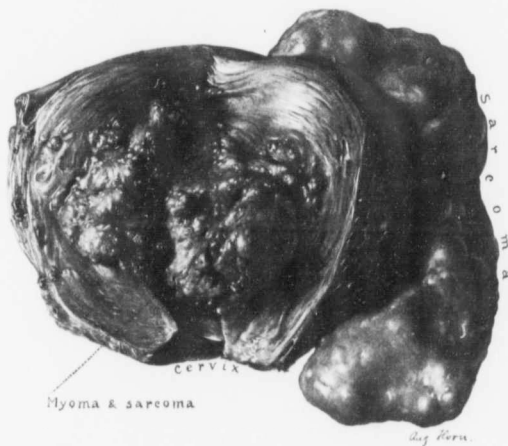

FIG. 126.—MYOSARCOMA OF THE BODY OF THE UTERUS WITH A SECONDARY AND PURE SARCOMATOUS COCKSCOMB-LIKE GROWTH ON THE POSTERIOR SURFACE. (1 nat. size.)

Path. No. 7555. The uterus has been opened anteriorly. Behind the uterus is the cockscomb-like sarcoma. (See Fig. 125.) Occupying the body of the uterus is a rather diffuse myoma, which on histologic examination showed marked hyaline degeneration and definite sarcomatous transformation of the muscle-fibers (Fig. 128). The cockscomb-like growth is attached to the posterior surface of the uterus by a broad pedicle, which consists essentially of a pure sarcomatous growth (Fig. 129).

thickness. It presents a markedly lobulated appearance. These lobules vary from a pin-point to 3 cm. in diameter; they have a mottled appearance in places, and are made up of secondary lobules not more than 1 mm. in diameter. On section some portions of the growth present the typical picture of myoma; others are homogeneous, mottled, and strongly suggest sarcoma. The center of the growth contains much blood. At the upper end of the growth and lying over the bifurcation of the pelvic vessels is a lobular nodule, 4 by 3 cm. (Fig. 127). This on section appears to be a myoma, although at operation it was supposed to be an enlarged and hardened lymph-gland.

Histologic Examination.—Sections from the uterine mucosa show that the cervical glands are perfectly normal and that the surface epithelium of the cervix is intact. In the body of the uterus the surface epithelium is still preserved. The glands are normal. The stroma just beneath the surface shows some edema and there is some slight dilatation of the glands. The uterine mucosa can be traced directly up to the growth occupying the fundus and encroaching on the cavity. This growth in the lower portion presents a typical myomatous picture. The greater part of the myoma has, however, undergone hyaline degeneration, only a few nuclei remaining.

Sections from the body of the uterus, also through the growth, likewise show much hyaline degeneration. We note, however, that the nuclei that still remain in this hyaline material, here and there show an increase in size, being two or three times as large as normal and staining rather deeply (Fig. 128). In other areas, where the myomatous tissue is still well preserved, we have a rather active condition of the cells, although the bundles are still perfectly preserved. The nuclei are here also two or three times as large as normal and stain deeply. That this alteration is going on in the bundles and cells is perfectly clear, as the outline of the bundles is in no way distorted. In other portions of the growth we find a totally different picture. We have scattered throughout the muscle masses of cells that at first sight look like carcinoma nests. On careful scrutiny it is found, however, that

the individual nuclei forming these nests are uniform in size throughout, and that they come out much more clearly than is usual in carcinoma, each cell being sharply circumscribed. The growth would undoubtedly be taken for carcinoma.

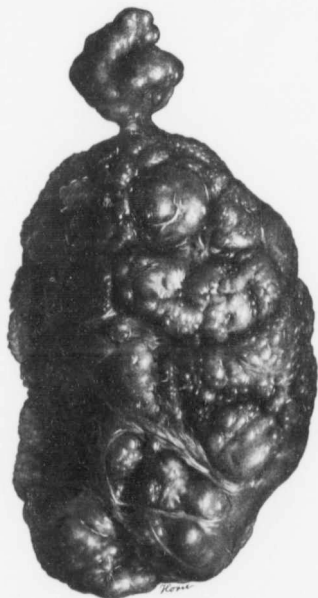


FIG. 127.—THE LOBULATED AND MYOMATOUS NODULE REMOVED FROM THE LEFT BROAD LIGAMENT IN FIG. 125. (1/3 nat. size.)

Path. No. 7555. This nodule was shelled out of the left broad ligament twelve days after removal of the uterus. An incision was made parallel to and just above Poupart's ligament. The peritoneum was gradually pushed medianward until the nodule was perfectly free. It was removed without it being necessary to control any blood-vessels. The small and partially constricted nodule *a* was at first thought to be an enlarged gland, but in reality it formed part of the large nodule. Histologic examination showed that the growth was a myoma with marked hyaline degeneration. It also contained typical sarcomatous tissue.

The true character is well shown in the cockscomb-like growth attached to the posterior surface of the uterus. Here we have a homogeneous sea of cells divided by a framework of connective tissue just sufficient to carry capillaries (Fig. 129). The individual cells have oval vesicular nuclei, and in the entire field practically all are of the same size and show the same staining properties. The picture here is one of typical sarcoma. The character of the growth would also indicate sarcoma. If we were dealing with carcinoma, we would not for a moment expect the entire cockscomb-shaped growth to be firm in texture and show at no point the slightest tendency to break down. This entire growth is

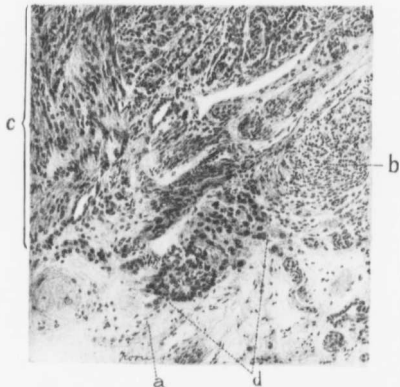


FIG. 128.—COMMENCING SARCOMATOUS TRANSFORMATION OF MYOMATOUS TISSUE. (X 100 diam.)

C. H. L., No. 78. Path. No. 7555. The section is from the submucous myoma seen in Fig. 126. At *a* the tissue has undergone almost complete hyaline degeneration. At *b* are cross-sections of muscle-fibers of the usual size. Over the area indicated by *c* the nuclei of the muscle-fibers are two or three times as large as usual and stain deeply. In the area indicated by *d* the nuclei are still larger, suggesting a rather active process. For the typical sarcomatous development, see Fig. 129.

made up of typical sarcomatous tissue. The differentiation is particularly well brought out by the van Gieson stain.

The nodular mass shelled out from the left broad ligament consists for the most part of a myoma that has undergone almost complete hyaline degeneration. Little tufts of muscle-fibers still persist, especially around the blood-vessels. About nine-tenths of the field consists of hyaline tissue. In these hyaline areas, however, we find cells sometimes four or five times the usual size, the central nuclei being surrounded by a broad zone of fine dark dots, looking very much like plasma cells. Other portions of this broad ligament growth are totally different. Here the cells have undergone coagulation necrosis, but one still makes out areas of malignant cells similar to those in the cockscomb-like growth. In

still other portions of the growth we find the muscular elements in the hyaline areas staining very sharply and showing a tendency to increase in size and to augment their supply of chromatin.

The nodules situated in the bifurcation of the iliac vessel are composed of fibrous tissue and of nests of sarcoma cells. In this specimen we have at certain points a glandular arrangement. No lymphoid elements can be detected, consequently it is not a lymphatic gland that has been invaded by the new growth.

We have here, then, a uterus twice its natural size, and with the fundus occupied by a lobulated growth which penetrates the uterine wall and forms a cockscomb-like growth on the outer surface. We also have a large irregular growth situated between the folds of the left broad ligament. The growth occupying the body of the uterus is to a great extent composed of a finely lobulated myoma which has undergone partial hyaline degeneration. The fibers of this myoma in certain areas show a marked tendency to proliferate and become malignant, notwithstanding the fact that muscle-bundles are still well preserved. The outer portions of this growth consist of tissue in no way distinguishable from sarcoma. The cockscomb-like growth is sarcomatous. The left intraligamentary nodule has to a large extent undergone hyaline transformation, but it also has been invaded by a new growth which started from the uterus. We have been unable to find any similar case in the literature. In all probability the myoma was the primary factor, and this myoma is undergoing sarcomatous transformation, and we believe, although we are not in a position to prove it, that the sarcomatous cockscomb-like growth of the uterus is secondary to the sarcomatous degeneration of the myoma, and that it is nothing more than an outgrowth of the sarcoma in the uterus. From a clinical standpoint it is particularly interesting that this patient is perfectly well, as far as the pelvic lesion is concerned.

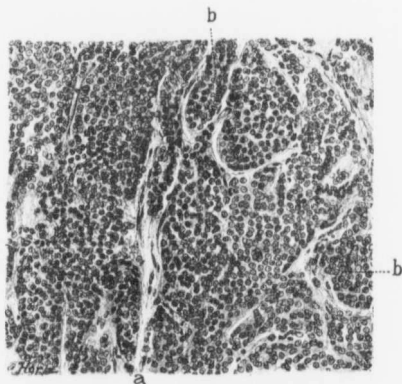


FIG. 129.—A SARCOMA THAT HAS DEVELOPED FROM AN INTERSTITIAL MYOMA. (X 125 diam.)

C. H. I. No. 78. Path. No. 7555. The section is taken from the cockscomb-shaped sarcomatous growth on the posterior surface of the uterus seen in Fig. 126. The malignant changes first commenced in an interstitial and partially submucous myoma and the secondary growth was a pure sarcoma, as seen in this picture. The cells are large and remarkably uniform in size. This sea of cells has delicate strands of stroma (a) scattered throughout it and dividing the growth into alveoli of various sizes, as indicated by b. The picture is typical of sarcoma.

C. H. I. W., Jan. 22, 1903. Path. Nos. 6421-8370.

Supravaginal hysterectomy supposedly for simple interstitial and subperitoneal myomata. Two years later sudden collapse due to hemorrhage from a sarcoma developing from the cervical stump (Fig. 130). Reëxamination of the original tumor showed typical sarcomatous transformation of the myoma (Fig. 131). Later intestinal obstruction; artificial anus with complete control. Death eight months after the second operation.*

Mrs. W., white, aged forty-two. Seen in consultation on January 22, 1903. For several years the menstrual periods have been exceedingly free. From time to time she has been treated for dyspepsia and for some cardiac lesion, but not until recently has any abdominal enlargement been detected. She is well nourished, but is exceedingly pale. The mucous membranes are blanched and the hemoglobin is 30 per cent. On vaginal examination the cervix is found to be normal, but filling the vaginal vault and extending half-way to the umbilicus is an irregular myomatous uterus. Above and to the right is a globular mass the size of a kidney. One of the most interesting phenomena is a thrill felt by the examining finger along the course of the left uterine vessels.

Operation. The uterus was brought up without much difficulty, and the large mass felt in the region of the liver proved to be a subperitoneal and pedunculated myoma. The uterus was removed from left to right. The left tube and ovary were not disturbed. The patient stood the operation well and lost very little blood. Phlebitis developed some days after operation, but did not retard her progress very much. Within a month her color had returned, and in less than three months she appeared to be in perfect health. I saw her on January 21, 1905, and she was in excellent condition.

Second operation, February 17, 1905. The patient felt perfectly well and went to market yesterday morning. About 1 p. m. she was taken with pain in the lower abdomen, and a little later almost fainted while at stool. Dr. Nathan R. Gorter was called to see her and advised immediate removal to the hospital.

On examination under anesthesia we found the pelvis partly filled with a mass the size of a small coconut. This apparently involved the left side more than the right. The left ovary having been saved at the previous operation, we thought that this tumor was certainly ovarian in origin. On opening the abdomen the left ovary was found to be perfectly normal, but projecting from the stump of the cervix, and extending down between the cervix and the rectum, was a definite sarcomatous nodule fully 10 cm. across (Fig. 130). This was somewhat lobulated. It had been slightly lacerated and free bleeding had occurred. We removed at least a quart and a half of free blood and clots from the abdominal

* Cullen, Thomas S.: Sarcomatous Transformation of Myomata, Jour. Am. Med. Assoc., March 10, 1906.

cavity. Her sudden discomfort had evidently been due to partial tearing of the growth. We were able to peel the growth out to a great extent, but it was impossible to remove it in its entirety.

The left lobe of the liver was sharp, the right lobe very blunt and thickened. We thought we were dealing with a hepatic metastasis, but on continuing the

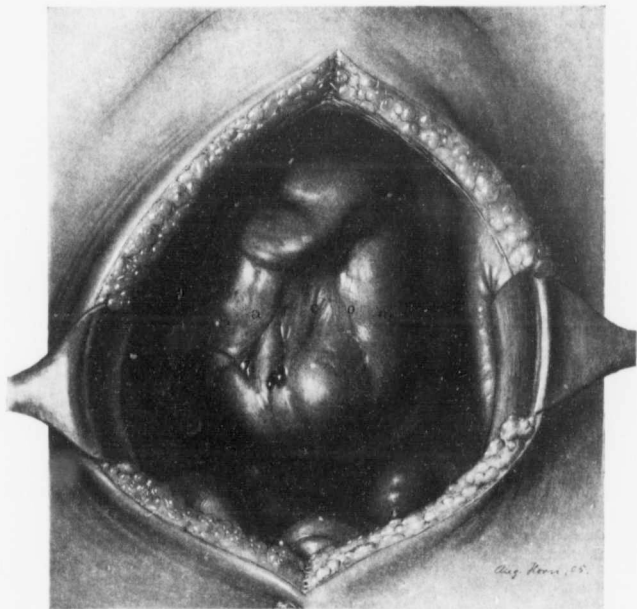


FIG. 130.—SARCOMA DEVELOPING IN THE CERVICAL STUMP.

Path. No. 8370. The pelvis is viewed from above. Rising from the pelvis between the bladder and the rectum is a smooth, lobulated growth presenting a somewhat scarred appearance. To the left is the intact and normal left ovary. The right appendages were removed at the first operation.

incision upward, found there was merely thickening of the liver. The omentum was free. The appendix was removed.

The condition is particularly interesting when we remember that the uterus had been removed two years before and that the patient had remained perfectly well.

Postoperative History.—The patient was readmitted to the Church Home on August 21, 1905. For the preceding four or five weeks she had great difficulty

in securing an evacuation of the bowels. On examination we found the pelvis practically filled with a new growth, rendering necessary the making of an artificial anus. The bladder was definitely implicated by the growth and the urine contained large quantities of blood. I made an incision through the left rectus, brought out the sigmoid flexure, cut it in two, closed the lower end, brought the upper end out through the rectus, passed it outward beneath the sheath of the rectus for about an inch and a half, then made a longitudinal section through the sheath of the rectus and through the fascia to the skin, attaching the bowel to the skin. The bowel, therefore, was brought upward, then outward, and then upward again. The patient experienced a great deal of relief. Her bowels moved once or twice a day, but she had practically absolute control, as there was no escape of fecal matter except at stool. She improved considerably. Occasionally there was some discomfort from the rectal tenesmus due to the ever-increasing growth pressing on the remaining portion of the rectum; otherwise she was comfortable. She remained in the hospital until October 1st. During the last two weeks of her life she became much weaker and died October 30, 1905.

Path. No. 8370. A sarcomatous growth developing from the cervical stump. The specimen (Fig. 130) consists of a mass of tissue, 10 x 8 x 5 cm. It is somewhat lobulated, rather smooth, and on its under surface has a basal attachment extending over an area 5 x 5 cm. The tissue is of brain-like consistence, yellowish-white in color. It is very friable. On section the mass is found to contain a large, irregular area of hemorrhage. At one point is a cystic space 2 x 1.5 cm. This is divided by trabeculae into smaller spaces and is filled with blood-clots. The general character of the growth is clearly evident without histologic examination.

Histologic Examination.—The tumor is found to be made up of a sea of cells. Most of these have oval vesicular nuclei and bear a striking resemblance to those of muscle-fibers. The cells themselves are spindle-shaped, with deeply staining nuclei, two or three times the natural size. Others are irregular and also stain deeply. In places we have masses of protoplasm containing five or six deeply staining nuclei. At other points there are giant-cells in which the nuclei are not over one-third the usual size. In places are seen spindle-cells undergoing division. There are large, irregular plaques of protoplasm containing fragmented nuclei and cells showing typical nuclear figures. The nucleus itself is sometimes divided into five or six young nuclei. The blood-vessels are large and abundant. The majority of them appear to be veins. Some are filled with thrombi and the tumor cells are gradually obliterating them. In fact, dividing tumor cells can be demonstrated lying free in such blood-vessels. In some places the tissue is much rarefied. In such areas giant-cells are particularly abundant. The growth is essentially a spindle-celled sarcoma which shows a marked tendency toward giant-cell formation.

Path. No. 6421. Description of the original tumor. The specimen (Fig. 131) consists of a globular uterus, approximately 18 cm.

in diameter. It is smooth and glistening. On the surface one or two nodules can be detected. Attached to the right cornu is a kidney-shaped subperitoneal nodule, 13 cm. in length and 8 cm. in breadth. It is attached by a pedicle, 2.5 x

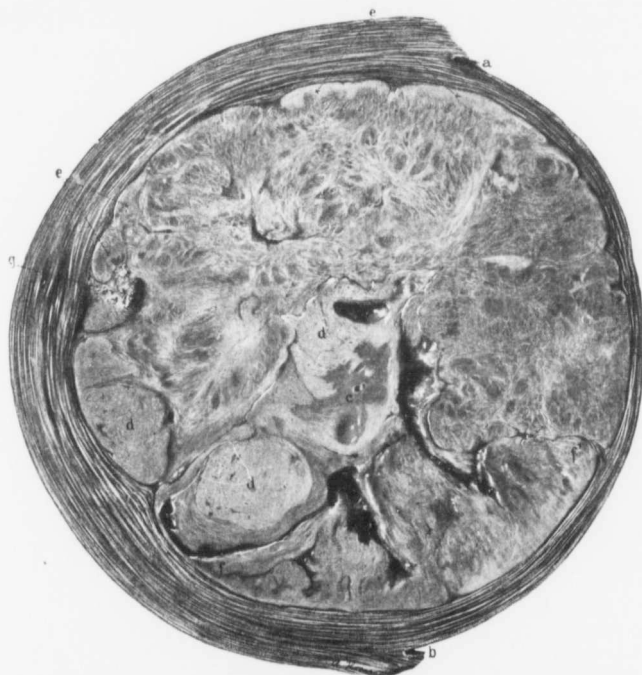

FIG. 131.—SARCOMATOUS TRANSFORMATION OF A UTERINE MYOMA. SUPRAVAGINAL AMPUTATION WITH RETURN OF THE GROWTH IN THE CERVICAL STUMP. ($\frac{1}{2}$ nat. size.)

Path. No. 6421. The picture represents a longitudinal section through the entire uterus. *a* is the upper limit of the uterine cavity; *b*, the lower or cervical portion. It is thus seen that the myoma occupying the posterior wall projected into the uterine cavity and put the mucosa on tension. The myomatous nodule is approximately circular and in many places yields the usual myomatous striation. At *e* is an area of typical hyaline degeneration, recognized by its homogeneous appearance. At numerous points indicated by *d* we find sharply outlined granular or spongy areas, which are at once recognized as sarcomatous. At *e* along the outer margin of the myoma are areas of sarcoma, and the tissue between *f* and *f'* is partly myomatous, partly sarcomatous; *g* is an area of calcification.

1.5 cm., and is freely movable. The uterine cavity is 17 cm. in length, and is markedly convex, owing to the fact that the tumor projects inward from the posterior wall. The mucosa on the whole looks normal, but is atrophic. Near

the fundus it has undergone in some places almost complete atrophy, the growth in the posterior wall shining through.

The enlargement of the uterus is due chiefly to a circular nodule 13.5 cm. in diameter, occupying the posterior wall. This nodule is almost spherical. The central portion has in part undergone typical hyaline degeneration, as is evidenced by large and small spaces traversed by delicate trabeculae. On careful examination there are several areas presenting a homogeneous spongy appearance (Fig. 131). These form a part of the myomatous tissue. They vary from 1 to 4 cm. in diameter, are irregular in their distribution, and have undoubtedly developed from the myomatous tissue. They give the characteristic appearance of sarcoma and are distributed throughout the solid portion of the tumor, being also intermingled with areas of hyaline degeneration. Macroscopically one is able to diagnose with absolute certainty a sarcoma developing from the myoma. The uterine walls posterior to the tumor vary from 1 to 1.5 cm. in thickness, and in some places there is a covering of from 2 to 5 mm. of uterine muscle separating the growth from the mucosa.

Histologic Examination.—The areas indicating hyaline degeneration are entirely devoid of nuclei. Here the tissue has undergone the usual complete hyaline transformation. Many sections have been taken from the areas suggesting sarcoma. In the majority of these most of the elements have undergone complete coagulation necrosis. Here and there, however, in the vicinity of the blood-vessels are a good many small round cells. In some of the sections in which there is incomplete hyaline degeneration a good many muscle-fibers are still preserved and there are quantities of mast cells. The nuclei of the muscle-fibers show considerable variation in size and staining properties. One is instantly reminded of a sarcomatous transformation. In the more characteristic sarcomatous areas, where the cells are still preserved, we find similar histologic changes. The nuclei are four or five times the natural size, are irregular in outline, and stain very deeply. In other places we have very large, irregular cells with protoplasm that takes the eosin stain deeply, and irregular nuclei situated in the centers or at the margins of the cells. Again, some cells contain six or seven nuclei. The picture instantly suggests sarcoma, but it is impossible to tell with certainty whether the growth has really started in the muscle-fibers or whether it has originated from the connective tissue. On the whole, the evidences of muscle origin appear to be the more reliable. In some of the hyaline areas the blood-vessels still persist, the endothelium is present, and the cells of the vessels are stained deeply and are irregular, suggesting that the connective tissue of the vessel wall is also undergoing a malignant change. The deeply staining cells stand out in sharp contrast with the surrounding areas of hyaline degeneration. Macroscopically and microscopically areas of calcification are evident. At no point do we find any evidence that the sarcoma extends beyond the confines of the myoma. The specimen was examined in the laboratory immediately after the first operation and longitudinal sections were made. In

these degenerative changes were noted, but through an unfortunate circumstance no further sections were made, and it was not until after the second operation, more than two years later, that we found the sarcoma springing from the cervical stump. When the original tumor was again examined, even a casual glance showed areas of hyaline degeneration in the myoma and also irregular areas of typical sarcoma.

A consideration of this case might well raise the question whether a complete hysterectomy would not be advisable in all cases. But the supravaginal operation is the easier one; it leaves better support to the pelvic floor, there is less danger of tying the ureters, and as the blood-supply of the bladder is but little interfered with, there is less likelihood of a postoperative cystitis. The advantages of the supravaginal operation would appear to more than outweigh the objection that there is an occasional occurrence of malignant changes in or associated with myomata. This case, however, clearly indicates that we should carefully examine not only the uterine mucosa for carcinoma, but also the myomata for sarcomatous changes before the cervical stump is closed.

Gyn. No. 7313. Path. Nos. 3673 and 3576.

A sloughing submucous myoma; large spindle-celled sarcoma occupying the anterior uterine wall, and implicating the uterine cavity (Figs. 132, 133, and 134). Formation of a secondary nodule in the right broad ligament; small interstitial myomata; localized endometritis. Later implication of the cervical glands and probably secondary growths in the lungs and pleuræ.

L. H., white, married, aged forty-five. Admitted October 25; discharged November 29, 1899. Complaint, tumor of the uterus. The patient has been married seventeen years, has had one child and one miscarriage. The child is fourteen years old. The patient had an instrumental labor, was in bed twelve weeks, and had chills and some fever. Her menses commenced at fourteen and have been regular every four weeks until nine months ago. They have always been profuse, and she has had a great deal of hemorrhage since the tumor was first noticed. The hemorrhage began in April, 1899, and the loss of blood has been almost continuous, but more marked at the menstrual periods. Two weeks ago she had a chill and a necrotic submucous myoma, 14 x 8 x 8 cm. in diameter, was expelled. The temperature was 100.4°; the pulse was 104. Three days preceding this she had labor-like pains. On abdominal examination a tumor is found extending 9 cm. above the umbilicus.

Operation, November 1, 1899. Abdominal hysterectomy. The omentum was adherent to a subperitoneal nodule, 7 x 7 cm. It was tied off, and the entire mass lifted out. Dense adhesions were cut, and the uterus was amputated just above the vaginal vault. On the right side was a large abscess full of thick

pus. The abscess was situated beneath the broad ligament; it was attached to the rectum and had burrowed about 4 cm. along the vagina on the right side. The vaginal vault was opened, and an iodoform gauze drain carried into the vagina. The cervix was covered over with peritoneum in the usual way, and the abdomen closed. The abscess originated in the tube. The maximum post-operative temperature was 100.6°. It reached normal on the eleventh day, and the patient made a satisfactory recovery.

This patient had been seen in May, 1899, and immediate operation was advised, but she decided to wait until the fall, thinking that the tumor might disappear.

Path. No. 3673. The specimen consists of a submucous myoma, spontaneously expelled from the uterus. It is 13 cm. in length, and varies from 3 to 5 cm. in breadth. The surface is comparatively smooth and of a bright red color. At the lower end the tumor is partially subdivided by a cleft 2.5 cm. in depth. The growth at its base, where attached to the uterus, is 3 cm. in diameter. On pressure it is firm and tough. At its extremity it appears to be gangrenous and has an exceedingly foul odor. On section, it does not present the characteristic appearance of myoma. It has a very abundant blood-supply, some of the vessels reaching 2.5 mm. in diameter.

Histologic Examination.—In sections taken from various portions of the tumor no trace of the mucosa is to be made out. The surface is entirely necrotic. The cell-outlines are no longer visible, but just beneath the surface are many fragmented polymorphonuclear leukocytes. In the deeper portions a few muscle-fibers are still visible. Here and there are large irregular and deeply staining nuclei. Scattered throughout the necrotic tissue are myriads of cocci, and some of the blood-vessels are filled with them. The deeper portions of the tumor consist of non-stripped muscle-fibers, showing much diffuse hyaline degeneration and a high degree of vascularity. The appearances are typical of a sloughing submucous myoma.

Path. No. 3576. The specimen consists of an enlarged and irregular uterus with the appendages intact. The uterus, which has been amputated through the cervix, is 15 cm. in length and 15 cm. broad. It has a smooth surface, and anteriorly is covered with peritoneum. Posteriorly are numerous dense adhesions; attached to the fundus is a soft, friable mass, 6 x 4 cm. This can be torn readily and seems to be arranged in long threads. On section, the great increase in size of the uterus is found to be due to a growth occupying chiefly the anterior wall. This growth reaches 9 cm. in thickness, is yellowish white in color, homogeneous in consistence, and divided into smaller lobules by glistening fibrous trabeculae (Fig. 132). In some portions this growth is honeycombed with small, cyst-like spaces, varying from 1 to 7 mm. or more in diameter. The tumor is sharply outlined from the uterine muscle, and in the middle of the uterus extends to the mucosa. Near the internal os it is devoid of mucosa and lies free in the cavity. It implicates the fundus, but does not encroach upon the

posterior wall. Situated in the posterior wall, however, is an interstitial myoma, 2 cm. in diameter. The uterine cavity is 11 cm. in length. The mucosa of the cervical portion is thin, and that of the body is also atrophic. Occupying the right broad ligament, and intimately connected with the uterus, is a nodule, 10 x 9 x 8 cm. This, on section, consists of the same homogeneous tissue that formed the tumor occupying the anterior wall. The central portion contains

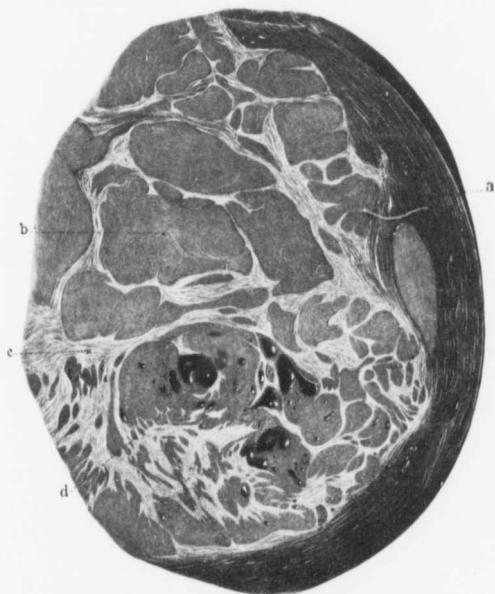


FIG. 132.—SARCOMA OF THE ANTERIOR UTERINE WALL. ($\frac{1}{2}$ nat. size.)

Path. No. 3576. *a* is the outer covering of normal muscle; *b*, the smooth homogeneous sarcomatous tissue, which is divided up into large and small islands by the bands of stroma, *c*. This stroma is fibrillated, and seems to be composed of myomatous tissue. Scattered throughout the sarcoma are many smooth-walled, cyst-like spaces (*d*), varying from 1 to 10 mm. or more in diameter.

an irregular, cyst-like cavity (Fig. 133), approximately 5 x 3 cm., and scattered throughout the growth are minute cysts.

On the right side the tube is 11 cm. long, and gradually increases in diameter from 6 mm. to 3.5 cm. at its distal extremity. It is covered with vascular adhesions. The ovary is bound to the tube and posterior surface of the uterus. It measures 3.5 x 2 cm., and contains a small cyst.

On the left side the appendages are apparently normal.

Histologic Examination.—Sections from the uterine mucosa show that the surface epithelium is intact, but that in a few places it is slightly thickened. Here and there the surface is covered with polymorphonuclear leukocytes, and at such points the mucosa is represented by granulation tissue. In most places, however, the uterine glands are normal, and the stroma, apart from localized small-round-celled infiltration, shows little alteration. We have a fairly normal mucous membrane, with foci of endometritis. The growth occupying the anterior uterine wall consists of large quantities of spindle-cells arranged in

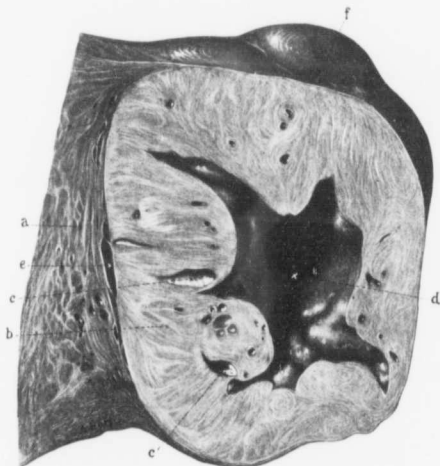


FIG. 133.—A LARGE SARCOMATOUS NODULE CONTAINING AN IRREGULAR, SMOOTH-WALLED CAVITY IN ITS CENTER. ($\frac{1}{4}$ nat. size.)

Path. No. 3576 a represents the uterine muscle, which is coarser than usual; b is the sarcomatous growth, which, although showing some fibrillation and whorls, is fairly homogeneous. Scattered throughout the growth are several small, irregular, cyst-like spaces, as indicated by c, and the center of the growth is made up of an irregular, smooth-walled cavity, (d). Histologic examination failed to reveal any epithelial or endothelial lining to this space. The sarcoma, while in places intimately blended with the muscle, at other points, as seen at e, is very loosely connected. At f the sarcoma has reached the peritoneal surface, forming a distinct prominence.

bundles. These have been cut lengthwise and transversely, and the picture at first sight suggests a very cellular myoma. But on further examination it is found that many of the nuclei are two or three times the length and double the breadth of those near them, and furthermore, that they stain intensely. Careful scrutiny shows that even in a single field it is possible to detect six or more minute nuclear figures in different stages of development. Other sections contain myriads of deeply staining nuclei. So abundant are they in places that they form fully half the field. Large areas of the growth have undergone complete coagulation

necrosis, and in the vicinity of such points many of the cells of the growth contain brown granular pigment. In the scanty amount of stroma numerous small round cells are demonstrable. The nodule situated in the right broad ligament is of the same character. The growth is, of course, malignant, and is a spindle-celled sarcoma (Fig. 134). At one point it is possible to trace the gradual transition of the muscle-fibers into the sarcomatous tissue.

In this case, from the general contour of the uterus on bimanual examination, one would naturally render a diagnosis of myoma. So characteristic was the growth in its outline that the assistant who wrote up the gross description before the organ was opened spoke of it as a myomatous uterus. This assumption naturally would be fully justified by the history of the submucous myoma.

The right tube is the seat of a subacute salpingitis; the left tube is normal.



FIG. 134.—PROBABLE SARCOMATOUS TRANSFORMATION OF BUNDLES OF MYOMATOUS TISSUE. ($\times 80$ diam.)

Path. No. 3576. The section is from the sarcoma seen in Fig. 132. The upper half of the field, as indicated by a, is composed of myomatous tissue; the lower part (b), of sarcomatous tissue; c is also sarcomatous tissue, and at d the muscle-bundles appear gradually to merge into the sarcoma. Some of the muscle-bundles have undergone necrosis.

The subsequent clinical history of Mrs. H. is of interest. Dr. Osler, in a letter dated November 12, 1902, writes: "I saw her with Drs. Humrichouse and Scott, of Hagerstown, on November 1, 1901. She had lost much in weight. There was great pain in the left side, dyspnea, dullness on the left side of the chest, uniform flatness, retained vocal fremitus, feeble, distant breathing, no dislocation of the heart. The glands were involved above the clavicle. I think there was no doubt of the correctness of the diagnosis made by the doctors of secondary growth in the lungs and pleura. Then we found out from Cullen that there was a sarcomatous degeneration of a myoma. She died a few weeks later."

Gyn. No. 12155. Path. No. 8723.

Sarcomatous transformation of the muscle-fibers in one myoma (Fig. 135) of a large myomatous uterus. Hysterectomy. Return of patient with abdominal metastases.

L. Q., colored, aged forty-eight, married. Admitted May 29; discharged June 24, 1905. The patient complains of pain in the left side of the abdomen and also in the back. Many of her relatives died of tuberculosis. Her menses began at twelve, were always regular up to two years ago, when they began coming at shorter intervals and the flow lasted from eight to ten days; it was free, but not painful. Two years ago they lasted as long as three weeks at a time. The last period was three months before admission. There was excessive bleeding, but there has been no hemorrhage since. The patient has been married fourteen years, has had no children, but one miscarriage twenty-three years ago. There has been a foul leukorrhoeal discharge at times for the past year.

Three years ago the patient felt a small mass in the right lower abdomen. It was about the size of a hen's egg. Two years ago this commenced to increase in size and to be tender to the touch. It would swell up and then decrease again. About this time she noticed a swelling in the feet, and was told by her physician that she had a tumor.

The tumor has apparently grown much more rapidly during the last few months, but there were no marked symptoms until about three weeks ago, when the patient began to complain of severe pain in the left lower abdomen, radiating to the back and down the left leg. For two years she has had some difficulty at times in voiding. There has been increased frequency, the amount of urine has been scant, and it has been difficult to start the flow. The patient has had a severe cold during the past winter. There are no marked heart or lung symptoms, though the patient is troubled with night-sweats.

She has been rapidly losing in weight.

On admission she is thin and pale. On abdominal examination a rounded swelling is found extending from the symphysis to the ensiform cartilage. Respiration is markedly limited. There is a small umbilical hernia. The ring admits the tip of the index-finger, and through it the finger can be forced into the abdominal cavity and can readily palpate a hard tumor. On bimanual examination it is possible to feel at least two large tumor masses. The diagnosis lies between a multinodular myomatous uterus and an ovarian cyst.

Operation. On opening the abdomen about two ounces of clear yellow serum were found in the abdominal cavity. Occupying the upper part of the abdomen was a large tumor, attached by a pedicle, 3 cm. in diameter. The tumor has made a three-fourths turn on itself. This readily accounts for the presence of the free fluid. The omentum was adherent to the upper pole of the tumor for a distance of 14 cm. Some of its vessels were from 1 to 2 mm. in diameter. There

was one adhesion on the left side, between the anterior abdominal wall and the tumor; this measured 2 x 0.5 cm. After some difficulty the uterus was removed. Little or no bleeding occurred. The highest postoperative temperature was 100.6°. The patient made a satisfactory recovery.

Second admission: The patient entered the hospital again on February 18, 1906, complaining of pain in the arms and left side of the abdomen. When she left the hospital in June she was in fair health, and remained so until October 1, 1905. She then began to feel a drawing, tingling sensation in the hands and finger-tips, and on account of poor circulation had to wear three pairs of gloves during the winter. About three weeks before admission she noticed her abdomen getting fuller, so that it was impossible for her to wear corsets. There was a "sticking pain" in the right side and also in the back. There was no fever and no vomiting. On examination there was dulness in the right side, and continuous with the liver and extending over as far as the left of the nipple. Occupying the right upper abdominal quadrant was a large firm mass which had thick, rounded margins. On its inner side was a notch resembling that between the lobes of the liver or the hilum of the kidney. The mass was so large that it was only slightly movable. It was very distinct posteriorly in the flank. A renal catheter was introduced and the kidney injected. Injection of 9 c.c. of fluid brought on pain, apparently located in the lower part of the tumor. A bladder examination showed nothing abnormal. At this time it was impossible to tell the exact character of the tumor, as the changes in the myoma had been totally overlooked in the laboratory. This was due to the fact that the tumor was supposed to be nothing more than a simple myomatous uterus, so that instead of making a systematic examination of each myomatous nodule, the pathologist had merely opened the uterine cavity and split the larger nodules. The patient shortly afterward left the hospital, although she had a temperature of 101° F. and had been lying in bed in a listless condition.

March 28, 1906: The patient entered St. Joseph's Hospital to be examined. She had lost greatly in weight and strength since leaving the Johns Hopkins Hospital. Her face was much emaciated, the ribs were prominent, and the abdomen was much distended with free fluid. Several irregular nodules were felt in the abdomen. At this time some skin metastases were seen in the abdominal wall. The patient was tapped later, and a small amount of bloody ascitic fluid withdrawn. She died on the following day.

Autopsy showed that the kidneys were normal. The abdominal tumor was apparently a sarcoma of the liver, two large nodules being found, one in the right, the other in the left, lobe. There were general metastases throughout the abdomen.

Path. No. 8723. The specimen consists of the body of the uterus, part of the right tube, and of large myomatous masses. The specimen is divided into two masses, connected by a twisted pedicle, 4 cm. in diameter. The smaller mass consists of the much distorted body of the uterus, with three myomatous nodules.

The upper and larger mass is composed of one large heart-shaped tumor that measures 21 x 22 cm. The upper mass is yellowish-white in color and has

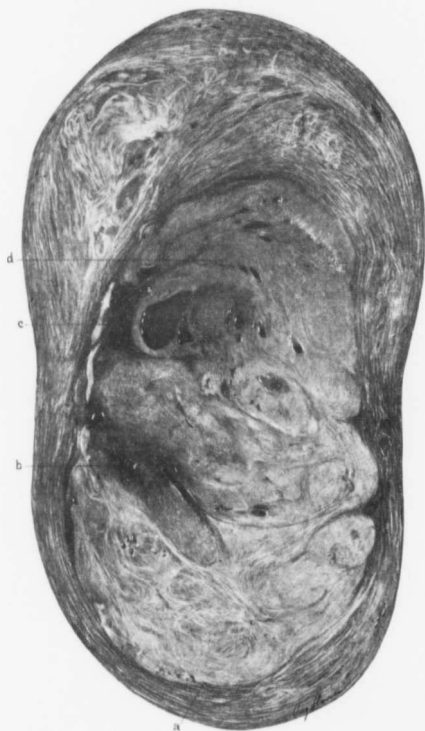

FIG. 135.—SARCOMA DEVELOPING IN THE CENTER OF A SUBPERITONEAL MYOMA. ($\frac{1}{2}$ nat. size.)

Gyd. No. 12155. Path. No. 8723. At the time of operation sarcoma was not suspected. This is a cross-section of a flattened, subperitoneal myoma. The outer zone consists of typical myomatous tissue, but the central portion has undergone degeneration. The line of demarcation is sharply defined, as seen at a. At b the tissue is homogeneous and shows some disintegration. At this point there is also calcification. A cystic space is seen at c, and in the area indicated by d the tissue has completely lost its muscular striation and has been converted into a characteristic homogeneous sarcomatous growth. As can be gathered from the history, the sarcoma was of a most virulent type.

numerous bright-red injected areas. Attached to the surface are omental adhesions over an area 10 cm. across. The omentum is here densely adherent;

it is intimately blended with the tumor, and has evidently furnished it a liberal blood-supply. The uterus is greatly distorted, and the normal tissue everywhere has been replaced by a myomatous growth. The anterior uterine wall appears to be of normal thickness. The uterine cavity is enlarged and stretched. It is 8 cm. in length and 4 cm. broad. From the upper inner and anterior wall of the uterus projects a tumor showing polypoid masses that are smooth and very soft. Projecting into the cavity from the fundus is a polyp 5 cm. in length, 3 cm. in breadth, and tapering down to 1 cm. at the point. It resembles very much a chicken's liver. It is long, narrow, and spongy, and apparently consists of mucosa. On section, the large myoma shows in the center an oval area 9 cm. in length and 7 cm. in breadth. It is sharply circumscribed, yellowish or whitish-yellow, reddish, or brownish in color, and presents a very mottled appearance. In many places it is homogeneous. In some places it looks friable (Fig. 135). At numerous points the blood-vessels are injected and reach 1 mm. or more in diameter. The picture macroscopically is most suggestive of sarcoma. It was not until after the patient's death that this portion of the tumor was examined, otherwise a definite clue to the subsequent clinical history would have been obtainable.

On histologic examination the mucosa shows considerable disintegration, but, taken on the whole, apart from some dilatation of the glands, it is perfectly normal. Sections from the uterine muscle show much hyaline degeneration. Many sections were made from the suspicious looking areas in the myoma. In the outlying portions is typical, but somewhat dense, myomatous tissue. We then come upon a zone where there is almost complete death or hyaline degeneration. Then we encounter a growth not so rich in cells. In some places this growth is somewhat homogeneous in character. In other places it appears to bear a definite relation to the blood-vessels. The nuclei of the cells in many places are of the natural size. At other points they are somewhat swollen and are vesicular. Then we have large rounded or oval cells with masses of chromatin, irregular in form, and showing that the nuclear division has not been of the normal type. At other points we have elongated cells with deeply staining nuclei. Then again the cells contain two or three nuclei. In some places the bundles of muscle-fibers are still preserved, but even here in the bundles are large and small nuclei. At some points nuclear figures are to be made out, and their presence in the specimen that has been hardened rather slowly certainly indicates that the growth has been an active one. Everywhere we have cells with small round nuclei. These appear to be chiefly muscle-fibers. They have been cut transversely, and in any field it is easy to find several of the very large, irregular nuclei. Some portions of the growth show coagulation necrosis over large areas. Where the myoma has undergone almost complete liquefaction it is particularly interesting, as here the cells are separated from one another by quite an interval. At such points large, irregularly formed nuclei are clearly in evidence. Other portions of the growth show the typical appearance of a spindle-celled sarcoma. Some

of the blood-vessels are thrombosed, others are perfectly preserved. In certain sections where there is coagulation necrosis we have marked dilatation of the blood-vessels and hemorrhage into the surrounding tissue. In such areas there is some preservation of the cell elements around the blood-vessels, giving the appearance of an angiosarcoma.

We have in this case a sarcoma developing in the interior of a very large myoma, which is undergoing hyaline transformation. The sarcoma is of the spindle-celled variety, and must have originated from the muscle-fibers, as all transition stages can be followed. From the histologic standpoint there is no doubt as to the positive diagnosis of sarcoma with accompanying degeneration. After making this diagnosis we learned that the patient shortly after developed metastases and died.

San. No. 1879. Path. No. 8458.

Sarcomatous transformation in the interstitial portion of a submucous myoma (Fig. 136).

F. D., white, aged forty-one, married. Admitted March 26; discharged May 5, 1905. The patient has been married fifteen years and has had one child, but no miscarriages. Her menses have been excessive and accompanied by some pain. At times there has been a profuse vaginal discharge. Her family and previous history are negative. She has lost no weight. For the last few months she has suffered from an excessive flow, at times amounting almost to flooding. There has always been pressure on the bladder and rectum, and a bearing-down sensation in the lower abdomen. Complete hysterectomy was performed, and the patient made a satisfactory recovery.

Path. No. 8458. The specimen consists of a uterus which has been completely removed. It is 12 cm. in length, 8 cm. in breadth, and 8 cm. in its antero-posterior diameter. Attached to it are the tubes and ovaries. The uterus has a smooth peritoneal covering. Projecting from the posterior surface are two small myomatous nodules, the larger of which is 1 cm. in diameter. Where the uterine cavity has been opened it is 5 cm. in length. The mucosa of the posterior wall is 2 or 3 mm. in thickness. That of the anterior wall is exceedingly thin, owing to the presence of a growth which occupies the entire body and projects into the uterine cavity. This growth, on section, is found to be somewhat irregular and reaches 6 cm. in length. The lower portion, where it projects into the cavity, consists of typical myomatous tissue, but in the upper portion this gradually shades over into a growth that is smooth, whitish-yellow in appearance, and homogeneous (Fig. 136). One is instantly reminded of sarcoma. Further sections of the tumor leave little doubt that it is a malignant growth, and in addition this nodule gradually shades over into myomatous tissue. This can be readily determined macroscopically. On retracing our steps to the myomatous tissue we find that, in places, it has undergone a certain amount of liquefaction, characteristic of that associated with hyaline transformation. The tubes and ovaries on both sides appear to be normal.

Histologic Examination.—Sections from the endometrium show that the mucosa has an intact surface epithelium. The glands look perfectly normal. The mucosa in the wall over the submucous nodule is much atrophied. The surface epithelium is still intact, but the glands are to a great extent missing, and we have spaces containing nothing but coagulated serum. They appear to be dilated lymphatic channels.

The lower part of the growth, which macroscopically resembled a myoma, consists essentially of myomatous tissue which here and there has undergone a certain amount of liquefaction. As one passes into the depth the muscle-fibers are more closely packed together. They vary considerably in shape and size. A short distance farther on we have a typical sarcomatous growth. In this growth the cells are very closely packed together. There are large areas of

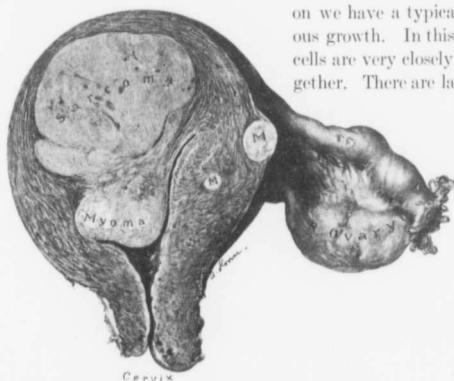


FIG. 136.—SARCOMA DEVELOPING IN PART, AT LEAST, FROM A SUBMUCOUS MYOMA. ($\frac{1}{3}$ nat. size.)

San. No. 1879. Path. No. 8458. The section represents the anterior half of the uterus. The cervix is normal. In one uterine wall are two small myomata. Projecting into the uterine cavity is a submucous myoma. In the lower part this presents the typical striated appearance, but in its upper portion it gradually shades off into a homogeneous growth—typical sarcomatous tissue. Macroscopically, the gradual merging of the myoma into the sarcoma could be traced. The histologic examination also demonstrated the transformation of muscle-fibers into sarcoma cells.

cells, with here and there large or small blood-vessels. Here and there nuclear figures are demonstrable. The growth is a spindle-celled sarcoma. The cells, on the whole, are very uniform in size and do not show any tendency to form large masses of chromatin. The transition from the myoma into the sarcoma and the contour of the myoma and sarcoma would macroscopically leave little doubt as to the origin of the sarcomatous growth, even though we had not the corroborative evidence as furnished by the microscope.

December 21, 1906: "Mrs. D. has written repeatedly that she is in the best of health" (H. A. Kelly).

This case had been overlooked in the routine histologic examination. The uterus had been cut partially in two, and the section had gone through the lower portion of the myoma, which presented the typical myomatous appearance. It was only when we made a section entirely through the uterus that this growth, which was clearly sarcomatous, even macroscopically, was discovered.

H. A. K. San. No. 1857. Path. No. 8349.

Commencing sarcoma in an intraligamentary myoma (Fig. 137).

A. L., white, married, aged forty-six. Admitted March 8; discharged April 16, 1905. The menstrual history has been normal, except for an offensive

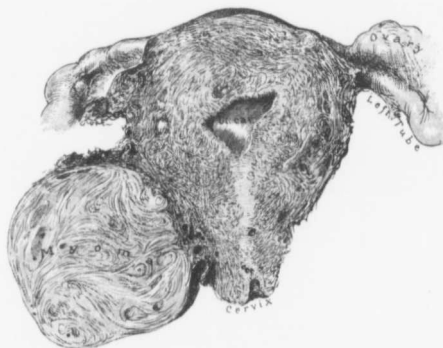

FIG. 137.—A MYOMA SITUATED TO THE RIGHT OF THE CERVIX AND SHOWING EARLY SARCOMATOUS CHANGES. ($\frac{1}{2}$ NAT. SIZE.)

Path. No. 8349. The section represents the posterior half of the uterus. Portions of the uterine cavity and cervical canal are seen. The myoma to the right of the cervix macroscopically presents the usual appearance, but on histologic examination sarcomatous transformation of muscle-fibers was demonstrable.

flow. Of late there has been a slight leukorrhœa. The patient has a constant feeling of pressure on the bladder and a continuous desire to urinate. There is some bearing-down pain in the rectum. She never has a natural movement.

Operation March 9, 1905. Hysteromyectomy. The patient made a satisfactory recovery, but was not very strong. Her highest postoperative temperature was 101.2°.

Path. No. 8349. The specimen consists of the uterus and of a growth springing from the right side of the cervix, and extending into the broad ligament. The uterus itself, which has been amputated through the cervix, measures 11 x 9 x 8 cm. Posteriorly, it is covered with adhesions; anteriorly, it is smooth. The uterine walls contain several myomata, chiefly interstitial. The largest of

these is 2 cm. in diameter. Attached to the right side of the cervix is a myoma, 9 x 6 x 7 cm. This was evidently not covered with peritoneum, and extended out into the right broad ligament. The right tube looks normal. The left tube and ovary are normal. On section, the large nodule to the right of the cervix resembles an ordinary myoma (Fig. 137), although at first sight its lobulated appearance suggests a malignant growth.

Histologic Examination.—On examination of the large myomatous nodule one instantly sees that something unusual exists. In the outlying portion typical myomatous tissue is encountered. Then, with the low power, we see that there is a decided picture of unrest. The muscle nuclei become two or three times the natural size. Some of them stain palely, others intensely. In the individual muscle-bundles one sees an increase in the size of the nuclei. The change is limited almost entirely to the muscle-fibers themselves. At other points we have deeply staining masses of chromatin representing nuclei. At still other places are irregular and deeply staining nuclei. The proliferation at certain points is of such a character that it bears a slight resemblance to gland formation, or might suggest that these large cells were in part due to proliferation of the endothelium of the capillaries. In other places we find the protoplasm of the muscle-fibers greatly increased in size, corresponding with the increase in size of the nuclei. In some sections a very interesting picture is to be noted. There is a good deal of edema and liquefaction of the myoma, and in such areas we find the nuclei particularly prone to increase in size and to stain deeply. In those areas we find the individual cells teased out from one another. There is a marked tendency for the cells still remaining to swell up, and for the deeply staining nuclei to multiply in number.

This specimen in particular leads one to think that the hyaline degeneration and the liquefaction of myomata are factors predisposing to the development of sarcomatous growths. Several of our cases have emphasized this point, and it is particularly well illustrated in Fig. 148 (p. 225).

In other places the cells are diminishing in number. In the sections in which they still persist they lie far apart. They have, therefore, an increased stimulus to active division. Sections from other portions of the growth show that, in certain areas, these large active cells are found in groups or colonies.

Although the myoma, as noted macroscopically, is not very large, we have undoubted evidence of commencing sarcomatous transformation. Inasmuch as in none of the sections do we find these cells right out at the margin, the prognosis might not be unfavorable. There is little doubt, however, that had this process gone much farther, metastases would have taken place. Sections from the cervix show perfectly a normal cervical mucosa. The endometrium in the depth has been poorly preserved, but looks normal.

In a letter dated January 29, 1907, Dr. Donahoo reports that the patient is in excellent health.

Gyn. No. 7474. Path. No. 3729.

Sarcoma developing in the center of a large uterine myoma (Figs. 138 and 139).

T. B., white, aged fifty-two, married. Admitted January 1; died February 5, 1900. Complaint, abdominal tumor. The patient has been married thirty-five years and has had seven children, but no miscarriages. The eldest child is thirty-five years of age. Her periods commenced at fourteen, were regular, lasting from six to seven days, and not very profuse. About five years ago the periods became less frequent, and last year they ceased entirely. The tumor was first noticed about twelve years ago. The abdomen is now filled with a tumor which extends down into the pelvis. It reaches 14 cm. to the right of the median line, and fills the entire left side of the abdomen. Rounded masses as large as tennis-balls can be felt connected with the main tumor. These are softer, especially at the costal margin on the left side.

On vaginal examination the outlet is considerably relaxed. There is a slight bulging of both anterior and posterior walls. There is also a slight bluish discoloration of the mucosa. The cervix is pushed up behind the symphysis, but is of normal size and consistence. The external os admits the tip of the index-finger.

Operation, January 8, 1900, supravaginal hysteromyectomy. On section of the abdomen a large white necrotic patch, fully 15 cm. in diameter, was found on the front of the tumor. Coursing over the sides of the tumor were large congeries of blood-vessels. The uterine arteries were fully as large as normal femoral arteries, and pursued a tortuous course over the surface of the tumor. On account of the difficulty in getting at the vessels the uterus was bisected. The tumor was shelled out, after which the collapsed organ was easily removed.

January 27th: The malignant character of the growth having been established, it was decided to excise the cervical stump. The cervix was grasped with tenaculum forceps and drawn forcibly downward. There was considerable oozing, which was checked by the free use of catgut sutures. The removal of the cervix was fraught with considerable difficulty. The anterior and posterior vaginal walls were approximated in the median line with two sutures, and a gauze drain was introduced to the right and left side.

February 5th: The patient gradually developed signs of intestinal adhesions, requiring an exploratory operation. A median incision was made. Loops of small intestine were found adherent along the line of incision. These were freed, but with some difficulty. The omentum was adherent to the scar, and also to the intestines. It was ligated and cut away. The small intestines were quite distended, and in the pelvis the intestinal coils were flaccid. There did not appear to be any peritonitis, and no fibrin was seen on the loops of gut. The intestinal loops were adherent to one another, to the bladder, the broad ligament, and the site of the drain in the pelvic floor. These adhesions were separated, at times with the finger, but in some places were so dense that scissors and knife

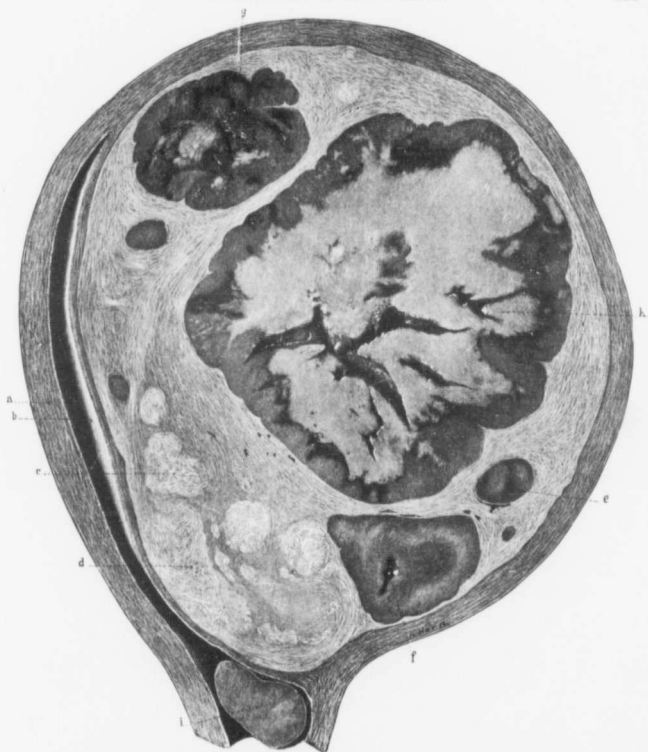


FIG. 138.—SARCOMA DEVELOPING IN THE CENTER OF A LARGE INTERSTITIAL UTERINE MYOMA. ($\frac{1}{4}$ nat. size.)

Path. No. 3729. The picture represents the cut surface of a longitudinal section through a greatly enlarged uterus. *a* is the posterior uterine wall, which, considering the stretching of the walls, is of the usual thickness. *b* is the uterine cavity which has been greatly lengthened out. Had a uterine sound been passed, it would scarcely have reached the top of the cavity. The uterine mucosa is scarcely 1 mm. in thickness. Occupying the anterior wall is a large interstitial myoma, very sharply defined from the muscle. At several points, especially at *c* and *d*, are very dense myomatous foci, easily recognized by their lighter hue. Scattered throughout the large myoma are large and small sarcomatous masses. The sarcomatous growth (*e*) is one of several small ones. All are homogeneous in structure and sharply outlined from the muscular growth. In the sarcomatous nodule (*f*) is an irregular cystic cavity. The nodule (*g*) shows areas varying in color and consistence. This is due to a breaking-down of the malignant growth. The largest sarcomatous focus (*h*) has undergone almost complete necrosis, as is indicated by the lighter central portion, only a small outer rim of solid tissue remaining. The various clefts in the center of this nodule are due to the degenerative process. *i* indicates a sarcomatous nodule situated in the cervix near the internal os. In this case the growth was primary in the myoma, showing conclusively that it developed from the myomatous tissue. Sarcoma was not suspected until the specimen reached the laboratory. This case indicates clearly the advisability of opening the uterus at once after removal. If the malignant process be present, the cervix can then be removed before the abdomen is closed, thus saving the patient a second operation, and avoiding the danger of leaving a possible sarcomatous cervix for a period of two or three weeks longer. The large myoma was shelled out of the uterus with ease.

were required. At the point at which constriction had taken place the adhesions were extremely dense, and over an area two inches in length, and almost surrounding the circumference of the intestine, the peritoneum had been denuded and some of the muscle-fibers were wanting.* A small rent, 1.5 cm. long, was made in the lumen of the gut. This was brought out at the side, most of the fecal matter and gas above was forced out, and the tear in the collapsed intestine was then closed with three mattress silk sutures and an additional layer of Lembert sutures. All adhesions were separated except over a small area of the sigmoid. The sutures and denuded areas were placed low down in the abdomen, next to the gauze drain, which was packed in the pelvis. This loop at the point of stricture was straightened out so as to prevent reformation of the stricture. The pulse was weak, and respiration rapid. The patient failed to react to stimulation, and died on the following day.

Path. No. 3729. The specimen consists of a large myoma which has been shelled out, and also of the uterus with the attached tubes and ovaries. The tumor is approximately globular, being 20 x 20 x 18 cm. in its various diameters. In part it is smooth and glistening and covered with peritoneum. At least three-quarters of it, however, has a ragged appearance, owing to the presence of a large myoma, which has at least two lobulations due to clefts extending from 3 to 5 cm. into the depth. These lobulations are further subdivided by minor clefts. The tumor, as a whole, is firm, but one of the lobulated areas is rather soft. On section, the tumor is found to consist of two distinct elements, the outer enveloping portion made up of muscle and a central portion consisting of a soft growth (Fig. 138). This is yellow in color, does not show the striation of muscle, but presents a porous appearance and, in fact, might be likened to a very fine sponge. The central portion of this growth is slightly friable, and here the porous appearance is more pronounced. It also shows numerous clefts. This large new-growth makes up fully one-half of the myoma, and other similar but smaller nodules, varying from 1 to 7 cm. in diameter, stud the outlying portion. One of the largest lobulations noted on the outer surface consists essentially of this peculiar new-growth, and here marked softening has taken place. In the cervix is a nodule, 4 cm. in length, 3.5 cm. in breadth, and 1 cm. in thickness. It is attached by a pedicle 2 cm. broad. The nodule is perfectly smooth and has an intact surface. The uterine cavity is 13.5 cm. long and 11 cm. broad at the fundus. The surface of the mucosa has a pinkish-yellow color and is somewhat wrinkled in appearance. About the middle of the right lateral wall is a disc-like projection, raised 1.5 mm. above the mucosa. Its margins are sharply defined. At the fundus is a soft polyp, 2 cm. in diameter.

The right tube is 15 cm. long and free from adhesions. The ovary is greatly flattened and measures 6 x 2 x 0.5 cm.

The left tube is 11 cm. long. The ovary has the same dimensions as that of the opposite side, and is free from adhesions.

*With our present knowledge we would, of course, merely do an enterostomy.

Histologic Examination.—The large tumor that was shelled out from the uterus consists of non-stripped muscle-fibers cut in various directions, and presenting the usual appearance of myoma. Here and there is much hyaline degeneration, principally diffuse in character. The large porous tumor, occupying the center of the myoma, and differing from it so widely macroscopically, shows a still greater contrast on histologic examination. It consists of a sea of cells

all having the same general characteristics. Its tissue is traversed in all directions by the most delicate capillaries, consisting merely of an endothelial lining. The cells of the growth are round and have round, uniformly deeply staining nuclei (Fig. 139). They vary greatly in size, and all gradations from minute spheric nuclei to those ten or twelve times larger are clearly demonstrable. It looks very much as if the small cells were gradually developing into the larger ones. Some of the large nuclei are irregular in outline and contain pale-staining spheric droplets. Between the cells we occasionally see large blood-vessels, with practically no connective-tissue framework. Many areas show hemorrhage, and at certain points there is complete coagulation necrosis, often accompanied by fragmentation of nuclei. At numerous points there has evidently been an old hemorrhage, as the tissue is studded with brown pigment-granules. The growth is a round-celled sarcoma. The other porous nodules scattered throughout the myoma are also sarcomatous in origin. Scattered throughout various portions of the myoma are microscopic foci of sarcomatous tissue.

The uterine mucosa is much atrophied, but its surface epithelium is intact. The glands are atrophic, and in a few places apparently dilated. The stroma

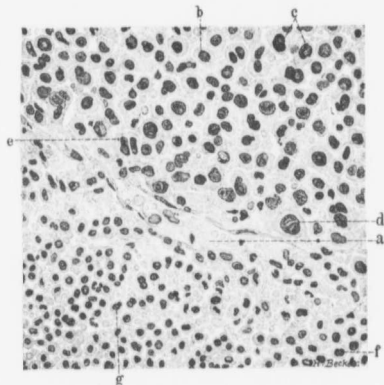


FIG. 139.—SARCOMA DEVELOPING IN THE INTERIOR OF A MYOMA.
($\times 360$ diam.)

Path. No. 3729. The section is taken from the sarcoma seen in Fig. 138. The delicate-walled blood capillary (a) divides the field into an upper half, composed of large cells, and a lower, of much smaller cells. The cells are loosely arranged. In most places it is possible to clearly outline not only the nucleus, but its protoplasm. In the upper half of the field, b may be taken to represent the average size of the cell. These nuclei and those indicated by c are moderately enlarged and irregular and stain more deeply. At d we have a relatively much larger cell, and at e the nucleus of a cell is divided into two, while as yet no cleavage has occurred in the protoplasm. In the lower half of the field the cells are fairly uniform. At f a small cell contains two nuclei, and at g is a budding nucleus. From a careful study of many sections we gather the impression that the cells were at first very small, and that they have gradually developed into the large ones. This would account for the crops of small and large cells found side by side and yet sharply defined from one another.

of the mucosa consists of spindle-shaped cells, and here and there shows some small-round-celled infiltration. The large nodule in the cervical canal is sarcomatous, as are also the polypi in the body. The smaller polyp in the body has pushed the surface epithelium in front of it. This is well recognized as a single row of cuboid cells lying directly on the sarcomatous tissue. The disc-like nodule described in the cavity is a small submucous myoma.

In this most instructive case we have a large myoma, partially subperitoneal, but to a great extent interstitial. In the center of this a sarcoma has developed, and has gradually given rise to secondary foci in the myoma, and also to deposits in the uterine wall and in the cavity of the uterus. That the growth is primarily of myomatous origin we are practically sure. In no other part of the body was there a primary malignant focus, and it is most exceptional to find a metastasis in a myoma. The appendages are normal.

This case demonstrates very clearly the advisability of avoiding bisection of the uterus whenever sarcoma is suspected.

Gyn. Nos. 7040 and 7212. Path. Nos. 3312 and 3472.

Subperitoneal, interstitial, and submucous uterine myomata; large circumscribed sarcomatous nodule in the uterus, apparently originating in a myoma (Figs. 140, 141); atrophy of the uterine mucosa; normal appendages. Supravaginal hysterectomy with return of the growth in the cervix.

E. C. B., white, married, aged fifty. Admitted July 2; discharged July 28, 1899. Complaint, abdominal tumor. The patient has had two children and one miscarriage. The first labor was normal; the second was attended with a great deal of flooding. Her menses commenced at fourteen and were regular until two years ago, lasting from five to six days. During the past two years the flow has increased in amount, has been dark and clotted, and has lasted from one to three weeks.

The presence of a tumor was first suspected four years ago. It was slow in growth until six months ago. Since that time it has increased rapidly in size. The bowels have been regular, and there has been a frequent desire to micturate. On examination the outlet is found to be markedly relaxed. The cervix is low down. Anteriorly, the entire vaginal vault is bulged out by a rounded, smooth, somewhat soft, non-sensitive mass. This is wedged down in the pelvis, is immobile, and is in direct connection with the abdominal mass, which extends upward to the umbilicus. The right fornix is clear, except at the apex, where the lateral structures are palpable. The left fornix is completely obliterated.

Operation, July 5, 1899. Hysteromyomectomy, the uterus being amputated through the cervix. The maximum postoperative temperature was 101.4° F. The patient was discharged on July 28th, but there was a movable mass the size of a walnut on the right side. She was readmitted to the hospital shortly afterward, and died September 25, 1899.

Path. No. 3312. The specimen consists of an enlarged uterus, amputated through the cervix, and of the appendages. The uterus presents a somewhat lobulated appearance, and measures 15 x 13 x 11 cm. At a few points there are small subperitoneal nodules. The anterior uterine wall is fully 8 cm. in thickness, owing to its invasion by a new-growth. Near the cervix is a nodule 6 cm.

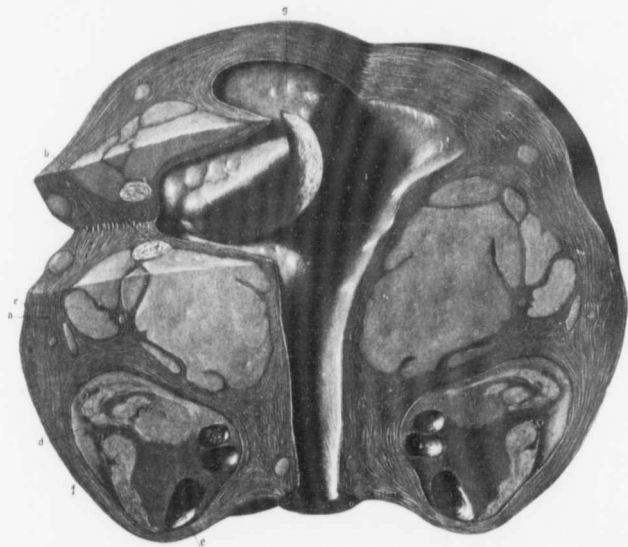

FIG. 140.—PROBABLE SARCOMATOUS TRANSFORMATION OF A MYOMA; ALSO DISCRETE MYOMATOUS AND SARCOMATOUS NODULES IN THE SAME UTERUS. ($\frac{1}{2}$ nat. size.)

Path. No. 3312. The uterus, which is much enlarged, has been opened anteriorly. The uterine muscle, as indicated by *a*, is much thickened, owing to a general hypertrophy. At *b* is a small myoma which has been cut in two. *c* is one of many large and small areas of homogeneous tissue scattered throughout the uterine walls. It is lighter in color than the muscle, and is sharply outlined. It is sarcomatous tissue. *d* is also a sarcomatous nodule. It contains several smooth cystic spaces, as indicated by *e*. This nodule at several points lacks the homogeneous appearance, the tissue being fibrillary and resembling myoma. This is particularly well seen at *f*. Here we have the remnants of a myoma entirely surrounded by sarcomatous tissue. Situated near the cervical canal is a small sarcomatous nodule. The uterine cavity is much lengthened. Its mucosa is atrophic, and situated near the fundus is a large, slightly lobulated submucous myoma (*g*). Its texture is readily recognized from the cut surface.

The appearance noted in the nodule *d* suggests that in this particular nodule the sarcoma originated from the myoma.

in diameter, irregular in contour, and consisting in part of myomatous tissue. A portion of it, however, has lost its fibrillation; it has become homogeneous and is yellowish in color. This area is very suggestive of sarcoma, and on section is found to contain irregular, cyst-like spaces, some reaching 2 cm. in diameter (Figs. 140, 141). The thickening in the anterior wall is due to the presence of a

similar nodule, 9 x 6 cm. This in a few places presents a myomatous picture, but at most points is light in color, homogeneous in consistence, and entirely devoid of fibrous arrangement. The uterine muscle shows isolated foci of this soft growth. On section of the large nodule, a typical myoma, 3 cm. in diameter, is found situated in the center of this peculiar and homogeneous mass. The posterior uterine wall varies from 3 to 4.5 cm. in thickness, the increase being due to the presence in its walls of a subperitoneal and partially interstitial myoma. It also contains a few small foci of the yellow and homogeneous

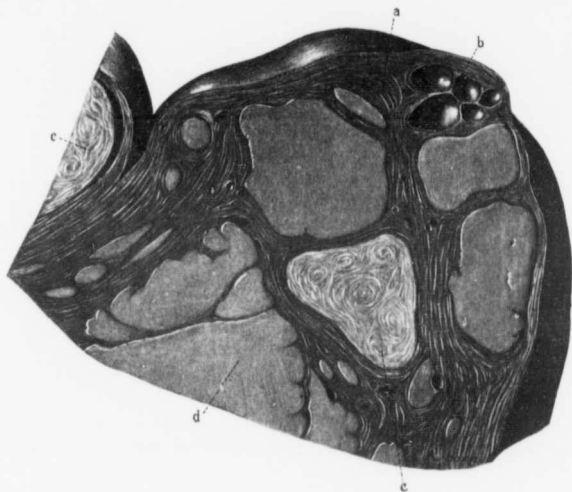


FIG. 141.—ASSOCIATION OF MYOMA AND SARCOMA IN THE SAME UTERUS. ($\frac{1}{10}$ nat. size.)

Path. No. 3312. This is a section through the thickened uterine wall in Fig. 140. a represents the coarse uterine muscle, which forms the general framework. At b is a group of five thin-walled cysts. At c and c are sections of two myomata, easily recognized by their striation. At d is one of the many smooth, homogeneous, sarcomatous nodules scattered throughout the uterine wall.

growth. Situated in the fundus are several of these small growths; projecting into the uterine cavity from the fundus is a submucous myoma, 7 x 4 cm.

The uterine cavity is 13 cm. in length. Its mucosa is apparently unaltered, and has nowhere been invaded by the soft and homogeneous growth. Over the submucous myoma the mucosa is still intact, but quite atrophic. The tubes and ovaries are apparently normal.

Histologic Examination.—The uterine mucosa is considerably atrophied. The surface epithelium is intact, and the glands present the normal appearance.

Over the submucous myoma it is possible to trace the surface epithelium, and here and there a group of glands is still visible. The submucous myoma presents the usual appearance and shows considerable diffuse hyaline degeneration. The soft nodules scattered throughout the uterine wall consist of a homogeneous tissue, made up of great quantities of cells, in most places showing no definite arrangement. This tissue is traversed in all directions by delicate blood capillaries. The individual cells have oval or round, deeply staining nuclei, and here and there is a nucleus five or six times the size of its neighbor, and staining intensely with hematoxylin. These cells are actively growing. Nuclear figures are abundant, and all stages of karyokinesis are visible. We often find the chromatin filaments delaying at the poles instead of passing along the achromatic threads to the center. Here and there is a large mass of protoplasm, staining deeply with eosin, and containing several deeply staining nuclei, so arranged as to form a mulberry-shaped mass. Large portions of this growth have undergone complete coagulation necrosis, without any subsequent polymorphonuclear infiltration. In some places, although coagulation necrosis has occurred, the large blood-vessels in such areas are still surrounded by a zone of well-preserved sarcoma-cells. The line of demarcation between the uterine muscle and the new growth is sharply defined, and it is a common thing to see the sarcomatous cells wandering in and separating the muscle-fibers from one another. The growth is a spindle-celled sarcoma.

In this case we have an enlarged uterus implicated by a myomatous and at the same time by a sarcomatous process. Macroscopically, one can see the gradual merging of a myoma into a sarcoma, and in a large nodule a typical myoma is surrounded by sarcomatous tissue. But histologically we are unable to trace the transformation of myomatous tissue into sarcomatous tissue. From the general arrangement, however, we believe that the sarcoma developed in the myoma.

The Fallopian tubes are normal. The right ovary contains a few gland-like spaces lined with cylindric epithelium. Both ovaries are, however, practically normal.

Gyn. No. 8732. Path. No. 4931.

Subperitoneal and interstitial uterine myomata, mixed-celled sarcoma of the anterior uterine wall; with remnants of the myoma in its interior (Figs. 142, 143, 144). Normal cervical mucosa; atrophy of the uterine mucosa; normal appendages.

M. J. L., black, married, aged forty-six. Admitted May 9; died May 16, 1901. The patient had one miscarriage two years ago. Her menses began at fifteen, were always regular, but profuse, and lasted from four to six days. The last period occurred four weeks ago. The patient's mind is not very clear, and consequently a complete history cannot be obtained. The cervix is in the normal position, firmly fixed. Behind it is a large hard mass. Situated in the

superior strait, and extending up into the abdomen, is a large soft mass, the size of an adult's head.

Operation, May 9th. Panhysterectomy. The large mass was very soft and fluctuating, and covered with vessels running in all directions beneath the peritoneal surface. The tumor in the hollow of the sacrum is very hard. As the entire growth was thought to be myomatous, enucleation was begun with the idea of cutting across the cervix and then tying the left ovarian vessels and round ligament, and beginning to work down to the left uterine vessels. A slight

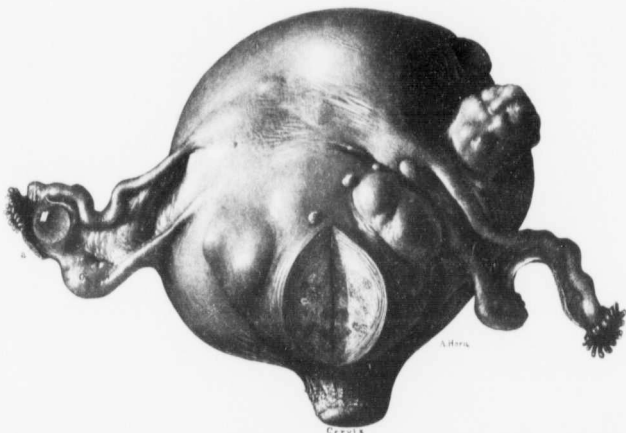


FIG. 142.—A SARCOMATOUS UTERUS CONFORMING IN CONTOUR TO A GLOBULAR MYOMATOUS UTERUS. ($\frac{1}{2}$ nat. size.)

Path. No. 4931. The uterus is much enlarged, globular in form, and strongly suggests a myomatous condition, especially as the majority of the nodules seen springing from the posterior surface are myomata. The nodule near the cervix is seen on section to be a myoma, and the dark patches scattered throughout it are areas of calcification. A glance at Fig. 143 shows that the greater part of the uterine enlargement is due to the presence of a sarcoma occupying the anterior wall.

On bimanual examination the diagnosis of a myomatous uterus would naturally be the most rational one, and even after the abdomen was opened, there would be little to suggest sarcoma except the rather flabby contour of the organ. The left tube and both ovaries appear to be normal. The right tube is longer than usual. Situated between the left tube and ovary is a small parovarian cyst (a).

tear in the large tumor allowed a brain-like substance to ooze out over the uterine vessels, showing almost conclusively that the large growth was sarcomatous. Panhysterectomy was immediately decided upon. The large vessels were tied off, the bladder was pushed down, and the vagina incised in front of the cervix, which was quickly cut all around. The entire growth and the pelvic organs were removed. A gauze drain was placed in the vagina. After operation the pulse gradually became rapid and the patient died on May 16th.

Path. No. 4931. The specimen consists of an enlarged uterus with its appen-

dages intact. The uterus (Fig. 142) with its intact cervix is approximately 18 cm. in length, 15 cm. in breadth, and 15 cm. in its anteroposterior diameter. It

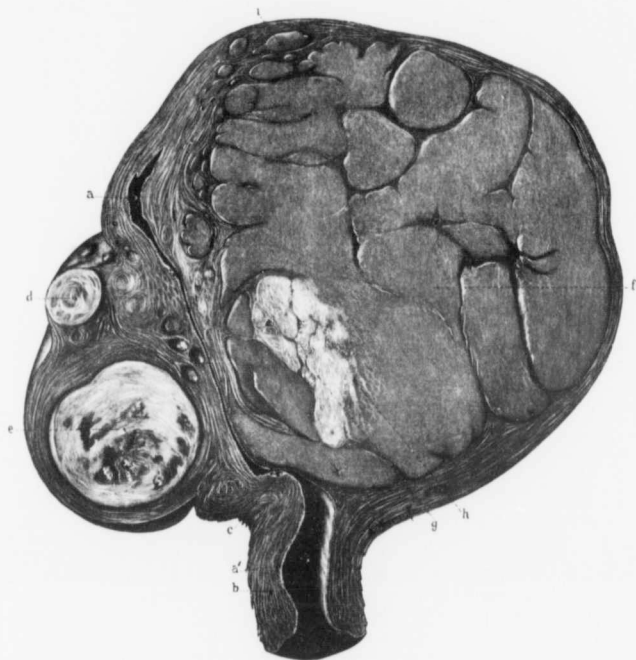


FIG. 143.—SARCOMA AND MYOMA IN THE SAME UTERUS. ($\frac{1}{2}$ nat. size.)

Path. No. 4031. This is an anteroposterior section through the uterus seen in Fig. 142. *a* is the upper part of the uterine cavity; *a'* is that of the cervical portion. The walls of the cervix are of the normal thickness, as seen at *b*. The uterine mucosa is rather atrophic, but at *e* two of the glands show cystic dilatation. Situated in the posterior wall are several small, ill-defined myomata, and the circumscribed nodule, *d*. The dark patches in the myoma, *e*, are areas of calcification. This is the myoma seen in Fig. 142. Occupying the anterior wall of the uterus is the large growth *f*. This is homogeneous in appearance and sharply outlined from the uterine muscle. It is partially subdivided into smaller masses by septa of muscle. At *g* are the remains of a myoma easily recognized by the arrangement of the muscle-bundles. At *h* this myoma gradually shades off into sarcomatous tissue. Scattered throughout the uterine muscle are numerous isolated sarcomatous foci, as seen at *i*. It looks very much as if the myoma (*g*) had undergone sarcomatous transformation. If the sarcoma had occurred independently, we would expect to find the myoma either pushed to one side or surrounded by sarcoma, instead of merging imperceptibly into it.

is irregular and nodular, and projecting from its surface are several pedunculated myomata, the largest of which is 3 cm. in diameter. Situated in the posterior

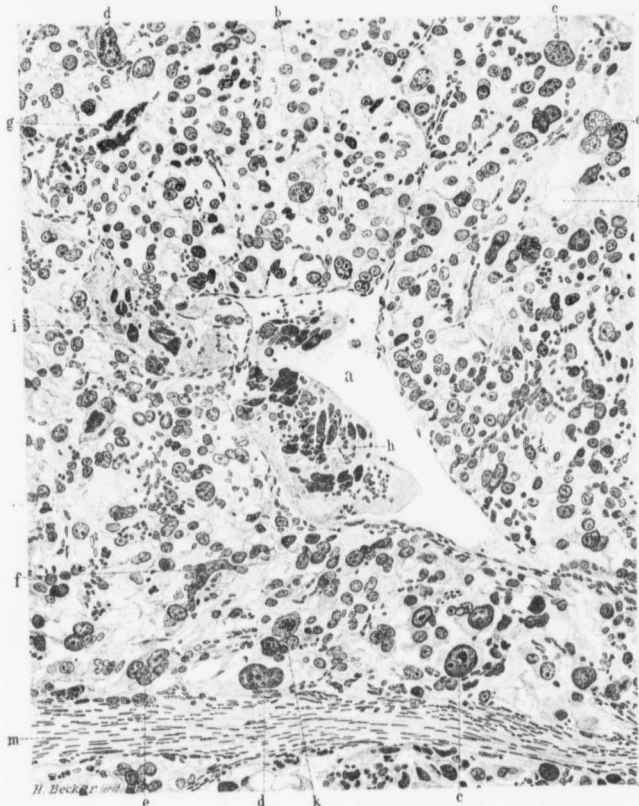


FIG. 144.—MIXED-CELLED SARCOMA OF THE UTERUS ASSOCIATED WITH MYOMATA OF THE UTERUS. ($\times 350$ diam.)

Path. No. 4931. The section is from the sarcoma in Fig. 143. At first glance it bears some resemblance to chorio-epithelioma. *a* is a large vein; *b* represents the average size of the nuclei. At numerous points indicated by *c* the cells are greatly enlarged; they stain deeply, and their chromatin is gathered up into coarse granules. At several points, *d, d*, the large nuclei are somewhat constricted, showing a tendency toward cleavage. At *e* six nuclei of variable size are contained in one mass of protoplasm, forming a giant-cell. A large and irregular mass of chromatin with several projections is seen at *f*, and at *g* we have three large irregular and ragged masses of chromatin contained in one mass of protoplasm. Nearly filling the large vein is a huge plaque of protoplasm (*h*) containing many large and small irregular masses of chromatin, roughly resembling small lumps of coal. Scattered throughout this protoplasm are many small round cells and polymorphonuclear leukocytes. A similar mass of protoplasm (*i*) fills the upper part of the vein. *l* represents one of the many vacuoles scattered throughout the field. *m* is a zone of stroma which forms only a very small part of the tumor. It is impossible to determine with certainty whether this stroma represents connective tissue or remnants of muscular tissue.

wall is an interstitial myoma, fully 6 cm. in diameter, and just beneath the peritoneum of the anterior wall are several small, soft, and slightly raised growths. These, however, are in no way suggestive of myomata. The chief increase in size of the uterus is due to a growth fully 12 cm. in diameter, occupying the anterior wall (Fig. 143). This is sharply circumscribed, yellowish-white, translucent, soft, edematous, and bears a striking resemblance to the gray matter of the brain. Scattered throughout it are bright yellow patches and others of a greenish hue. At several points over the center of the tumor are areas slightly suggestive of myomatous tissue. The large tumor has an outer covering of muscle averaging 2 mm. in thickness. Its inner portion extends to the mucosa. The cervix presents the usual appearance.

The uterine cavity is 7 cm. in length, and at the fundus 7 cm. in breadth. Its mucosa is not over 1 mm. in thickness. It is smooth and glistening. The appendages are apparently normal.

Histologic Examination.—The cervical glands in places reach 3 to 4 mm. in diameter; otherwise the mucosa in this portion is unaltered. The cells of the new-growth are clinging to the surface. This appearance is certainly due to the fact that the juice of the tumor has oozed out when pieces were being excised for examination. Sections from the body of the uterus show marked atrophy of the mucosa. The surface epithelium is intact, but consists of low cuboid or almost flat cells. The glands are very small, but are normal except for occasional dilatation. The stroma of the mucosa is very dense, and in places it is impossible to differentiate between muscle-bundles and altered stroma.

Situated in the uterine muscle are small typical myomata. The larger nodule, occupying the anterior wall and consisting of soft tissue, is made up of a framework of spindle-shaped connective-tissue cells and apparently of non-striated muscle-fibers. Its stroma contains many large blood-vessels and, roughly speaking, it would have made up one-quarter of the tissue. The major portion of the tumor consists of solid masses of cells which vary greatly in size. Some are rounded or polygonal in shape, have vesicular nuclei, and bear some resemblance to decidual cells (Fig. 144). Others contain large vesicular nuclei, ten or twenty times the size of those in the near vicinity. Scattered abundantly throughout the section are large, deeply staining nuclei, and great irregular masses of chromatin. Everywhere small round cells are to be seen, and frequently polymorphonuclear leukocytes. Scattered throughout many portions of the tumor are large and small vacuoles, lying between cells or in the cell-protoplasm. Frequently masses of tumor-cells are found projecting into or lying free in veins or arteries. Many parts of the tumor have undergone complete necrosis or show marked fragmentation of nuclei.

As seen from the description, this large tumor is a sarcoma of the mixed-celled variety. Whether or not it has originated from the myoma it is impossible to say with absolute certainty. The appearance of the gross specimen, however, strongly suggests such an origin.

Gyn. No. 7604. Path. No. 3865.

Sarcoma of the posterior wall of the uterus, originating in a myoma (Fig. 145); metastases in the lungs and endocardium.

E. R., white, aged forty-four, married. Admitted February 27, 1900. She has been married nineteen years, but has had no children and no miscarriages. The menses have usually been regular, of five days' duration, and accompanied by considerable pain before the flow commenced. For the past five or six months there has been a slight blood-stained, watery discharge. The bowels have been constipated, and there has been some burning and increased frequency

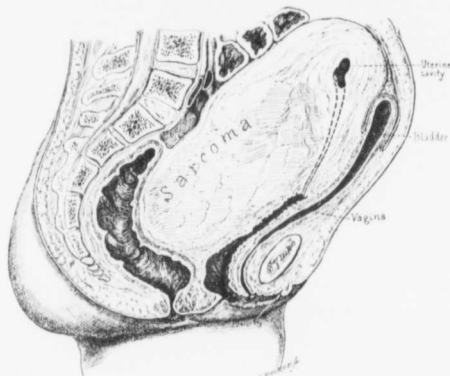


FIG. 145.—SARCOMA OF THE POSTERIOR UTERINE WALL, ORIGINATING IN A MYOMA.

Path. No. 3865. The uterus is much enlarged, mainly from the presence of a growth in its posterior wall. Histologic examination shows this to be a sarcoma developing in a myoma. It is firmly fixed in the pelvis, being intimately blended with the rectum. The bladder is drawn high into the abdomen.

of micturition. At one time the patient had the cervix dilated for dysmenorrhea, and a polyp was removed from the uterus. She had definite signs of stone in the left kidney, and thinks she passed a stone into the bladder, after which the renal symptoms disappeared. For the past three or four months there has been pain in the pelvic region, radiating down the legs, and the patient has noticed the abdomen increasing in size for two months. For the last three months there has been considerable difficulty in voiding, and at times the flow of urine would suddenly stop. There has always been great straining and obstinate constipation. She has been in bed for eight weeks, and has been taking large quantities of morphin. For the past week she has been unable to void at all, catheterization being necessary.

Operation, March 3, 1900. The vagina was encroached upon posteriorly by a cystic tumor filling the cul-de-sac. The cervix was small and soft, and pushed above the symphysis. The urethra was jammed against the symphysis, and the bladder reached to the umbilicus. As a great deal of difficulty was experienced on account of the dense adhesions (Fig. 145), the uterus was bisected. As soon as the uterus was split there was a gush of blood-stained serous fluid from the cavity. The lower portion of the uterus was occupied by a soft, stringy substance, resembling striated muscle, much softer and darker in color than usual, and very vascular. There was alarming hemorrhage wherever it was cut. An opening was made into the bladder, and urine escaped into the peritoneal cavity. The patient at the time of operation was exceedingly weak, and there was a good deal of shock. She grew weaker, had much abdominal pain and nausea, and died on March 14th, eleven days after the operation.

Path. No. 3865. The specimen consists of the uterus, together with both tubes and ovaries. The uterus has been divided into two portions and is considerably enlarged, being twice the size of a man's fist. Accurate measurements cannot be given on account of the mutilation of the specimen. The tubes and ovaries are bound together by dense adhesions, and so greatly distorted as to be scarcely recognized. Both ovaries have been converted into cysts, and are almost completely embedded in adhesions. One is approximately the size of a small orange. The cyst on the left is apparently the size of a hen's egg; it presents numerous partitions and trabeculae, which show that it was multilocular. The posterior portion of the ovary is occupied by a mass of tissue composed of stroma, in which are masses of tissue irregular in shape. The posterior wall of the uterus and the anterior half of the uterus present numerous dense adhesions.

Histologic Examination.—The surface of the mucosa has to a great extent been mechanically removed, but in a few places is fairly well preserved, and here the surface is smooth. The uterine glands are of the usual number and are normal. Others are considerably dilated. The stroma is dense. The muscular tissue immediately beneath the mucosa is normal. In the uterine wall the muscle-cells end abruptly; in some places they are abundant and stain intensely; they vary somewhat in size. In the center of the tumor the arrangement of cells in bunches is less evident and the cells are less distinct, until finally there is a mass of oval or elongate cells having no definite arrangement, and traversing it are numerous bunches of blood-vessels. Many of the cells are minute. Bunches of fibers still persist in the tumor mass, and were it not for the presence of irregular masses of cells, the diagnosis would be myoma. In some places the cells are small; in other places the nuclei are several times their usual size. The picture is one of typical sarcoma developing in the interior of a myoma, although the cell changes are not so marked as are usually found.

Autopsy No. 1503, March 14, 1900. Anatomic diagnosis: Recent surgical incision, with drain reaching into the pelvic cavity; recent amputation of the

uterus; blood-clot filling pelvis; general anemia of all organs. Both branches of ovarian veins thrombosed; gangrene of left ovary; involvement of lumbar glands by sarcomatous metastases. Metastases in the lungs. Vegetations on the chorda tendinea of the tricuspid valve and on the columnæ carneæ of the right ventricle; bronchopneumonia; cloudy swelling of the viscera; focal areas of necrosis in the liver; cholelithiasis; gall-stone in the diverticulum of Vater.

On opening the abdominal cavity the peritoneum is found to be smooth and glistening. The intestinal loops are somewhat distended with gas. At the site of the wound there are firm adhesions between intestinal loops and the peritoneum. Except for these adhesions the intestinal coils are quite free. Filling the entire pelvis is a large blood-clot which appears to be several days old.

The left ovary is dark, firm, tense, and on section is found to be filled with a blood-clot and necrotic material. There is no rupture, and nothing can be found in the pelvis to account for the quantity of blood present.

Intestines: The rectum and greater part of the colon appear practically normal. The cecum, however, is considerably distended. On examination, the mucosa is found to be injected but intact.

Lungs: The metastases in the lungs are rather extensive.

The hemorrhage in this case was apparently not the result of bleeding from vessels of any size, but of a general oozing. There is little wonder that the patient in her weakened condition did not survive the operation.

Gyn. No. 6724. Path. No. 2946.

Uterine myoma undergoing cystic sarcomatous degeneration.

M. F., white, aged twenty-seven, single. Admitted February 26; discharged April 1, 1899. The family history is not important. The patient as a girl was always healthy. The menses commenced at fifteen, were regular, painful, but not especially copious. The patient, about four weeks ago, noticed pain and swelling of her ankles, associated with some discomfort in the back and lower part of the abdomen. During the last four years her periods have been regular except for the last seven months. Since August, seven months ago, the periods have occurred every two weeks and have been profuse and painful. The last menses ceased about ten days ago. On abdominal examination a smooth, firm, spheric, immobile tumor mass can be felt rising from above the symphysis and extending to the umbilicus; a little to the left of the median line a second, but smaller, mass, apparently continuous with the first, crosses the median line to the right.

Operation, February 27, 1899. Abdominal myomectomy. For nearly two

days after operation the patient had a great deal of abdominal pain and a feeble and rapid pulse; there was also a considerable degree of abdominal distention. Nervous symptoms were prominent during convalescence, but gradually abated, and she was discharged on April 1, 1899. Her highest postoperative temperature was 102.5° F., on the day following the operation. The pulse on that day was very feeble, rising to 140. From this time on there was a gradual drop to 82.

Path. No. 2046. The specimen consists of several myomata, the largest 11 cm. in diameter, a smaller one, 5 cm. in diameter, and a third still smaller one, to which is attached a piece of the uterine wall. These myomata are apparently edematous. Situated just below and to the right of the tube is a small nodule, 9 x 6 x 4 mm. Its surface is slightly lobulated, and apparently consists of fibrous tissue. The large myoma presents a different picture from those usually seen. It is made up chiefly of coarse fibers forming bundles, which sometimes present a whorl-like arrangement, while in other places they interlace in various directions. The nuclei vary greatly in size and shape. They are, for the most part, oval or fusiform, but may be spheric. Many are several times the usual size, and frequently large, deeply staining masses of chromatin are seen, or several cells seem to have bunched together and to have coalesced, while the nuclei have remained distinct. Some of the nuclei stain palely and show a few rather coarse granules of chromatin, while others take an intense homogeneous stain. No definite division of the cells is to be seen. In some areas the fibrillated tissue has been replaced by a homogeneous or granular, eosin-stained substance containing a few degenerated cells. In some parts of the tumor the cells are very abundant and closely packed together, while at other points they are few in number. Near the periphery of the myoma typical myomatous tissue is present. There is moderate vascularity of the tumor. The growth is undoubtedly an early sarcoma, occurring in the interior of a myoma.

The patient was in good health when heard from on January 1, 1907, about eight years later.

Gyn. No. 6045. Path. Nos. 2311 and 2314. Autopsy No. 1085.

Multiple and subperitoneal uterine myomata, with sarcomatous development in the interior of a myoma (Figs. 146-155).

E. F. M., white, aged fifty-six, single. Admitted April 21; died April 23, 1898. The patient complains of tightness in the abdomen, accompanied by abdominal swelling. Her menses began at fourteen and were regular, lasting from one to one and one-half days. The flow was scanty. The menses ceased six years ago. Micturition has been more frequent than normal for the past two or three months. The bowels are constipated. The abdomen is much distended, and on palpation several nodular and tender masses can be felt. There is slight edema of the labia.

Operation, April 23. Exploratory laparotomy was performed, but nothing was removed. The patient died on April 23, 1898.

The Journal of Obstetrics

Autopsy No. 1085. Anatomic diagnosis: Uterine myomata undergoing sarcomatous degeneration; general anemia of the organs.

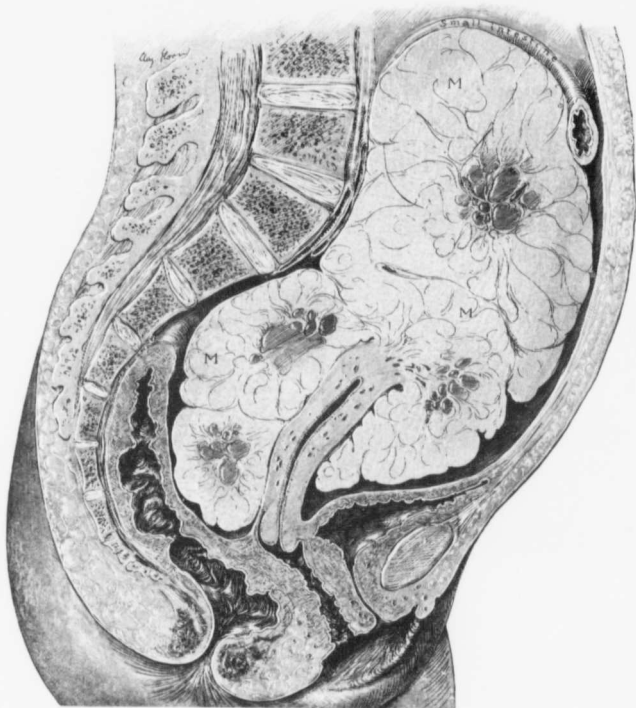


FIG. 146.—SARCOMATOUS TRANSFORMATION OF A MULTINODULAR PEDUNCULATED, SUPERFICIAL MYOMA.

Gyn. No. 6045. Path. Nos. 2311 and 2314. The specimen was obtained at autopsy. Attached to the fundus by a rather broad pedicle is a multinodular, lobulated myomatous tumor. Dr. Louis Livingood, who made the autopsy, noted that the tumor as a whole was softer than a myoma and that it tore readily. The central portion of the lobulations showed degeneration, but in the outer portions typical myomatous tissue was still visible. For the histologic pictures showing that the sarcoma originated from a malignant metamorphosis of the muscle-fibers see Figs. 147-155.

The edges of the abdominal wound are well approximated. The intestinal coils occupy the upper portion of the cavity, the lower part being filled with a large tumor springing from the uterus. The lower intestinal coils and the tumor

mass are covered with blood, which is traversed by shreds of tissue suggesting small blood-vessels. The appearance resembles that seen in an organizing blood-clot. The intestinal coils are loosely attached to the upper part of the tumor, and at first completely hid it from view.

Dr. Livingood kindly placed the pelvic organs at the disposal of the gynecological department.

Path. No. 2311 and 2314. The specimen consists of the uterus, with a large tumor springing from the fundus, and also of the intact tubes and ovaries. The uterus is distorted by the presence of a tumor. The uterus is 8 cm. long, 5.5 cm. broad, and 2 cm. in its anteroposterior diameter. The

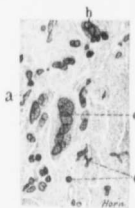

FIG. 147.—SUSPICIOUS CELL CHANGES IN A MYOMA. ($\times 460$ diam.)

Path. No. 2314. a represents approximately the usual size of the nucleus in a muscle-fiber. At b one cell is overlapping another. Both are much enlarged. At c we have a giant-cell containing six nuclei, all of which are larger than those of normal muscle-fibers. There is some polymorphonuclear and small-round-celled infiltration, as indicated by d. The presence of the large nuclei at b and c is somewhat suggestive of sarcoma, but these are occasionally found in benign myomata.

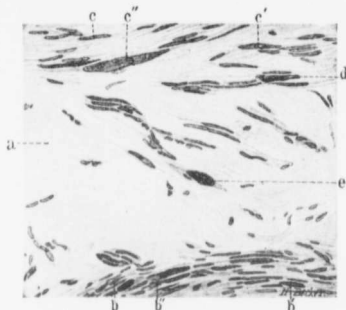


FIG. 148.—EARLY SARCOMATOUS CHANGES IN A MYOMA ($\times 225$ diam.)

Path. No. 2314. Much of the tissue has undergone hyaline degeneration, as indicated by a. At b we have muscle-fibers of the usual size; at b' is a nucleus twice as large as normal, and at b'' the nuclei are not only much larger, but also contain an increased amount of chromatin. c, c', c'' also depict the gradual transformation of muscle nuclei into very large ones, so suggestive of a malignant change. The nucleus d is enlarged, stains deeply, and has an irregular outline. The cell e is particularly well outlined, lying free in the hyaline tissue. It is greatly enlarged, and the nucleus is fully five times the normal size, contains much chromatin, and two hyaline droplets. From this field alone we would strongly suspect sarcoma, but could not venture a positive diagnosis.

cervical canal is 6 cm. in length and its mucosa is slightly granular. The uterine cavity is 4.3 cm. long and 1.5 cm. broad at the fundus. The mucosa lining the uterine cavity averages 2 mm. in thickness and has a smooth surface, but a few of the glands are dilated, some reaching 1 mm. in diameter.

Springing from the fundus by a pedicle, 3.5 cm. in diameter, is a large lobulated tumor, about the size of an adult's head, measuring 21 x 16 x 11 cm. (Fig. 146). This is the large mass that filled the lower abdomen. It is irregularly roughened, pinkish in color, and on section appears fibrillated. Some of the fibers present a parallel arrangement; others are grouped concentrically. At many points the tissue appears to have undergone degeneration. Taken as a

whole, the tumor is softer than an ordinary myoma, and tears more readily. The portion of the tumor which shows the least degeneration, however, presents the typical myomatous appearance. Situated in the posterior wall of the uterus is a small myoma, 2 cm. in diameter.

Right side: The tube on passing outward 10 cm. is lost on the surface of the tumor. It averages 5 cm. in thickness. The ovary measures 5 x 2 x 6 cm. Its outer pole is adherent to the tumor.




FIG. 119.—MYOMATOUS TRANSFORMATION OF MYOMATOUS TISSUE. (X 275 diam.)

Path. No. 2314. At a the nuclei of the muscle-fibers are pale-staining and comparatively normal in size. In the area indicated by b, and including about one-sixth of the field, the muscle-bundles have been cut transversely. The majority of the fibers are normal, but here and there (c) the nuclei are enlarged, slightly irregular, and stain deeply. In the area d, where the fibers have been cut longitudinally, the gradual transition of normal nuclei into the large, irregular, and deeply staining ones can be followed. In the area e the same gradual transition of average-sized nuclei into large and deeply staining ones can be outlined.

Left side: The appendages are normal.

The glands along the uterine are slightly enlarged; no metastases are to be detected in them or in any of the organs. The right lung shows a good deal of consolidation in the lower lobe, and cultures reveal a lamellicolte diplococcus, probably *M. mageritensis*.

Heart: The coronary arteries are diffusely thickened. The heart valves are normal.

Histologic Examination.—Sections from the denser portions of the tumor

show non-striped muscle-fibers closely packed together. Sometimes these are cut transversely, but in many places longitudinally; or they run in and out in every direction. The picture is that of an ordinary myoma. Here and there are foci of hyaline degeneration, sharply defined from the surrounding muscle and frequently entirely devoid of muscle-fibers. Occasionally the degeneration is more diffuse, isolated bundles of muscle undergoing hyaline transformation. In other portions of the tumor the picture is different. Here dark-staining areas can be detected with the low power. On careful examination they are found to consist of enlarged nuclei (Figs. 147, 148, 149, 150, 151, 152, 153, 154, and 155). Some of these are spindle-shaped and four or five times the size of those surrounding them; they stain very deeply, and their chromatin is finely granular. All gradations from the ordinary muscle nuclei to these enlarged and deeply staining ones are demonstrable. In the neighborhood of these there are also very large and irregular, deeply staining masses of chromatin, at least twenty times the size of an ordinary nucleus. Many of these enlarged cells are found scattered throughout the tissue. On examination of still other portions of the tumor a very unusual picture is noted. The nuclei of the cells become about twice the size of those of an ordinary muscle-fiber. There is, however, no alteration in the arrangement of the fibers. This area is undoubtedly malignant in

character, and there is a direct transformation from the myomatous into sarcomatous tissue, characterized primarily by an increase in size of the nuclei and the tendency to become irregular in outline, and by a considerable augmentation in the chromatin. From some portions of the tumor all traces of myoma have disappeared, and the cells have oval, vesicular nuclei. A number of them contain nuclear figures. The nuclei are very closely packed together, and the

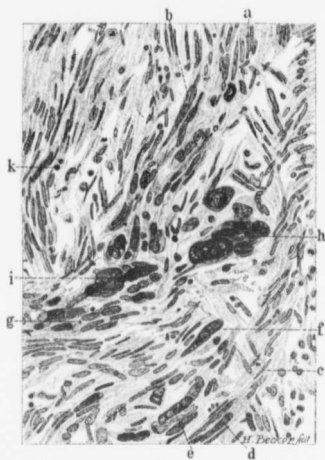

FIG. 150.—GRADUAL BUT DIRECT TRANSITION OF MYOMATOUS INTO SARCOMATOUS TISSUE. ($\times 210$ diam.)

Path. No. 2314. a is the normal size of the nucleus of the muscle-fiber. At b we see the gradual transition into nuclei fully five or six times as large. At c the nuclei are also normal, but at d considerably enlarged and more deeply staining. At e they are grouped and still more enlarged, and at f are of such a size as to very strongly suggest a sarcomatous change. In the vicinity of g the same gradual transition from normal muscle-fibers into enlarged and suspicious ones is seen. The groups of very large, irregular, and deeply staining nuclei at h and i leave absolutely no doubt as to the malignant character of the process. Some of these nuclei contain hyaline droplets. The tissue shows slight small-round-celled infiltration, as indicated by k. This picture demonstrates clearly the gradual transition of muscle-fibers into sarcomatous cells.

entire picture is that of sarcoma. This sarcomatous tissue does not show a tendency to hyaline degeneration, but where the tissue dies, it undergoes

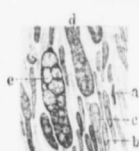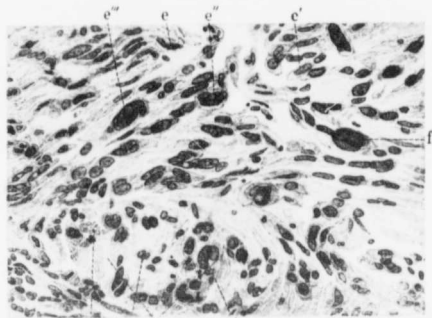


Fig. 152.

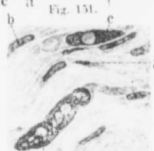

Fig. 153.

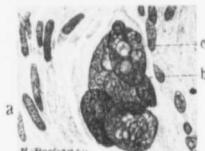

Fig. 154.

SARCOMATOUS TRANSFORMATION OF MYOMATOUS TISSUE. ($\times 380$ diam.) Figs. 151, 152, 153, and 154 are from the same specimen (Path. No. 2314); all are enlarged the same number of times.

FIG. 151.—a represents a cross-section of a myomatous bundle of muscle-fibers. At b are cross-sections of the tips of muscle-fibers too near their ends to include portions of the nuclei. c is a cell containing two nuclei, and at d we have a cell containing three large, deeply staining nuclei. In this muscle-bundle all transitions from normal fibers to those containing very large and suspicious nuclei can be traced. e is the nucleus of a comparatively normal muscle-fiber. At e' the nucleus is fully twice the usual size. e'' is much enlarged, contains a good deal of chromatin and several hyaline droplets. e''' shows a still further nuclear enlargement, together with a tendency toward the formation of giant-cells. At f there is a distinct giant-cell formation.

In this specimen we can trace the gradual transition of muscle-fibers into sarcoma cells, not only where the fibers have been cut longitudinally, but also where they have been cut transversely.

FIG. 152.—a shows the average size of a myomatous muscle-fiber; b, c, and d represent the various stages in the enlargement of the muscle-fibers. e is a very much enlarged cell containing an abundance of chromatin and many hyaline droplets.

FIG. 153.—a represents the average size of the nucleus of the myomatous muscle-cell. b shows considerable enlargement, but the nucleus still stains palely. c is much enlarged, contains an abundance of chromatin, and one hyaline droplet. d is a greatly enlarged and somewhat irregular nucleus, containing much chromatin and many hyaline droplets.

FIG. 154.—No muscle-fibers of normal size are to be seen. At a the nuclei are fully twice the average size, and quite a number of cell-shadows are seen where the nucleus is wanting. b indicates the group of five very large nuclei, containing quantities of chromatin and many large and small hyaline droplets, as indicated by c. (Figs. 152 and 153 are in themselves very suggestive of sarcoma. Figs. 151 and 154 indicate beyond doubt the sarcomatous character of the growth.)

coagulation necrosis. Traversing the sarcomatous areas are numerous delicate blood-vessels.

This is a most instructive case. On the one hand, we have typical myomatous tissue; on the other hand, a most pronounced example of sarcoma, both situated in the subperitoneal myoma, and almost isolated from the uterus. Fortunately, we are able to trace the direct transition of the myomatous muscle into the sarcomatous tissue. For those who are skeptical as to the sarcomatous

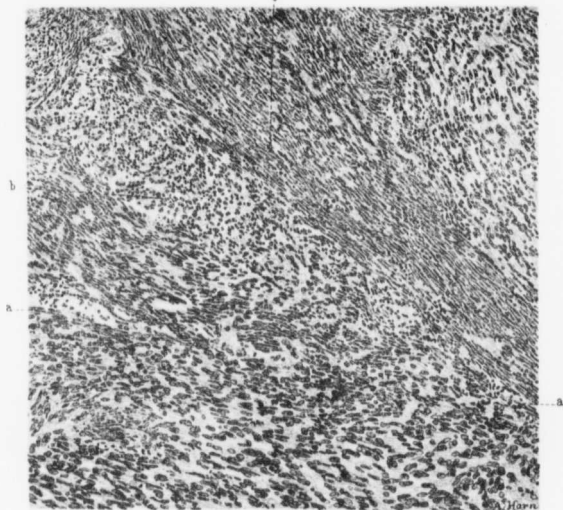


FIG. 155.—JUNCTION OF MYOMATOUS AND SARCOMATOUS TISSUE. (X 150 diam.)

Path. No. 2314. A line between a and a' divides the field into an upper one, composed of myomatous tissue, and a lower, made up of sarcoma-cells. At b the bundles of muscle-fibers have been cut transversely, and the nuclei accordingly appear round. They are uniform in size. In the vicinity of c the fibers have been cut lengthwise. The sarcomatous tissue commencing at a and extending to the lower border of the field shows no definite arrangement, but consists of a homogeneous sea of cells. The nuclei of these cells are, for the most part, oval and vesicular; they are much larger than those of the muscle-fibers. The line of junction between the myomatous and sarcomatous tissue is not well defined.

transformation of muscle-fibers we think that the histologic picture, as seen in the accompanying drawings, will tend to remove all doubt.

Gyn. No. 8836. Path. No. 5032.

Sarcoma of the uterus apparently originating in a myoma. Clinical diagnosis, degenerated myoma.

J. R., white, aged forty-eight, married. Admitted June 13; died June 15, 1905. The patient entered complaining of uterine hemorrhage. Her menses

began at sixteen, and were regular, usually lasting three days. She has been married twenty-five years, has had two children (twins), but no miscarriages. Following the labor she had a severe attack of puerperal sepsis, the fever lasting for three weeks. Her last menstrual period was three weeks ago, and since then she has had a slight but constant bleeding, although not severe enough to cause any marked symptoms. She is well nourished. The abdomen is rounded and symmetric. On vaginal examination a free hemorrhagic discharge is noted. The cervix is high up, pointing posteriorly. In front of the cervix, and between it and the symphysis, is a large, rounded mass, reaching half-way to the umbilicus. This appears to be fluctuating, and is apparently continuous with a hard mass posteriorly, and resting more or less on the sacral promontory.

Operation. Panhysterectomy. It was found necessary to do a bisection on account of adhesions. Both the bladder and rectum were injured and were immediately repaired. Two pelvic drains were introduced, and also a retention catheter. The pulse was thready and weak throughout the entire operation, being hardly perceptible when the operation was started. The bladder anteriorly had been carried well up above the symphysis by adhesions, and posteriorly there were many adhesions to the bowel, some of which were very dense. The patient on her return to the ward was much collapsed, notwithstanding the rapidity with which the operation was performed. Her pulse was 130, very weak and irregular, and the extremities were cold. In spite of stimulation she gradually grew worse, and died the same afternoon.

Path. No. 5032. The specimen consists of a bisected uterus with the lateral appendages. The whole mass measures 14 x 10 x 10 cm. The outer surface is everywhere rough and covered with adhesions. The uterus is more or less symmetrically enlarged, on account of the soft, fluctuant tumor which has developed in the posterior wall. The anterior wall is 3 cm. in thickness and of normal appearance. The uterine cavity is 10 cm. in length. The mucosa appears normal. On cross-section the myoma presents a somewhat edematous appearance. The lateral structures are adherent, but not much enlarged. The specimen is mutilated, making a more accurate description impossible. Macroscopically, the diagnosis is interstitial myoma with adherent appendages. Scattered throughout the walls of the uterus are several small myomata, but the main growth is exceedingly soft, and gradually blends with the surrounding muscle, being in no way so sharply circumscribed as an ordinary myoma.

Histologic Examination.—The growth apparently arises from the muscle. All transition stages from muscle-fibers to those of a malignant type can be traced. The nuclei gradually become larger; they stain more deeply, and finally all evidence of muscle structure disappears. In some places the arrangement is that of a myoma; in other places there is no definite arrangement. No cell division is evident. The blood-vessels are well formed. The diagnosis of sarcoma is certain.

This case demonstrates the danger in the routine adoption of bisection of

the uterus. It is impossible to tell whether the sarcoma is really due to a breaking-down of a myoma, but the evidence is strongly in favor of it. At any rate, we have a sarcoma associated with a myoma.

Gyn. No. 8610. Path. No. 4823.

Sarcoma of the uterus apparently originating from a myomá.

M. G., white, aged thirty-nine, married. Admitted March 27; discharged April 23, 1901. Clinical diagnosis: Uterine myoma with sarcomatous degeneration. The patient entered complaining of painful menstruation and constant backache. Her menses began at fourteen and were usually regular, lasting three or four days. In August, 1900, the patient had a slight bleeding after her regular period was over. In February, 1901, she had two periods, and for the last month the bleeding has been constant. The patient has been married seventeen years and had one child, sixteen years ago. She has had much pain in the lower abdomen for ten months, and backache for years. The abdomen is full, rounded, everywhere soft except in the hypogastric region, where there is considerable resistance on deep palpation. On vaginal examination the cervix is found low down, lying to the left side. Springing from the cervix and filling the superior strait is a smooth, hard, rounded mass, apparently extending two-thirds of the way to the umbilicus. This mass is somewhat fixed.

Operation. On opening the abdomen a purplish tumor mass was found choking the pelvis. This resembled a cystic ovarian tumor, and was so firmly wedged in the pelvis that it could not be pushed up. It was very adherent on the left to the pelvic brim, and also somewhat friable, suggesting malignancy. Bisection was followed by very little hemorrhage. The cervix was split for drainage, as there was considerable persistent oozing. For the first day after operation the patient had considerable oozing from the vagina. She gained rapidly and was discharged in good condition.

Path. No. 4823. The specimen consists of a large uterus with the tubes and ovaries attached. The portion of the uterus present measures 12 x 14 cm. Occupying the anterior portion of the cavity is a nodular growth. The nodules vary from 0.5 to 3.5 cm. in diameter. At first sight they appear to be cystic, but on careful examination the majority are found to be solid. The smaller are smooth, and on palpation are found to be soft. The larger ones present a mottled appearance, being pink, dark red, or red in color, as a result of the appearance of the blood-vessels, which at certain points vary considerably in number. The larger nodules are very soft, and here and there appear to be cystic. On section, the growth occupying the anterior wall seems to consist of one diffuse mass. In the central portion it resembles myomatous tissue, and numerous strands of tissue can be seen running in all directions. In over one-half of the specimen, particularly in the outlying portions, a very homogeneous appearance is present. These areas are very translucent, and stand out in sharp contrast to what ap-

pears to be myomatous tissue. It is this homogeneous and translucent growth that forms the bosses or nodules on the surface.

Right side: The tube is 7 cm. long and has a patent fimbriated extremity. The ovary is apparently intact. The utero-ovarian ligament contains a sub-peritoneal nodule, 1.5 cm. in diameter. This, on section, is perfectly white in color and homogeneous in structure. The ovary measures 3 x 2 x 2 cm.; it is covered with delicate adhesions, and contains a dilated corpus luteum. Between the tube and ovary is a lobulated mass, 2 cm. in length, 1.5 cm. in breadth, and approximately 1 cm. in thickness. On section, it is found to be made up of distinct foci of a homogeneous growth. They are without doubt extensions from the uterine growth.

Left side: The tube is 7 cm. in length, and is small throughout its course. At its proximal end, for a distance of 2 cm., it is represented by a flattened band, 1 cm. in thickness. The fimbriated extremity is free, but at several points are milky-white areas in the folds of the fimbriae, and on palpation small nodules can be felt. The nodular growth has evidently involved the fimbriae of the tube. The tube measures 4.5 x 3 x 2 cm. It is covered with a few adhesions. Between the tube and ovary is a nodule 8 mm. in diameter. This is sharply circumscribed, pearly white, and translucent, being evidently secondary to the old growth. Between the end of the tube and the ovary is a smaller nodule, 7 mm. in diameter.

Histologic examination shows that the growth is a sarcoma, and there appears to be a transition between the muscle-fibers and the sarcoma. It is impossible to determine with certainty whether it was primary sarcoma of the uterus or whether it was secondary to the myoma.

Gyn. No. 11944. Path. No. 8350.

Large interstitial and partially submucous myoma. Marked hyaline transformation, with liquefaction, and undergoing sarcomatous transformation. Normal tube and ovary.

R. A., white, aged forty-six, married. Admitted March 7; discharged March 29, 1905. The patient complains of an abdominal tumor. She has had two children and no miscarriages. The oldest child is thirteen, the youngest, ten. The menses began at sixteen, and at first were regular and normal in amount. Since the birth of the last child, ten years ago, the flow has been excessive, lasting as long as eight or nine days, until two years ago; since that time it has been very scant, and the periods have been irregular. At times she has had no flow for four or five months. The last period was two months ago. This one was so excessive that the uterus had to be packed. The doctor at the time the child was born, ten years ago, noticed a tumor, and thought at first that it was a second child. This tumor increased in size, and six years later she was treated with electricity and the tumor apparently became smaller. Since the hemorrhage two

months ago the patient has remained in bed on account of weakness. The left leg began to swell. There was difficult and painful urination.

The abdomen was distended to the size belonging to a full-term pregnancy. The tumor was rather soft in consistence. It rose to the costal border. The uterine vessels were very large, some of them reaching 1 cm. in diameter. The uterus was amputated through the cervix. The patient stood the operation well. She made an excellent recovery, and was discharged March 29, 1905.

Path. No. S350. The specimen consists of a greatly enlarged uterus, which has been amputated through the cervix. It is 25 cm. in length, 17 cm. in breadth, and 16 cm. in its anteroposterior diameter. It is perfectly smooth and glistening. The great increase in size of the uterus is due to the presence of a myoma, 20 cm. in its greatest diameter. This myoma on section is edematous, and here and there shows a certain amount of breaking down, presenting a typical picture of a myoma undergoing diffuse hyaline degeneration with moderate liquefaction. At one point is an irregular cystic space, 3 x 2 cm. Its walls are rather ragged, and the appearance suggests a breaking down of myomatous tissue. At several points are little whitish nodules, rather hard. Such areas have undergone calcification. The uterine cavity is 15 cm. in length. The mucosa is smooth and glistening, but exceedingly thin.

On histologic examination the mucosa of the body of the uterus is intact. The surface epithelium is perfectly preserved. The glands are normal. The mucosa is exceedingly thin. The stroma is normal. The veins in the mucosa are here and there much dilated. The muscle immediately beneath the mucosa is normal. Then, as we pass directly to the myoma, a marked change is noted. The muscle has a wild appearance, and under the low power the nuclei are enlarged and stain deeply. These deeply staining nuclei sometimes are isolated; in other places there are rows of three or four. The nuclei also occur in bunches of four or five, presenting a mulberry-shaped appearance. These nuclei are three or four times the normal size, and stain deeply. Nearly the entire central portion of the myoma has undergone complete hyaline transformation, and there is also liquefaction, partial or complete. In places where the muscle-bundles are intact one also notes an irregularity in the size of the nuclei, many of which are becoming larger. Far out in the hyaline tissue the muscle-bundles here and there are still preserved. Some of these present the usual appearance; others show an increase in size of the nuclei, and augmentation in amount of chromatin, together with deep staining. At one point in the hyaline tissue one sees an exquisite picture, a few muscle-fibers being preserved around an artery. The lumen of the artery is still intact, and a few of the muscle-fibers present the normal appearance, but those a short distance away show marked activity. Sections were cut from various areas corresponding to over half the surface of a longitudinal section of the myoma. The same picture is noted in nearly all of them. Sections through other portions of the myoma show absolute hyaline transformation.

We have here an interstitial and partially submucous myoma, which has

undergone almost complete hyaline transformation. The myoma, at its junction with the normal muscle, has undergone sarcomatous transformation. The islands of myomatous tissue that have been preserved in the hyaline areas also show similar changes. There is not the slightest doubt that the sarcoma is developing from a myoma. This is another example of the predisposition of myomata that have undergone marked hyaline changes and liquefaction to become sarcomatous.

Gyn. No. 1558. Autopsy No. 353.

Multiple uterine myomata with marked sarcomatous implication of the abdominal viscera and lymph-glands.

In this case the uterus was enormously enlarged, and possibly bore a causal relation to the wide distribution of sarcomatous nodules. Being in no position, however, to prove this, we have placed the case in a class by itself.

M. B., colored, aged thirty-eight, married. Admitted September 10; died October 1, 1892. The patient has never been pregnant. Her menses commenced at fourteen and were regular, the flow lasting from five to six days, and accompanied by cramp-like pains. The flow has been very profuse and abundant. In 1891 her friends noticed that her abdomen was larger than usual, but the increase in size had been painless. She has lost in weight since March of this year, and is very short of breath. The abdomen is distended from the symphysis to the xiphoid, and from flank to flank. It is globular in shape. There is an umbilical hernia, 3.5 x 3.5 cm.; through the hernial opening hard nodular masses can be felt, and the lower ribs are lifted up.

The patient was not operated upon, but sunk rapidly during the two or three days preceding her death, suffering but little from pain, but markedly from dyspnea. The temperature for the first two weeks varied between normal and 100.7° F. for two days prior to her death, later between 95° and 96.4° F.

Autopsy No. 353. Anatomic diagnosis: Multiple uterine myomata; myoma in vaginal wall; compression of the iliac veins; sarcoma of the peripancreatic and mesenteric lymph-glands. Secondary sarcoma of the peritoneum, omentum, mesentery, intestine, stomach, liver, pleura, and lungs.

Peritoneal cavity: Several hundred cubic centimeters of yellow fluid were present. When the abdomen was opened, a large mass was found occupying the entire pelvis and reaching to the umbilicus. It was nodular, hard, and had a sulcus corresponding to the median line. Smaller nodules were distributed over the surface of the tumor. The parietal peritoneum was studded with nodules varying from 1 to 6 mm. or more in size. Some of them were coalescing. Similar nodules were present on the intestines and the mesentery. The omentum was greatly distorted and thickened, and extended to the lower border of the umbilicus. It was studded with similar nodules, grayish white in color. The

smaller ones were somewhat translucent. The omental vessels everywhere were dilated and showed extravasations. The liver was adherent to the intestine and to the abdominal wall in the median line, and extended 8 cm. below the ensiform cartilage. The whole of the small intestine was located in the right hypogastric region, and coagulated serum was present between the intestinal loops. In the left hypogastric region was a large firm mass, adherent to the adjacent structures.

The spleen was adherent and high up. At the site of the left kidney was a large firm nodular mass. The lungs were not adherent, but nodules could be felt beneath the pleura. The uterus was enormously and symmetrically enlarged. The left side was more prominent than the right. The peritoneal surfaces were studded with nodules, similar to those above mentioned. Large confluent nodular masses covered the floor and sides of the cul-de-sac. On the right side and anterior to the uterus was a globular mass, about the size of an orange, markedly constricted at its point of attachment. On section, it was dense and presented the usual myomatous picture. Above and to the right of it a second and similar tumor, the size of a walnut, was present. On the left, over the posterior surface, were some six or eight other subperitoneal nodules, the smaller ones measuring about a centimeter, the larger the size of a walnut. On section, the walls of the uterus, which was greatly hypertrophied, were found to contain numerous myomata of various sizes. Submucous myomata were also present.

Vaginal myoma: In the posterior wall of the vagina, embedded in loose tissue and not adherent to the wall, was a myoma, 4 x 2 cm. This tumor was shelled out without difficulty.

Mesenteric tumor: A tumor, weighing 2800 gm. and measuring 23 x 9 x 13 cm., occupied the left upper abdominal quadrant and was pressing down upon the left kidney. It was separated from the surrounding structures with difficulty. It appeared to be retroperitoneal. It was firmly attached behind, and sprang apparently from glands about the pancreas. It was encased in a thin capsule, from which it could be stripped. It was irregularly nodular, and on its outer surface were grayish trabeculae. On section, it appeared homogeneous, excepting where large areas of coagulation necrosis and hemorrhage were present. Firmly adherent to the upper surface of this tumor was a second one, measuring 22 x 12.5 x 10 cm., and weighing 1200 gm. It presented an appearance similar to that of the tumor described.

Metastases were found in the walls of the stomach and intestines, in the liver, pleura, lungs, and mesentery.

Histologic examination showed that the retroperitoneal growth was a sarcoma. There is no mention as to the probable origin of this retroperitoneal growth. On microscopic examination of the uterus it looked very much as if we had two independent processes, a retroperitoneal sarcoma and numerous subperitoneal, interstitial, and submucous uterine myomata.

MYOMATA PRESENTING GROSS OR HISTOLOGIC APPEARANCES SUGGESTIVE OF SARCOMATOUS DEGENERATION.

In the foregoing pages we have dealt with myomata showing undoubted sarcomatous changes. We will now review several cases in which the myomata show alterations somewhat suggestive of sarcomata, changes, however, that are not sufficiently conclusive to warrant a positive diagnosis of malignancy. Sometimes the gross appearance of the myoma suggests a sarcomatous change, but in the majority of these the growth will present the typical myomatous picture, and only on careful histologic study will any evidence of sarcoma be found.

Sometimes it is particularly difficult to determine whether a given specimen really shows sarcomatous changes or not. We have had seventeen cases in which the growth, either in the gross or microscopically, presented alterations that strongly suggested a malignant condition, but in which the changes were not sufficiently marked to enable us to say with certainty that they were sarcomatous. These border-line cases are of especial interest to the pathologist, and we accordingly give the salient features in each case.

For convenience these cases can be divided into two groups:

- (1) Those showing gross appearances strongly suspicious of sarcoma.
- (2) Those in which the histologic picture is suggestive of sarcoma.

Of course, some of the cases show both gross and histologic changes strongly indicative of malignancy.

Cases in which the Gross Appearances of the Tumor Suggested Sarcoma.

The myoma in Case 12788, although small, was markedly lobulated, presented a mottled appearance, and might have been readily mistaken for sarcoma. As soon as it was touched, however, all doubt was dispelled, as the characteristic density of myomatous tissue was everywhere in evidence.

In Case 8477 a nodule, 2 cm. in diameter, projecting from a large myoma, was so soft that sarcoma was at once suspected. So firmly convinced was the operator that he was dealing with a sarcoma that a complete hysterectomy was performed.

In Case 12864 the tumor at operation was found to be very soft; moreover, it bled easily and felt like sarcoma. This softening was due chiefly to cystic and hyaline changes. In certain areas the capillaries were so abundant, and their endothelium had so proliferated, that the tissue was divided up into myriads of alveoli, at first glance strongly suggesting a malignant growth.

In Fig. 156 (p. 238) we have a large subperitoneal myoma springing from the posterior surface of the uterus, and attached to it by a broad pedicle. One is instantly struck by the unusual appearance, the growth presenting a markedly lobulated form, welling up, as it were, on all sides of the pedicle. Again, at c and d are represented clumps of small flat papillary outgrowths. From the pathologic report we learn that the surface of the growth was very vascular. Thus far the

growth bears a striking resemblance to a malignant growth, as only exceptionally do we find such a welling-out of tissue on all sides; and, further, in benign myomata such papillary masses as are seen at c and d are rarely ever noted. On section, the growth was found to be in part solid, in part cystic. Its cut surface resembled that of a myoma. On histologic examination, in general it presented the appearance of a simple myoma, but in places the cells were very abundant and closely packed together. Furthermore, a few nuclear figures were found. Both these findings suggest to a slight degree sarcoma, but there was marked uniformity in the size of the nuclei. In this case, although sarcomatous degeneration cannot be positively excluded, the weight of evidence is in favor of a rapidly growing but benign myoma. Fig. 157 (p. 241) represents half of a uterus which shows a diffuse myomatous thickening. At c we have a small, well-defined submucous myoma; at d, two minute myomata, and at e a partially pedunculated submucous myoma. This pedunculated submucous nodule is the one of chief interest. The mucosa over it is everywhere intact. The nodule near its base shows remains of the muscle-bundles, but in the upper portion and near the tip the tissue presents a homogeneous appearance, all trace of fibers having disappeared. This homogeneity, coupled with the softness of the growth, instantly arouses one's suspicions of a malignant growth, and as the mucosa covering it is intact and somewhat atrophic, the most natural supposition is that the myoma is undergoing sarcomatous changes, which, however, are very early.

The histologic appearances of this submucous nodule, as seen in Fig. 158 (p. 242) and Fig. 159 (p. 243), are even more suggestive of sarcoma. In Fig. 158 the appearance of "unrest" is manifest. Here in places the cells are more closely packed; in another place one cell may contain two nuclei, while in the neighborhood may be a cell containing five or six nuclei. Some of the nuclei contain an increased amount of chromatin. In Figs. 159 and 161 the changes are still more marked. Here we have ill-defined giant-cells and large, irregular, deeply staining nuclei, containing hyaline droplets. Polymorphonuclear leukocytes and small round cells are also scattered throughout the field. In Fig. 160, while the same changes are to be noted, very large and irregular clumps of chromatin are seen lying in hyaline tissue. In this case both the gross and histologic pictures are very suggestive of sarcomatous degeneration of the myoma. If a malignant change is present, it is still in its infancy, as the growth is small, well defined, and has not pushed its way through the thin overlying layer of mucosa. We can readily understand how a sarcoma may develop in such a small myoma, and how, in the course of a few months, all trace of the original myomatous tissue may be obliterated.

Gyn. No. 9118. Path. No. 5274.

A large myomatous uterus with myomatous tissue welling out from the uterus, and presenting a picture macroscopically suggestive of sarcoma (Fig. 156).

E. S., white, aged forty-eight. Admitted October 10; discharged November 8, 1901. The patient complains of an abdominal tumor. The menses commenced at eleven and were regular; the flow was scanty in amount. Since the onset of the present trouble the flow has lasted one week, but there has been no excessive bleeding. There has been a discharge with a very offensive odor.

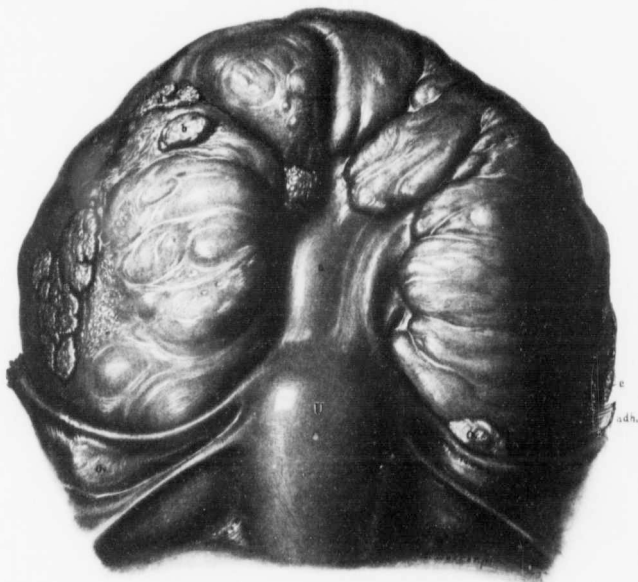


FIG. 156.—A RAPIDLY GROWING SUBPERITONEAL MYOMA WITH SMALL, PAPILLE-LIKE OUTGROWTHS SPRINGING FROM ITS SURFACE. ($\frac{1}{3}$ NAT. SIZE.)

Path. No. 5274. The uterus is relatively normal in size, and the tubes and ovaries present the usual appearance. Springing from the fundus by a broad pedicle, *a*, is a very large subperitoneal myoma. This tumor, instead of being smooth and globular, wells up on all sides of the pedicle, leaving here and there deep clefts where the connective tissue has been particularly dense. *b* is a flattened myomatous nodule lying on the surface of the large growth. At *c*, *d*, and *e* are flattened, papilla-like outgrowths of myomatous tissue. A myoma presenting such a picture is rarely seen.

The patient has been married twenty-eight years and has had two children. She first noticed a mass in the right side seven years ago. This has grown steadily larger and caused pain in the right side; otherwise she feels well. Hemoglobin, 75 per cent.

Operation. The pedicle attaching the tumor to the uterus was first cut, the tumor being then separated from the uterus. The tumor having been bisected,

the left half was removed, and later the right. This bisection was done on account of adhesions. The patient made a very satisfactory recovery.

Path. No. 5274. The tumor is oval in shape, and measures 22 x 16 x 16 cm. It was attached to the posterior part of the left side of the uterus. It was densely adherent to the rectum and to surrounding tissue. The tumor as a whole is bluish gray in color, and on first inspection reminds one of an ovarian cyst. It is irregularly lobulated, and springing from the surface are numerous papillalike outgrowths. Their presence is explained by the fact that the tumor substance has grown too rapidly for the capsule, and hence has welled out, producing these papillary masses (Fig. 156). They vary from the size of a pea to 4 cm. in diameter. The outer surface of the tumor is very vascular. On section, the portion nearest the pedicle has the appearance of a soft myoma. The remaining half has been converted into a thin-walled cyst. Traversing this cyst are numerous trabeculae stretching from side to side. The cyst contents are bloody in character.

Histologic Examination.—The growth in general presents the appearance of a myoma. In many places, however, there is much hyaline degeneration. At other points the entire field is filled with muscle-cells lying in such close relationship to one another as to give an indefinite suggestion of sarcoma. A few nuclear figures are here and there seen, but there is a marked uniformity in the size of the nuclei. The large, irregular, cyst-like spaces are due to a breaking-down of the tumor, as its walls have no epithelial lining, but are composed of hyaline tissue. There are also other smaller areas of liquefaction. The growth is a myoma undergoing hyaline degeneration. We do not think that there is any sarcomatous change, although the possibility cannot be excluded in view of the fact that nuclear figures are scattered throughout the myoma, a condition that is most unusual.

Subsequent history, November 24, 1902: Dr. Alexander Hannah writes that the patient feels quite well—better than she has been for twenty years, and is able to do all her own housework.

January, 1907: This patient is in excellent health five years and four months after operation.

Gyn. No. 12864. Path. No. 10311.

A very large multinodular myomatous uterus which at operation was so soft and bled so freely that the condition was strongly suggestive of sarcoma.

M. B., colored, aged forty-four, married. Admitted April 21; discharged May 23, 1906. Her menses commenced at thirteen, occurred every four weeks, and were usually rather profuse. The last period came on one month before admission. She has been married twenty-seven years, had one child twenty-six years ago, and no miscarriages. Swelling of the abdomen was first noticed fifteen years ago. The patient thought she was pregnant, but the menses did not cease, and there was no pain. The growth increased slowly, and seven

years later her physician told her she had a myoma, but advised against operation. The swelling has steadily increased in size. For the past five months there has been pain in the lower back, and bearing-down pains in the abdomen after exertion. For the last three months the tumor has grown quite rapidly, and the pain in the abdomen and back has been severe at times. For the last four or five days she has had difficulty in micturition.

Operation. The omentum was densely adherent to the tumor. In lifting up the tumor it was found firmly adherent in the pelvis. It was very soft, bled easily, contained cystic areas, and was very suggestive of sarcoma. It was impossible to get a satisfactory exposure, and in dissecting on the left side an opening was made into the bladder, which had been lifted high up and pushed forward by a retrovesical nodule. After considerable difficulty the tumor was entirely removed. The patient was catheterized in all 58 times. She made a very satisfactory recovery.

Path. No. 10311. The specimen consists of a large multinodular myomatous uterus, 28 x 25 x 20 cm. The omentum is densely adherent to one of the large nodules. The myomata have undergone hyaline degeneration, and several contain areas of calcification along their edges. The uterine cavity is distorted, and the mucosa is scant in amount. The tubes and ovaries are normal save for a small cyst, 6 x 4 x 4 cm.

Histologic examination shows a myomatous uterus with definite hyaline areas. Along certain parts of the myoma the endothelium of the capillaries has proliferated to such an extent that the muscle-fibers are divided off into alveoli which one might very readily think belonged to a malignant growth.

San. No. 471. Path. No. 1815.

A submucous myoma presenting a homogeneous appearance and suggesting sarcoma (Fig. 157). Histologic changes suggestive of sarcoma (Figs. 158, 159, 160, 161).

D. C. C., white, aged forty-four, married. Admitted May 22; discharged June 30, 1897. Complaint, uterine hemorrhages. The patient has been married ten years, has had one child and no miscarriages. A year ago the periods became prolonged, lasting eight days, and the flow was more profuse. The patient has lost a great deal of blood. Operation, May 25, 1897. Abdominal hysterectomy. The highest postoperative temperature was 101°. The patient made a good recovery.

Path. No. 1815. The specimen comprises the uterus, tubes, and ovaries intact. The uterus measures 11 cm. in length, 8 cm. in breadth, and 5 cm. in its anteroposterior diameter (Fig. 157). Its peritoneal surface is smooth. The cervix presents a nodular appearance when viewed from below, but the mucosa lining the canal has minute prickles springing from its surface. The uterine cavity is 4.5 cm. in length. Its mucosa is very thin, but has a smooth, intact

surface. The anterior uterine wall varies from 2 to 3 cm. in thickness, the posterior from 2.5 to 4 cm. Occupying the fundus and projecting into the uterine cavity are two myomata. One is circular, 2.5 cm. in diameter, and presents the typical myomatous picture. The second nodule is somewhat pear-shaped, and

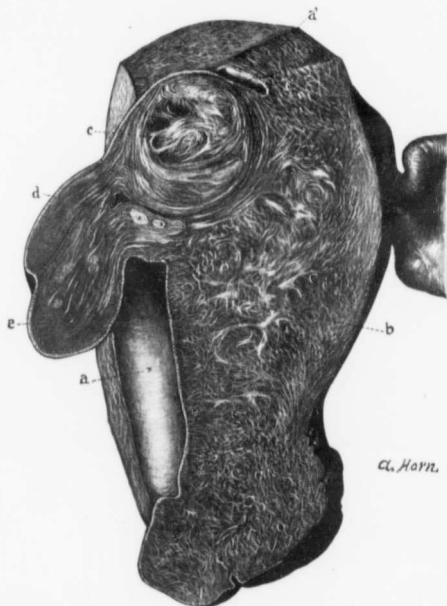

FIG. 157.—DIFFUSE MYOMATOUS THICKENING OF THE UTERINE WALL. DISCRETE SUBMUCOSAL MYOMA AND A SUBMUCOSAL MYOMA PRESENTING AN APPEARANCE SUGGESTIVE OF SARCOMA. (Nat. size.)

Path. No. 1815. The picture represents a longitudinal section through the uterus. The uterine cavity, as seen at *a*, is slightly enlarged. The mucosa is somewhat atrophic. At *a'* the upper part of the uterine cavity is seen. *b* is the diffusely thickened uterine wall. At *c* is a typical submucous myoma. *d* also indicates two similar, but much smaller, nodules. *e* is a pedunculated submucous myoma. Near its base the strands of muscle are clearly in evidence, but toward the tip the tissue is homogeneous and the fibrillation is lacking. This homogeneity is most unusual, and makes one instantly suspicious of a malignant change. For the histologic appearances see Figs. 158, 159, 160, and 161.

measures 3 cm. in length and 2 cm. in breadth. It is pedunculated and projects far down into the uterine cavity. It bears some resemblance to a myoma, but the coarse striation is lacking and the tissue appears somewhat homogeneous. This nodule is covered with an intact mucosa, which is, however, not more than 0.5 mm. in thickness. The tubes and ovaries are normal.

Histologic Examination.—Sections from the cervix show that the vaginal portion is normal, and that the cylindrical epithelium of the cervix, as well as that of the cervical glands, presents the usual appearance. The delicate out-growths seen springing from the surface of the cervix are papillary masses of stroma covered by a layer of cylindrical epithelium continuous with that of the mucosa proper. They are in no way suspicious. The mucosa of the body of the uterus has an intact surface epithelium. Its glands in a few places show hypertrophy, but, as a rule, are little altered. The stroma of the mucosa in the superficial portion contains a few small round cells scattered between the stroma cells.

The pedunculated, submucous nodule springing from the fundus consists in part of typical myomatous tissue, which here and there has undergone

complete hyaline degeneration. Along the margins of such hyaline areas there is frequently a deposition of orange-yellow pigment droplets, presumably the remains of old hemorrhages. In other portions of this small submucous myoma the tissue is rarefied or contains large areas of hemorrhage. At still other points all trace of the myomatous tissue is lost, and the nuclei, instead of being elongated, oval and regular in size, are plumper and vary greatly in diameter. Some of them contain round or oval translucent bodies, and nuclei five or six times the usual size, somewhat irregular in outline, and staining rather deeply. Again, four or five nuclei may form one clump, producing ill-defined giant-cells. Here and there is an irregular, very deeply staining nucleus. Such areas as the ones just described bear a striking

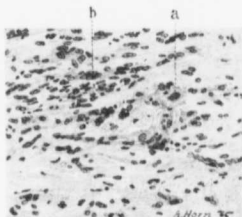


FIG. 158.—SUGGESTION OF SARCOMA IN A SMALL SUBMUCOUS MYOMA. (X 145 diam.)

Path. No. 1815. The section is from the suspicious nodule *e* in Fig. 157. On glancing at the picture one is instantly impressed with the appearance of unrest, and is reminded of sarcoma. At *a* is a cell containing two nuclei; at *b* is an aggregation of nuclei forming an ill-defined giant-cell. Scattered throughout the field are several deeply staining nuclei. The tissue is freely infiltrated with small round cells.

resemblance to those seen in sarcoma. Given such a picture alone, we would not hesitate to make a diagnosis of sarcoma. Having the gross specimen before us, however, with its still well-defined outline, we hesitate to speak of it as a malignant growth. We are, however, inclined to believe that there is a commencing sarcomatous degeneration.

The histologic changes are well depicted in Figs. 158, 159, 160, and 161.

Subsequent History.—The patient writes in 1902, that is, about five years after operation: "The year immediately following the operation I was in fairly good condition, but at the expiration of that year I began to lose strength and flesh, and for three years was in a most horribly nervous condition, unable to sleep most of the time without trional, and suffering constantly from intestinal indigestion. I am seemingly better this fall than I have been at any time since the operation."

Gyn. No. 12788. Path. No. 9662.

Interstitial and submucous uterine myomata. One of the myomata on section presents an appearance that might readily be mistaken for sarcoma.

J. D., white, aged forty, married. Admitted March 21; discharged April 26, 1906. Her mother died at the age of fifty-two, supposedly from uterine myomata, and two sisters were operated upon for myomata; both recovered. The patient at times has swelling of the feet and also shortness of breath. A year ago (Gyn. No. 11700) she entered the hospital and was treated for cystitis. Her menses began at sixteen, were profuse, and lasted from six to seven days. There

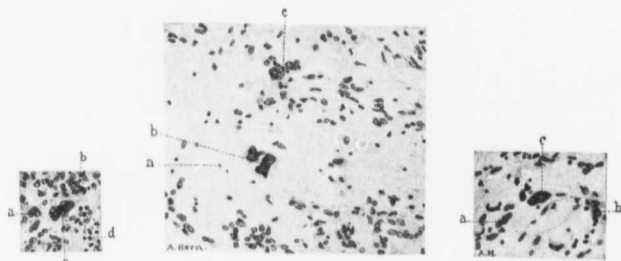


FIG. 159.

FIG. 160.

FIG. 161.

SUSPICIOUS CELL CHANGES IN A SMALL SUBMUCOUS MYOMA. (X 150 diam.)

FIG. 159.—Path. No. 1815. The section is from the suspicious submucous myoma (c) in Fig. 157. a is a small giant-cell. At b the nuclei of the muscle-fibers show a tendency to clumping; at c are two large, irregular, and rather deeply staining nuclei, suspicious in character. There is considerable small-round-celled infiltration, as indicated by d.

FIG. 160.—Path. No. 1815. This field is from the nodule (c) in Fig. 157, and shows hyaline degeneration, pronounced at (a). The two large, irregular, and deeply staining nuclei at b are most suggestive of a malignant change. The nuclei tend to form clumps (c). Scattered throughout the field are numerous small round cells.

FIG. 161.—Path. No. 1815. This section is also from the submucous nodule in Fig. 157. a and b show clumping of the nuclei, which correspond exactly in size and shape with those of the surrounding muscle-fibers. c is a very large irregular and deeply staining nucleus, containing two hyaline droplets and very suggestive of a commencing sarcomatous change. The tissue shows some small-round-celled infiltration.

never has been any intermenstrual bleeding until four weeks ago. The patient has been married twenty-two years, but has never been pregnant. The present trouble began four weeks ago, when she had profuse bleeding, with severe pain in both sides and in the back. The bleeding was excessive, and large clots came away. She first noticed swelling of the abdomen one month ago, and thought that she was getting stout. Hemoglobin, 70 per cent.

Operation. Hysteromyectomy with removal of adherent appendages. The patient made a satisfactory recovery. Her highest postoperative temperature was 101.5° F., on the second day.

Path. No. 9662. The specimen consists of the uterus amputated through the cervix. It is approximately 9 cm. in length, 8 cm. in breadth, and 7 cm. in its

anteroposterior diameter. Posteriorly it is covered by a few adhesions. Situated in the fundus is a markedly lobulated myoma, 3 cm. in diameter. This, on section, has a mottled appearance, due to the presence of large and small bundles, and might very readily be mistaken for sarcoma. It proves, however, to be exceedingly hard. Occupying the posterior wall and projecting markedly into the cavity is a submucous myoma, 3.5 cm. in diameter. The uterine mucosa is very atrophic throughout the entire cavity. The right tube is covered with a few delicate adhesions. The ovary is exceedingly small. The left tube is thickened and has a patent fimbriated extremity. The ovary has apparently been slightly adherent.

Histologic Examination.—The endometrium is to a great extent devoid of an epithelial covering. The glands are few and far between. The stroma of the mucosa shows considerable small-round-celled infiltration. There has evidently been a mild grade of endometritis. Over the submucous myoma the mucosa has almost entirely disappeared, and we have a zone of marked small-round-celled infiltration.

The gross appearance in this case was at first very suggestive of sarcoma. From a clinical standpoint the case is particularly interesting, as the patient's mother presumably died of myoma and as the patient's two sisters were operated upon for uterine myomata.

Gyn. No. 8477. Path. No. 4672.

Panhysterectomy instead of supravaginal hysterectomy on account of a suspicious subperitoneal myoma.

E. L., white, aged forty-nine. Admitted January 26; discharged February 21, 1901. Complaint, soreness and sharp pain in the lower abdomen. Her menses began at fourteen and were perfectly regular. The menopause occurred thirteen months ago. She has had no hemorrhage since then. She has been married thirty-one years, has had eight children and two miscarriages. Two weeks ago the patient was suddenly taken with pain and burning in the bladder region, and for a short time had marked frequency of urination accompanied by much pain. After seventy-two hours the dysuria practically disappeared, and the day following the patient had some soreness in the upper right side. Her temperature at this time rose to 101.5° F.

Operation. Hysteromyectomy performed in the usual manner; the perineum was also repaired. An abdominal incision having been made and the uterus brought up, a conical subperitoneal myoma was felt. On the tip of this myoma, which was the size of an orange, was a rounded projection 2 cm. in diameter, and softer in consistence than the myoma. This apparently was a small sarcoma, and on this account complete hysterectomy was performed. The patient made an uninterrupted recovery.

Path. No. 4672. The specimen consists of the uterus. From the posterior

surface a myoma has developed. The uterus measures 6 x 7 x 4 cm., and is of the normal consistence. Developing from the upper posterior wall of the fundus is a tumor 6 x 6. It is soft and almost fluctuating. It is covered with smooth peritoneum. The cut surface is succulent and resembles a soft myoma. The uterine cavity is 4 cm. in length and 4 cm. in breadth at the fundus. The mucosa is smooth and normal in appearance. In the median line of the fundus is a sessile polyp measuring 5 by 10 mm. The uterine wall is everywhere thicker than normal, averaging 2.5 cm.

In this case it is readily seen that, although the appearance at operation was very suggestive, the tumor on section bore no resemblance whatever to sarcoma.

MYOMATA MACROSCOPICALLY PRESENTING THE USUAL APPEARANCE, BUT HISTOLOGICALLY CONTAINING AREAS SUGGESTIVE OF SARCOMATOUS DEGENERATION.

The literature contains very little on this subject, but we are certain that if a systematic examination of all myomata were made early, sarcomatous changes or at least suspicious pictures would occasionally be detected. In the course of our investigation at least twelve tumors, which macroscopically presented little of interest, on histologic examination yielded pictures more or less suggestive of sarcoma. In Case 3113, although the myoma as a whole showed little that was unusual, nevertheless at several points the muscle nuclei were very large and contained correspondingly large oval or almost round nuclei (Fig. 162, p. 248).

The cell alterations in Case 3295 are very instructive. A lobulated sub-mucous myoma had been removed, and on histologic study at the junction of two lobulations marked cell changes were noted. At this point some of the nuclei were normal in size; others were four to five times the usual size, and stained deeply. Some nuclei appeared as long threads, being three or four times the normal length, and others cells contained three or four nuclei bunched together. Such a field is strongly suggestive of sarcoma. A rather odd coincidence in this case is the fact that, more than five years later, the uterus was removed on account of an adenocarcinoma which had meanwhile developed just above the internal os.

Case 3461 is also a good example of changes strongly suggestive of early sarcoma in the myoma. The tumor was composed of non-striated muscle-fibers which were markedly separated from one another, the entire tissue appearing to be edematous. Many of the muscle-fibers were normal, but numerous unusual pictures were seen. Here and there were spindle-shaped cells at least five times the usual length and four times the breadth. These contained five or six oval nuclei, which stained more deeply than those in the vicinity. In other places four or five nuclei were joined end to end. The picture instantly suggests sarcomatous transformation of muscle-fibers. Such cell changes were found sparsely scattered throughout the tumor, but were most abundant near the peritoneal surface.

In San. No. 577 we have another instructive example of suspicious cell changes in myomata. The myoma was situated in the posterior uterine wall and was edematous. Macroscopically, there was not the faintest suspicion of a malignant change. A reference to the pathologic report shows that the solid portions of the tumor presented a typical myomatous picture. Occasionally, however, the muscle nucleus was irregular in outline, stained somewhat deeply, and was five or six times the usual size. At other points the muscle-fibers had nuclei varying markedly in diameter. On careful study of such fields the following were noted: some of the nuclei were small, oval, and vesicular; others were twice the normal dimensions, while quite a number were four or five times larger than normal and had irregular outlines. All gradations between those of normal size and the larger ones were demonstrable. Occasionally large masses of protoplasm staining deeply with eosin and containing four or five large nuclei bunched in their centers were noted. Such cells are depicted in Figs. 163 (p. 250) and 165 (p. 252). At other points long fusiform masses of protoplasm, fully twelve times the length of normal muscle-fibers, were demonstrable, and some of these contained two or three enlarged nuclei bunched in their centers. One of these large fusiform cells is seen in Fig. 164 (p. 251), extending almost the entire length of the field. In sections from the softened areas of the myoma all trace of the myomatous arrangement had entirely disappeared. The tissue was rarefied, and many giant-cells were found. Nowhere, however, were nuclear figures demonstrable, nor was there much excess of chromatin. In this case the entire histologic picture was most suggestive of sarcoma.

The histologic picture seen in Fig. 166 (p. 253) represents a large giant-cell containing many small nuclei scattered regularly throughout it. This was the only unusual cell found in the myoma. Fig. 167 (p. 253) is from Case 5496, in which the patient suffered from "recurrent fibroids." These submucous myomata were, for the most part, necrotic; in many places no cell elements remained, but at other points were fragments of nuclei and much small-round-celled and polymorphonuclear infiltration. In the figure we see two very large muscle-fibers with correspondingly large and irregular nuclei. As noted in the history, this patient is now perfectly well. In some cases in which the myoma is undergoing necrosis much inflammatory reaction has taken place. We occasionally encounter rather large and deeply staining nuclei, as seen in Fig. 168 (p. 256). They suggest slightly a malignant change, but are evidently degenerative phenomena. While in nearly all these cases evidences of sarcoma were prominent, in none of them were we justified in making a positive diagnosis of malignancy. As is well known, early carcinomata may often be recognized by commencing changes in the epithelial elements, but the benign alterations in connective-tissue growths are so manifold and frequently resemble to so remarkable a degree malignant growths that one is often at a loss to determine whether a given case is benign or malignant, and must await the subsequent clinical history of the case or be able to detect metastases before saying that the tumor is really sar-

comatous. On the other hand, the growth may appear benign in character, and yet the clinical history may show that it is malignant. This is especially true of some spindle-celled sarcomata.

Gyn. No. 3113. Path. No. 487.

Interstitial uterine myomata with cell changes somewhat suggestive of sarcoma (Fig. 162). Very early carcinoma of the body of the uterus (Fig. 184, p. 295).

A. V. G., white, aged fifty-two, married. Admitted October 16; discharged December 6, 1894. The abdominal veins were greatly distended.

Operation, October 24th. Hysteromyectomy. There was excessive vascularity of the uterus and of the tumors, and extensive subperitoneal myomatous development. The bladder was high up in the abdomen. During removal of the tumor a portion of the bladder wall was accidentally removed. The ureters were catheterized. After removal of the uterus the bladder was sewed up with interrupted sutures. The patient made an uninterrupted recovery.

Path. No. 487. The specimen consists of a large globular tumor, in the upper part of which the uterus is situated. Both tubes and ovaries are intact. The tumor is approximately circular, 25 cm. in diameter. On its lower and anterior surface are five ill-defined bosses, the largest of which measures 8 x 5 x 3.5 cm. The tumor is whitish red in color, smooth and glistening, and covered with peritoneum. The under cut surface presents a denuded area, 25 x 15 cm. On the anterior surface of the tumor is a piece of bladder mucosa, 6 x 3 cm. The tumor on pressure is firm but yielding, and gives a faint sensation of fluctuation. On section it is whitish in color and presents a finely striated appearance. Scattered throughout the tumor are sinuses, the largest of which is 1.2 cm. in diameter. They are smooth-walled and communicate with one another. They contain a serous-like fluid. Some, however, are filled with dark-red blood. Most of these sinuses appear to be lymphatic in origin.

On section, it is found that the entire tumor mass springs from the posterior uterine wall. It is interstitial, having an outer covering of muscle, averaging 2 mm. in thickness. The posterior uterine wall is also filled with sinuses smaller than those found in the tumor.

Histologic Examination.—The glands of the cervix in places are dilated. The uterine mucosa is very atrophic. The surface epithelium is intact. The glands are few in number, and are small and circular on cross-section. The stroma of the mucosa shows considerable lymphoid infiltration, and non-stripped muscle-fibers are seen passing up into the stroma of the mucosa nearly as far as the uterine cavity. Springing from the mucosa are three polypi, one situated near the internal os and having a broad base; the second is 1.5 cm. from the fundus and pedunculated; a third is situated at the fundus. These polypi are covered with cylindric epithelium, have numerous glands scattered throughout

them, some of which are dilated, others empty. Some of the glands contain polymorphonuclear leukocytes and desquamated epithelium, blood, or hyaline casts. At one point is a very early carcinoma (Fig. 184, p. 295).

The uterine muscle just beneath the mucosa appears to be perfectly normal. In other places it contains numerous small empty spaces, some of which have an endothelial lining. These are probably lymph-spaces. The large tumor situated in the posterior wall is composed of non-striated muscle-fibers which show diffuse hyaline degeneration. In some places this degeneration is so marked that the muscle-bundles appear as small cells in hyaline material. There are many recent hemorrhages which are chiefly found in hyaline areas. In some places the tumor is edematous. In no place can polymorphonuclear leukocytes be detected. The blood-vessels of the tumor are moderate in number, the veins predominating. Scattered everywhere throughout the tumor are large and small empty spaces, some with, others without, an endothelial lining. As the blood in the arteries and veins has been well preserved in Müller's fluid, and since these spaces are comparatively free from blood, we are inclined to believe that they are lymph-channels. Passing across some of the smaller spaces are delicate capillaries, just large enough to admit the passage of one red blood-corpuscle at a time. In one of the large arteries a hyaline thrombus is seen. The tubes and ovaries are normal.

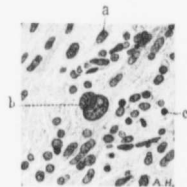


FIG. 162.—LARGE CELLS OCCURRING IN A SIMPLE INTERSTITIAL MYOMA. ($\times 450$ diam.)

Path. No. 487. *a* represents the average size of the nuclei of the muscle-fibers. At *b* are two nuclei, approximately spheroidal and much enlarged. Their chromatin is, however, only slightly increased. Above and below the center many of the nuclei tend to overlap one another and to arrange themselves in rows. *c* indicates some small round-celled infiltration. After detecting the large nuclei (*b*) further sections should be examined to see if more definite signs of sarcoma are present. From these nuclei alone we would not be warranted in saying that the growth was malignant.

The chief interest in the case centers in the presence of some very large cells containing equally large oval or almost round vesicular nuclei (Fig. 162). These suggest to a slight degree commencing sarcomatous transformation, but are by no means conclusive.

After the operation the patient did perfectly well, but she could not retain her water long without some pain.

Gyn. No. 3295. Path. Nos. 582 and 3948.

Submucous myoma showing cell changes very suggestive of sarcoma. Five years later complete hysterectomy for an adenocarcinoma apparently originating in the body of the uterus.

R. B., white, aged forty-five, married. Admitted January 24; discharged February 23, 1895. She has been married twenty-three years, but has had no children and no miscarriages. Eighteen years ago, when suffering from uterine

hemorrhages, the patient was told that she had a tumor, and eight years ago noticed what seemed to be a tumor protruding from the vulva. She was relieved somewhat by wearing a pessary. For the past two years, at intervals of a few days to two weeks, she has had a hemorrhage from the vagina, usually appearing as large dark clots.

Operation, January 30, 1895. Vaginal myomectomy. The patient made a satisfactory recovery.

Path. No. 582. The specimen consists of an irregular and globular mass, 10 cm. in diameter. This is coarsely lobulated, pinkish in color, and covered with numerous adhesions. At one extremity is a raw surface, 6.5 x 5 cm. This corresponds to the pedicle. The tumor is firm and non-yielding; on section it is whitish pink in color, and consists of concentrically arranged striae.

Histologic Examination.—The outer surface of the tumor is covered with several layers of cells, from nearly all of which the nuclei have disappeared. There is no evidence of mucosa. The tumor is composed of non-striped muscle-fibers cut both longitudinally and transversely, and the tissue shows much hyaline degeneration. These degenerated areas are scattered irregularly throughout the muscle, and in such places a few isolated muscle-fibers are still visible. The tissue just beneath the outer surface has a rich blood-supply. At one point, where one lobulation joins another, the muscle-cells are markedly altered. Some of their nuclei are normal in size, others are four times as large as usual and stain deeply. Some of the nuclei appear as long threads, three times the normal length, and other cells contain three or four nuclei bunched together. The picture is a very unusual one and, were only such a field in question, one might be warranted in making a diagnosis of sarcoma. But the gross appearance of this area is identical with that of an ordinary myoma, and, as seen from the description, the surrounding muscle-fibers are of the type so constant in myoma. It is possible that there is a commencing sarcomatous degeneration, but if so, it is in an exceedingly early stage.

Path. No. 3948. The specimen consists of the entire uterus. The upper part of the cervix and lower part of the body are involved in a cancerous growth which, on histologic examination, proved to be an adenocarcinoma. There is also a small interstitial myoma.

In October, 1902, the patient returned with an inoperable recurrence in the vagina.

This case is particularly interesting on account of the changes that took place in the submucous myoma, and from the fact that five years later carcinoma developed. The coincidence of these two is certainly an accidental occurrence, the one appearing independently of the other.

San. No. 577. Path. No. 2402.

An edematous subperitoneal myoma presenting histologic changes strongly suggestive of sarcoma (Figs. 163, 164, 165).

B. K., white, aged fifty, single. Admitted March 15; discharged April 19, 1898. Complaint, a constant flow for the last three months.

Operation, March 17, 1898. Hysterectomy. The patient made a satisfactory recovery.

Path. No. 2402. The specimen consists of an enlarged uterus which has been converted into a globular tumor, 12 x 11 x 11 cm. Its surface is free from adhesions. The increase in size of the uterus is due to the presence of a tumor that occupies its posterior wall. The anterior wall is of the normal thickness. The uterine cavity is 5.5 cm. long and 3 cm. broad at the fundus. The mucous membrane has an undulating surface. The tumor occupying the posterior wall

is approximately 10 cm. in diameter. At some points it presents a typical myomatous appearance, but in many places between muscle-bundles are less dense areas, presenting a homogeneous surface and entirely devoid of a myomatous arrangement. These closely resemble edematous areas. Here and there are small irregular empty spaces, so often seen where a myoma is breaking down. The most prominent portion of the specimen contains an irregular hemorrhagic area, 4 cm. in diameter. This has in part broken down, and clinging to the walls of the cavity are small blood-vessels. There is a second area of hemorrhage, but here no dissolution has taken place. In the neighborhood of the uterus the tumor has a

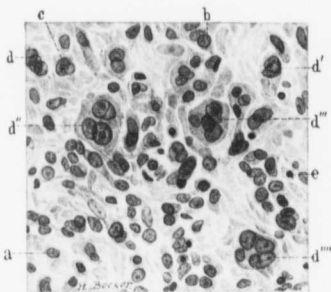


FIG. 163.—GIANT-CELLS IN AN EDEMATOUS MYOMA. ($\times 420$ diam.)

Path. No. 2402, a represents the average size of a muscle nucleus; b is a shade larger and stains a little more intensely; c shows partial subdivision; d, d', d'', d''', and d'''' depict various stages in the development of giant-cells. Note that all of the nuclei of the giant-cells, although increased in size, show little or no increase in chromatin. The tissue is sparsely infiltrated with small round cells, as indicated by e. This field, while slightly suggestive of sarcoma, is almost too quiet to make one very suspicious.

covering of muscle varying from 1 to 8 mm. in thickness. But at the point most distant from the organ the growth is practically devoid of muscular covering, and the fibers of the tumor are clearly visible. From the foregoing description it will be seen that the tumor appears to be an ordinary myoma in which some degeneration has taken place. The gross appearance in no way suggests a malignant process.

Histologic Examination.—The uterine cavity appears to be normal. Sections from the solid portion of the tumor in many places yield typical myomatous tissue. Occasionally, however, we find a nucleus five or six times the usual size, irregular in shape, and staining fairly deeply. This tissue also contains small round cells, freely interspersed between muscle-bundles, but apparently

no polymorphonuclear leukocytes. At other points the muscle-fibers have nuclei varying markedly in size. Careful scrutiny of such fields shows that some of the nuclei are small, oval, and vesicular; that others are twice the natural size, while a number are four or five times the normal size, are irregular in shape, but do not stain deeply. All gradations between the normal nuclei and the large ones are demonstrable. Occasionally we note a large mass of protoplasm staining deeply with eosin and containing four or five of these large nuclei bunched in its center (Figs. 163 and 165). At other points are long, fusiform masses of protoplasm, sharply defined from the fact that they take the eosin stain so deeply. These are sometimes twelve times as long as the normal muscle-fibers (Fig. 164). The giant fibers occasionally contain two or three somewhat enlarged nuclei, bunched in their centers. There is one cell of this character which contains three nuclei—one of the normal size, the second about three times, and a third about ten times, the usual diameter. This largest nucleus has a distinctly hyaline droplet in its center. Sections from the softened areas are still more startling. The typical arrangement of the myoma has entirely disappeared. The cells vary greatly in size, and there are many large plaques of protoplasm, varying in diameter, staining deeply, and containing anywhere from one to four or five nuclei. The more rarefied the tissue, the more abundant these giant-cells. In the areas in which the hemorrhage has taken place we find numbers of these giant-cells. No nuclear figures can be detected in the tumor.

From the foregoing description one is instantly reminded of sarcoma. At no

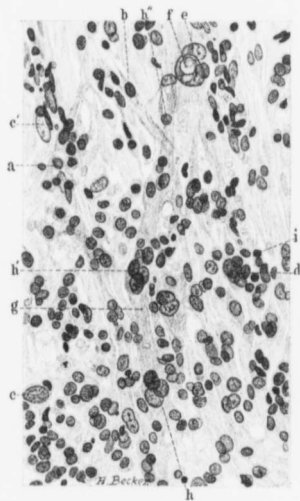


FIG. 164.—SUSPICIOUS CELL CHANGES IN AN EDEMATOUS AND PARTLY SUBPERITONEAL MYOMA. ($\times 350$ diam.)

Path. No. 2402, a shows the average size of the muscle nuclei on cross-section. At *h* we have a spindle-shaped cell cut longitudinally. *c* represents one of several large nuclei. *e'* is also a large nucleus, but its chromatin is diminished instead of being augmented. The nuclei tend to form clumps at *d*. At *e* the nuclei are much larger, and the same tendency toward clumping is noted. Here the largest nucleus contains the hyaline droplet *f*. *g* is the protoplasm of a cell that can be traced nearly the entire length of the field. Near its lower portion it contains the clump of nuclei (*h*). At its middle is a group of nuclei (*h'*), and in the upper portion a small nucleus (*h''*). There is some small round-celled infiltration, as indicated by *i*.

The presence of the gigantic cell *g*, with its clumps of nuclei, together with the large nuclei scattered throughout the field, make one mindful of sarcoma. The knowledge, however, that we are dealing with an edematous myoma should deter us from making a positive diagnosis of malignancy. See Figs. 163 and 165 for sections from the same myoma.

point, however, do we find typical sarcomatous tissue, nor do we find a very marked tendency to an increase in amount of nuclear chromatin. Furthermore, it will be noticed that the most pronounced changes are found in the rarefied areas. At no point in the gross specimen were we able to detect a solid and circumscribed homogeneous area, so characteristic of sarcoma. It is impossible to render a positive diagnosis, but the probability is that no sarcoma is present. From a clinical standpoint, however, should we find tissue of such a character in a myoma, it is incumbent on the pathologist to advise immediate and complete removal of the uterus.

November 27, 1902, four years and a half after the operation, the patient writes that she is in good health.

Gyn. No. 5635. Path. No. 1973.

October, 1897. The specimen consists of a small myoma from the right horn. This measures 5 x 4 x 2 cm. On histologic examination it presents the typical myomatous picture. It contains one suspicious area, as depicted in Fig. 166.



FIG. 165.—GIANT-CELLS FROM AN EDEMATOUS MYOMA. (X 320 diam.)

A. Path. No. 2402. The nuclei are, on the whole, more oval than spindle-shaped, but are of the usual size. *a* is a very large mass of protoplasm containing four nuclei of various sizes.

B. *a* is a very large irregular plaque of protoplasm surrounded by nuclei of muscle-fibers. It contains five grossly sized nuclei and several smaller ones (*b*). Their chromatin is slightly increased; *c* is a small round cell.

These two giant-cells are somewhat suspicious of sarcomatous changes, and should stimulate further examination of the tumor.

Gyn. Nos. 5496 and 5907. Path. Nos. 1899 and 2222.

“Recurrent fibroid” with histologic appearance strongly suggestive of sarcoma (Fig. 167).

M. D., white, married, aged thirty-eight. Admitted September 3; discharged September 30, 1897. The patient has been married fourteen years; she has had no children, but two miscarriages. The menses began at thirteen and were regular until six months ago, when the flow became scant. Three months ago she had a hemorrhage, and since then has had frequent bleeding. For three years there has been a thick, offensive leukorrhœal discharge, and for the past three months constant pain in the lower abdomen. During this time she has become very weak.

Operation, September 4, 1897. Vaginal myomectomy. A large, cauliflower-like myoma projected into the vagina. It was about 10 cm. in diameter, very

friable, and bled profusely. The uterine cavity was packed. Her temperature on admission was 101.5° F. After operation it rose to 103.6°, and on the third day gradually fell to normal. The patient rapidly gained flesh and strength and was discharged feeling well.

Path. No. 1899. The specimen consists of numerous fragments of tissue from the uterine cavity.

Histologic Examination.—The tissue has to a great extent undergone degeneration, but at some points, especially around the blood-vessels, the cells are still preserved. They are spindle-shaped, closely packed together, and form

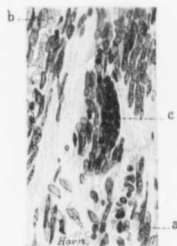

FIG. 166.—A LARGE NUCLEUS IN A MYOMA. ($\times 320$ diam.)

Path. No. 1973. *a* represents the average size of the nuclei. At *b* is a nucleus somewhat enlarged. *c* is a much elongated, oval-shaped giant-cell containing more than twenty nuclei, which stain more deeply than those in the surrounding tissues. Apart from the one giant-cell, nothing unusual was noted in the myoma, and this large cell alone would scarcely suggest a malignant change.

whorls or run in various directions. The picture instantly reminds one of myomatous tissue. At some distance from the vessels the tissue is found to show marked hyaline degeneration.

Other portions of the tumor have undergone complete necrosis, not a nucleus being visible. Here and there a few large, suspicious-looking muscle-fibers are seen (Fig. 167). Where the necrosis has taken place, the blood-vessels are exceedingly numerous and are much dilated. Some of them contain thrombi.

Gyn. No. 5907. The patient was readmitted on March 2, 1898, and discharged on March 30, 1898.

In November, 1897, about two months after her operation at the hospital, a sloughing submucous myoma was removed by her family physician. For two months she was relieved, but then commenced to lose flesh and had chills and

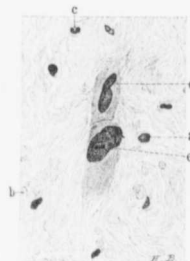


FIG. 167.—SUSPICIOUS CELL CHANGES IN A SLOUGHING SUBMUCOUS MYOMA. ($\times 315$ diam.)

Path. No. 1899. The nuclei are few and far between, much of the tissue having undergone hyaline change. *a* represents the average size of the nuclei of the muscle-fibers. At *b* are a few red corpuscles; at *c* a polymorphonuclear leukocyte. *d* is a large plaque of protoplasm containing two enlarged nuclei, overlapping one another. *e* is also a mass of protoplasm containing two very large and deeply staining nuclei. Below this cell is another clump of protoplasm devoid of nuclei.

The two large cells, *d* and *e*, make one very suspicious of malignancy, and further tissues should be examined. Such pictures are occasionally found in edematous myomata. From this field alone one would not be justified in saying that the growth is malignant.

fever. For the past two weeks she has had pain and tenderness in the lower left abdomen.

Operation, March 4, 1898. Vaginal myomectomy. A pedunculated sloughing submucous myoma, 9 cm. in diameter, was removed from the vagina. There was a considerable degree of inversion of the uterus. Her temperature after the operation reached 103.4°, but after the fifth day gradually dropped to normal, and she was discharged, feeling well.

Path. No. 2222. The specimen consists of many pieces of tissue, the largest 5 cm. in diameter. It is very firm, and on section is yellowish white in color, and apparently consists of bands of fibrous tissue running in all directions. Other portions show marked dilatation of the blood-vessels. Many of these are surrounded by a zone of hemorrhage, and some portions of the tumor are hemorrhagic throughout. Along the edges of some of the pieces the tissue is very friable, looks necrotic, and has an exceedingly offensive odor.

Histologic Examination.—The solid portion is composed of bunches of cells cut longitudinally and transversely. The nuclei are oval, elongate-oval, or in some places spindle-shaped. They are fairly uniform in size, and take the stain evenly. Occasionally a nucleus is two or three times as large as an adjoining one, and now and then one sees a large mass of chromatin, somewhat granular and apparently divided up into several smaller nuclei. The tissue bears much resemblance to a myoma, but the connective tissue is conspicuous by its absence. The blood-vessels are fairly abundant. In other sections in which the tissue was softer the same spindle-shaped cells are present, but are to a great extent separated from one another by blood-corpuscles. Scattered throughout the hyaline tissue are polymorphonuclear leukocytes. The surface of the offensive portions is composed almost entirely of leukocytes. From the macroscopic examination one would naturally make a diagnosis of suppurating myoma, but the presence of the few large cells noted histologically, and the fact that there is little connective tissue, make the presence of sarcoma quite probable. From a histologic standpoint it is not advisable to make a positive diagnosis. One must be guided entirely by the clinical history.

November 14, 1902, the patient writes that she has been perfectly well since the last operation, and that her weight, which was formerly 90 pounds, is now 143 pounds. It is over four and a half years since the last operation.

Gyn. No. 3461. Path. No. 682.

Submucous, interstitial, and subperitoneal myomata. Subperitoneal myoma showing marked vascularity and apparently undergoing sarcomatous transformation.

M. C., white, aged forty-nine, married. Admitted April 23; discharged May 18, 1895. The patient has had no children and no miscarriages. One year ago she had a severe attack of pain in the lower abdomen, and now has constant

pain, worse on the left side, and extending down to the limbs and back. The abdomen is somewhat tender; micturition is frequent and painful. Defecation is painful.

Operation, May 24, 1895. Hysteromyectomy and herniotomy for incarcerated femoral hernia. The patient made a satisfactory recovery.

Path. No. 682. The specimen comprises the uterus and a large myoma springing from its left side. The appendages are also present. The uterus is somewhat irregular in outline, and measures 9 x 6 x 6 cm. It is smooth and glistening, but springing from its anterior wall is a pedunculated nodule, 1 cm. in diameter, and a sessile nodule, 2 cm. in diameter. A small nodule projects from the fundus. All these are firm and non-yielding. Situated in the fundus is an interstitial nodule, 4 cm. in diameter. This is yellowish-white in color, and presents a striated appearance; it is firm and non-yielding. The uterine cavity is 4 cm. in length. Its mucosa is grayish-white in color and presents a slightly granular appearance. That covering the anterior wall contains small cysts. Springing from the middle of the left side of the uterus is a globular tumor, 12 x 11 x 10 cm. This is connected with the uterus by a round pedicle, 4.5 cm. in diameter, 4.5 cm. in length. It is bluish-white in color, and contains many superficial vessels which spring from the uterus and ramify over the tumor. Over its upper portion the tumor is bright red, but in the dependent portions bluish red. It is everywhere covered with peritoneum, is soft and somewhat yielding, and where pressure is exerted, the tissue becomes blanched, but is very vascular. The appendages are normal.

Histologic Examination.—The uterine mucosa is, on the whole, normal. Projecting into the uterine cavity is a polyp consisting of mucosa. The sub-mucous myoma is composed of non-striated muscle-fibers cut longitudinally and transversely. They are closely packed together, and stain much more deeply than do those of the uterine muscle. The myoma is intimately connected with the uterine muscle. Sections through the pedicle of the tumor springing from the left side show that it is quite vascular. The tumor is composed of non-striated muscle-fibers which are markedly separated from one another, the entire tissue appearing to be edematous. Many of the muscle-fibers are normal, but numerous unusual forms are seen. Here and there are spindle-shaped cells at least five times the usual length and four times the normal breadth. These contain five or six oval nuclei, which stain more deeply than those near them. In other places four or five nuclei are joined end to end. One is immediately reminded of sarcomatous transformation of the muscle-fibers. Such cells are found sparsely scattered throughout the tumor, but they are most abundant near the peritoneal surface. Toward the center of the tumor are homogeneous areas which stain pink with eosin, and sprinkled throughout these areas are a few muscle-fibers. It looks as if the tissue were becoming liquefied. The outer portions of the tumor are exceedingly vascular, both the arteries and veins being very abundant, and it is in the vicinity of these blood-vessels that the

atypical cells are most numerous. The vessels are so numerous that the tumor might be justly called an angioma.

We must consider the tumor primarily as a myoma which has such a rich blood-supply that it might be called an angiomyoma. Secondly, from the atypical cells we must strongly suspect sarcoma or, to say the least, an exceedingly rapidly growing myoma.

November 13, 1902, the patient writes that she is not feeling very well, but her description of her condition is not definite. The length of time since operation—seven and a half years—demonstrates clearly that even if, by any chance, the process was malignant, the sarcoma had been completely removed.

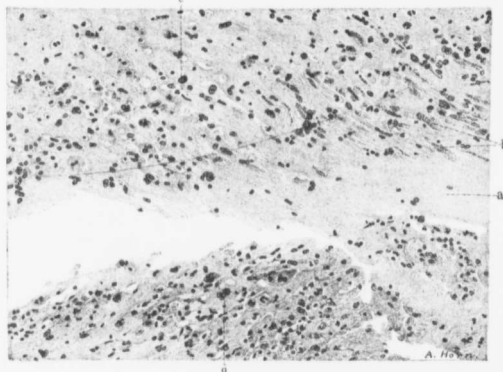


FIG. 168.—CELL CHANGES IN A MYOMA UNDERGOING PARTIAL COAGULATION NECROSIS. (X 130 diam.)

Path. No. 2372. The section is from the neighborhood of an area which has undergone coagulation necrosis. The area indicated by (a) consists of hyaline myomatous tissue. Many of the nuclei, as shown at b, have lost their outlines and consist merely of fine granular chromatin. At c is a nucleus slightly enlarged and staining deeply, and at several points we have small aggregations of nuclei tending to form giant-cells. This is well seen at d. Scattered throughout the field are many small round cells and a moderate number of polymorphonuclear leukocytes. Such an infiltration is very common in the tissue surrounding an area of coagulation necrosis. The giant-cells impress one as being the result of a breaking up of the cells, with the subsequent coalescence of the surviving nuclei. Although at first sight the cell changes suggest to a slight degree sarcoma, a careful analysis of the cells clearly shows that there is no evidence of malignancy.

San. No. 581. Path. No. 2372.

Degenerative change in a myoma that might be mistaken for sarcoma (Fig. 168).

M. Operation March 22, 1898. Myomectomy. The specimen consists of five myomata. The largest is lobulated, and measures 9 x 8 x 7 cm. The others are much smaller. The large nodule is very friable, tears easily, and shows marked degeneration.

Histologic Examination.—Sections from the undegenerated portion of the

nodule present the usual myomatous picture. The greater part of the tumor consists of hyaline material, but separating this from the outer and still well-preserved tissue is a zone of coagulation necrosis, for the most part consisting of granular material that stains with eosin, and of nuclear detritus. Scattered throughout the outer portion of the necrotic zone are cells containing deeply staining nuclei of various sizes (Fig. 168). Many of the cells contain several such nuclei. One gathers the impression that such pictures are due to the fact that adjoining cells have fused with one another.

Gyn. Nos. 6407 and 12139. Path. No. 8750.

Large multinodular myomatous uterus with general pelvic adhesions; marked hyaline degeneration of the myoma, presenting a picture at first suggestive of sarcoma, but on further examination bearing no definite resemblance to such a condition.

M. R., colored, aged forty-two, single. Admitted May 20; discharged June 17, 1905. The patient was in the hospital (Gyn. No. 6407) in October, 1898, with a right pyosalpinx and an encysted peritonitis, which was opened through the vaginal vault and drained. One month after leaving the hospital she had an attack of pain which commenced in the lower abdomen and extended down the thighs. Since then she has had four more definite attacks of severe pain.

Operation, May 27, 1905. Hysteromyomectomy and appendectomy. On opening the abdomen the omentum was found everywhere adherent to the pelvic organs. It was tucked down behind the uterus and adnexa to the bottom of the cul-de-sac. After releasing the omentum we found that we were dealing with a large multinodular myomatous uterus. On the right side there was a chronic salpingitis. The tube and ovary were plastered down to the back of the broad ligament. On the left side there was an adherent ovarian cyst, 6 cm. in diameter. A supravaginal amputation was performed, and the patient made a very satisfactory recovery.

Path. No. 8750. The specimen consists of a lobulated myomatous uterus to which the omentum is densely adherent. The uterus with its nodule is 10 cm. in length, 12 cm. in breadth, and 8 cm. in its anteroposterior diameter. Projecting from the surface are pedunculated and sessile myomata, the largest reaching 5 cm. in diameter. Covering the surface, and intimately blended with the myomata, is the omentum. Scattered throughout the uterine walls are smaller myomata, some of them submucous. Attached to one side is a cystic mass, 7 cm. in diameter, also covered by adhesions. It appears to be composed of the tube and ovary, but the exact relations are difficult to establish.

Histologic Examination.—Sections from the myomata show hyaline tissue with deep patches scattered throughout it. At first sight it reminds one of a malignant growth, but on careful study we find deeply staining bunches of

muscle-fibers lying in the hyaline tissue. In fact, we have a most typical example of diffuse hyaline transformation of a myoma. Sections from the endometrium show that the surface is covered with polymorphonuclear leukocytes, that the surface epithelium is flattened, and that the underlying stroma shows a great deal of small-round-celled infiltration. We have here a chronic inflammation of the cervix with dilatation of the capillaries. One of the tubes shows a typical follicular hydrosalpinx.

Gyn. No. 11949. Path. No. 8351.

A large interstitial myoma showing cell changes strongly suggestive of sarcomatous transformation.

M. S. K., white, aged thirty-nine, married. Admitted March 8, 1905; discharged six weeks later. The menses have always been regular.

Operation. Hysteromyectomy, double salpingectomy, right oöphorectomy. The uterus is considerably enlarged, owing to the presence of a large myoma that springs from its posterior surface. The rectum is adherent to the posterior surface of the uterus near the cervix. It is easily freed. Hysterec-tomy was performed without any difficulty. The patient made a very satisfactory recovery. The highest postoperative temperature was 100° F.

Path. No. 8351. The specimen consists of the uterus, the right tube and ovary, and the left tube. The uterus is approximately 21 cm. from before backward, 17 cm. in length, and 12 cm. in breadth. The great increase in size is due to the presence of a myoma, 15 x 11 cm., situated in the posterior wall. The anterior uterine wall varies from 1.5 to 2.5 cm. in thickness. It shows diffuse myomatous thickening. The uterine cavity is 5 cm. in length. The mucosa in the thicker portions reaches 5 mm. in thickness. The appendages show nothing of interest.

Histologic examination shows that some of the cervical glands are enlarged, but otherwise are normal. The surface epithelium is intact. The glands are more convoluted than usual; they show a slight tendency toward hypertrophy, and here and there can be traced for some distance into the muscle. Sections from the myoma show diffuse hyaline degeneration. In some places, however, the nuclei are five or six times the natural size; they are irregular and stain deeply. At one point we may have two or three nuclei bunched together, while at other places the nuclei are of the usual type, and about twice the natural length and breadth, and stain deeply. In a few areas the cells seem to have a very wild look; in other words, they are more active than usual. In others the nuclei are twice the normal length and three times the normal breadth, and appear irregular. In some places the nuclei are irregularly triangular, stain deeply, and are fully four or five times larger than those that surround them.

In this case we have an atypical myomatous growth. The cell changes are most suspicious of a commencing sarcoma developing from the muscle. Were it possible clinically to remove a section of a myoma without taking out the entire

growth, and had we found such suspicious changes, we would certainly have advised immediate removal of the uterus in its entirety. In this case, of course, the uterus with the myoma has been removed, and if the growth is actually commencing sarcoma, we have in all probability eliminated the process, as it seems too early for metastases.

San. No. 1973. Path. No. 9129.

Subperitoneal and interstitial uterine myomata, suspicious alterations in the muscle-fibers of the myoma strongly suggesting sarcomatous transformation.

E. H. S., white, aged twenty-nine, married. Admitted October 17; discharged December 1, 1905. The patient has had no children and no miscarriages. She is a frail woman; the hemoglobin is 75 per cent.

Operation. Supravaginal hysteromyomectomy. The highest temperature was 100.4° F. Recovery was uninterrupted.

Path. No. 9129. The specimen consists of an enlarged uterus, with the tubes and ovaries attached. The uterus, which is multinodular, is 15 cm. in length, 11 cm. from side to side, 12 cm. in its anteroposterior diameter. It is riddled with nodules, subperitoneal, interstitial, and submucous. The uterine mucosa varies from 2 to 6 mm. in thickness. The appendages are normal. On section, the largest myoma shows a moderate amount of disintegration.

Histologic Examination.—Sections from the endometrium show that the mucosa is greatly thickened. The glands themselves are perfectly normal, although they show a slight tendency toward hypertrophy. The superficial portions of the mucosa show marked edema. Sections from the large myoma show marked hyaline degeneration and considerable liquefaction. Here and there throughout the liquefied areas are deeply staining nuclei and nuclei two or three times the natural size. On examination of further sections we note the appearance of unrest in the myomatous tissue. On careful examination of the muscle-cells the majority are found to be swollen endothelial cells of the capillaries, which stain rather deeply. There are, however, nuclei that are twice the natural size and stain intensely. Then, here and there, are bunches of two or three nuclei, also staining rather deeply, and masses of protoplasm containing six or seven nuclei in a row. The picture is, on the whole, rather suspicious, but the cell alterations are not sufficiently marked to enable us to say positively that there is any malignant change. Furthermore, at no point do we find evidence of nuclear division. We should be inclined to look upon this as a benign myoma, but from a clinical standpoint would advise removal of the uterus. The appearance in this case is another link in the chain that suggests to us most strongly the rôle apparently played by hyaline transformation and liquefaction in a sarcoma developing in a myoma. The muscle-fibers are separated from each other and are loosened up, these changes affording them an increased chance of undergoing further development, in other words, of becoming larger.

Gyn. No. 12297. Path. No. 8887.

Suspicious histologic changes in a subperitoneal myoma which has been shelled out of the uterus.

V. McC., white, aged thirty-two, married. The patient's menstrual periods have been perfectly regular, and she has had eleven children, but no miscarriages. Urination has been increased in frequency for the last four months. About two months ago she noticed some abdominal enlargement, but has had no marked discomfort, except pain in the lower abdomen at night. There has been slight fever, but no nausea or vomiting.

Operation. Myomectomy and appendectomy. There were five myomata; the large one was pedunculated; all were removed without difficulty. The patient made a very satisfactory recovery.

Path. No. 8887. The specimen consists of five myomata, the largest 15 x 9 x 6 cm. It is markedly lobulated, but is smooth and glistening. At one point there is a raw area, 4 x 2.5 cm., corresponding to the uterine attachment. On section, this myoma, over an area 3 cm. in diameter, presents a dark-mottled appearance. There is considerable softening; in fact, the tissue is porous-like. This shows how difficult it is to tell at operation whether or not the myoma is undergoing degeneration, although in this case the area of degeneration reaches to within 2 mm. of the surface. In a very short time the omentum would have become adherent, and before long the uterine attachment would have been very small. The other nodules are quite small, the largest one being 2.5 cm. in diameter; they offer nothing of interest.

Histologic Examination.—Certain portions of the large tumor show distinct hyaline degeneration. There are also areas of coagulation necrosis, with here and there quite a number of polymorphonuclear leukocytes. Some areas of the myomatous muscle are strikingly well preserved, considering the degeneration. There is no definite clue as to any marked sarcomatous changes, but one gets the general impression that there is a slight tendency toward malignancy.

C. H. I. No. 686. Path. No. 8829.

Interstitial and submucous uterine myomata; submucous myoma undergoing hyaline changes and disintegration, and presenting a picture that might readily be mistaken for sarcoma.

R. W., white, aged forty-two, married. Admitted July 3; discharged July 30, 1905.

Operation, abdominal hysterectomy and appendectomy. The patient made an uninterrupted recovery. Her highest postoperative temperature was 101.4° F., twenty-four hours after operation.

Path. No. 8829. The specimen consists of a myomatous uterus and of the appendix. The uterus is 16 cm. broad, 12 cm. in length, and 16 cm. in its antero-posterior diameter. The increase in size is due to the presence of a myoma, 8 cm.

in diameter, occupying the posterior wall, and also of numerous smaller nodules. The uterine cavity is distorted by a myoma which projects into it and completely fills it. The mucosa covering this myoma varies from 2 to 3 mm. in thickness.

Histol. Examination.—In sections from the endometrium the cervical glands are somewhat dilated. The epithelium lining the body of the uterus is intact, the glands are normal, and show some tendency to extend into the depth.

The myoma projecting into the uterine cavity shows a great deal of hyaline degeneration, especially in its superficial portion, and the degeneration is of such a character that one might readily mistake the remaining fibers for an infiltration by a new-growth. Portions of the myoma have undergone complete coagulation necrosis. In the suspicious areas there is a great deal of fibrous tissue, and then swollen islands of muscle-fibers which stand out sharply in the tissue and give a suspicious appearance. The changes are due entirely to hyaline degeneration and disintegration, and we do not for a moment think that there is any sarcoma.

CHAPTER XV.

CARCINOMA OF THE CERVIX ASSOCIATED WITH UTERINE MYOMATA.

Myomatous growths supply about one-eighth of the pathologic conditions in gynecologic work, and carcinoma of the cervix is by no means rare. Hence it is perfectly natural that the two conditions should occasionally be met with in the same individual. In discussing the association of the two diseases, it is not our intention to include the cases in which only very small myomata existed, but chiefly those in which the presence of the myomata* caused a material increase in the size of the uterus.

In "Adenomyoma of the Uterus" (p. 206) six cases of squamous-celled carcinoma of the cervix associated with adenomyoma of the body are described. In Chapter XXIII two autopsies on patients suffering from carcinoma of the cervix and uterine myomata are given in detail.

In addition to these 8 cases, we have had 10 others—making 18 in all—in which the myomatous uterus was also the seat of carcinoma of the cervix.

In Case 4607, in which the carcinoma of the cervix was well marked (Fig. 170, p. 265), there was a submucous myoma 4 cm. in diameter.

The uterus in Case 1135 was densely adherent and contained a myoma 5 cm. in diameter. A carcinoma of the cervix had extended to both broad ligaments.

In Case 7086 the uterus was the seat of far-advanced carcinoma of the cervix, and the fundus contained an interstitial myoma 5 cm. in diameter. A successful abdominal hysterectomy was performed.

In Case 9004 the cervix was occupied by a fungating carcinomatous mass. The body of the uterus, owing to the presence of myomata, was four times its natural size. It was densely adherent. A successful panhysterectomy was performed.

In Gyn. No. 11293 a hard, movable myoma, the size of a child's head, rose from the pelvis and extended almost to the umbilicus. The cervix had been replaced by a friable growth which involved the vagina on all sides and extended to the broad ligaments. The disease was too far advanced to warrant operative interference.

In Case 7819 (Fig. 171, p. 268) the cervix was occupied by a far-advanced carcinomatous tumor. The uterus contained an interstitial and partly submucous myoma, nearly 5 cm. in diameter. Its outer surface had undergone

* In Cases 5498, 6062, 7428, 7564, 7840, 12313, 12610, in which carcinoma of the cervix was found, myomata varying from the size of a pea to that of a walnut were also present. In these cases the myomata were too small to have much clinical significance.

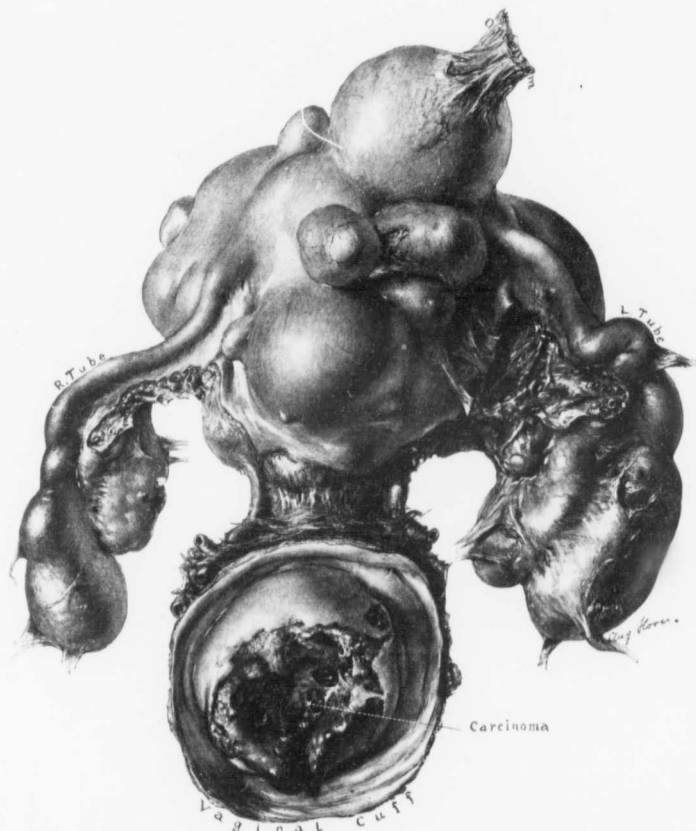


FIG. 169.—SQUAMOUS-CELLED CARCINOMA OF THE CERVIX; SUBPERITONEAL AND INTERSTITIAL MYOMATA; DOUBLE PYOSALPINX; CYST OF LEFT OVARY. (1 diam.)

GYN. NO. 13056. PATH. NO. 10077. The patient was colored, aged forty-three, and had never been pregnant. Abdominal hysterectomy was performed. She made a satisfactory recovery.

The cervix is encircled by a typical carcinomatous growth, and surrounding it is a cuff of vaginal mucosa. The body of the uterus is studded with myomata, the largest of which is 6 x 7 cm. Attached to one of the nodules is an omental adhesion which carries several vessels to the tumor. Both Fallopian tubes are filled with pus, and the left ovary contains a small cyst.

complete calcification, the calcareous material forming a mantle averaging 1 to 2 mm. in thickness.

In the following cases only the salient features are detailed.

Gyn. No. 1135.

Carcinoma of the cervix, myoma in the body of the uterus.

H. W., white, married, aged forty-seven. Admitted December 18, 1891; discharged January 20, 1892. The patient has been married twenty-four years and has had four children. The menses commenced at thirteen, were regular, lasting three days, and accompanied by some pain. She has had quite a profuse leukorrhœa for one year.

On vaginal examination the outlet was found to be relaxed; the cervix was the seat of a carcinomatous growth. There was induration in both broad ligaments.

Operation, December, 13, 1891. Vaginal hysteromyomectomy.

A myoma, 5 cm. in diameter, was found in the body. Considerable difficulty was experienced in removing the uterus on account of dense adhesions. The temperature rose to 100.3° F. on the first and second days, after which it fell to normal. The patient was discharged apparently well. Later, however, she had a recurrence, and died in February, 1893.

Gyn. No. 7086. Path. Nos. 3373 and 3390.

Squamous-celled carcinoma of the cervix; interstitial myoma of the body of the uterus.

C. H., white, married, aged sixty. Admitted July 20; discharged August 31, 1899. The patient has had three children. The menopause occurred at forty-nine. For six months the patient has had a bloody discharge, moderate in amount, occurring every few days. On other examination the outlet is found to be decidedly relaxed. The vagina is lined with a dark necrotic looking, foul-smelling material. From the cervix projects a mushroom-like growth, which is dark brown, mottled in appearance, and somewhat necrotic. It breaks down readily under the examining finger.

The cervical growth was first everted away on August 31, 1899, and a pan-hysterectomy with enucleation of the glands was done. The disease extended on the left side out into the broad ligament. The patient made a very satisfactory recovery.

Path. No. 3373. Examination of the tissue removed from the cervix shows that it is a typical squamous-celled carcinoma.

Path. No. 3390. The specimen consists of the uterus, tubes, ovaries, and several lymph-glands. The uterus is 11 x 6 x 6 cm. The cervix is dense and brawny, and to the touch feels like a hard, twisted rope. The os presents a funnel-shaped depression, which implicates the entire cervix. The fundus is

irregular and globular in form, and on section an interstitial myoma, 5 cm. in diameter, is found, which has distorted the uterine cavity considerably. The uterine cavity is approximately 7 cm. in length; at the fundus, 3 cm. in breadth. The lymph-glands removed show no microscopic evidence of carcinoma.

Gyn. No. 4607. Path. No. 1304.

Early squamous-celled carcinoma of the cervix and submucous myoma of the body of the uterus (Fig. 170).

L. D., married, white, aged forty-five. Admitted August 29; died Sep-

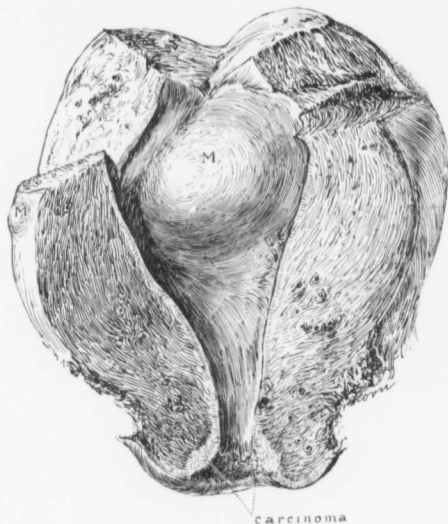


FIG. 170.—SQUAMOUS-CELLED CARCINOMA OF THE CERVIX AND SUBMUCOUS MYOMA OF THE BODY OF THE UTERUS.
($\frac{1}{2}$ nat. size.)

Gyn. No. 4607. The cervix is the seat of an early carcinoma, which might have been readily overlooked at operation. Projecting into the uterine cavity is a myoma, 4 cm. in diameter; a submucous myoma is indicated by *m*.

tember 1, 1896. The patient has been married twenty-one years, and has had six children and one miscarriage. The menses were regular until the last two years. Since then they have been profuse, almost continuous, and offensive in odor. About a year and a half ago she had an attack of appendicitis.

Operation, August 31, 1896, Panhysterectomy. Vaginal* hysterectomy was exceedingly difficult on account of the hip-joint disease from which the patient was suffering. At the end of the operation the patient's pulse could scarcely be felt. There had been considerable loss of blood during the operation. She never rallied, and died twelve hours later.

Path. No. 1304. The specimen consists of the uterus with its left appendages intact. The uterus is 10 cm. long, 8 cm. broad, and 8 cm. in its anteroposterior diameter (Fig. 170). Its surface is covered with dense vascular adhesions. On the anterior surface is a small myoma, 7 mm. in diameter. The cervix is 3 cm. in diameter, and is exceedingly firm and resistant. The posterior cervical lip is somewhat everted. The vaginal portion is smooth, but the cervical portion presents a roughened and granular surface. The anterior lip has an ulcerated area in its left side, from the floor of which stand out many delicate papillary projections. The uterine cavity is 5.5 x 4.5 cm. Projecting into the cavity is a submucous myoma, 4 cm. in diameter. Over this the mucosa is markedly atrophied. Microscopically, sections from the cervix show the typical picture of squamous-celled carcinoma. The uterine mucosa over the submucous myoma is much thinned out, but is otherwise normal.

Gyn. No. 9004. Path. Nos. 5176 and 5223.

Squamous-celled carcinoma of the cervix; myomata of the body of the uterus; pelvic adhesions.

M. W., aged forty-nine, black. Admitted August 22; discharged October 15, 1901. Complaint, uterine hemorrhages. The menses began at fourteen and were perfectly regular, lasting from five to six days, until thirteen months ago. Since then the patient has had a slight continuous bleeding practically every day. Occasionally the discharge is rather free and contains numerous clots. On two occasions she has had a sudden sharp hemorrhage, losing a pint or more. She has had three children, the youngest nine years of age. Recently the patient has lost from fifty to sixty pounds. For two weeks she has been so weak that she has been unable to do any work. She is very anemic; the hemoglobin is 34 per cent. On vaginal examination the cervix is nodular and hard, one of the nodules being fully 3 cm. in diameter. The uterus is in the midline, the size of that of a four months' pregnancy, and very adherent.

Operation. The cervix was first curetted. Several days later a vaginal hysterectomy was performed. The patient rapidly recovered, and left the hospital in good condition.

Path. No. 5176. The growth is a squamous-celled carcinoma of the cervix.

Gyn. No. 11293.

Carcinoma of the cervix; large myoma of the body of the uterus.

* Vaginal hysterectomy for carcinoma is now never employed by us when the abdominal route can be adopted.

L. D., colored, aged fifty-five, married. Admitted May 17; discharged May 27, 1904. The patient has had four children, the youngest thirty years of age. The menopause occurred at forty. For the past three months the patient has noticed a profuse discharge from the vagina. This at first was whitish in color, but lately has become bloody and foul-smelling. During the past two months she has complained of a dull aching pain in the lower abdomen, more pronounced in the left side. This has gradually increased in severity. The bowels have been constipated. The abdomen is very lax, and extending up from the pelvis to the umbilicus is a hard, movable tumor mass as large as a child's head. The cervix has been replaced by a friable growth, which involves the vagina on all sides and extends out into both broad ligaments. Filling the pelvis is a large multinodular mass which was detected through the abdomen. The disease was too far advanced to warrant operation.

Gyn. No. 7819. Path. No. 4074.

Squamous-celled carcinoma of the cervix; sub-peritoneal and interstitial uterine myomata; sub-acute salpingitis and peri-oöphoritis (Fig. 171).

S. B., white, aged forty, married. Admitted May 15; discharged June 12, 1900. Her father died of cancer of the throat; otherwise the family history is unimportant. The patient has been married twenty years and has had two children, the youngest seventeen. The labors were normal. Several weeks ago she noticed a slight reddish discharge and complained of sharp pain in the lower part of the abdomen. This pain has now become localized on the right side. The attack was accompanied by nausea and vomiting and a feeling of faintness. The discharge has gradually increased in quantity up to the present time, and has assumed a sanguino-purulent character. The patient is pale and poorly nourished. Hemoglobin, 35 per cent.

Operation, May 17, 1900. Panhysterectomy. The patient made a fairly satisfactory recovery, and was discharged June 12, 1900.

Path. No. 4074. The specimen consists of the uterus, tubes, and ovaries. The uterus measures 12 x 8 x 8 cm. The posterior surface is covered with adhesions, and on the anterior surface is a very small myoma. Posteriorly, the uterus presents a large rounded boss, very hard, which on section proves to be an interstitial myoma 6 cm. in diameter (Fig. 171). The peripheral portion has undergone calcification, and the center shows coagulation necrosis. The cervix is also enlarged and resistant; it feels nodular, and is approximately 6 cm. in diameter. The vaginal portion on the right side is irregular in outline, but is covered with smooth mucosa. The cervix to the left side presents a large, crater-like area, 3 to 5 cm. in diameter, and about 3 cm. in depth. The base of this presents a roughened, granular surface, with here and there masses of delicate, friable-looking papillae. It is, for the most part, surrounded by a band of smooth vaginal mucosa, but at one point, for a distance of 1 cm., the growth apparently

extends to the cut margin. The cervical canal is 3 cm. long, and posteriorly is lined with smooth mucosa. Anteriorly, however, the walls are composed of a new-growth, and the entire inner surface is ulcerated. The cervical walls average 1.5 cm. in thickness, and are penetrated by the growth to within less than 1 mm. of the outer surface. The cut surface of the growth consists of a yellowish-white, granular material, traversed by delicate fibrous bands. The growth has extended to the internal os. The uterine mucosa is injected, but

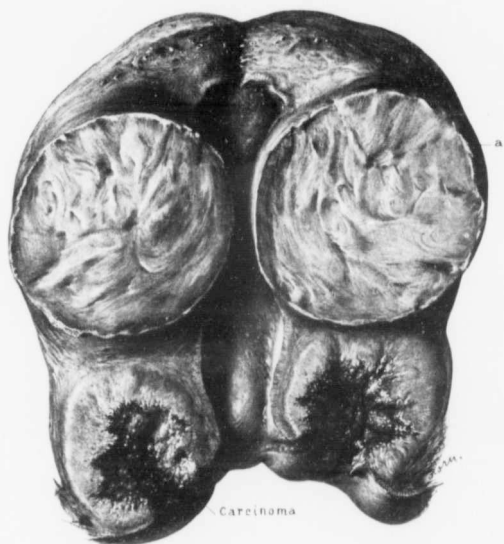


FIG. 171.—SQUAMOUS-CELLED CARCINOMA OF THE CERVIX; PARTIALLY CALCIFIED INTERSTITIAL MYOMA IN THE BODY OF THE UTERUS. (½ nat. size.)

Gyn. No. 7819. Path. No. 4074. The cervical growth is far advanced, and has extended almost to the cut surface. The interstitial and partially submucous myoma is surrounded by a calcareous mantle (a), easily recognized by its white, jagged contour.

otherwise normal. On the right side the tube and ovary are bound together by adhesions. On the left side the appendages are also covered with dense adhesions.

Microscopically, the growth proves to be a squamous-celled carcinoma of the cervix.

In the above cases the diagnosis of carcinoma was perfectly clear on digital examination, but if the physician had known that myomata had existed for a

long time, he might readily have supposed that the hemorrhage and offensive discharge came from one of the nodules that had become submucous and was sloughing. In all myoma cases in which no operation is deemed necessary it is advisable to make a vaginal examination from time to time to determine if, by any chance, a carcinoma of the cervix is developing.

CASES OF EARLY CARCINOMA OF THE CERVIX ASSOCIATED WITH MYOMATA.

In such cases the malignant growth of the cervix might readily be overlooked. Case 12725 affords a striking example of such a condition. The external os was slightly patulous. The surface of the cervix was a little roughened, but "not suggestive of malignancy." The body of the uterus was somewhat enlarged, and slightly irregular in outline. Vaginal hysterectomy was performed. An interstitial myoma, 3 x 3 x 2 cm., was found in the fundus. On removal, the cervix macroscopically looked normal, but was slightly indurated.

On histologic examination we found the seat of the earliest squamous-celled carcinoma we have ever encountered. Had an abdominal supravaginal hysterectomy been done instead of total vaginal hysterectomy, we would ere long have had a well-marked carcinoma of the cervix, and would have classed it as a carcinoma developing in the cervix after removal of the myomatous uterus, whereas the growth, though clearly present at the time of the operation, would have been overlooked.

In Case 2432 the patient was in a weakened condition. The pelvis was filled with a large myomatous uterus, to which the omentum and bowel were adherent. Had hysterectomy been attempted, the patient would have undoubtedly died on the table. Examination of the cervix showed adenocarcinoma.

In Case 6330 the position of the cervix, which was jammed up behind the symphysis, rendered the detection of the cancer very difficult. The uterus seemed much enlarged. On examination under ether, however, the true character of the condition was readily ascertained. In the vagina were several indurated areas, one of which was apparently about to ulcerate. The cervix was much thickened and friable, and readily broke down under the finger. The body of the uterus was the size of a three months' pregnancy, owing to the presence of a myoma. Histologic examination showed that the cervical growth was a squamous-celled carcinoma.

In Case 13015, in which a multiplicity of pathologic processes existed, and in which a supravaginal hysterectomy was done, a very small carcinoma occupying the upper part of the cervix and lower part of the body (Fig. 172, p. 272) was totally overlooked until examined in the laboratory. Had the operator known carcinoma of the cervix was present, however, it would have made little difference, as the independent and primary carcinoma of the ovary had already given rise to many metastases throughout the abdominal cavity, and the operation was therefore merely palliative, not radical. In this case the uterus contained numerous small myomata, subperitoneal, interstitial, and submucous.

Gyn. No. 12725. Path. Nos. 9502 and 9546.

Interstitial myoma in the body of the uterus; very early squamous-celled carcinoma of the cervix.

S. C. E., white, aged thirty-seven, married. Admitted February 24; discharged March 21, 1906. This patient was admitted to the hospital several years ago (Gyn. No. 5864) with a diagnosis of extra-uterine pregnancy. After operation she made an uninterrupted recovery. The patient has been bleeding steadily for the past two months and has had almost constant pain in the lower abdomen on both sides. On vaginal examination the cervix was found to present a peculiar hardness, although there was practically no breaking down and although, as mentioned in the history, there was no suggestion of malignancy. The body of the uterus was considerably enlarged.

Operation, February 28, 1906. Vaginal hysterectomy. Convalescence uneventful.

Path. No. 9546. The uterus is 12 cm. long. The cervix looks normal. Occupying the fundus is an interstitial myoma 3 x 3 x 2 cm.

Histologic Examination.—Sections from the cervix show just a few cells beginning to proliferate and to invade the stroma. Had it not been for the scraping prior to operation, it would have been very difficult for us to have said with absolute certainty that we were dealing with a malignant growth. The combined picture, however, leaves no doubt whatever that we have an early squamous-celled carcinoma.

Gyn. No. 2432. Path. Nos. 101 and 119.

A myomatous uterus; carcinoma of the cervix.

S. B., white, aged thirty-three, single. Admitted November 28; died December 26, 1893. Seven months before admission the patient first noticed a tumor in the lower abdomen in the left side, and for the past three weeks she has been complaining of severe pain in the pelvis and has been confined to bed. During the last few months the periods have increased in duration and the flow has been excessive. Menstruation has been irregular. The cervix was found to be the seat of a carcinomatous growth.

Operation, December 2, 1893. On section, the pelvis was found filled with a myomatous uterus to which the omentum and bowel were adherent. It was impossible to attempt enucleation on account of the weak condition of the patient. As a palliative measure the uterine arteries were clamped on both sides and the vagina was packed with gauze. The patient improved for a time, then lost ground and died December 26th. The enlargement of the body of the uterus was caused by multiple myomata. The growth of the cervix on histologic examination proved to be a carcinoma.

Gyn. No. 6330. Path. No. 2584.

Squamous-celled carcinoma of the cervix; myoma in the body of the uterus.

M. M., colored, aged forty-seven, married. Admitted August 30; discharged September 20, 1898. Complaint, pain in the lower abdomen and painful micturition. For the last four months the patient has had a profuse yellowish, offensive leukorrhœal discharge, and for a month has noticed a dull aching pain in the back and radiating down the legs. The pain at times has been cramp-like in character. Micturition has increased in frequency, and has been attended with considerable pain. During this period she has also lost much weight. On vaginal examination the outlet is found to be relaxed. The cervix is jammed up behind the symphysis, and the uterus is apparently much enlarged, retroflexed, and immovable. On ether examination the exact condition of affairs is readily ascertained. The vagina is very large. At the junction of the anterior and lateral wall on one side is a thickened area, irregular and rounded, about 2.5 cm. in diameter, rising above the surrounding tissue. The mucous membrane over this is reddened and apparently about to ulcerate. There is a similar thickened area low down in the vagina on the left side, and several smaller thickenings on the posterior wall. The surface of the cervix is roughened and readily breaks down under the examining finger. The body of the uterus is irregular, large, and nodular, the size of a three months' pregnancy, and markedly adherent posteriorly. The clinical diagnosis is carcinoma of the cervix, myomatous uterus incarcerated in the pelvis, secondary carcinoma of the vaginal wall. On September 2 the upper part of the cervix was curetted away. The abdomen was opened, the incarcerated myomatous uterus freed, but the carcinomatous process in the cervix had extended too far to permit of removal of the uterus.

Path. No. 2584. Histologic examination showed the growth to be a typical squamous-celled carcinoma of the cervix.

Gyn. No. 13015. Path. No. 10033.

Multiple and small uterine myomata; primary carcinoma of the upper part of the cervix and lower part of the body; primary carcinoma of the ovary, with wide-spread metastases (Fig. 172).

S. G., white, married, aged fifty-one. Admitted June 16; discharged July 14, 1906. Complaint, a tumor in the abdomen. The menopause occurred five or six years ago. Since then there has been no bleeding. Fifteen months ago the patient consulted her physician on account of griping pain in the abdomen. Although the pain was general in character, it was more marked in the right side. At this time she found that she had a tumor the size of a fist. Since then there has been a gradual abdominal enlargement. She has noticed some swelling of the feet and also enlargement of the veins on the right side.

On section, several quarts of dark-brownish fluid escaped from the abdomen. An ovarian cyst was found in the right side. The small intestines everywhere were covered with nodules 1 to 2 mm. in diameter, and the appendix had similar nodules on its surface. No definite metastases were found in the omentum, al-

though it was thickened and its vessels were dilated. Numerous small vessels were attached to the left ovary. Supravaginal hysterectomy was performed. The patient was discharged twenty-three days after operation.

Path. No. 10033. The uterus has been amputated through the cervix. It is 4.5 cm. in length, 5 cm. in breadth, and 4 cm. in its anteroposterior diameter. It is covered with adhesions. On the surface are several small pedunculated myomata, the largest 1 cm. in diameter. There is also a small submucous myoma 2 cm. in diameter, situated in the posterior wall. The upper part of the cervix and the lower part of the body are occupied by a growth apparently 2 cm. in length. This is porous in appearance and suggests carcinoma. Occupying what

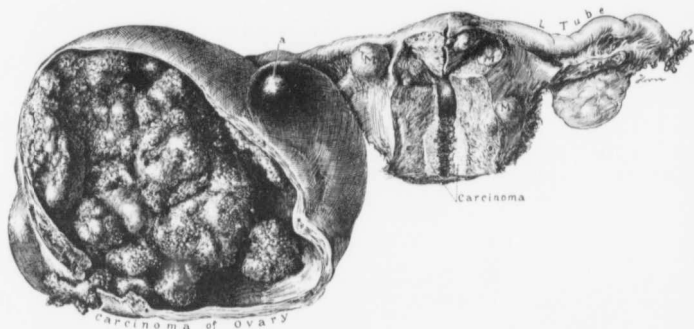


FIG. 172.—MULTIPLE SMALL UTERINE MYOMATA; PRIMARY CARCINOMA OF THE OVARY; PRIMARY CARCINOMA OF THE UTERUS. ($\frac{1}{2}$ nat. size.)

GYN. No. 13015. Path. No. 10033. The specimen is seen from the front. The uterus contains several myomata—subperitoneal, interstitial, and submucous. Occupying the upper part of the cervix and the lower part of the body is an early carcinoma. This has been cut through and a portion left behind. The right ovary has been converted into a cystic tumor filled with papillary masses, which have at one point perforated the cyst-wall and reached the peritoneal surface. As mentioned in the history, wide-spread metastases were found in the abdominal cavity. *a* is a corpus luteum which has not ruptured.

corresponds to the right ovary is a tumor 14 cm. in diameter. This is covered with adhesions, is pearly white in appearance, but has areas of mottling. On section, the cyst is found to be partly cystic, with little masses projecting from the surface. To a great extent, however, it is solid, having cauliflower-like masses projecting into the cavity. Some of these masses resemble brain tissue. The solid portion is 5 cm. in thickness.

Histologic Examination.—The tumor of the right ovary consists of masses of papillary outgrowths of all kinds. In some places the glands are large, in others exceedingly small. The gland epithelium here and there has proliferated, but, as a rule, is well preserved. We have a characteristic picture of adenocarcinoma. The nuclei of the cells, on the whole, are very uniform.

The friable area in the cervix, suggesting malignancy, proves to be carcinoma. We have gland-like spaces lined with one layer of very high cylindrical epithelium. In some places the glands are completely filled with young secondary glands, and at other points the epithelium of these secondary glands has so proliferated that we have masses of cells which, under the low power, closely resemble epithelial pearls. The individual epithelial cells are fairly uniform in size. Here and there, however, are large vesicular nuclei, irregular nuclei, and a great number of nuclear figures. There is a certain amount of disintegration. The growth is an adenocarcinoma and is apparently independent of the carcinoma of the ovary. Along its advancing margins there is considerable small-round-celled infiltration.

In this case we have multiple uterine myomata, two malignant processes, one commencing in the ovary and forming metastases over the surface of the intestines, the other a primary carcinoma originating in the cervix and lower part of the body of the uterus.

CHAPTER XVI.

ADENOCARCINOMA OF THE BODY OF THE UTERUS ASSOCIATED WITH UTERINE MYOMATA.

In our examination of over 1400 cases of myomatous uteri adenocarcinoma was detected in the body of the uterus in 25 cases (about 1.7 per cent.): Adenomyomata associated with adenocarcinoma of the body (see "Adenomyoma of the Uterus," p. 218), 3 cases. Myoma and adenocarcinoma of the uterus seen at autopsy, 6 cases (see p. 404). Myoma and adenocarcinoma of the body of the uterus, operated upon, 16 cases.*

Clinical History.—The accompanying histories demonstrate that in most of the cases myomata had been present for several years, that for some months or a year before admission uterine hemorrhages had been noted, and that between periods there had been a watery and offensive vaginal discharge.

Color.—In 15 out of the 17 cases in which definite data could be obtained the patients were white.

Age.—In 17 cases we have data as to the patient's age. The period at which the carcinoma has been detected corresponds to the decade of life during which carcinoma of the body of the uterus is usually found. The youngest patient was thirty; the oldest, sixty-four.

Between thirty and forty—	2 cases.
Between forty and fifty—	5 cases.
Between fifty and sixty—	8 cases.
Between sixty and seventy—	2 cases.
	17 cases.

The association of sterility with the development of carcinoma of the body of the uterus was emphasized by us several years ago.† Our previous experience is strikingly supported by the table on p. 275.

Out of the 17 patients, 6 were single and 3 more had never been pregnant. Of the remaining 8 patients, 3 had had one miscarriage each, but had never born full-term children. Thus, 12 out of the 17 had never been delivered of a child at term. The remaining 5 women had given birth to 12 children. Sterility certainly seems to be in some way closely associated with the development of adenocarcinoma of the body of the uterus.

* In Cases 2832, 3258, and 12771 myomata and adenocarcinoma of the body of the uterus were found in the same uterus. The myomata were, however, too small to be of any clinical significance, and these cases have, accordingly, been omitted from the table.

† Thomas S. Cullen, *Cancer of the Uterus*, page 474.

GYN. NO.	MARRIED	NUMBER OF CHILDREN	MISCARRIAGES
Std. No. 1852	Yes	4	0
10220	Yes	4	1
10085	No		
9141	No		
1069	No		
1691	No		
4262	Yes	1	0
5858	No		
5957	Yes	0	1
3295	Yes	0	0
10462	Yes	0	0
10997	No	0	0
9443	Yes	2	0
9012	Yes	0	1
9934	Yes	0	0
K. C. H. I. Nov. 8, 1900	Yes	0	1
3113	Yes	1	0
		12	4

Gross Appearances of the Uterus.—The myomata may be situated in any part of the uterus. Most frequently they are found in the body, but in some cases are located low down in the cervix. For example in Fig. 175 (p. 278) we see a myomatous nodule several centimeters in diameter, situated to the side of the cervix. In Fig. 182 (p. 290) the cervix is much distorted by a large myoma, rendering it as large as the body, which is also much increased in size as a result of the carcinoma combined with interstitial myomatous nodules.

In Fig. 183 (p. 292) the uterus is several times its natural size. Studding the surface are numerous small myomata, and scattered throughout the walls are several myomatous growths. The chief increase in size is due, however, to a most extensive carcinoma occupying every part of the uterine cavity.

The uterus shown in Fig. 180 (p. 286) was several times the usual size, and presented the characteristic myomatous appearance, but there was a peculiar volcanic appearance of the outer surface at *a*. Here, as shown later, the carcinoma had penetrated the entire thickness of the uterine wall and lay just beneath the peritoneum.

Occasionally, as in Case 1691, in which the enlarged uterus extended four inches above the pubes, a submucous myoma was associated with the carcinoma.

It must be borne in mind that in nearly every case the myomatous condition partly or completely obscures the presence of the carcinoma. Histologically, these adenocarcinomata differ in no way whatever from uncomplicated adenocarcinoma of the body of the uterus.

Diagnosis of Adenocarcinoma.—A glance through the histories of the accompanying cases will show that in most of them carcinoma was not suspected until after removal of the uterus. Clinically, uterine hemorrhages can be caused by uterine myomata, and when the nodules become submucous and undergo disintegration, a foul and at times watery discharge is the natural accompaniment.

In such cases the cervix is normal and the enlarged and irregular uterus presents the characteristic undulating contour of a multinodular uterus. As a rule, no malignant change will be found in the uterine mucosa, although in a certain percentage carcinoma of the body exists. True, in a goodly number of cases curettage would reveal the carcinoma, but if we followed these lines, curetting would be done in many cases in which no carcinoma exists, and in some instances, as, for example, Case 9141 (Fig. 182, p. 290), in which there was a very large cervical myoma, the uterus was so distorted that it would be almost impossible to reach all parts of the uterine cavity with the curet.

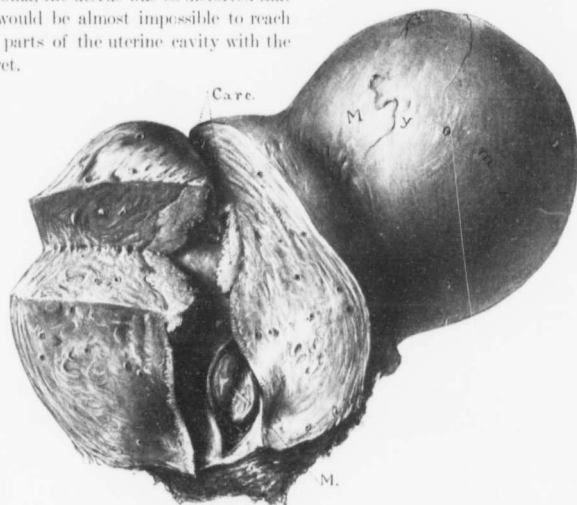


FIG. 173.—ADENOCARCINOMA OF THE BODY OF THE UTERUS, ASSOCIATED WITH MYOMATA. (1 nat. size.)

Path. No. 6811. This specimen was sent us by Dr. Paul Owsley, of Chicago, on January 25, 1903. It is not included in our statistics, but is such an excellent example that we have had it drawn. Near the cervix is a small submucous myoma. Occupying the upper part of the body is an early carcinomatous growth which as yet has not broken down. The myoma, occupying the left upper uterine wall, measured 8 cm. in diameter. The uterus also contained several other nodules.

Treatment.—The association of adenocarcinoma of the body of the uterus with myoma in about 1.7 per cent. of the cases would naturally suggest total abdominal hysterectomy as a routine procedure. We know by experience, however, that the supravaginal amputation is not only the easier operation, but that where the uterus is much enlarged and distorted, it is often the only one feasible. We feel that in this operation there is much less danger of injuring the ureters. If the presence of carcinoma of the body can be definitely established or is relatively certain, total hysterectomy should certainly be performed. We are

still in favor of the routine supravaginal hysterectomy, with the usual precautionary control measures*—opening the uterus to determine if carcinoma exists and cutting open any suspicious myomata to see if by chance sarcomatous changes are present. If malignancy is detected, the cervix is at once removed. When carcinoma of the body exists, the chances of infection and death are considerably increased as a result of the foul vaginal discharge.

CASES IN WHICH ADENOCARCINOMA OF THE BODY OF THE UTERUS WAS ASSOCIATED WITH UTERINE MYOMATA.

Gyn. No. 9443. Path. No. 5671.

Subperitoneal and interstitial myomata; adenocarcinoma of the fundus, probably originating near the internal os. (Fig. 174).

D. S., aged sixty-four, white, married. Admitted March 4; discharged April 12, 1902. The menopause occurred ten years ago. The patient has had two children; no miscarriages. For ten years she has had some pain over the bladder, especially on lying down, and more recently has had constant pain, more marked on exertion. Operation, March 15th. Panhysterectomy. Recovery.

Path. No. 5671. The specimen consists of the entire uterus with the appendages. The uterus is 10 cm. in length, 7 cm. in breadth, and 5 cm. in its anteroposterior diameter (Fig. 174). The appendages are slightly adherent. Springing from the right uterine horn is a myomatous nodule, 3.5 cm. in diameter. The cervix appears normal. The uterine walls vary from 2 to 2.5 cm. in thickness, show diffuse myomatous thickening, and contain some discrete myomatous nodules. The mucosa of the cervix in the lower part looks normal. Occupying the upper part of the cervix, and also

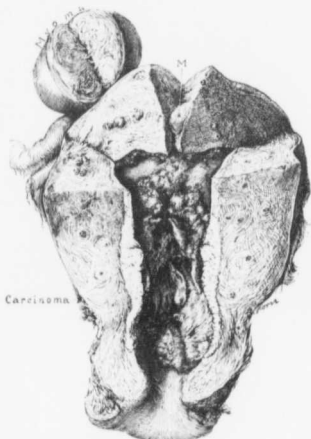

FIG. 174.—CARCINOMA OF THE LOWER PART OF THE BODY AND UPPER PART OF THE CERVIX; UTERINE MYOMATA. (3 nat. size.)

Gyn. No. 9443. Path. No. 5671. The greater part of the uterine cavity was the seat of a carcinomatous growth. The uterine walls showed diffuse myomatous thickening and contained small discrete myomata. The subperitoneal myoma was 3.5 cm. in diameter.

* Thomas S. Cullen, Examination of Uterine Mucosa and Myomatous Nodules after Hysteromyectomy to Exclude Malignant Disease, Jour. A. M. A., March 10, 1906.

the greater part of the uterine cavity, is a shaggy growth. In some places this projects fully 1 cm. from the surface. The shaginess in places consists of fine outgrowths, but at other points there are little tongue-like projections.

On histologic examination the growth in the body of the uterus is found to consist of typical adenocarcinoma, apparently of the type that originates in the body.

Bimanual examination of such a uterus would show that the body is considerably enlarged and that, on the surface, is a nodular growth. One would at first suppose that he was dealing with a myomatous uterus, but curettage would instantly give a proper clue as to the diagnosis.

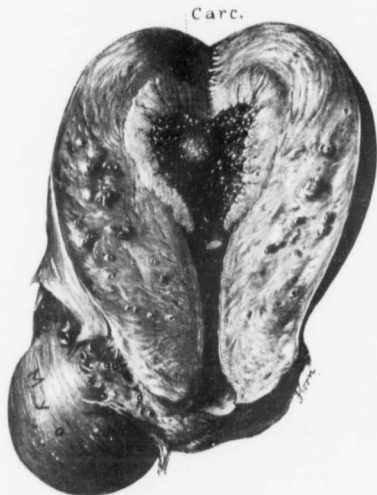

FIG. 175.—MYOMA OF THE CERVIX AND CARCINOMA OF THE BODY OF THE UTERUS. (Nat. size.)

Gyn. No. 10220. Path. No. 6418. The myoma to the left of the cervix was 4 cm. in diameter, and situated in the anterior wall was an interstitial nodule 2.5 cm. in diameter. There is some diffuse thickening of the uterine walls, and cross-sections of the blood-vessels stand out prominently. The carcinomatous growth uniformly occupies the upper part of the cavity and is sharply defined.

a leukorrhœal discharge for the past year and a half. This at first was yellowish in color, but later assumed a reddish tinge.

Operation, supravaginal hysterectomy. After removal of the uterus it was split open, and in the fundus was found a polypoid friable growth. The rest of the cervix was now removed. The patient made a satisfactory recovery.

Path. No. 6418. This specimen consists of the uterus, left tube and ovary, and the remaining portion of the cervix. The portion of the uterus measures 8 x 6 x 6 cm., and is considerably distorted. Projecting from the anterior wall

Gyn. No. 10220. Path. No. 6418.

Cervical myoma associated with adenocarcinoma of the body of the uterus (Fig. 175).

N. S., white, married, aged fifty-eight. Admitted January 28; discharged March 3, 1903.

The periods commenced at fourteen and were regular, every four weeks, lasting four or five days. The menopause occurred seven years ago. The patient has had four children and one miscarriage. She has had

is an interstitial nodule approximately 2.5 cm. in diameter, and from the side of the cervix a myoma 4 cm. in diameter. The cervical canal forms a semilunar slit. The mucosa lining the cervix is apparently normal. Occupying the body of the uterus is a growth which in places reaches 1 cm. in thickness (Fig. 175). It has a shaggy surface and here and there forms little polypoid masses. It has penetrated the uterine wall for a considerable distance, and has apparently involved the mucosa throughout the greater part of the cavity. The left tube and ovary show nothing of interest.

Microscopically, the myoma in the anterior wall shows considerable hyaline change. The growth in the body of the uterus is an adenocarcinoma. In most places the gland epithelium has proliferated to such an extent, however, that it forms solid masses, and here and there suggests a squamous-celled growth.

From a clinical standpoint the condition might very readily be mistaken for a simple myomatous uterus. We have to the left of the cervix a hard nodule, a typical myoma, and in the anterior wall just above this a myomatous nodule. One would naturally suppose that the hemorrhage had come from the submucous myoma.

Gyn. No. 10462. Path. Nos. 6685 and 6730.

Carcinoma of the body of the uterus, apparently originating near the internal os; subperitoneal myomata; pelvic adhesions; subacute salpingitis (Fig. 176).

K. S., white, aged fifty-one, married. Admitted May 5; discharged June 1, 1903. The patient has been married twenty-five years but has never been pregnant. Seven weeks ago she noticed a yellowish vaginal discharge. Six weeks ago hemorrhage began and has continued ever since. The patient is rather emaciated and weak. Hemoglobin, 50 per cent.

Operation. The uterus was the size of a four months' pregnancy and was lifted upward with a great deal of difficulty on account of numerous adhesions. On pressure it suddenly collapsed and a large amount of necrotic material escaped from the cervix, suggesting a pyometra. Two myomatous nodules on the right side were adherent to the pelvic wall, apparently causing a hydroureter on the right side. On account of the subsequent pathologic findings the cervix was removed two weeks later *per vaginam*. The patient was discharged twenty-five days after the first operation.

Path. Nos. 6685 and 6730. The specimen consists of a myomatous uterus amputated through the cervix and of the tubes and ovaries. The uterus measures 6 x 5 x 5 cm. Anteriorly, it is smooth; posteriorly, covered with adhesions. Projecting from its surface are two pedunculated myomata, one 6 x 5 cm., the other somewhat smaller (Fig. 176). These are likewise covered with adhesions. On section, it is found that nearly the entire cervical portion of the uterus and the greater portion of the body is occupied by a shaggy growth, which in the cervix extends downward almost to the line of incision, and has

apparently not been entirely removed. The uterine wall above the point of invasion varies from 1 to 2 cm. in thickness.

Microscopic sections show that the growth in the uterus is of a glandular type. In many places the epithelium has so proliferated that we have solid masses of cells closely resembling squamous epithelium. The superficial portions show considerable disintegration. The growth is

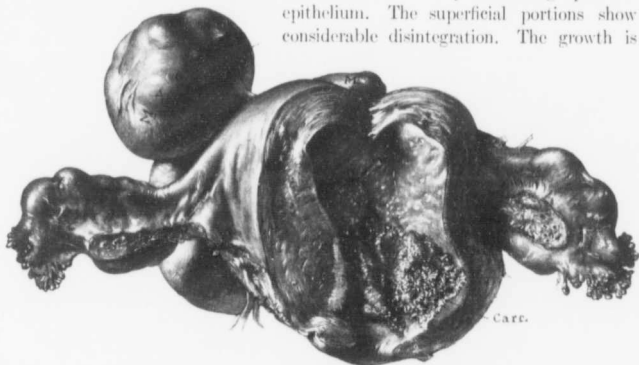


FIG. 176.—MULTIPLE UTERINE MYOMATA; CARCINOMA OF THE LOWER PART OF THE BODY AND UPPER PORTION OF THE CERVIX. (1/2 nat. size.)

Gyn. No. 10462. Path. Nos. 6685 & 6730. Before the drawing was made the cervix, which was removed later, was added to the upper part of the uterus. Three subperitoneal myomata are seen. The largest of these was 6 x 5 cm. The external os is normal but the upper part of the cervix and lower part of the body are occupied by a shaggy papillary adenocarcinomatous growth.

an adenocarcinoma. Sections from the left tube near its middle show a moderate degree of subacute salpingitis.

This case is interesting from a clinical standpoint. The general contour of the uterus, with its accompanying nodules, strongly suggests a myomatous uterus. The growth is seen extending down to the internal os, and might very readily be overlooked; in fact, carcinoma was not suspected until the uterus had been removed.

San. No. 1852. Path. No. 8347.

Subacute inflammation of the cervix; adenocarcinoma of the body of the uterus; adenomyoma of the body of the uterus, and an apparently independent round-celled sarcoma of the body of the uterus.

This case is reported in detail in "Adenomyoma of the Uterus," p. 225.

Gyn. Nos. 3295 and 7699. Path. Nos. 582 and 3948.

Submucous myoma, with areas strongly suggesting sarcomatous degeneration. Five years later

complete hysterectomy for carcinoma of the body of the uterus.

R. B., aged forty-five, married, white. Admitted January 24, 1895. At that time the vagina was filled with a smooth, hard, conical mass. A myomec-tomy was performed, and the patient discharged on February 23, 1895.

Histologic examination of the myoma showed changes very suggestive of sarcoma.

The patient was admitted again in April, 1900, more than five years later, and the uterus removed on account of a carcinomatous growth, which occupied the body.

Path. No. 3948. The specimen consists of the uterus with its appendages. The uterus is somewhat enlarged, measuring 13 cm. in length, 8 cm. in breadth, and 6 cm. in its anteroposterior diameter. Occupying the right cornu is a nodule 3 cm. in diameter, which proves to be a myoma. The cervix has been converted into a mere shell, measuring 7 cm. in length and 5 cm. in its antero-posterior diameter. The internal os is 1.7 cm. wide. The lower 2.5 cm. of the cervical canal presents the usual appearances, but the remaining portion has been hollowed out with a curet. Here the surface is rough and covered with a layer of friable tissue and blood-clots. Occasionally long, finger-like, papillary out-growths are seen, and where the growth joins the uterine cavity and has not been injured by the curet, definite yellowish-white, very friable papillary masses are present. The walls of the excavated portion of the cervix vary from 3 to 4 mm. in thickness, are indurated, but break down readily. The uterine cavity is 3 cm. long. The mucosa in the upper portion is slightly injected, but smooth. In the lower half of the cavity it is gathered up into papillary masses continuous with those of the cervical growth. Projecting into the uterine cavity are two small polypi. The tubes and ovaries are slightly adherent, but otherwise normal.

On histologic examination the growth in the uterus proved to be an adenocarcinoma, and probably originated just above the internal os. The uterus, besides containing the subperitoneal nodule, also had small interstitial myomata scattered throughout it.

In October, 1902, the patient returned with an inoperable growth in the vagina. This case is interesting because the myoma which was removed five years before showed changes most suggestive of sarcoma. (See p. 248.)

Gyn. No. 10997. Path. No. 7246.

Multiple uterine myomata, submucous, interstitial, and subperitoneal; adenocarcinoma involving fundus and cervix (Fig. 177).

B. A., aged fifty-four, white, single. Admitted January 18; discharged February 27, 1904. One sister was operated upon in this hospital for myoma some years ago. For seven years the patient has noticed an abdominal tumor. Two years ago there was considerable abdominal pain. For the last year there

has been a continuous vaginal discharge, usually watery in character, often stained with blood.

Operation. Hysteromyomectomy with amputation through the cervix. The endometrium looked carcinomatous, and in consequence the entire cervix was removed. The patient made a perfect recovery.

Path. No. 7246. The specimen consists of a multinodular myomatous uterus, 16x14x10 cm. This has been amputated through the cervix. Anteriorly, the growth is free from adhesions; posteriorly, these are numerous. Occupying the anterior wall is a myomatous nodule 8 cm. in diameter (Fig. 177). There is a subperitoneal myoma 2 cm. in diameter, and several others scattered throughout

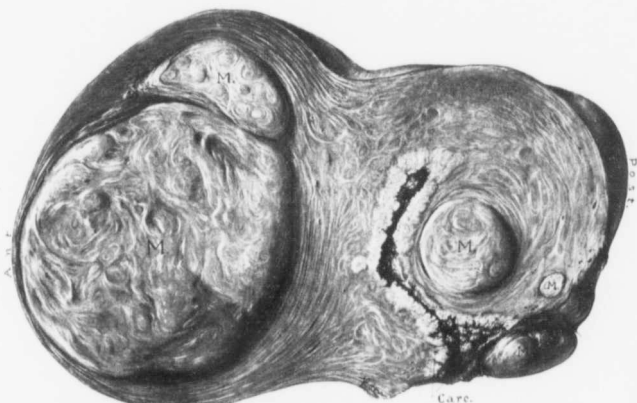

FIG. 177.—MULTIPLE UTERINE MYOMATA; CARCINOMA OF THE BODY OF THE UTERUS. (Nat. size.)

GYN. No. 10997. Path. No. 7246. The uterus contained several interstitial myomata, the largest of which was 8 cm. in diameter. Lining the entire uterine cavity was a carcinomatous growth that extended to the point of amputation. This fact having been discovered at the time of operation, the remainder of the cervix was at once removed.

the walls. The appendages are apparently normal. On section, the cavity of the uterus is found to be irregular in shape and 7 cm. in length. Surrounding the entire cavity from cervix to fundus is a fine papillary or tree-like growth. In the cervical portion it is very well outlined and preserved, but in the body it has in places become necrotic. At no point is there any evidence of normal mucosa. The growth in certain places involves the wall for a distance of 1.5 cm. It is sharply outlined from the uterine muscle.

Microscopically, no trace of normal mucosa of the cervix or of the body is found. The cavity of the uterus is lined with an irregular growth of glands, that in some places show a distinct papillary arrangement. The growth is a typical adeno-carcinoma.

Gyn. No. 5858. Path. No. 2146.

Adenocarcinoma of the body of the uterus, associated with interstitial myomata; chronic endometritis both of body and cervix (Fig. 178).

K. H., aged forty-seven, white, single. Admitted February 8, 1898, complaining of pain in the left lower abdomen and also of uterine hemorrhage. For two years she has had severe hemorrhages and some vaginal discharge, watery in

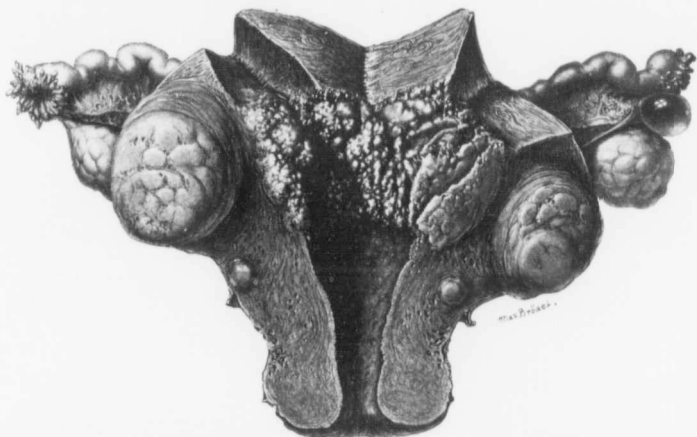


FIG. 178.—ADENOCARCINOMA OF THE BODY OF THE UTERUS ASSOCIATED WITH INTERSTITIAL MYOMATA.
($\frac{1}{2}$ nat. size.)

Gyn. No. 5858. Path. No. 2146. The uterus is nearly twice its natural size and is pear-shaped. Situated in the anterior wall near the fundus is a typical myoma, and just below it a smaller one, of the interstitial variety. The cervix is much thickened, but retains its normal contour. The vaginal portion is intact. In the gross specimen the cervical canal appears unaltered, although a severe endometritis was present. The mucosa in the lower part of the uterine cavity likewise presents the usual appearance, although here also there was a most extensive endometritis. Occupying the upper part of the cavity is a new-growth, roughly divided into parallel rows. These vary in size and have smooth surfaces, in contradistinction to the delicate, finger-like outgrowths usually present. In a few of the crevices between the polypi, however, some of the finger-like processes are noted. The growth averages 1 cm. in thickness, and has invaded the greatly thickened muscular walls to a slight extent. Macroscopically, the appendages on both sides appear to be normal, but the tube on the right side was found to be the seat of an acute salpingitis, although the fimbriated extremity was patent. It is almost certain that the streptococcal peritonitis developed from the discharges caused by the profuse endometritis. (After Thomas S. Cullen.)

character, and frequently blood-tinged and offensive. On examination of scrapings the presence of adenocarcinoma of the body was detected.

Operation, February 12, 1898. Panhysterectomy. The adherent omentum having been released, the uterus was removed in the usual way. The patient developed a general peritonitis and died within twenty-four hours. A pure culture of *Streptococcus pyogenes* was obtained from the abdominal cavity.

Path. No. 2146. The specimen consists of the uterus, tubes, and ovaries. The uterus is 11 cm. in length, 7 cm. broad, and 8 cm. in its anteroposterior diameter. It is free from adhesions. Projecting from the anterior surface is a rounded boss 5 cm. in diameter. It is firm in consistence, and on section presents the usual myomatous appearance. The vaginal portion of the cervix appears to be normal. The cervical portion is 3.5 cm. long, and averages 9 mm. in diameter. The mucosa is smooth, but somewhat injected. The uterine cavity is 5 cm. in length, and at the fundus reaches 5 cm. in breadth. Occupying nearly the entire cavity is a new-growth, grayish in color (Fig. 178). It is for the most part divided up into several longitudinal ridges, separated by deep furrows. The tissue composing the ridges has a smooth surface, but at several points along the advancing margin of the growth delicate, finger-like processes are visible. The downward extension of the tumor is sharply defined, the growth overlapping the mucous membrane. On an average it is 1 cm. in thickness and has extended for about 3 or 4 mm. into the depth. On section, the tissue of the new-growth is seen to be somewhat friable.

Histologic Examination.—The mucosa of the cervix and that of the body not invaded by the cancer has been converted almost entirely into granulation tissue, evidently as a result of a long-standing infection. The patient was undoubtedly infected from the uterine discharge, the general peritonitis which so soon caused her death being readily accounted for.

This case is described in detail in Cullen's "Cancer of the Uterus," p. 452.

Gyn. No. 5957. Path. No. 2238.

A large myomatous uterus with adenocarcinoma of the body; general pelvic peritonitis (Fig. 179).

S. B., colored, aged forty-seven, married. Admitted March 16; discharged April 22, 1898. Complaint, abdominal tumor. Her menses commenced at thirteen and were always regular until six years ago. She had a miscarriage at twenty-three. Six years ago she had a fairly constant bloody uterine discharge, alternating with a leukorrheal flow, and about three years later first felt a small lump in the abdomen, which has increased slowly in size. During the last nine months she has had a dull, aching sensation in the lower part of the abdomen.

Operation, March 21, 1898. Abdominal hysterectomy. The uterus was amputated through the cervix, carcinoma not being suspected until after the operation was completed.

Path. No. 2238. The specimen consists of the uterus, which has been converted into a globular tumor 11 cm. in diameter, covered with numerous vascular adhesions. Springing from it are several myomata, some of which are sessile, others pedunculated. The portion of the cervix present is 2 cm. in length; its mucosa presents the usual appearance. The uterine walls vary from 4 to 8 cm. in thickness, and contain several myomatous nodules, the largest being 6 cm. in diameter. The uterine cavity is 6 cm. long and 4.5 cm. broad at the fundus

(Fig. 179). The mucosa covering the posterior wall is smooth and glistening and slightly injected. It varies from 1 to 2 mm. in thickness. The portion covering the anterior wall is profoundly altered, and now consists of a new-growth averaging 1 cm. in thickness. The surface, for the most part, is smooth, but occasionally projecting from it is a minute, finger-like process, while at several

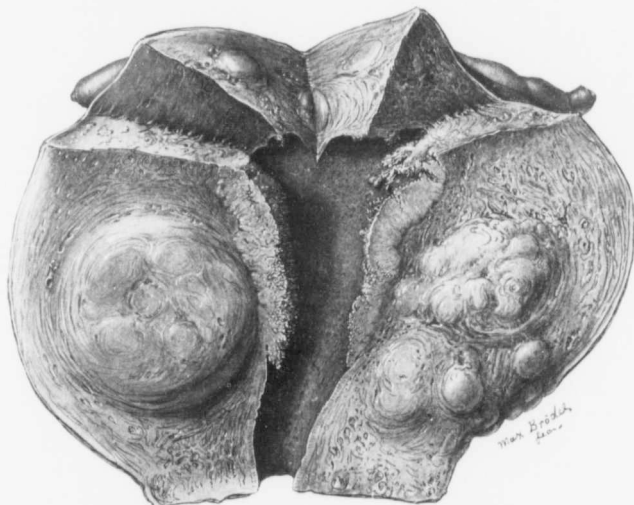


FIG. 179.—A LARGE MYOMATOUS UTERUS SHOWING ALSO AN ADENOCARCINOMA OF THE BODY. ($\frac{1}{2}$ nat. size.)

Gyn. No. 5957, Path. No. 2238. The uterus is much enlarged and has subperitoneal nodules projecting from its surface. Situated in the anterior wall are one large and several smaller interstitial myomata. The uterus has been amputated through the cervix. The mucosa in the lower part of the uterine cavity is normal, but on being traced upward several centimeters on the anterior wall it is replaced by a new-growth, which in places is smooth, but at most points is covered with delicate, finger-like outgrowths. The growth reaches 1 cm. in thickness, and stands out in sharp contrast to the uterine muscle, which it has invaded to a slight extent. Upward it reaches to the top of the uterine cavity, its advancing margin being irregular. The mucosa covering the posterior wall is slightly mottled, but otherwise appears normal. The stumps of both Fallopian tubes are visible in the upper part of the picture. All the symptoms in this case might readily have been caused by the myomata, and without curettage it would have been impossible to diagnose the carcinoma. Had we known that the carcinoma was present in this case, the uterus would have been entirely removed instead of being amputated through the cervix. (After Thomas S. Cullen.)

points the surface presents a shaggy appearance, due to aggregations of myriads of these finger-like projections. At one point these delicate outgrowths form a bunch projecting fully 1 cm. from the surface. The growth, on section, presents a waxy appearance, and stands out in sharp contrast to the muscle which it has invaded for a short distance.

On histologic examination the growth in the body is found to be a typical adenocarcinoma.

This case is described in detail in Cullen's "Cancer of the Uterus," p. 449.

K., C. H. I. Path. No. 4479.

Subperitoneal, interstitial, and submucous myomata; extensive adenocarcinoma of the body of the uterus (Fig. 180).

E. P. K., white, aged thirty-eight, married. Admitted to the Church Home and Infirmary November 8; died November 17, 1900. She had one miscarriage

nine years ago. In March, 1900, she had three hemorrhages, which were severe and showed large clots. Since then there has been frequent bleeding, and lately a profuse leukorrhoeal discharge.

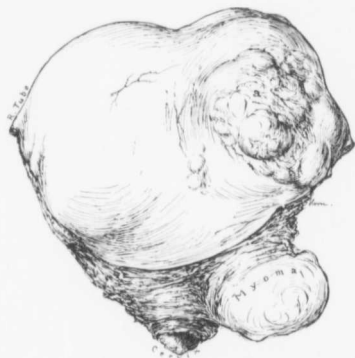

FIG. 180.—MULTIPLE UTERINE MYOMATA; ADENOCARCINOMA OF THE BODY, WITH EXTENSION TO THE PERITONEAL SURFACE. ($\frac{1}{3}$ nat. size.)

K., C. H. I. Path. No. 4479. The uterus has been amputated through the cervix, and to the left is a myoma. The body of the uterus contains several myomatous nodules. Over a large area (a) the tissue presents a volcanic appearance, due to a welling-out of the growth. On section, carcinoma of the body was found, the unusual appearance of the surface being due to extension of the growth by continuity to the peritoneal surface.

Had the carcinoma been suspected at operation, the cervix would, of course, have been removed at once. The cervical myoma, together with the general contour of the uterus, would naturally suggest to the operator that he was dealing with an ordinary myomatous uterus.

The uterus reached a point midway between the pubes and umbilicus, and on examination presented a peculiar appearance. The mass suggested a myoma, and yet there was an unevenness of the surface—what might be termed a volcanic appearance, the growth welling out on all sides and having an umbilicated center. The left tube and ovary were tied off, the round ligament was controlled, and a myoma 5 cm. in diameter was then detected lying in the broad ligament. After operation the uterus was opened and the malignant growth detected, and we expected to remove the cervix at a later date.

For the first day after operation the patient did comparatively well, but then commenced to show definite signs of peritonitis and died in a few days. This case shows the absolute necessity of opening the uterus the minute it is removed. Had we followed out this rule, the cervix would have been taken out at once; we would have placed a liberal gauze drain in the pelvis, and probably have avoided

infection, which so frequently follows where such a foul carcinomatous growth exists.

Path. No. 4479. The specimen consists of a large multinodular myomatous uterus (Fig. 180). The fundus is occupied by a large tumor mass, 12 x 13 cm., developed more posteriorly than anteriorly. The surface is generally smooth. On section of the uterus the cavity is found to be filled with a carcinoma of the body, associated with numerous myomatous nodules.

Gyn. No. 4262. Path. No. 1137.

Subperitoneal, interstitial, and submucous myomata; adenocarcinoma of the body of the uterus (Fig. 181).

E. P., aged thirty, colored, married. Admitted March 30; discharged April 30, 1896. The patient has had one child and no miscarriages.

Operation, April 6, 1896. Abdominal hysteromyectomy with amputation through the cervix. The patient made an uninterrupted recovery.

Path. No. 1137. The specimen consists of the uterus with its appendages. The uterus is approximately globular, measuring 15 x 13 x 13 cm. Both anteriorly and posteriorly it is smooth and glistening. The portion of the cervix present is 4 cm. in diameter. The posterior uterine wall varies from 2.5 to 3 cm. in thickness, and scattered throughout it are several myomata, some of which are interstitial, others sessile. The anterior wall varies from 2 to 9 cm. in thickness; besides containing several small myomata, it is occupied by a submucous myoma 8 cm. in diameter. The uterine cavity is 8 cm. in length, and at the fundus 7.5 cm. in breadth. The mucosa at the fundus varies from 2 to 3 mm. in thickness, but the greater part of that covering the anterior wall and also that on the posterior wall presents a markedly altered appearance, being gathered up into large and small tongue-like folds, varying from 0.3 to 1.5 cm. in breadth (Fig. 181). Some of these reach 7 mm. in thickness, but where subjected to pressure, they are flattened. The small tongue-like masses are smooth and glistening, and cannot be subdivided into smaller ones, as is usually the case in adenocarcinoma of the body. After hardening in Müller's fluid it is possible to make out in a few places a delicate branching or tree-like arrangement. The larger eminences are traversed by shallow depressions, which to a slight extent subdivide them into smaller ones. They also have delicate capillaries ramifying over them in all directions. Near the fundus the mucosa reaches 2 cm. in thickness, and only its superficial portions tend to become polypoid. The mucosa in its deeper portion is sharply defined, being well marked off from the muscle, which it apparently has not penetrated. The posterior wall over a limited area has been entirely denuded of mucosa by the curet.

Microscopically, the growth proved to be an exceptionally interesting adenocarcinoma. (The histologic findings are given in detail in Cullen's "Cancer of the Uterus," p. 440.)

Gyn. Nos. 1069 and 1782.

Uterine myomata; carcinoma of the body of the uterus.

L. W., single, white, aged forty-four. Admitted November 16; discharged December 17, 1891. The menstruation has been profuse for the last three or four years; lately associated with pain in the lower abdomen. Operation, November 23, 1891, removal of both ovaries.

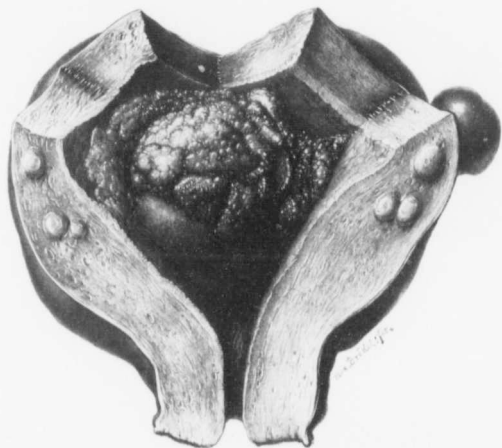


FIG. 181.—MYOMATA AND ADENOCARCINOMA OF THE BODY OF THE UTERUS. (3 nat. size.)

Gyn. No. 4262. Path. No. 1137. The much enlarged uterus has been opened posteriorly. Projecting from the posterior surface is a small subperitoneal myoma. Scattered throughout the walls, which are increased in thickness, are a few interstitial myomata. The cervical canal is unaltered. The uterine cavity is much enlarged. Projecting into it from the anterior wall is a large submucous myoma. Occupying the anterior wall and extending over the posterior wall is a new-growth, in some parts forming a homogeneous and slightly lobulated mass, but in some places consisting of polypi of various sizes and with fairly sharp edges. In a few places delicate, finger-like outgrowths spring from the surface of the polypi or from the depressions between them. The new-growth stands out sharply from the normal mucosa covering the posterior wall. (After Thomas S. Callen.)

She was again admitted on January 29, and discharged on February 27, 1893 (Gyn. No. 1782). Operation, February 4, 1893, hysteromyomectomy; amputation through the cervix. On removal of the large, irregular myomatous uterus carcinoma of the body was found. The patient made a perfect recovery. No histologic examination was made.

Gyn. No. 1691.

A sloughing submucous myoma associated with carcinoma of the body.

R. A., white, single, aged forty-five. Admitted November 23; discharged

December 29, 1892. The menses were regular until seven years ago, after which the flow appeared every two weeks and was very profuse. During the past year it has been almost continuous. The bleeding at times has been so profuse that the patient has fainted.

Operation, November 28, 1892. Hysteromyomectomy with amputation through the cervix. When the uterus was opened, a sloughing submucous myoma was found, and also a carcinoma of the body. A note was made on August 13, 1895, that the patient was well and growing fat; her only complaint was of slight backache. No histologic examination was made.

Gyn. No. 9141. Path. No. 5312.

A large cervical myoma; subperitoneal and interstitial uterine myomata; advanced adenocarcinoma of the body (Fig. 182).

S. T., single, white, aged sixty-one. Admitted October 17, 1901. The menopause occurred at fifty-four. For the past six years there has been a slight yellowish discharge, and five years ago this became blood-tinged; for the past year it has been offensive.

Operation, October 21, 1901. Panhysterectomy. A large mass above the symphysis was found to be the fundus pushed up from below by a myoma situated near the cervix. On the surface of the uterus, near the right cornu, was an elevation, 2 cm. in diameter; this differed entirely from an ordinary myoma, and was evidently an area of carcinoma from an extension of the growth through the uterine wall. Complete hysterectomy was performed. The patient was discharged on November 16, 1901.

Path. No. 5312. The specimen consists of an enlarged uterus, with its appendages intact. The uterus is approximately 14 x 10 x 10 cm. in its various diameters. The surface is smooth and glistening, but nodular. Over the right cornu is an irregular, slightly raised, whitish area, with puckered margins. It is about 2 cm. in diameter, and closely resembles an area of lupus where healing has taken place. Scattered throughout the uterine walls are myomata, the chief increase in size being due to a globular myoma, 7 cm. in diameter (Fig. 182). This is situated directly behind the cervix, and has evidently projected down beneath the peritoneum into Douglas' cul-de-sac. The uterine cavity is about 10 cm. in length. The mucosa of the cervix presents the usual appearance, but the cavity of the uterus is considerably distended, and is everywhere lined with a friable material of brain-like consistence. The superficial portions of this consist of small, delicate, finger-like projections, and covering the surface is necrotic tissue. The growth reaches a thickness of 2 cm. or more, and is everywhere penetrating the uterine walls. At the right uterine horn, where the puckering was noticed on the surface, it has extended to the peritoneum. The tubes and ovaries on both sides are apparently normal.

On histologic examination the growth is found to be an adenocarcinoma with

a definite tendency to form papillary outgrowths. Along its advancing margin there is a great deal of round-celled infiltration.

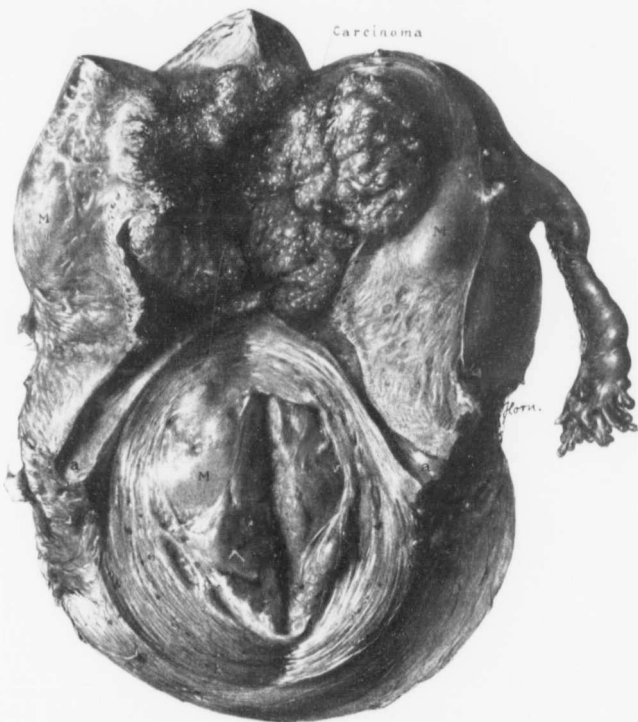


FIG. 182.—A LARGE MYOMA OF THE CERVIX; ADENOCARCINOMA OF THE BODY OF THE UTERUS. (1 nat. size.)

Gyn. No. 9141. Path. No. 5312. Behind the cervix is a globular myomatous nodule, 7 cm. in diameter. Smaller subperitoneal and interstitial myomata are also seen. The uterine cavity is filled with a carcinomatous growth which, in places, reaches 2 cm. in thickness. Over the right uterine horn was an irregular, slightly raised, whitish area, with puckered margins, and closely resembling a patch of lupus where healing had taken place. This represented an extension of the carcinoma to the peritoneal surface of the uterus by continuity.

Gyn. No. 9012. Path. No. 5180.

Myomatous uterus; adenocarcinoma of the body; double hydrosalpinx; ovarian cyst on the right side; tubo-ovarian abscess on the left side.

M. S., white, aged fifty, married. Admitted August 26; discharged October 10, 1901. During the last eighteen months the menses have been irregular and profuse; recently there has been bleeding for six or seven weeks at a time. During this period the patient passed a hard body, probably a submucous myoma. She has had one miscarriage. Six years ago she was told that her uterus was enlarged. She can feel something shifting about in the abdomen; this is particularly noticeable when she moves around.

Operation. Hysteromyomectomy; radical cure of hernia; drainage of tubo-ovarian abscess through the abdomen.

A long abdominal incision was made, and a small umbilical hernia excised. Much difficulty was experienced on account of a tubo-ovarian abscess on the left side, which had to be drained. The left tubo-ovarian mass was very closely associated with the intestines, and the omentum was thickened, pale, and bled very freely. Resting upon the ovarian cyst was a large myomatous uterus. Later, the perineum was repaired, and the patient left the hospital very much improved.

Path. No. 5180. The specimen comprises an enlarged uterus, a cyst of the ovary, and a portion of a small ovarian abscess. The uterus, which is irregular and pear-shaped, measures 16 x 10 x 11 cm. Its surface presents irregular prominences, corresponding to interstitial myomata. On section, a large, partially subperitoneal myoma, 9 cm. in diameter, is found occupying the fundus, and to one side of this is an interstitial nodule 6 cm. in diameter. This, on section, appears to be cystic, consisting of fibrillated material with translucent areas in its meshes. The uterine cavity is 5 x 5.4 x 3.5 cm. The lower portion is lined with a slightly injected, fairly normal looking mucosa. The upper portion, however, is occupied by an exceedingly friable papillary growth, the papillae of which are long and finger-like. The advancing margin of the growth is fairly well defined; it shows a rounded but somewhat irregular outline.

The right ovary has been converted into a thin-walled cyst, 18 x 15 x 15 cm., covered with numerous tags of adhesions. It is pale reddish in color, and by transmitted light is found to be unilocular; it contains a pale yellowish fluid. An ovarian abscess is present on the left side.

Sections from the body of the uterus show that the growth is an adenocarcinoma of the fundus.

Gyn. No. 10085. Path. No. 6275.

Subperitoneal, interstitial, and submucous myomata; advanced adenocarcinoma, involving both the body and the cervix (Fig. 183).

P. D., white, single, aged fifty-two. Admitted November 13; discharged December 17, 1902. The patient first noticed, about two years ago, that her periods, instead of gradually stopping, were so frequent that she could not tell whether she was having a continuous flow or when the next period began. Hemoglobin, 55 per cent.

Operation, hysterectomy. The lower abdomen is distended with a multinodular hard mass which reaches one-third of the distance from the symphysis to the umbilicus; it is somewhat movable.

November 17, 1902: An incision exposed what was apparently a myoma.

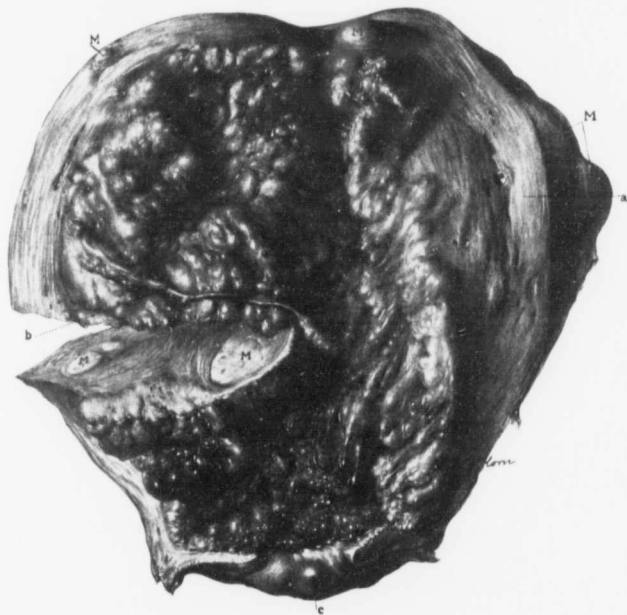

FIG. 181.—SUBLIGONAL, INTERSTITIAL, AND SUBMUCOUS MYOMATA; ADVANCED ADENOCARCINOMA INVOLVING CERVIX AND BODY. ($\frac{1}{2}$ nat. size.)

Gyn. No. 10085. Path. No. 6275. The uterus is much enlarged, measuring 15 cm. in length, 12 cm. in breadth and 11 cm. in its anteroposterior diameter. Scattered throughout it are numerous myomata, subperitoneal, interstitial, and submucous (M). The cervix is intact, as seen at *c*, where there is a cystic gland. The entire uterine cavity is lined with a carcinomatous growth. The tree-like projections are in evidence near the cervix, but in the upper part of the cavity the growth is more polypoid in form. At *b* is a delicate stem of the growth several centimeters in length, and terminating in a club-like extremity. *a* indicates the normal musculature of the uterus.

Simple bimanual examination in this case was strongly suggestive of a normal myomatous uterus. Had carcinoma been suspected, under no circumstances would bisection have been commenced.

Bisection was begun. After the first cut there was a gush of apparently carcinomatous material from the anterior wall of the uterus. The uterus was removed in its entirety at once. The patient made an uneventful recovery and was discharged on the thirty-second day.

Path. No. 6275. The specimen consists of the uterus and normal appendages. The uterus is globular, about 15 x 12 x 11 cm. Anteriorly and posteriorly it is smooth. On the anterior surface is a smooth myoma, 1.5 cm. in diameter. On the posterior surface several smaller ones are seen. The vaginal portion of the cervix looks normal. On section, it is found that portions of the cervix and body have been replaced by a new-growth (Fig. 183). The cavity of the uterus is 12 cm. in length. The growth presents a very shaggy appearance, and consists of many tree-like processes, little buds, or of small papillary projections. The individual projections vary from 1 to 8 mm. in diameter. The growth projects into the cavity for from 2 to 5 cm. The uterine walls are only slightly encroached upon. Projecting a little way into the cavity from the posterior wall is a submucous myoma fully 3 cm. in diameter. Numerous other myomata are scattered throughout the uterine walls, which are considerably thickened.

Histologic examination shows that the growth is essentially of a glandular character, and that it is an adenocarcinoma.

The general contour of the growth strongly suggests myoma. This view is supported by the fact that there are somewhat isolated myomatous nodules, and one might very readily, as was done here, make a diagnosis of myoma. Even with the abdomen open the operator felt sure that he was dealing with a myomatous uterus. Examination of scrapings in this case would, however, render the diagnosis easy.

Gyn. No. 9934. Path. No. 6127.

Uterine myomata; adenocarcinoma of the body.

J. S. B., white, aged fifty, married. Admitted September 29; discharged November 1, 1902. One aunt died of a uterine tumor, aged fifty-five. There is tuberculosis on the paternal side. The patient has been married twenty-eight years, but has never been pregnant. During the past two years the menstrual flow has gradually increased; it has been very copious and frequent for the last six weeks, and the patient has had severe hemorrhages. Apart from a progressive weakness due to loss of blood, her health has been normal. Hemoglobin, 55 per cent.

Operation. Hysteromyectomy with amputation through the cervix. The patient was discharged November 1, 1902.

Path. No. 6127. The specimen consists of an enlarged uterus, amputated through the cervix. The appendages are intact. Extending from the posterior wall close to the cervix is a subperitoneal myoma, 7 cm. in diameter. On section, it shows a typical hyaline change. The body of the uterus is considerably enlarged, and on section is found to be occupied by a moderately large, cauliflower-like growth which extends into the cavity and involves the uterine wall for about one-half its thickness. The endometrium lining the lower portion of the uterine cavity is quite smooth.

The growth on histologic examination proves to be a typical adenocarcinoma.

AN EXCEPTIONALLY EARLY ADENOCARCINOMA OF THE BODY OF THE UTERUS, ASSOCIATED WITH A LARGE MYOMATOUS UTERUS.

The following case is only one example of the interesting conditions that may be detected by a careful and routine examination of all specimens coming from the operating-room. The multinodular myomatous uterus measured 25 cm. in diameter.

On histologic examination we detected one of the earliest carcinomata of the body of the uterus on record (Fig. 184). The growth could not possibly be seen macroscopically on account of its small size, and because it was flush with the surface of the mucosa, not projecting from the surface. It had not yet penetrated the muscle, and was surrounded on all sides by normal mucosa. The general pattern of the glands left absolutely no doubt that we were dealing with a commencing carcinoma of the body.

Gyn. No. 3113. Path. No. 487.

A. V. G., white, aged fifty-two. Admitted October 16; discharged December 6, 1894. The other interesting features in this case are reported in the chapter on Sarcoma (p. 247).

Path. No. 487. The specimen consists of a large globular tumor involving the upper portion of the uterus. It is approximately circular, and has a diameter of 25 cm. The uterine cavity itself is 6 cm. long, and about 1 cm. in diameter. The mucosa is yellowish in color, and at the cervix is somewhat hemorrhagic. It is 1 mm. in thickness.

Histologic Examination.—Some of the cervical glands are dilated. The uterine mucosa in most places is atrophic. The surface epithelium is intact, the glands are few in number, dilated, small, and circular on cross-section; some of them run parallel to the surface. The surface of the mucosa shows considerable round-celled infiltration, and non-striped muscle-fibers are seen passing up into the mucosa nearly as far as the uterine cavity. Springing from the mucosa are three polypi, one situated near the internal os, and having a broad base, a second 1.5 cm. from the fundus, presenting a pedunculated appearance, a third situated at the fundus. These polypi are covered with cylindrical epithelium and have numerous glands scattered throughout them. A section taken at one point in the region of the polyp gave the picture seen in Fig. 184. Here we have normal mucosa on both sides, and over a very small area, probably not more than 1 to 2 mm. in diameter, the glands are so changed that they leave no doubt as to the malignancy of the growth. The surface epithelium is becoming thicker; the cells stain more palely. The epithelium is several layers in thickness, and the glands present the typical picture of a mucosa undergoing a carcinomatous change.

It is particularly interesting in this case to note that there were also very suspicious changes in the cells of the myomata. The muscle-fibers contained

large oval and round, vesicular nuclei (Fig. 162, p. 248), suggestive in a slight degree of a sarcomatous transformation of the myoma.

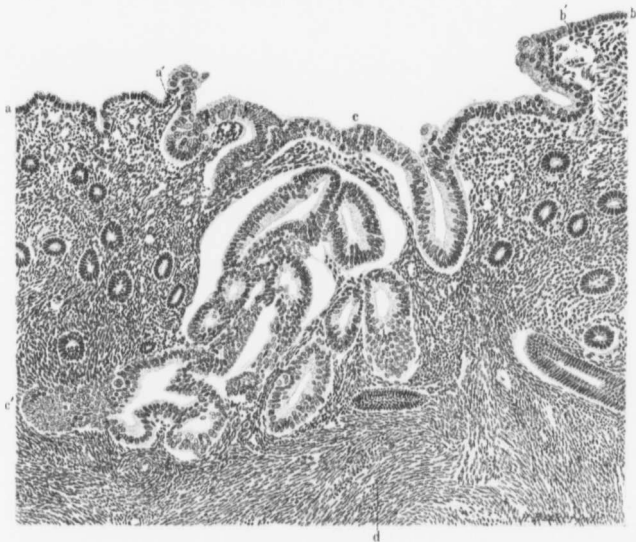

FIG. 184.—AN ADENOCARCINOMA OF THE BODY OF THE UTERUS, SO SMALL THAT IT COULD NOT BE RECOGNIZED EXCEPT WITH THE AID OF THE MICROSCOPE. ($\times 145$ -diam.)

Gyn. No. 3113. Path. No. 487. This picture was accidentally discovered during our routine examination of the mucosa. The mucosa to the left and right of the field is normal. The surface epithelium between *a* and *a'* and between *b* and *b'* is also normal, but between *a'* and *b'* it is several layers in thickness and stains more faintly. The general gland pattern in the central area, extending from *c* to *c'*, is totally different from that of the normal and surrounding glands, and the epithelium has proliferated to a marked degree. The epithelium at *a'* also shows signs of proliferation and sends out a small bud. *d* is the normal uterine muscle. This is the earliest carcinoma of the body of the uterus we have ever seen, or of which we can find any record in the literature.

SECONDARY CARCINOMA OF THE UTERUS, ASSOCIATED WITH UTERINE MYOMATA.

Two cases of this character have come under our observation, and in both instances the primary carcinoma was of ovarian origin.

In Case 7992 both ovaries were carcinomatous and metastases were found in the Fallopian tubes and uterus. The uterus contained two small subperitoneal and several small interstitial myomata.

In Case 5528, five months after removal of both ovaries, on account of a carcinoma, a complete hysterectomy became necessary. The uterus was 11 x 12 x 8 cm., and contained myomatous nodules, varying from 1 to 6 cm. in diameter. Attached to the right side of the uterus was a ragged, friable carcinomatous mass,

8 cm. in diameter. Occupying the anterior uterine wall was a carcinomatous mass 2 x 4 cm. This was directly continuous with the uterine mucosa and was soft and slightly friable. The mucosa itself was perfectly smooth. It is evident that in this case the carcinomatous nature of the ovarian growth was not clear, otherwise the uterus would have been removed with the ovarian growths at the first operation.

CHAPTER XVII.

THE CONDITION OF THE UTERINE MUCOSA IN CASES OF MYOMA.

In most of our cases when the uterus has been removed, supravaginal amputation has been employed. As a result, only rarely have we been able to ascertain the histologic appearances of the vaginal portion of the cervix.

In nearly all the cases in which the uterus was removed we carefully opened the uterine cavity and studied the appearances macroscopically and histologically. Pieces of mucosa were removed from various portions of the cavity, especial attention being given to any area suggesting the least pathologic change. It will readily be understood that a histologic examination of the mucosa from all parts of the cavity in over 1000 cases would be out of the question, and, therefore, the pathologic changes in a few cases have undoubtedly been overlooked. The findings, on the whole, however, are relatively accurate.

The mucosa of the uterus is naturally divided into two main kinds—that from the cervix and that lining the uterine cavity. They will, therefore, be considered separately.

CHANGES IN THE CERVICAL MUCOSA.

Edema.

Hypertrophy.

Atrophy.

Dilatation of the cervical glands.

Cervical polypi.

Unfolding of the cervical glands.

Cervical endometritis.

Suspicious changes in the cervical mucosa.

Carcinoma of the cervix.

Edema.—In only one case was edema of the mucosa noted. Here the uterus had been partially inverted by a submucous myoma.

Hypertrophy.—Marked increase in size of the cervix was noted four times, and on referring to p. 441 it will be seen that in each of these cases there was prolapse of the uterus. The mucosa usually showed marked thickening of the squamous epithelium of the vaginal portion of the cervix, and the papillae projecting into the squamous epithelium were much longer than usual and showed marked branching.

Atrophy.—Where partially submucous cervical myomata exist, the cervix is occasionally so unfolded that little of it remains. The cervical mucosa is put

on marked tension and, on account of the stretching, becomes much thinner than usual. The atrophy is more apparent than real, the appearance being due to a thinning out of the mucosa, which now has to cover a wider area.

Dilatation of the Cervical Glands.—Enlarged glands are very common in the cervix, and are often recognized as slightly raised, circular, translucent areas. In our experience dilated glands are not more frequent in myoma cases than in those in which no tumor exists.

In Case 3349 some of the cervical glands reached 5 mm. in diameter.

In Case 3038 they reached 6 mm. in diameter, and in Case 3493 there was a

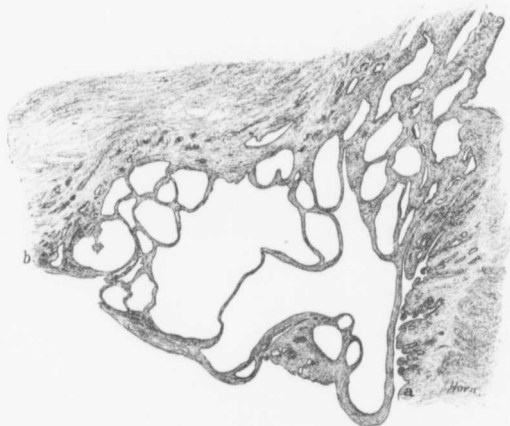

FIG. 185.—MARKED DILATATION OF THE CERVICAL GLANDS, WITH A TENDENCY TOWARD THE FORMATION OF A POLYP. ($\times 5$ diam.)

Gyb. No. 3493. Path. No. 715. The myomatous uterus was 16 x 16 x 22 cm. The section is from the cervix. On the right, at a, the glands are normal, and on the left, at b, the mucosa is of the usual thickness, but between these two points the glands are markedly dilated, some being spheric, others oblong and very irregular. The gland epithelium is in places normal, at other points slightly flattened.

marked tendency toward dilatation of the glands (Fig. 185). One gland reached 0.5 x 1.5 cm.

The dilated glands are usually spheric, but may be irregular. The gland contents, as a rule, are viscid and semitranslucent; occasionally they are whitish yellow or opaque, owing to an abundance of exfoliated epithelium. Their epithelium may be high cylindrical, or considerably flattened.

Cervical Polypi.—Polypi of the cervical mucosa, in our experience, have been comparatively rare in myoma cases. In some cases they were found near the internal os; in others they were near the external os, or projected slightly into

the vagina. They were usually single, but occasionally several were present, as in C. H. I. No. 768.

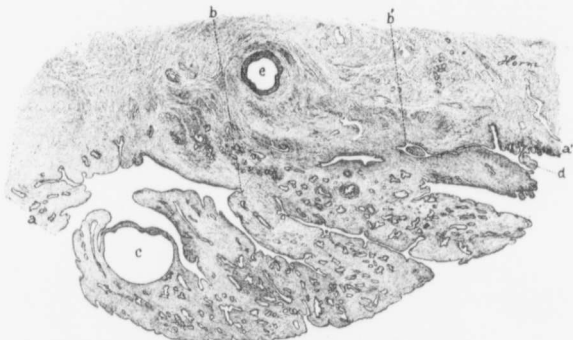


FIG. 186.—A CERVICAL POLYP. ($\times 8$ diam.)

Gyn. No. 6169. Path. No. 2426. The uterus contained a small submucous myoma. The endometrium presented a wavy, polypoid appearance, and polypi were found in the cervix.

At *a* and *e'* we have a normal mucosa. Projecting from the mucosa is a polyp attached by a broad base, the confines of which are indicated by *b* and *b'*. The polyp consists of normal cervical mucosa. A dilated gland is seen at *c*. *d* is a very small polyp. At *e*, a dilated gland is seen deep in the stroma of the cervix.

The size of the uterus or the situation of the myomata seemed to have little or no influence on the development of the polypi, as they occurred just as frequently when the myomata were small and when no submucous nodules existed.

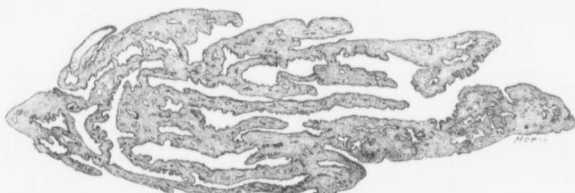


FIG. 187.—A CERVICAL POLYP. ($\times 6$ diam.)

Gyn. No. 6169. Path. No. 2426. The uterus contained a small submucous myoma. The cervix contained the polyp depicted in Fig. 186.

This polyp is made up chiefly of long, finger-like outgrowths of cervical mucosa. The stroma resembles that of a normal cervix, and the projections are covered with the characteristic high cylindrical epithelium of the cervix. The polyp was attached to the cervical mucosa by a delicate pedicle, indicated on the left.

On histologic examination some of the polypi closely resembled the normal cervical mucosa (Fig. 186) and were in reality nothing more than small areas

of mucous membrane that had been extruded and partially nipped off. In other polypi the process of extrusion had advanced further. The polypi were composed of long narrow tongues of mucosa (Fig. 187), and the attachment to the parent mucosa was very slender.

In San. No. 1872 (Path. No. 8433) the glands of the polypi were uniformly and markedly dilated, and the picture resembled closely that of a thyroid gland.

A Rare Form of Cervical Polyp.—In the following case, in which a small submucous myoma was removed, a large cervical polyp was also taken

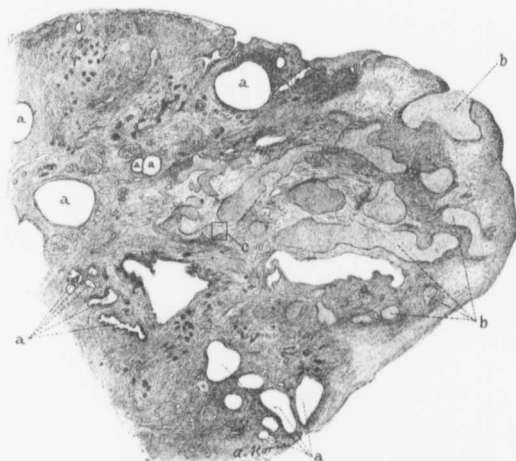

FIG. 188.—A RARE FORM OF CERVICAL POLYP. ($\times 6$ diam.)

Gyn. No. 7615. Path. No. 3879. This is a small portion of a cervical polyp, 1.5 x 3.5 x 4.5 cm. The polyp was mottled in appearance and contained cyst-like spaces, some minute, others reaching 3 mm. in size. The glands are indicated by *a*. Some are of the normal size, others much dilated and spheric.

Scattered throughout the polyp are many pale-staining and solid areas (*b*), which, under the lower power bore some resemblance to cartilage. For the finer details of these areas see Fig. 189, in which the area indicated by *c* is magnified.

away. The histologic appearances of the polyp are so unusual that we give them in detail.

Gyn. No. 7615. Path. No. 3879. The patient was fifty-one years of age, and the operation consisted in the removal of two polypoid masses from the cavity of the uterus. The specimen comprises two small tumor masses. The larger of these is 4.5 x 3.5 x 1.5 cm., presents a lobulated appearance, and has a mottled surface, with areas of dark green, gray, or bright red. On section, it is found to contain cyst-like spaces, varying from a pinpoint to 2 or 3 mm. in diameter.

This growth is a polyp. The small tumor measures 1.5 x 2.5 cm., and consists of myomatous tissue.

Sections from the large and cystic polyp show that the surface is devoid of epithelium, and that, to a great extent, the superficial portion consists of granulation tissue on the surface of which is fibrin containing polymorphonuclear leukocytes in its meshes. The tissue immediately beneath the granulation zone shows much small-round-celled infiltration. The stroma of the polyp resembles that ordinarily found in the cervical mucosa, and penetrating it in all directions are cervical glands. These are more convoluted than usual, and contain many delicate, teat-like ingrowths. The epithelium lining most of these glands still preserves its normal type, and in some places the cells are flattened and the nuclei stain deeply. Occasionally there is proliferation of the gland epithelium,

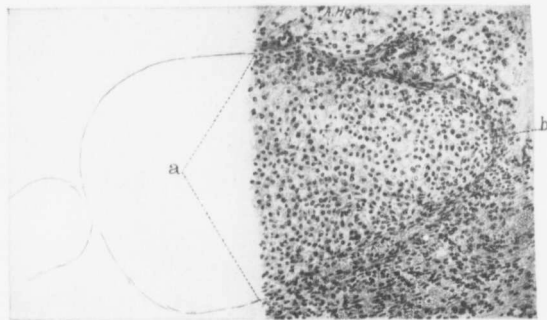


FIG. 189.—A RARE FORM OF CERVICAL POLYP. (X 120 diam.)

Gyb. No. 7615. Path. No. 3879. The picture represents an enlargement of the area *c* in Fig. 188. The stroma of the polyp consists of ordinary cervical stroma, but scattered throughout it is much blood. The cells of the pale-staining area, the confines of which are indicated by *a* and *b*, consist of polygonal cells having round or oval nuclei. The protoplasm of these cells took the hematoxylin stain faintly.

several layers of cells being present. Some of the glands are much dilated, producing the cysts noted macroscopically. The epithelium of the dilated glands is much flattened, and at some points has disappeared. Scattered throughout the stroma are large oval or irregular, deeply staining areas, under the low power strongly suggesting cartilage (Fig. 188), but when examined with the high power, differing much therefrom (Fig. 189). The individual cells of these areas are polygonal in shape, have oval or round, uniformly staining nuclei, and a protoplasm that takes the hematoxylin stain faintly. These areas were at first sight thought to represent broken-down cervical glands, but on closer examination they resemble more a mucoid transformation of the stroma, although it is difficult to explain the sharp line of demarcation between them and the stroma. We have never seen another polyp presenting these peculiarities.

Unfolding of the Cervical Glands.—In those cases in which the cervical canal is much drawn out or the mucosa of the cervix is put on great tension by a large submucous myoma, the glands may literally unfold. The gland epithelium then forms part of the lining of the cervical canal. Although the squamous epithelium usually ends at or near the external os, it may extend far up into the canal. If such is the case, when the unfolding of the glands takes place, the epithelial lining will consist of two types—squamous epithelium, alternating with the high cylindrical variety. Such a condition we have noted on several occasions.

Cervical Endometritis.—Inflammation of the cervical mucosa is relatively frequent when a sloughing submucous myoma or a carcinoma of the uterus exists, but is rarely found under other circumstances, even if there be an old inflammatory process in the adnexa.

In Case 3199, in which the cervical glands showed proliferation, there was a marked small-round-celled infiltration, but the surface epithelium was intact.

In Case 12221 there was likewise new gland-formation in the cervix. In places the surface epithelium was intact, but at other points it had been replaced by granulation tissue.

In Case 2800 (Path. No. 312) the omentum was adherent to the large multinodular uterus over a wide area, and the appendages were bound up in adhesions. The cervical mucosa presented a branching, arborescent appearance. The surface epithelium was intact, and covered with polymorphonuclear leukocytes, while the underlying stroma showed marked small-round-celled and polymorphonuclear infiltration.

In Case 12139 the woman had been in the hospital seven years before, a pelvic abscess being evacuated through the vagina at that time. When the abdomen was opened, the omentum was found glued to the myomatous uterus, and general pelvic adhesions were encountered. Sections from the cervix showed that the surface was covered with polymorphonuclear leukocytes. The surface epithelium was intact, but the underlying stroma showed much small-round-celled infiltration.

Suspicious Changes in the Cervical Mucosa.—In at least five of our myoma cases sections from the cervix have yielded rather suspicious histologic pictures when macroscopically nothing abnormal could be detected.

The uterus in Case 3418 (Path. No. 661) was the seat of a diffuse adenomyoma of the posterior wall. The cervical glands were in some places normal, but here and there had proliferated. The epithelium lining the cervical canal was intact.

In Case 3199 (Path. No. 524) the multinodular myomatous uterus reached to the umbilicus. The cervical epithelium was intact, but the glands were smaller than usual, and appeared to have proliferated. The newly formed glands were small and had a lining of cuboid epithelium. They did not appear to extend far into the stroma, but the latter showed marked infiltration, with small round cells.

In Case 3349 (Path. No. 610) the nodular myomatous uterus measured 10 x 12 x 16 cm. Some of the cervical glands were dilated. In close proximity to one of the glands was an aggregation of minute glands, some of which were branching. They were lined with cuboid ciliated epithelium, and had round or oval nuclei situated near the center of the cells. The picture instantly suggested commencing adenocarcinoma.

The myomatous uterus in Case 12221 (Path. No. 8832) measured 6 x 7 x 10 cm. The cervical glands had proliferated, forming many new and smaller ones. The cell proliferation had in places advanced so far that solid nests had been formed. These resembled masses of squamous epithelium. At other points the surface epithelium had been replaced by typical granulation tissue.

In one of our cases we found very suspicious changes in the uterine mucosa, changes which strongly indicated that a malignant growth was starting in the mucosa. In Case 3133 the abdomen was filled with a myomatous tumor, 36 x 32 x 32 cm. On histologic examination some very interesting changes were found. Fig. 190 represents a portion of a gland in the cervix. The epithelium on one side is normal; on the other side the nuclei are increasing in size, and there is a large circular nucleus projecting into the lumen. A section from the same region shows more marked changes (Fig. 191). Here and there through the surface are large masses of protoplasm which are totally devoid of nuclei, and near the center of the field is a nucleus at least ten times as large as the surrounding ones, staining more deeply, and showing many hyaline droplets. That this large cell is distinctly abnormal is clearly indicated by the zone of small round cells which partially wall it off from the uterine tissue. Other sections show that the surface epithelium has a decided tendency to form finger-like out-growths (Fig. 192) or slender projections composed entirely of epithelium. At *d* the nucleus of the epithelial cell is becoming larger and stains more deeply. The entire picture strongly suggests a commencing carcinoma of the uterus.

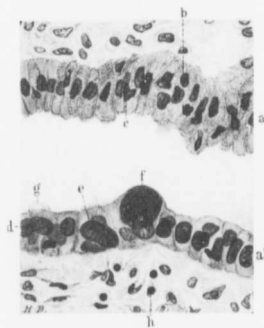


FIG. 190.—SUSPICIOUS EPITHELIAL CHANGES IN A GLAND FROM THE CERVIX, ASSOCIATED WITH A LARGE MYOMATOUS UTERUS. ($\times 360$ diam.)

Gyb. No. 3133. Path. No. 494. The section shows a portion of a gland; *a* and *a'* indicate opposite walls; *b* and *c* represent irregular nuclei, both of which, however, are of normal size. The nuclei *d* and *e* are much enlarged, and the nucleus *f* even more so. Normally, nuclei of such a size and character never exist in the epithelium, and their presence strongly suggests a malignant tendency in the uterine mucosa. (For other changes see Figs. 191 and 192.) At several points cilia are demonstrable; they are particularly well seen at *g*. The underlying stroma is practically normal, but a few small round cells are wandering in at *h*.

Gyn. No. 3133. Path. No. 494.

A large myomatous uterus, with changes in the mucosa very suggestive of a commencing carcinoma.

M. E. R., aged fifty, white, married. Admitted October 24; discharged November 24, 1894. A supravaginal hysterectomy was performed. Recovery was uninterrupted.

Path. No. 494. The specimen consists of a greatly enlarged uterus, with the tubes and ovaries intact. The uterus is pear-shaped and measures 36 x 32 x 32 cm. The upper surface of the tumor is covered with peritoneum and is smooth and glistening. The lower two-thirds, both anteriorly and posteriorly, are denuded of peritoneum. Projecting through the cervical canal is a small uterine polyp. The portion of the uterine cavity present is 31 cm. long, and

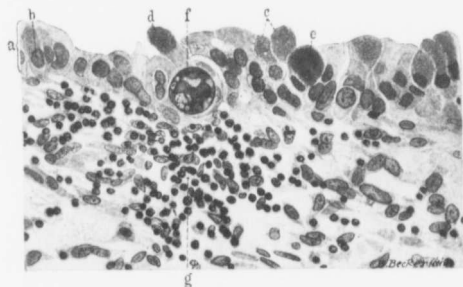


FIG. 191.—SUSPICIOUS EPITHELIAL CHANGES IN THE MUCOSA OF THE CERVIX, FROM A LARGE MYOMATOUS UTERUS. (X 300 diam.)

GYN. NO. 3133. PATH. NO. 494. *a* represents the normal thickness of the surface epithelium, and *b* shows a nucleus of normal size. *c*, *d*, and *e* are granular masses of protoplasm of various sizes. They resemble miniature "puff balls," and are devoid of nuclei.

f is an exceptionally large nucleus containing aggregations of chromatin and large and small hyaline droplets. This nucleus is strongly suggestive of an early malignant change. Nature evidently fears trouble, as she is partially walloffing it off with many small round cells (*g*).

varies from 9 to 14 cm. in breadth. The mucosa is whitish yellow in color, smooth and glistening, and apparently very thin. Sixteen centimeters from the fundus is a polyp 3.5 cm. long, 1 cm. broad at the base, and 2 mm. in thickness; it is attached by a very delicate pedicle. In the posterior wall, about 12 cm. from the fundus, is a yellowish area, 3 cm. in diameter. From this mucus mixed with blood oozes into the uterine cavity. The cavity from which the mucus can be squeezed has smooth walls.

On histologic examination the entire uterine mucosa is markedly atrophied, and seems to consist of one layer of epithelium, resting almost directly upon the uterine muscle. The surface of the mucosa in the cervical portion is comparatively smooth, but near the fundus it becomes somewhat convoluted. The

epithelium lining the lower part of the uterus is alternating, for a certain area being of the cervical type, then of the body type, and then again of the cervical. The chief interest centers in the suspicious pictures noted in Figs. 190, 191, and 192.

It will be noted that in each of these five cases the picture was suggestive

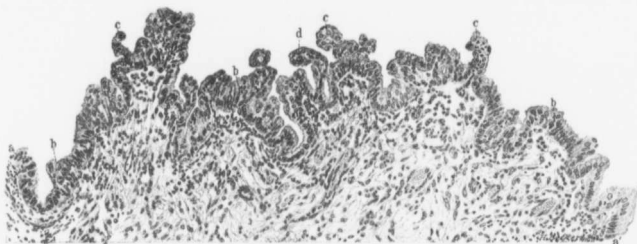


FIG. 192.—SUSPICIOUS PROLIFERATION OF THE CYLINDRIC SURFACE EPITHELIUM OF THE CERVIX, ASSOCIATED WITH A LARGE MYOMATOUS UTERUS. ($\times 100$ -diam.)

Gyn. No. 3133. Path. No. 494. a and a' indicate normal surface epithelium. At b the epithelium is several layers thick, and at c forms distinct outgrowths, totally devoid of a supporting stroma. This condition in itself is strongly suggestive of a malignant change. At d is an enlarged and more deeply staining nucleus. Scattered among the epithelial cells, and also in the stroma, are small round cells and polymorphonuclear leukocytes.

of a beginning carcinoma, but in no instance was the evidence conclusive. In two of the five cases an inflammation of the cervix was present.

Carcinoma of the Cervix.—From p. 262 it will be seen that in eighteen cases carcinoma of the cervix was associated with uterine myomata. As each of the cases is described in detail in another portion of the book, further reference to them here is unnecessary.

THE UTERINE CAVITY IN MYOMA CASES.

Size and shape of the uterine cavity.

Partial obliteration of the uterine cavity.

Blood in the uterine cavity.

Pus in the uterine cavity.

SIZE AND SHAPE OF THE UTERINE CAVITY WHEN MYOMATA ARE PRESENT.

The size and shape of the uterine cavity depend in a great measure on the size and situation of the uterine tumors. If a myoma develops in the upper part of the fundus, the cavity may remain normal in size or be very small (Fig. 194). If the tumor is intraligamentary, it may reach very large proportions without causing the cavity to increase in size. On the other hand, when a myoma remains interstitial and reaches large proportions, with the gradual enlargement of the tumor there is a corresponding lengthening and often broadening of the

uterine cavity. The cavity may retain its normal shape, but if invaded by submucous myomata, it becomes greatly distorted and may be very tortuous. In Fig. 193 we have an example of a large myomatous uterus with a tortuous but slit-like cavity.

The following cases give a fair idea of the various shapes and sizes that the uterine cavity may assume.

In Case 2919 (Path. No. 380) the multinodular myomatous uterus measured 11 x 13 x 14 cm. The myomata were interstitial and subperitoneal. The cavity of the uterus was scarcely more than 1 cm. in length. It is difficult to account for such a small cavity in a patient only thirty-four years of age. The mucosa, however, was fully 1 cm. thick.

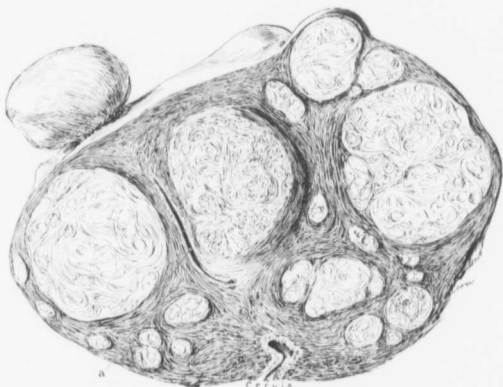


FIG. 193.—A SLIT-LIKE TORTUOUS UTERINE CAVITY. (1 nat. size.)

Path. No. 2538. Scattered throughout the uterine walls are many interstitial myomata, and projecting from the surface are several others. The upper part of the cervix is readily recognized in the lower part of the picture. The upper part of the uterine cavity appears as the narrow chink *a*.

In Case 12086 (Path. No. 8727) the myomatous uterus was 22 cm. in breadth and 12 cm. in its anteroposterior diameter. The uterine cavity formed a cavernous space, 5 x 6 cm. Its walls could not drop together, as in Fig. 193, because the uterine cavity was literally paved with myomata, whose presence rendered it a non-collapsible space.

The uterus in Case 5734 (Path. No. 2034) was much enlarged, being converted into a lobulated tumor 14 x 19 x 27 cm. The great increase in size was due chiefly to the presence of three subperitoneal myomata, averaging 11 cm. in diameter. The uterine cavity was narrow and tortuous, approximately 10 cm. long, and averaging 1.5 cm. in diameter.

In Case 3491 (Path. No. 713) the globular uterus measured 16 cm. in diameter. Occupying the posterior wall, and projecting into the cavity, was a myoma 12 cm. in diameter. The uterine cavity was 13 cm. long and 9 cm. broad in its upper portion.

The globular uterus in Case 5617 (Path. No. 1962) was 22 cm. in diameter, and resembled a pregnant organ. Situated in the anterior wall was a myoma 17 cm. in diameter. The uterine cavity was 22 cm. in length and 13 cm. broad at the fundus.

One of the largest uterine cavities we have ever seen was furnished by Case 3133 (Path. No. 494). The uterus was pear-shaped, measuring 32 x 32 x 36 cm.

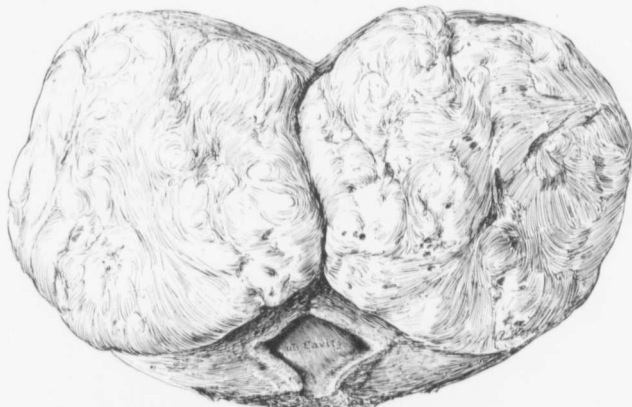


FIG. 194.—A VERY SMALL UTERINE CAVITY WITH A LARGE MYOMA OF THE FUNDUS. ($\frac{1}{4}$ nat. size.)
GYN. No. 10916. Path. No. 7162. The globular myoma, which was 11 cm. in diameter, has been split in two.
The uterine cavity was not over 2 cm. in length. The mucosa presented the usual appearance.

The great increase in size was due to the presence of a myoma occupying the anterior wall. The uterine cavity was 31 cm. long, and varied from 9 to 14 cm. in breadth. Situated in the posterior wall, about 12 cm. from the fundus, was a yellowish area, 3 cm. in diameter. From this mucus mixed with blood escaped into the uterine cavity. This secondary cavity, on histologic examination, was found to be lined with one layer of epithelium, and seemed to be a markedly dilated gland.

The foregoing examples are sufficient to show that the uterine cavity may assume almost any size and shape, and, further, that the alteration is dependent entirely on the size and position of the myomata.

PARTIAL OBLITERATION OF THE UTERINE CAVITY.

In a few of the cases of submucous myomata the mucosa from the anterior wall is so firmly pressed against that of the posterior wall that the walls become adherent

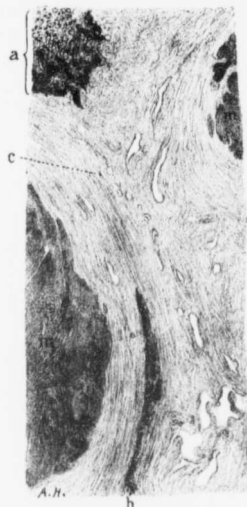


FIG. 195.—PARTIAL OBLITERATION OF THE UTERINE CAVITY WITH DISAPPEARANCE OF THE MUCOSA. ($\times 4$ diam.)

CASE No. 3008. Path. No. 435. In this case the uterine cavity was partially obliterated by a submucous nodule, situated in the anterior wall, becoming adherent to a similar nodule in the posterior wall, thus giving the cavity an X-shaped contour.

The section is taken from the point of coalescence. Pressing in from either side are myomata, the edges of which are indicated by *m*. *a*, is the normal mucosa from the upper part of the cavity. At *c*, where most pressure has been exerted, all trace of mucosa has disappeared. In the lower part of the field, as indicated by *b*, the mucous membrane is again present, but is markedly compressed. The clear, elongate, and irregular spaces are blood-vessels.

and the mucosa disappears from this area. Thus in Case 3008 (Path. No. 435), in which the multinodular myomatous uterus filled the pelvis, the uterine cavity, which was 6 cm. in length, had become partially obliterated by a submucous nodule, situated in the anterior wall, becoming adherent to a similar nodule in the posterior wall, thus giving the cavity an X-shaped contour. The uterine mucosa, on the whole, is normal, but toward the point at which the uterine cavity is partially obliterated the mucosa becomes somewhat atrophic, and that of the anterior fuses with that of the posterior wall. The glands gradually diminish in number, and then entirely disappear, leaving only a small amount of stroma (Fig. 195). This finally disappears, and the muscle from the anterior wall becomes continuous with that from the posterior wall. At the point of junction are numerous blood-vessels, and the muscle shows small-round-celled infiltration. On passing still further toward the upper part of the cavity the mucosa gradually reappears, and near the top of the cavity has regained its normal appearance.

In Case 3111 (Path. No. 479), the multinodular myomatous uterus was 9 x 10 x 9 cm. The uterine cavity was 5 cm. in length. The mucosa covering the small submucous myoma in the anterior wall had become adherent to the corresponding mucosa of the posterior wall, thus partially obliterating the cavity. On histologic examination it was found that where the nodule projected into the uterine cavity the mucosa suddenly became compressed (Fig. 196), that from the anterior wall being directly continuous with that from the posterior wall. The mucosa became still more atrophic, and over the most prominent part of the nodule entirely disappeared.

Here the muscle from the posterior wall was directly continuous with that covering the submucous myoma. The line of fusion could still be recognized by a moderate infiltration with small round cells.*

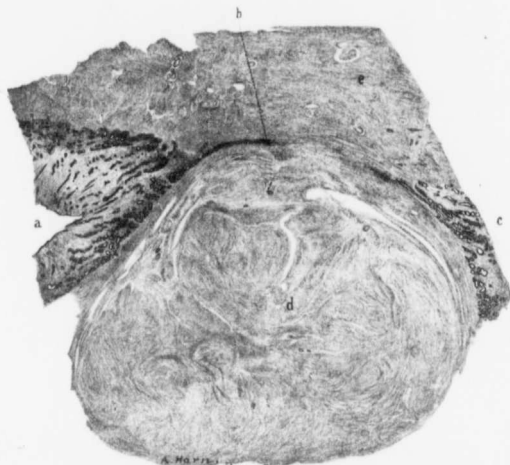


FIG. 196.—PARTIAL OBLITERATION OF THE UTERINE CAVITY CAUSED BY A SUBMUCOUS MYOMA. ($\times 6$ diam.)

Gyn. No. 3111. Path. No. 479. The uterus measured $9 \times 10 \times 9$ cm., and contained interstitial and subperitoneal myomata. Situated in the anterior wall, just beneath the mucosa, was a myoma, 1.5 cm. in diameter. The myoma had become adherent to the muscle of the posterior wall, thus partially obliterating the uterine cavity.

At a the uterine mucosa is normal. It gradually becomes thinner, and at b entirely disappears. This is due to the fact that the submucous myoma of the anterior wall has pressed so firmly on the posterior wall that the two have united. At c, where little or no pressure has existed, the normal mucosa is again found.

Coalescence of the uterine walls rarely occurs, but is not infrequently simulated when submucous myomata greatly narrow the lumen of the cavity. In such cases, however, they have merely pushed the mucosa in front of them without causing fusion with the mucosa of the opposite walls.

BLOOD IN THE UTERINE CAVITY.

As a rule, when the cavity of the uterus is opened, little or no blood is found, but occasionally, as in Case 8738, the cavity will be found partially or completely filled with blood. In this case it was full of tarry masses and recently coagulated blood.

In Fig. 197 we have a large submucous myoma filling the entire uterine cavity

* Partial obliteration of the uterine cavity, due to coalescence of the uterine walls, was also noted in Cases 2006 (Path. No. 196), 2713 (Path. No. 256), 4314 (Path. No. 1152), and 3319 (Path. No. 592). In the last case, however, there was tuberculosis of the endometrium.

and also dilating the cervical canal. In the upper part of the cavity the surface is covered with a large clot.

If blood is present in the cavity, the amount will depend upon the copiousness of the flow and the ease or difficulty with which it can escape from the cervix.

PUS IN THE UTERINE CAVITY IN CASES OF MYOMA.

A definite pyometra is rarely associated with myomata, but occasionally at operation a small amount of pus is found in the uterine cavity. In Case 2098, for example, the lower abdomen was filled with a myomatous uterus, and a small quantity of pus was found in the cavity.

In Case 12439 the large multinodular uterus was adherent in the pelvis, and

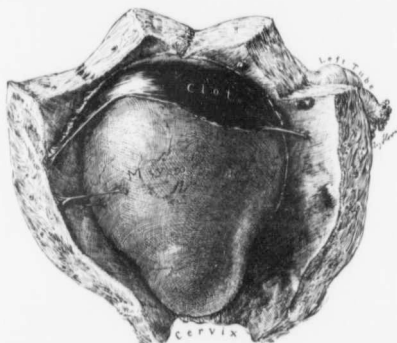


FIG. 197.—A LARGE CLOT IN THE UTERINE CAVITY. ($\frac{1}{2}$ nat. size.)

Gyn. No. 14373, Path. No. 12090. The anterior uterine wall is of normal thickness. Filling the uterus is a pear-shaped submucous myoma. Covering the surface of the myoma, in the upper part of the cavity, is a large clot. The small connections passing from the uterine wall to the myoma are drawn out and rather elastic threads, composed of fibrin, with red blood-corpuscles in the meshes.

also firmly fixed to a loop of small bowel. Both tubes were filled with pus. The cavity of the uterus contained pus. The uterine cavity had evidently long been the seat of an inflammation, as the mucosa had been replaced by granulation tissue.

In all cases in which there is a foul discharge from the uterus, any abdominal operation should be postponed until the discharge has been eliminated, otherwise there will be great danger of infection. Of course, in some cases immediate operation is imperative, irrespective of such risks.

CONDITION OF THE MUCOSA LINING THE UTERINE CAVITY IN CASES OF MYOMATA.

Glands running parallel to the surface of the mucosa.

Extension of the muscle into the mucosa.

Alterations in the blood-vessels of the mucosa.

Thrombosis of the veins in the mucosa.

Unusual gland shapes.

Edema.

Dilatation of the uterine glands.

Gland hypertrophy.

Uterine polypi.

Atypical changes in the epithelium lining the uterine cavity.

Adenocarcinoma.

A small myoma developing in the uterine mucosa.

Endometritis.

Tuberculosis of the endometrium.

If the myomata are so situated that the uterine cavity is not encroached upon nor enlarged, and provided the tubes are normal, as a rule it may be assumed that the uterine mucosa is normal. Occasionally, however, it is thicker than usual, as appears in Fig. 198, or in rare instances it is gathered up into irregular mounds forming localized areas of very thick mucosa, as seen in Fig. 199.

When an interstitial myoma reaches large dimensions, it usually produces a corresponding lengthening and broadening of the uterine cavity. Under these circumstances the normal amount of mucosa has to cover an area sometimes twice, or in other instances four or more times as great as before, and naturally will then be only one-fourth the usual thickness. Fig. 200 shows a small segment of normal mucosa from an enlarged uterine cavity. If the myoma is small or of moderate size, it will almost always become subperitoneal or submucous. If it passes toward the cavity of the uterus, the overlying mucosa gradually becomes thinner, as is well seen in Fig. 202. This mechanical thinning out becomes more and more marked, until finally little or no mucosa can be detected over the more prominent part of the tumor, and sometimes it is clearly evident, even macroscopically, that this portion is totally devoid of a mucosa. When the myoma is small, the tension on the mucosa is naturally not as great, and the tumor, even though submucous and pedunculated, may still have a liberal covering of mucosa. In Fig. 201 we have an example of a young myoma forcing its way through the mucosa into the uterine cavity. The myoma is virtually plowing through the mucosa, pushing it to either side,

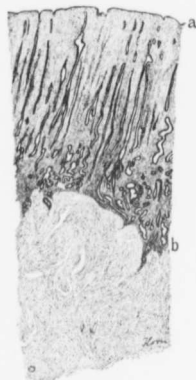


FIG. 198.—THICKENING OF THE UTERINE MUCOSA. ($\times 8$ diam.)

GYN. No. 2706. Path. No. 245. The uterus contained small interstitial and subperitoneal myomata. The uterus was 4.5 cm. long. The mucosa is considerably thickened, and consequently the glands are much lengthened. They are normal, a indicates the surface epithelium, and b the irregular line of junction between the mucosa and the muscle.

and also causing atrophy over the most prominent portion of the nodule, whereas the mucosa at the sides is much thicker than usual.

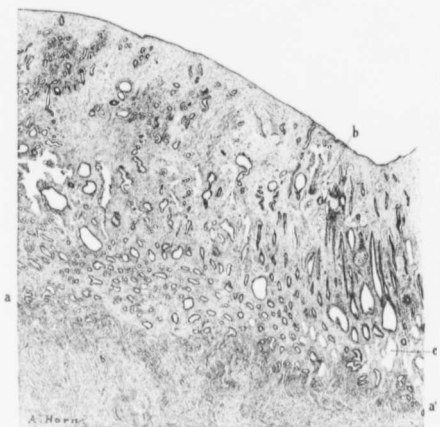


FIG. 199.—THICKENING OF THE MUCOSA IN A MYOMATOUS UTERUS. ($\times 8$ diam.)

GYN. No. 3014. Path. No. 788. The uterus was 11 x 9 x 9 cm., and covered with dense adhesions. Its walls showed diffuse myomatous thickening, in places reaching 5 cm. An interstitial myoma, 9 cm. in diameter, was also present. The uterine cavity was 6 cm. in length, and the mucosa in the upper part of the cavity was gathered up into mounds, varying from 1 to 3 cm. in diameter, and projecting from 1 to 8 mm. into the cavity. The section is from one of these elevations. *a* and *a'* indicate the line of junction between the mucosa and the myoma. The surface epithelium is intact. Many of the glands, especially in their deeper portions, are dilated. The stroma in the superficial portion is somewhat rarefied. It also contains many capillaries, one of which is seen at *b*. Near the muscle are numerous vacuoles, indicated by *c*.

With the continued inward progress of the myoma the mucosa becomes thinner and thinner, until all trace of the glands disappears and merely the surface



FIG. 200.—MODERATE THINNING-OUT OF THE MUCOSA OVER A SUBMUCOUS MYOMA. ($\times 44$ diam.)

Path. No. 501. The globular uterus measured 17 x 17 x 12 cm. The uterine cavity was 15 cm. in length, 11 cm. in breadth, and projecting into it from the posterior wall was a submucous myoma, 13 x 11 cm. The section is from the surface of this large submucous tumor. *a* is the mucosa, which is much thinner than usual, but otherwise normal. *b* is a thin layer of uterine muscle separating the mucosa from the underlying myomatous tissue (*m*).

epithelium and a zone of underlying stroma are left, separating the myoma from the uterine cavity. This is clearly shown in Fig. 203. The stroma becomes more

and more thinned out, until only a few layers of stroma cells are interposed between the myoma and the surface epithelium (Fig. 204). Finally, when the myoma projects far into the cavity, the mucosa may be represented merely by

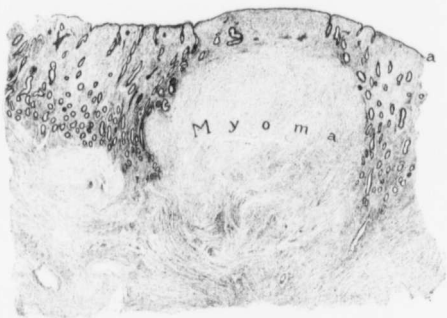


FIG. 201.—A SMALL MYOMA PUSHING THROUGH THE MUCOSA. ($\times 12$ diam.)

Path. No. 333. a is the surface epithelium. The myoma is pushing the mucosa to either side and is causing a thinning-out of the mucosa over the most prominent portion of the tumor. The mucosa is thicker on the sides of the myoma than it is elsewhere.

a layer of somewhat flattened epithelium, resting directly on the myoma. Such a condition is presented in Fig. 205.

The next stage is so well exemplified in Case 8767 (Path. No. 4959) that a




FIG. 202.—THINNING OUT OF THE MUCOSA OVER A SUBMUCOUS MYOMA. ($\times 54$ diam.)

Gyn. No. 3008. Path. No. 435. a indicates the normal thickness of the mucosa, and b the layer of muscle separating the submucous myoma from the mucosa. Toward the left the myoma becomes more prominent, and the muscle and mucosa gradually become thinner until at a' all traces of the glands have disappeared, and the mucosa is represented merely by the surface epithelium and a certain amount of underlying stroma.

detailed description will be given. The specimen consisted of a globular uterus, averaging 18 cm. in diameter. The great increase in size was due to the presence of an interstitial myoma, approximately 17 cm. in diameter, and occupying the posterior wall. The uterine cavity was 15 cm. in length, and its mucosa

averaged about 1 mm. in thickness. At one point over the submucous myoma the mucosa had entirely disappeared from an area measuring 7 x 5 cm. The myoma here was dark brown in color and somewhat roughened. On histologic examination, the mucosa lining the uterine cavity was found to be perfectly

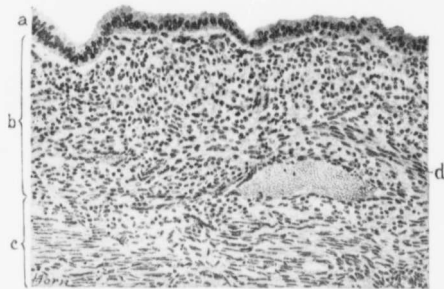


FIG. 203.—ATROPHY OF THE MUCOSA OVER A SUBMUCOUS MYOMA. (X 140 diam.)

Gyn. No. 3218, Path. No. 539. The surface epithelium (a) is normal. b is the zone of underlying stroma, devoid of glands; c is the muscle. The myomatous tissue lies immediately beneath this. A few strands of muscle are passing up into the stroma at d.

normal, but near the denuded area it had become thinner and thinner, until nothing but surface epithelium remained. This finally disappeared, and the myomatous tissue which had undergone hyaline transformation now formed the surface. Scattered throughout the hyaline material were numerous polymorphonuclear leukocytes. The next step would be breaking down of the degenerated myomatous tissue, with a speedy formation of a sloughing submucous myoma.

In some cases the myomata are very abundant, and literally pave the uterine cavity. In such cases the walls suggest a mosaic. Over the myomata the mucosa is very thin, whereas the spaces between myomata are filled with mucosa, which is often injected and much thickened.

Case No. 2658 (Path. No. 213) afforded an excellent example of such a condition. The uterus was approximately globular, being 13 x 11 x 11 cm. Scattered throughout the walls were many small myomata. The uterine cavity was 5 cm. in length, and projecting into it from the top were two pedunculated myomata, the

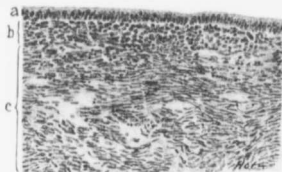


FIG. 204.—MARKED THINNING-OUT OF THE MUCOSA OVER A SUBMUCOUS MYOMA. (X 140 diam.)

Gyn. No. 3449, Path. No. 683. a is the normal surface epithelium. It is separated from the myomatous muscle (c) merely by (b) narrow zone of stroma (b).

larger being 5 cm. in diameter. The entire inner surface of the uterus was

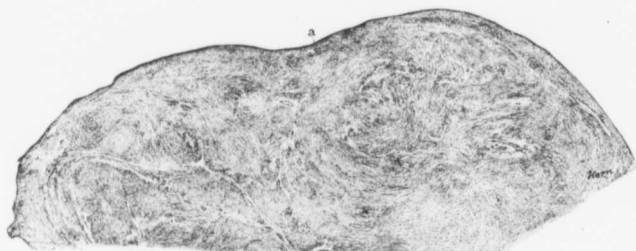


FIG. 205.—A SUBMUCOUS MYOMA ALMOST DEVOID OF MUCOSA. (X 4) diam.)

Gyn. No. 3293. Path. No. 583. The surface epithelium (*a*) is all that remains of the mucosa. It rests directly on the myomatous tissue.

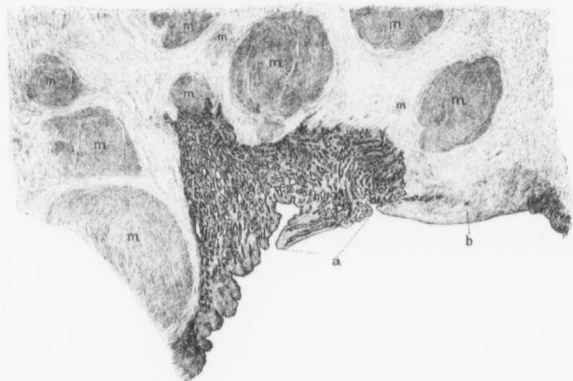


FIG. 206.—MARKED THICKENING OF THE UTERINE MUCOSA IN A DEPRESSION BETWEEN MYOMATOUS NODULES. (X 5 diam.)

Gyn. No. 2658. Path. No. 213. The uterus was enlarged, measuring 13 x 11 x 11 cm. Scattered throughout its walls were myomata, varying from 0.5 to 5 cm. in diameter.

The uterine cavity was 5 cm. in length. Projecting into it from the top were two pedunculated submucous myomata. The whole inner surface of the uterus was paved with small, pearly white myomata, varying from 3 mm. to 3 cm. in diameter, the intervening spaces being occupied by injected mucosa.

The picture represents the cleft between myomata, where the mucosa reached 8 mm. in thickness. Scattered everywhere throughout the muscle are myomata of various sizes. To the left the mucosa is fairly well preserved. In the cleft it is very thick, but otherwise normal. At *a* a young polyp is developing. At *b* the mucosa is represented by one layer of cylindric epithelium which rests directly on the myomatous muscle.

paved with small, pearly white myomata, varying from 0.3 to 3 cm. in diameter. The intervening spaces were occupied by injected mucosa, which in one cleft

reached 8 mm. in thickness. Histologic examination showed that the mucosa was in places virtually absent, but at other points reached 8 mm. in thickness (Fig. 206). That covering the submucous nodules over their most prominent portion was represented by one layer of cylindric epithelium resting almost

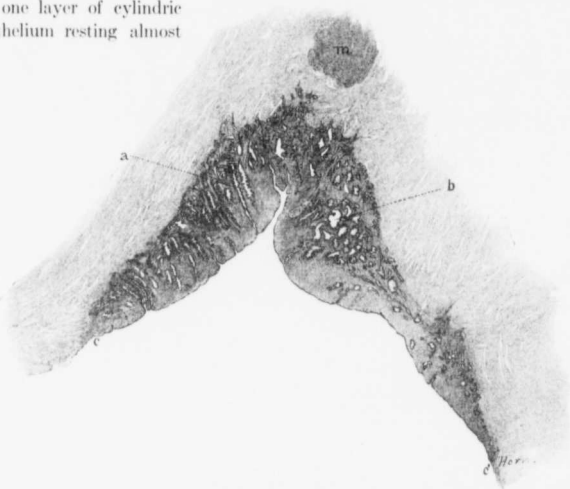


FIG. 207.—GLAND HYPERTROPHY IN A CLEFT BETWEEN MYOMATOUS NODULES. ($\times 7$ diam.)

J. (H. A. K., December 9, 1899). Path. No. 3674. The slightly irregular myomatous uterus measured 13 x 10 x 10 cm. Scattered throughout its walls were myomata, the largest 7 cm. in diameter. The uterine cavity was approximately 10 cm. in length, but much distorted and narrowed by submucous nodules. The mucosa was smooth. Over the submucous nodules it was as thin as parchment, but where not subjected to pressure, reached from 2 to 3 mm. in thickness.

On histologic examination, the mucosa presents an undulating surface and an intact surface epithelium. Over the prominent portion of the submucous myomata it consists merely of a narrow layer of stroma covered with epithelium, but devoid of glands. In the protected areas the mucosa was thickened. The picture represents such an area. At *a* and *c'* the surface epithelium rests directly on the muscle, but in the cleft becomes even thicker than normal. It shows typical gland hypertrophy, especially well seen at *a*. Some of the glands, as at *b*, are dilated. *m* is a small myoma.

directly on the muscular tissue. Some distance from the most prominent portion of these tumors the mucosa had regained its normal thickness.

In a few cases the thickened mucosa in the crevices between myomata showed typical gland hypertrophy, as seen in Fig. 207.

GLANDS RUNNING PARALLEL TO THE SURFACE OF THE MUCOSA.

It is no uncommon thing to see the deeper portions of a gland running parallel with, instead of at right angles to, the surface. This is especially prone to occur over the less prominent portions of a submucous myoma. In such cases it

would seem that, with the ingrowth of the myoma, the deeper portions of the glands are pressed upward until they are at right angles to their superficial portions. This explanation will apply only to a certain percentage of cases, as we have not infrequently seen this deflection of the glands in the absence of submucous myomata.

EXTENSION OF THE MUSCLE INTO THE MUCOSA.

It is a common occurrence to find one or more uterine glands extending a short distance into the muscle, especially if there be an adenomyomatous tendency, but the extension of muscle-bundles into the mucosa is relatively rare.

In Case 2852 (Path. No. 347) some of the uterine glands were much dilated, the stroma of the mucosa showed moderate hemorrhage in its superficial portion, and here and there bundles of muscle-fibers had extended into it.

The picture in Case 3113 (Path. No. 487) was even more striking. The mucosa was very atrophic. The surface epithelium was intact, the glands were few in number, small, and round on cross-section. The stroma of the mucosa showed a considerable amount of infiltration with small round cells, and non-stripped muscle-fibers were seen passing up into the stroma of the mucosa nearly as far as the surface epithelium.

ALTERATIONS IN THE BLOOD-VESSELS OF THE UTERINE MUCOSA IN MYOMA CASES.

As a rule, the mucosa will present the usual appearance if the tumors do not encroach upon it, and even if there is a marked projection of the tumor into the cavity, little or no change in the mucosa may be noted.

In a moderate number of the cases the mucosa is uniformly bright red, apparently owing to an injection of the capillaries. More common than this are foci of ecchymosis. These ecchymotic spots, if recent, are bright red in color, and appear as splotches of red. They are irregular in outline, and sharply differentiated from the surrounding and normal mucosa. Sometimes they are found in a mucosa of the normal thickness, but are more likely to be noted over the prominent surface of a large submucous myoma. As the hemorrhagic areas become older, they change in color, being in turn dark red and then almost black.

Where the mucosa is exceedingly thin, dilated veins beneath it are often clearly visible. These veins are often greatly increased in size when large myomata are present.

On histologic examination one frequently notes an abundance and much dilatation of the capillaries in the superficial portions of the mucosa. In Fig. 208 we have an example of a mucosa showing marked dilatation of the larger veins. This mucous membrane is otherwise unaltered.

In the cases in which ecchymosis is noted, there is usually much free blood in the stroma of the mucosa. This may be fresh, as in Figs. 209 and 210, or show a moderate degree of disintegration. In most cases all trace of the hemorrhage eventually disappears, but occasionally blood-pigment remains. In Case 3960

(Path. No. 971), for example, the uterine cavity was 3 cm. in length, 3 cm. in breadth, and its smooth mucosa presented numerous fine ecchymoses. In sections from these areas the surface epithelium was intact and the glands were



FIG. 208.—MARKED DILATATION OF THE VEINS OF THE UTERINE MUCOSA. ($\times 11$ diam.)

Path. No. 524. a is the mucosa, b, the underlying muscle. The surface epithelium and the glands are normal but the veins (c) are greatly dilated.

normal. The stroma of the mucosa showed slight small-round-celled infiltration, and there were deposits of yellowish-brown, granular pigment.

In Case 3492 (Path. No. 711) a myoma, 10 cm. in diameter, projected into the uterine cavity. Scattered throughout the mucosa were numerous patches of

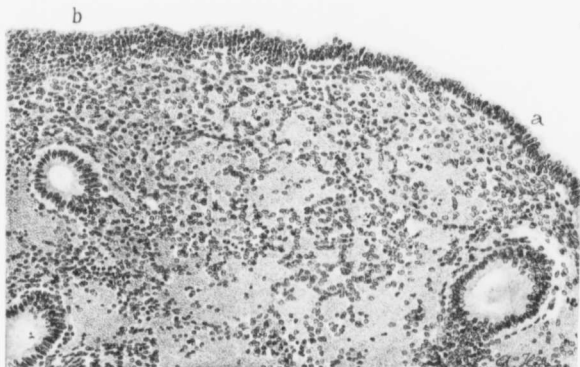


FIG. 209.—HEMORRHAGE INTO THE UTERINE MUCOSA. ($\times 130$ diam.)

Gyn. No. 3038. Path. No. 452. The surface epithelium a is normal. At b it has been cut on the bevel, and thus appears several layers thick. The uterine glands are normal, but scattered throughout the stroma are quantities of fresh blood, and in places the stroma-cells lie totally isolated from one another.

ecchymosis. Histologic examination showed the mucosa covering the sub-mucous myoma to be atrophic, and there was also edema. Where the ecchymotic patches were noted, large quantities of an almost black pigment were found in the stroma. This pigment occurred in irregular clumps or as minute

specks. Whether or not it was contained in the cells it was difficult to determine.

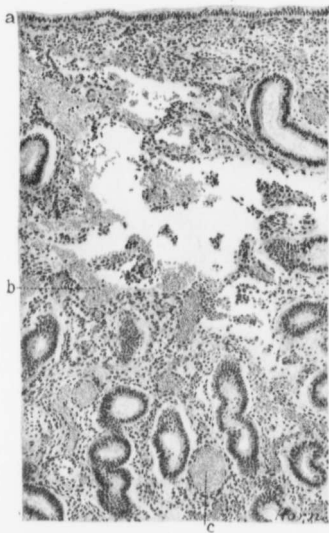


FIG. 210.—HEMORRHAGE INTO THE MUCOSA. ($\times 90$ diam.)

Gyn. No. 3281. Path. No. 573. The surface epithelium (a) is intact, and the glands are normal. The stroma of the mucosa shows marked hemorrhage (b). The large, irregular, empty areas were also filled with blood. This has dropped out, owing to its crumbling character. The veins of the mucosa are much dilated (c).

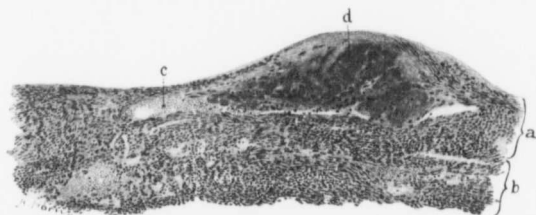


FIG. 211.—RUPTURE WITH SUBSEQUENT THROMBOSIS OF A VEIN OF THE UTERINE MUCOSA OVER A SUBMUCOUS MYOMA. ($\times 100$ diam.)

Gyn. No. 8354. Path. No. 4539. a represents the remnant of the atrophic uterine mucosa covering the large submucous myoma; b is the underlying muscle. Occupying the upper part of the field is a large vein. This, at e, still contains normal blood, but at d is filled with a thrombus which reaches to and opens on the surface. There has undoubtedly been a recent hemorrhage from this vein.

It is most exceptional to find any evidence of a definite bleeding vessel in the

mucosa. The surface epithelium is invariably intact, and the bleeding seems to be just a general oozing from the vessels in the mucosa, without any especial injury to their walls. In all the cases just described the hemorrhage was into the mucosa, and the surface was smooth. In Case 7688, however, in which the cavity of the uterus was distorted by interstitial and submucous myomata, the mucosa showed large hemorrhagic areas which, to a great extent, were covered with fibrin and blood.

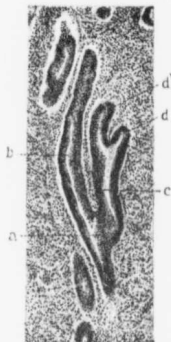

FIG. 212.—BRANCHING OF A UTERINE GLAND. ($\times 50$ diam.)

Gyn. No. 3008. Path. No. 435. The uterus contained subperitoneal, interstitial, and submucous myomata. *a* is the point at which the tubular gland divides into secondary glands, *b* and *c*. The gland *c*, after passing a short distance, divides into *d* and *d'*. The glandular epithelium is everywhere normal, and the surrounding glands and stroma present the usual appearance.

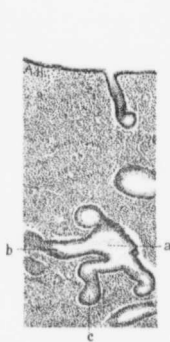


FIG. 213.—AN ATYPICAL UTERINE GLAND. ($\times 50$ diam.)

Gyn. No. 3216. Path. No. 534. The uterine cavity in this case was not encroached upon, but situated in the right broad ligament was a suppurating myoma (Fig. 105, p. 138). The surface epithelium is intact. In the depth is a slightly dilated gland (*a*). This continues downward, but also sends off two secondary branches, *b* and *c*. The epithelium of all the uterine glands is normal, and the surrounding stroma is unaltered.

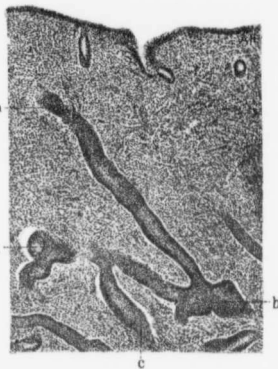


FIG. 214.—AN UNUSUAL UTERINE GLAND. ($\times 50$ diam.)

Gyn. No. 3385. Path. No. 634. The multinodular myomatous uterus measured 14 x 15 x 11 cm. The nodules were chiefly interstitial and subperitoneal.

The surface of the mucosa is smooth, and the glands near the surface are normal. The gland (*a*) can be traced downward and to the right. Its apparently solid character is due to the fact that the section has been cut through the margin, instead of through the center of the gland. As it spreads out, it is continued downward and also to the left, where it gives off the terminal branches *c* and *d*. Although the picture is a most unusual one, there is not the slightest suspicion of malignancy. The surrounding glands and their intervening stroma are normal.

THROMBOSIS OF VEINS IN THE MUCOSA.

In Case 6667 (Path. No. 2900) there was a history of a sudden hemorrhage four years before, and profuse bleeding each month after that. The cavity of the uterus was occupied by one large and two small myomata. On histologic examination several large thin-walled veins of the atrophic mucosa were found thrombosed.

In Case 8354 (Path. No. 4539) the uterus was greatly enlarged as a result of

subperitoneal, interstitial, and submucous myomata, and the uterus contained a very large polyp (Fig. 230, p. 331). The mucosa lining the uterine cavity was very thin. Its surface epithelium was intact, but flattened. The glands were small. The stroma showed slight infiltration, and occasionally a thrombosed vessel simulating to a limited extent a young tubercle. At one point at least (Fig. 211) the walls of a superficial vein had given way, but the leak had been partially controlled by a thrombus.

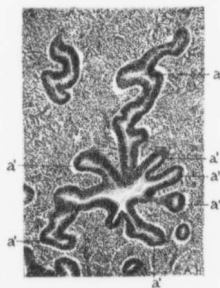


FIG. 215.—MARKED BRANCHING OF A UTERINE GLAND. ($\times 50$ diam.)

Gyn. No. 3385. Path. No. 634. The gland *a* in its upper portion is normal, but on passing toward the muscle, divides into the six terminal branches *a'*, *a'*, *a'*, *a'*, *a'*, *a'*. Its epithelium is normal. The surrounding glands present the usual appearance, and the stroma of the mucosa is unaltered.

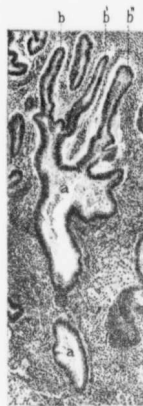

FIG. 216.—MARKED BRANCHING OF A UTERINE GLAND. ($\times 50$ diam.)

Gyn. No. 3038. Path. No. 452. The gland *a* in the lower part of the field is slightly dilated. That in the upper part is greatly dilated and partially filled with blood and granular detritus. The gland sends off the terminal branches *b*, *b'*, and *b''*, while the gland between *b* and *b'* is probably a branch cut at another level. To the right the gland spreads out into a large bay. All the glands are lined with normal cylindrical epithelium and the surrounding stroma is unaltered.

UNUSUAL SHAPES OF THE GLANDS ASSOCIATED WITH UTERINE MYOMATA.

As has been said, when the myomata do not encroach upon the uterine cavity, the latter is usually of the normal size; the mucosa is normal in appearance, and the uterine glands are of the usual type. Even if a submucous myoma is present, the only change in the mucosa will be a thinning-out.

In a few instances we have found unusual patterns in the glands; some of the more interesting of these are shown in Figs. 212, 213, 214, 215, and 216.

In Fig. 212 we see a dichotomous branching, and one of the secondary branches again divides.

In Fig. 213 we have a slightly dilated gland in the depth of the mucosa sending off two lateral branches.

In Fig. 214 a tubular gland can be followed from near the surface into the depth, where it sends off branches to the right and left. One of these again subdivides.

In Fig. 215 a gland in its superficial portion is normal, but in the depth spreads out and apparently ends in six terminal branches.

The large gland in Fig. 216 is considerably dilated, and spreads out into three terminal branches.

The glands in each case are lined with normal cylindric epithelium, and are

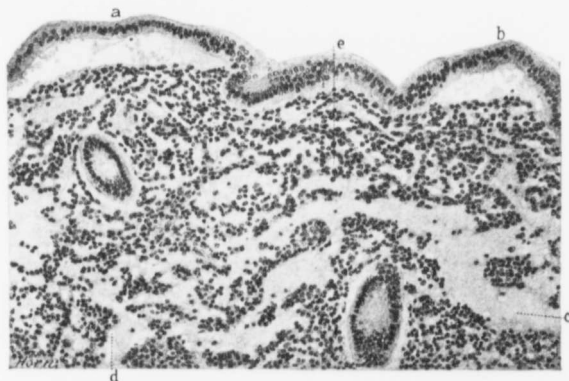


FIG. 217.—EDEMA OF THE UTERINE MUCOSA. ($\times 130$ diam.)

CYB. No. 3209. Path. No. 540. Separating the surface epithelium from the mucosa at a and b is coagulated serous fluid. The uterine glands are normal in appearance. The stroma is very edematous, as is particularly well seen at c. Scattered throughout the coagulated serum are many small vacuoles, one of which is indicated by d. At e the stroma-cells are arranged around a vacuole resembling a small gland.

surrounded by the characteristic stroma of the mucosa. In none of them is there the slightest suspicion of malignancy.

EDEMA OF THE UTERINE MUCOSA.

Edema is usually recognized by the succulent character of the tissue in which it is found, and by the escape of serous fluid from the cut surfaces. The uterine mucosa has a glistening, translucent appearance, so that edema might very readily be thought to be present, when in reality none exists. The diagnosis, as a rule, can be made only on histologic examination.

Edema of the mucosa is rare and, when met with, is usually limited to the superficial portions, and is not found near the muscle. It may be localized or

uniform throughout the cavity. It occurs irrespective of the presence or absence of submucous myomata.

The surface epithelium is intact, and the glands are usually normal. The stroma cells are separated from one another by a granular material which takes the eosin stain. Scattered throughout it are large or small vacuoles. The granular material is undoubtedly coagulated serum. A certain amount of fibrin can also be demonstrated in some cases by means of Weigert's stain. Oc-

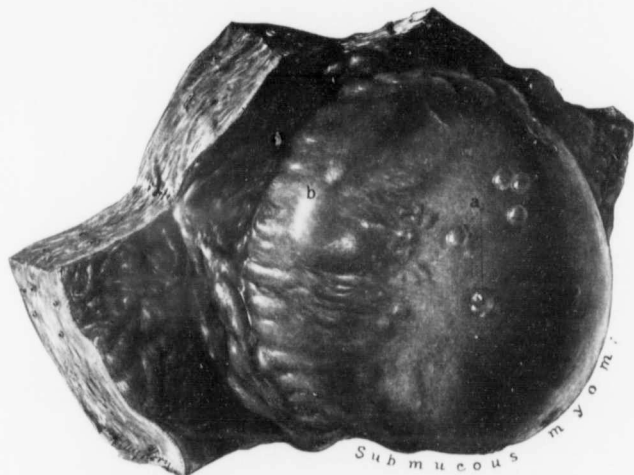


FIG. 218.—DILATED UTERINE GLANDS OVER A SUBMUCOUS MYOMA. (1/2 nat. size.)

Gyb. No. 12490. Path. No. 9186. As soon as the uterus was opened, its muscular walls contracted, leaving the submucous myoma standing out prominently. The mucosa over the submucous nodule is very thin, and standing out sharply from this, are the cystic glands (a). The mucosa (b) at the base of the myoma is considerably thickened. That lining the opposite wall is gathered up into folds, owing to the marked contraction of the walls as soon as the uterus was opened.

asionally the exudate is exceptionally rich in albumin. It then forms a homogeneous mass that takes the eosin stain. When the edema is very pronounced, as in Fig. 217, much serum is poured out not only into the stroma, but also into the glands, and the surface epithelium may be separated from the stroma by serum. Occasionally the lymph-vessels in the underlying muscle are dilated, as in Case 4203 (Path. No. 1116).

DILATATION OF THE UTERINE GLANDS.

In a moderate number of myoma cases we have found slight dilatation of some of the uterine glands. The dilated glands may be present in any part of

the cavity, and are more prone to occur when submucous myomata exist. The smaller ones are recognized as spheric cysts, 0.5 to 1 mm. or more in diameter, and filled with a translucent or transparent content. If the mucosa is atrophic, these small cysts stand out prominently. They are also especially noticeable in uterine polypi.

In rare instances the cysts become relatively large, as in Fig. 218, in which we see numerous cysts, several millimeters in diameter, projecting from the atrophic mucosa covering the submucous myoma. Another striking example of cystic glands is furnished by Fig. 219. Here the uterine cavity is much increased in size, and the mucosa over a large submucous myoma has numerous cysts or blebs projecting from its surface. These cysts tend to arrange themselves in rows; they have exceedingly fine walls, and ramifying over their surfaces are delicate traceries of blood-vessels. They are filled with a clear, limpid fluid.

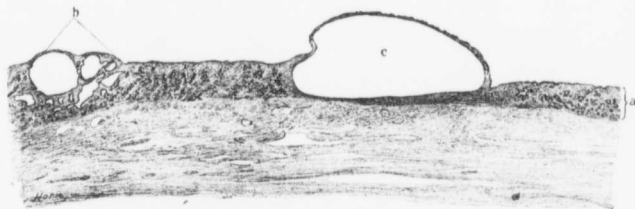


FIG. 220.—MARKEDLY DILATED UTERINE GLANDS. (X 5 diam.)

Gyn. No. 3232. Path. No. 543. The section embraces one of the dilated glands in Fig. 219. *a* is the normal mucosa. At *b* the glands show cystic changes. The smaller cysts are irregular, the larger spherical. *c* is one of the markedly dilated glands. The surface epithelium is continued over it. All trace of an epithelial lining has disappeared from the inner walls of the greatly dilated glands, although still present in those showing only moderate dilatation.

Occasionally the dilated glands contain small yellow bodies that float around in the clear fluid. These bodies usually consist of exfoliated epithelial cells.

On histologic examination the glands showing moderate dilatation have an intact cylindrical epithelium. They may be empty, as in Fig. 221, or contain a granular detritus or a solid coagulum resembling a hyaline cast. When the glands become still more dilated, the epithelium sometimes retains its normal form, but is usually flattened. In a few instances, as in Case 3437, the epithelium may show proliferation, being several layers in thickness.

Where marked dilatation occurs, the epithelium may entirely disappear. In Fig. 220 some glands show slight dilatation and are irregular in contour. Those moderately dilated are spheric, whereas the one showing great dilatation is irregularly oval.

An example of gland dilatation of a marked degree is furnished by Case 3133 (Path. No. 494). The uterus was pear-shaped, and measured 36 x 32 x 32 cm. The uterine cavity was 31 cm. long, and varied from 9 to 14 cm. in breadth. Its

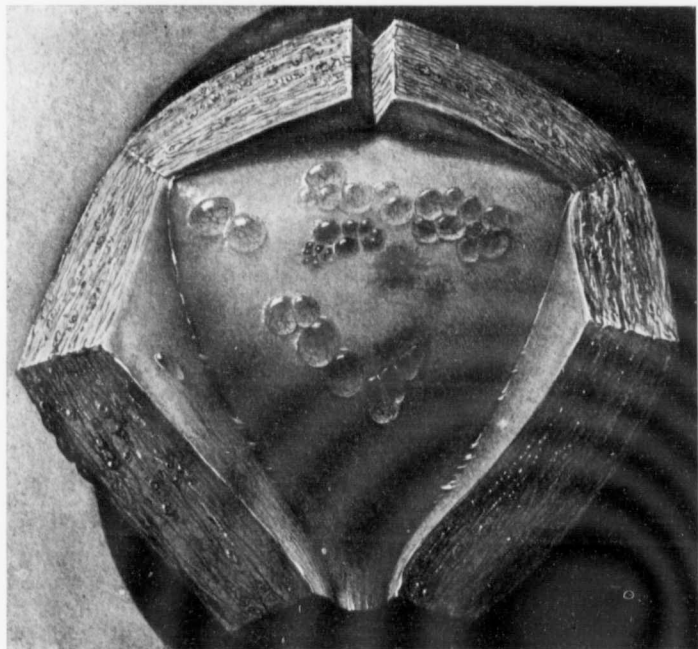



FIG. 219.—MARKED DILATATION OF THE UTERINE GLANDS OVER A SUBMUCOUS MYOMA. ($\frac{1}{4}$ nat. size.)
Gyn. No. 3232. Path. No. 543. Mr. Brödel painted this picture within a few minutes after the uterus was opened, and was fortunate in getting the exact colors of the mucosa.

Occupying the posterior uterine wall, and seen in hazy outline, is a myoma 15 cm. in diameter. The uterine cavity is much increased in size. The mucosa has a yellowish tinge, and scattered over the anterior and posterior walls are a few irregular patches of ecchymosis. Scattered over the posterior walls are numerous cysts varying from 1 to 7 mm. in diameter, and apparently arranged in definite rows. The larger cysts have elevated margins, are sharply defined, and project fully 1 mm. from the surface. They are covered with a delicate membrane, which is everywhere traversed by a fine network of blood-vessels. The blood-supply of these cysts reminds one somewhat of the vascular arrangement of the fundus of the eye.

For the histologic appearances of the cysts see Fig. 220.



mucosa was atrophic, and projecting into the cavity from the upper part were three large polypi. Situated in the posterior wall, about 12 cm. from the top of the cavity, was a yellowish area, 3 cm. in diameter. From this mucus mixed with blood escaped into the uterine cavity. This cavity had smooth walls.

On histologic examination marked atrophy of the mucosa was found, and most of the glands had disappeared. The cyst-like cavity seen near the middle of the uterus, and communicating with the uterine cavity, was lined with one layer of epithelium similar to that covering the surface of the mucosa. This cavity was in all probability a dilated uterine gland. The fact that it secreted mucus, however, suggests the possibility of a cervical origin.

GLAND HYPERTROPHY.

This was noted in several cases. When present, it was usually associated with submucous myomata, and even macroscopically the mucosa was thicker than

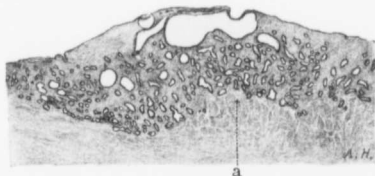


FIG. 221.—A MODERATE GRADE OF DILATATION OF THE GLANDS. ($\times 8$ diam.)

Gyn. No. 2852. Path. No. 347. The mucosa on the right and left is normal. The glands in the central portion are more convoluted and show slight dilatation. Just beneath the surface is a markedly dilated and irregular gland. The dilatation has produced a decided elevation of the surface of the mucosa at this point.

usual (Fig. 207, p. 316). The hypertrophic changes were almost invariably limited to the superficial layers of the mucosa. The cause of the gland hypertrophy is unknown. In Case 7795 (Path. No. 4055), in which a right tubal pregnancy existed, the exciting factor was evident.

UTERINE POLYPI ASSOCIATED WITH MYOMATA.

On opening the cavity of a myomatous uterus one or more polypi are not infrequently found. These may be situated in any part of the cavity, but are more prone to occur in the upper part. An examination of 44 cases in which uterine polypi were present showed that in 34 there was 1 polyp; in 5 there were 2, and in 5 cases 3 polypi; thus it is evident that the polypi usually occur singly.

The polypi were found in large and small myomatous uteri, the size of the organ seeming to have little or no influence on their development.

Some of the polypi were very small, as in Fig. 222, and appeared as little flat and yet sharply outlined elevations from the surface of the mucosa. The relation

of such small polypi to the mucosa is clearly seen in Fig. 225, where the polyp is evidently nothing more than a heaping up of the mucosa at a given point.

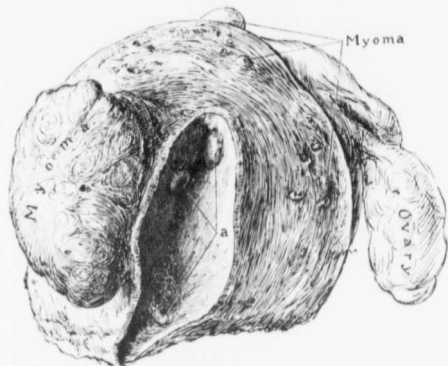


FIG. 222.—THREE SMALL POLYPI. ($\frac{1}{2}$ nat. size.)

Gyn. No. 9132. Path. No. 5286. The picture represents the right half of the uterus. The right tube is much thickened near the cornu. In the anterior wall is a myoma, several centimeters in diameter. In the posterior wall are a few minute tumors. In the uterine cavity are three small flat polypi, as indicated by a. Two are in the upper part of the cavity; one is near the internal os.

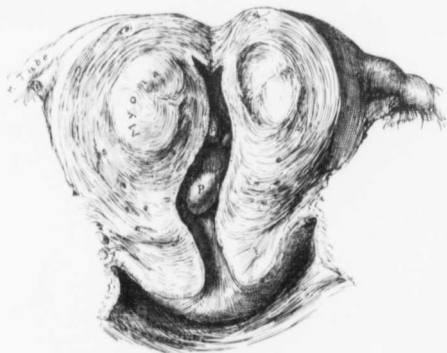

FIG. 223.—SMALL UTERINE POLYPI. ($\frac{1}{10}$ nat. size.)

Aut. No. 869. Path. No. 1382. The cervix is normal. The anterior uterine wall is thickened, and contains a small myoma. Projecting into the uterine cavity are two small pedunculated polypi, and between them and to one side are the faint outlines of a smaller one.

As the polypi get larger they become somewhat pedunculated, as seen in

Figs. 223 and 224. The majority have broad bases, and are relatively thin, being not over 1 to 2 mm. in thickness. Nearly all of them point downward. The polyp in Case 3038 (Path. No. 452) is one of the rare exceptions. This polyp was 1.5 cm. long and 4 mm. broad; it was attached near the internal os and pointed upward.

The polypi are usually smooth, and consist of a whitish-yellow, semi-transparent substance—uterine mucosa. Scattered throughout it are often seen small cystic spaces—dilated glands. The lower and free margins of the polypi are often deeply injected, as a result of hemorrhage into their dependent portions.

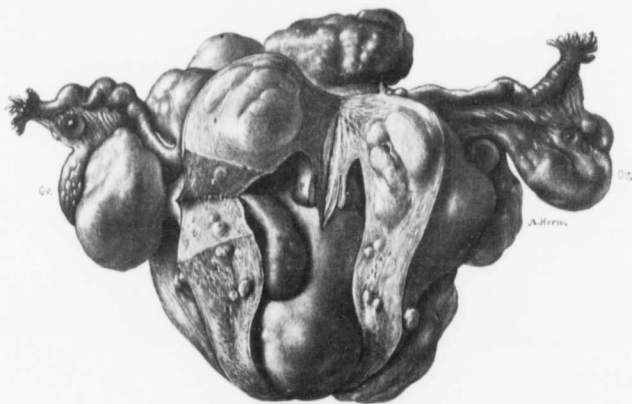


FIG. 224.—POLYPI ASSOCIATED WITH UTERINE MYOMATA. ($\frac{1}{2}$ nat. size.)

GYN. No. 9707. Path. No. 5912. The appendages are normal. The uterus had been opened posteriorly. Springing from its surface, and studding its walls, are myomata of various sizes. Occupying the greater part of the cavity is a long and partially submucous myoma. Springing from the left side of the fundus, near the cornu, and attached by a delicate pedicle, is a slightly lobulated polyp, several centimeters long. Hanging down from the top of the cavity is a second but smaller polyp, which has been cut in two.

The uterine mucosa surrounding the polypi may be of the normal thickness, atrophic, or even show an increase in thickness.

In a few cases the mucosa had shown a marked tendency to gather into ridges or folds, but no definite polypi had developed. In Case 4955 (Path. No. 1484), the globular uterus had a cavity 15 cm. long and 7 cm. broad. The mucosa covering the posterior wall was pale, smooth, and averaged 2 mm. in thickness. This surface was concave, having been subjected to pressure exerted by a tumor occupying the anterior wall. Near the fundus, the mucosa was gathered up into a broad flat mound, 3 cm. in diameter and 1 cm. thick. Its margins were slightly injected.

Histologic appearances of polypi from the body of the uterus.

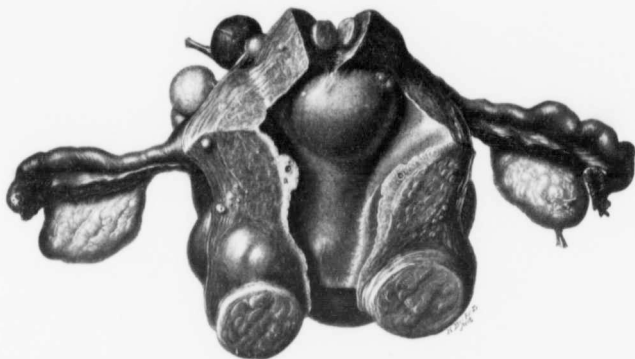


FIG. 225.—A VERY EARLY STAGE OF A UTERINE POLYP. ($\frac{1}{2}$ nat. size.)

Gyn. No. 8368. Path. No. 4554. The appendages are normal. The uterus has been opened from the front. Growing from its walls are subperitoneal, interstitial, and submucous myomata. The mucosa of the posterior wall is atrophic; that of the anterior wall is of the normal thickness, except at a, where it forms a distinct area of thickening, producing a cystic, sessile polyp. The small cyst in the polyp is a dilated gland.

Uterine polypi are nothing more than portions of the mucosa that have been partially extruded, and with the succeeding and frequent contractions of the

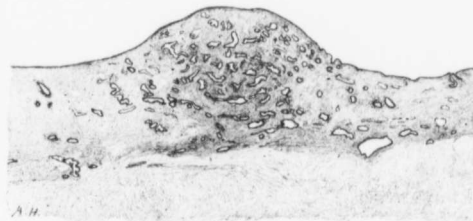

FIG. 226.—THE BEGINNING OF A UTERINE POLYP. ($\times 12$ diam.)

Gyn. No. 3130. Path. No. 499. The section is from the body. To the right and left is normal mucosa. In the center the mucosa is thicker, and forms a dome-like elevation from the surface. Here the glands are very abundant. In time this elevated portion would be forced more into the cavity, until it became a pedunculated polyp.

uterus have been forced out into the cavity. Fig. 226 is an excellent example of the earliest stage. The mucosa on either side is relatively normal, whereas in

the center it is being heaped up into a dome-like elevation. This area would, in time, be pushed farther into the cavity and would form a definite polyp.

If the uterine mucosa from which the polyp is nipped off is normal, we should expect the polyp to consist of normal mucosa. The surface of the polyp is usually smooth, as in Fig. 226, but may be wavy in outline. The majority of the glands present the usual appearance, but as a result of obstruction, some of them tend to become cystic, and their epithelium flattened. In the stroma of the pedicle of the polyp non-striated muscle is not infrequently found. This is due to the fact that some of the muscle is drawn out with the mucosa as it is being extruded.

The mucosa near the tip of the polypi often shows a good deal of hemorrhage. A few of the polypi show slight disintegration; the gland epithelium

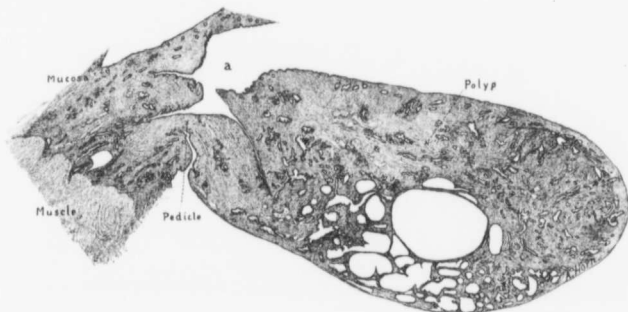


FIG. 227.—A UTERINE POLYP. ($\times 7$ diam.)

GYN. No. 7699. Path. No. 3948. The character of the polyp shows that it is from the body of the uterus. To the left is uterine mucosa, which, apart from slight gland dilatation, is normal. *a* indicates the top of the uterine cavity. Attached by a narrow pedicle is an oblong polyp with a rounded end. Its surface epithelium is continuous with that lining the uterine cavity, and represents uterine mucosa. Many of its glands are dilated, some reaching large proportions. Where marked dilatation has occurred, the partitions between glands have in places disappeared.

ends to drop off, and the gland cavities are filled with hyaline-like casts, as was noted in Case 3113 (Path. No. 487).

When the uterine mucosa is the seat of gland hypertrophy, the polypi, as a rule, will also show hypertrophy of the glands. This was especially noticeable in Case 12021 (Path. No. 8502).

Very Large Polypi.—That uterine polypi may reach very large proportions is clearly demonstrated by the following cases:

In Case 5946 (Path. No. 2242) the uterus was converted into a nodular tumor, approximately 24 x 40 cm. The uterine cavity was 11 cm. in length and 7 cm. in breadth. The upper two-thirds was filled with three remarkably large polypi (Figs. 228 and 229). The larger of these measured 7 x 4 x 2.5 cm. The

surfaces of the polypi were injected, traversed by branching blood-vessels, and studded with minute cysts, averaging 1 mm. in diameter. Sections from these polypi showed cyst-like spaces scattered everywhere throughout their substance, some of them reaching 5 mm. in diameter.

The uterine mucosa was smooth, but markedly hemorrhagic. The myomata showed little tendency to encroach on the uterine cavity.

On histologic examination all the polypi presented the same picture. Their surfaces were comparatively smooth, and in many places were covered with one layer of epithelium. Scattered throughout the stroma of the polypi were many typical uterine glands. The cyst-like spaces were dilated glands. In the majority of them the epi-



FIG. 228.—CROSS-SECTION OF A LARGE UTERINE POLYP IN A CASE OF MULTIPLE MYOMATA. (Nat. size.)

Gyn. No. 5946. Path. No. 2242. The section is taken from the fundus. a is normal uterine muscle; b, the edge of a large myoma; c, dilated veins; d shows a cross-section of a large polyp. Its surface, although undulating, is perfectly smooth, but on section it presents a cystic appearance, due to the many dilated glands, one of which reaches at least 5 mm. in diameter. The polyp has a broad base, and shows no tendency to penetrate the muscle. Histologic examination shows it to consist of practically normal mucosa. e is normal mucosa. (After Thomas Cullen.)

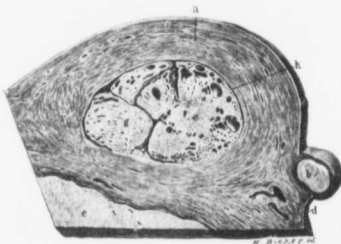


FIG. 230.—CROSS-SECTION OF A VERY LARGE UTERINE POLYP IN A CASE OF MYOMA. (Nat. size.)

Gyn. No. 5946. Path. No. 2242. The section is taken from the neighborhood of the uterine horn, and shows a small part of the uterine cavity filled with polypi, a is normal uterine muscle; b, a small sessile subperitoneal myoma; c, the edge of a large myoma; d indicates blood-vessels, rich, judging from their thin walls, are probably veins; e, f, and g are cross-sections of polypi. Scattered throughout the substance of the polypi are large and small cyst-like spaces—dilated uterine glands. h is the smooth inner surface of the uterine cavity. (After Thomas Cullen.)

thelium was still well preserved. In not a few places, however, it had dropped off in ribbons, forming irregular skeins in the gland-spaces, and at first sight offering a suggestion of malignancy. The appearance, however, was due to faulty hardening. The stroma of the mucosa corresponded to that of the uterine mucosa.

In Case 8354 (Path. No. 4539) the myomatous uterus was 24 x 20 x 15 cm. The uterine cavity was 13 cm. long and 7 cm. broad in its upper portion. The

FIG. 230.—A VERY LARGE UTERINE POLYP (1/3 nat. size.)

Gyn. No. 8354. Path. No. 4539. The myomatous uterus extended to the umbilicus, and was 24 x 20 x 15 cm. It is literally riddled with subperitoneal, interstitial, and submucosal myomata. Filling the upper part of the uterine cavity is a lobulated polyp with a delicate granular surface, strongly suggestive of carcinoma. This polyp was 7 cm. long, 5 cm. broad, and 3 cm. in thickness. On histologic examination it was found to be composed of uterine mucosa, showing areas of gland hypertrophy. It is the largest uterine polyp that we have ever seen.

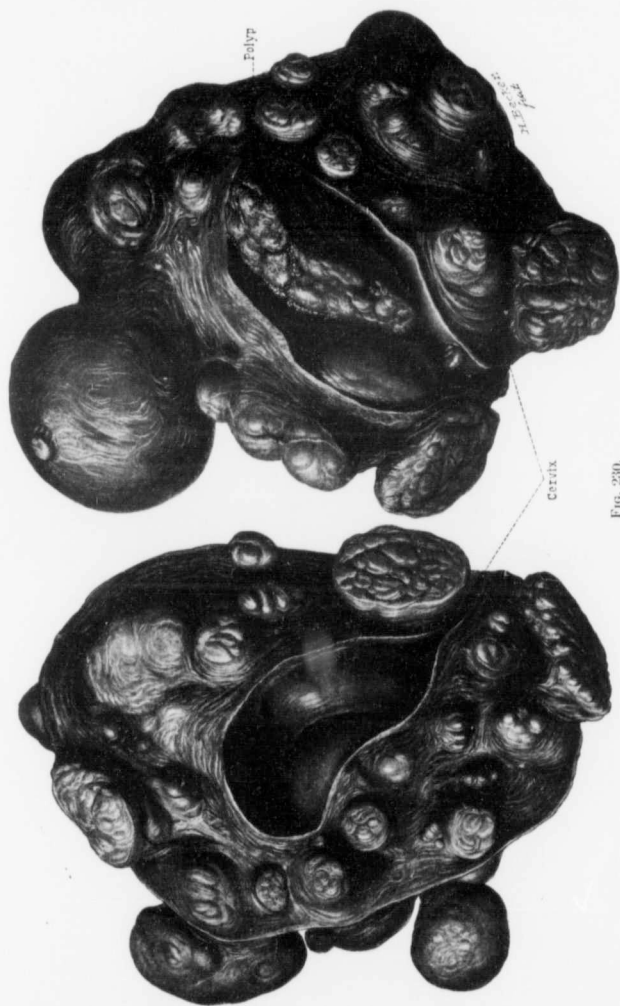


FIG. 230.

mucosa was very thin. The chief interest centered in a mass which was attached to the uterine wall by a delicate pedicle, and filled almost the entire cavity. This mass was irregular in shape, somewhat lobulated, and had a fine granular surface (Fig. 230). It measured 7 x 5 x 3 cm. Its granular appearance strongly suggested carcinoma, but it showed no areas of disintegration. On section, the growth was fairly homogeneous and cut like cheese. Scattered throughout it were numerous hemorrhagic areas and many dilated blood-vessels.

On histologic examination the growth filling the uterine cavity was found to consist essentially of mucosa. Its surface was covered with one layer of epithelium. Its glands in places were normal; at other points they branched a great deal or showed dilatation. Some areas showed typical gland hypertrophy. The stroma of the polyp was, to a considerable extent, infiltrated with small round cells. The growth was nothing more than an exceptionally large uterine polyp.

In Gyn. No. 12155 (Path. No. 8723) a very large myoma sprang from the surface of the uterus, whose walls were studded with smaller nodules. The uterine cavity was 8 cm. long and 4 cm. broad. Projecting into the cavity from the top was a polyp 5 cm. in length, 3 cm. in breadth, and tapering to 1 cm. at the point. It bore a strong resemblance to a long and narrow chicken's liver, was spongy, and apparently consisted of mucosa. Histologic examination proved it to be a simple uterine polyp. Some of its glands had been imperfectly preserved, and the epithelium had dropped off in ribbons, forming a skein-like arrangement.

Large polypi were also noted in Case 12234 (Path. No. 8844). The uterus was irregularly nodular and measured 25 x 21 x 15 cm. The uterine cavity was balloon-shaped, and projecting into it were several myomata and three polypi, the largest of which was 5.5 x 4 x 3 cm. This large polyp, on histologic examination, showed typical gland hypertrophy. Such large polypi as have just been described are, of course, exceptionally rare.

ATYPICAL CHANGES IN THE EPITHELIUM LINING THE UTERINE CAVITY.

In addition to the cell-changes found in endometritis and in cancer, we have also noted in a few cases a definite tendency in the surface epithelium to proliferate. In Case 3320 (Path. No. 589), in which the uterus was greatly enlarged from the presence of subperitoneal and interstitial myomata, the epithelium covering the surface of the mucosa showed a slight tendency to proliferate, being two or three layers in thickness at several points.

Proliferation of the surface epithelium was also noted in Case 3408 (Path. No. 659) and in Case 6479 (Path. No. 2700). Occasionally small papillary outgrowths may be detected arising from the surface of the mucosa. In Case 3133 (Path. No. 494) the uterus was tremendously enlarged from the presence of an interstitial myoma. The uterine cavity was also greatly increased in size, being 31 cm. long, and varying from 9 to 14 cm. in diameter. The mucosa was naturally greatly thinned out. About the middle of the cavity were delicate papillary outgrowths from the surface epithelium.

In Case 3340 (Path. No. 607) the uterus was the seat of subperitoneal, interstitial, and submucous myomata and the uterine cavity was 6 cm. long. The mucosa was somewhat atrophic. The surface epithelium was everywhere intact, and in most places normal, but near the submucous myomata were three finger-like outgrowths of epithelium, and not far distant from these the surface epithelium had proliferated, being three or four layers in thickness. The newly formed cells stained much more faintly than normal epithelial cells, and they were separated from each other by a moderate number of polymorphonuclear leukocytes. The uterine glands were normal.

Were the mucosa lining all portions of the uterine cavity systematically examined histologically, we feel sure that such alterations in the surface epithelium as we have noted would be much more frequently found. Some of them undoubtedly indicate a commencing malignant change; others, however, would advance no further.

ADENOCARCINOMA.

This subject is dealt with fully on pp. 274 and 404.

A SMALL MYOMA DEVELOPING IN THE UTERINE MUCOSA.

In Fig. 231 we have a definite example of a small myoma originating in the uterine mucosa. It is the only picture of this kind that we have ever encountered! The uterus formed a globular tumor, 14 cm. in diameter. The anterior wall contained an interstitial and slightly submucous myoma, 12 cm. in diameter. The uterine cavity was 12 cm. long, 11 cm. in breadth. Its mucosa was atrophic,



FIG. 231.—A MYOMA ORIGINATING IN THE UTERINE MUCOSA. ($\times 4$ diam.)

GYN. No. 2808. Path. No. 2101. The uterus contained a subperitoneal and interstitial myoma, and two polypi lay in the uterine cavity.

The mucosa at *a* and *a'* is perfectly normal, except for slight gland dilatation, but between these points and projecting slightly from the surface is a small flat myoma. This is confined entirely to the mucosa, has pushed the glands to either side, and is covered over with the surface epithelium, *b*. This myoma had undoubtedly originated in the mucosa, probably from some preëxisting muscle-fibers that were located there. In the lower part of the picture a small portion of a large interstitial myoma is seen.

and some of its glands were dilated! Projecting into its cavity was a tongue-shaped polyp, 3.5 cm. long and 1.3 cm. broad. A second and smaller one lay near the internal os.

On histologic examination the mucosa, apart from atrophy and gland dilatation and the presence of the myoma, as seen in Fig. 231, was little altered.

ENDOMETRITIS.

Inflammation of the endometrium has, in our experience, been very rare. One of us (Cullen) in 1898* reported that in the routine examination of the specimens from the gynecologic operating-room of the Johns Hopkins Hospital for a period of four years endometritis had been found only 48 times; in other



FIG. 232.—POLYPOID ENDOMETRITIS AND DOUBLE PUS-TUBES ASSOCIATED WITH A MYOMA OF THE FUNDUS.
($\frac{1}{5}$ nat. size.)

Gyn. No. 8693. Path. No. 4808. The uterus was pyriform in shape, and measured 11 x 7 x 6 cm. In the fundus was a myoma 5 cm. in diameter. The uterine mucosa varied from 2 to 4 mm. in thickness, and presented a granular appearance, due to flattened projections varying from 1 to 1.5 mm. in diameter. The tubes and ovaries were bound up in adhesions. Both tubes were filled with pus. On histologic examination it was found that the surface of the mucosa was in many places greatly altered, the cylindric epithelium having been replaced by many layers of cells resembling squamous epithelium. Lying beneath the epithelial cells were myriads of polymorphonuclear leucocytes. The knob-like outgrowths were composed of newly formed connective tissue containing many blood-vessels, and covered externally with cylindric epithelium or with many layers of cells of the squamous type. The uterine glands showed some hypertrophy in the superficial portions, but in the depth most of them were normal.

words, on an average of only once each month. We were astonished at the lack of frequency with which it was encountered, and were still further surprised to find that even when the Fallopian tubes showed definite evidences of inflammation, the endometrium was often unaltered. If, however, an inflammation of the uterine mucosa exists, the excessive vascularity, together with the excellent

* Thomas S. Cullen, Endometritis, Md. Med. J., 1898, p. 571.

drainage afforded by the more or less perpendicular position of the uterus, favors the speedy restoration to normal.

What applies to the endometrium in general is equally applicable in myoma cases. In our experience the mucosa rarely shows any inflammation when the uterus contains myomata. After carefully tabulating the cases in which there was an endometritis,—usually of a very mild grade,—we have found that with one or two exceptions either the uterus contained a submucous myoma, usually disintegrating, or the tubes showed definite evidences of a recent or old inflammation.

These findings are of importance to the surgeon in that he can with almost certainty say that if the patient has no vaginal discharge, and if the appendages are normal, the uterine mucosa is unaltered. Knowing this, he can open the uterine cavity, if necessary, with relative certainty that there is no danger of infection lurking there.

In Fig. 232 we have an example of a small myomatous uterus with a fine polypoid endometritis, associated with double pus-tubes.

TUBERCULOSIS OF THE ENDOMETRIUM ASSOCIATED WITH UTERINE MYOMATA.

From the accompanying table it will be seen that we have had 7 cases* in which, in addition to the myoma, tuberculosis of the endometrium was noted. In 6 of the cases the uterus was relatively small; only in Case 3319 did it reach fairly large proportions. In 2 of the cases minute tubercles were recognized on the surface of the uterus.

In some of the cases the implication of the endometrium was quite recent; in others, nearly the entire mucosa had been replaced by tuberculous tissue, and in Case 4965 the small uterine cavity was filled with creamy fluid.

In Case 3319 the tuberculosis had extended to the muscle beneath the mucosa. In none of our cases, however, had the tuberculous process involved a myoma. In April, 1901, Dr. Homer Gage, of Worcester, Mass., sent us a myomatous uterus showing definite tuberculous implication of a myoma. The interstitial myoma was approximately globular and 7 cm. in diameter. On section, it presented a putty-like appearance and was very soft, fully three-fourths of the myoma showing this degeneration. Smears made by Dr. Gage yielded tubercle bacilli in moderate numbers.

On making sections from the endometrium we found normal mucosa in places, but at other points the stroma showed small-round-celled infiltration, and at one point in the mucosa a definite tubercle was found.

The myoma was everywhere riddled with areas of caseation showing surrounding zones of tuberculous tissue. All stages in the tuberculous process were demonstrable. Scattered throughout the myoma were a few islands of uterine mucosa. In other words, it was in part an interstitial adenomyoma.

*The endometrium was also tuberculous in Aut. No. 869 (Path. No. 1382).

Both tubes were the seat of advanced tuberculosis.

It is well known that tuberculosis of the tubes is usually present when tuberculosis of the endometrium is found, and, as seen from the table, our cases closely

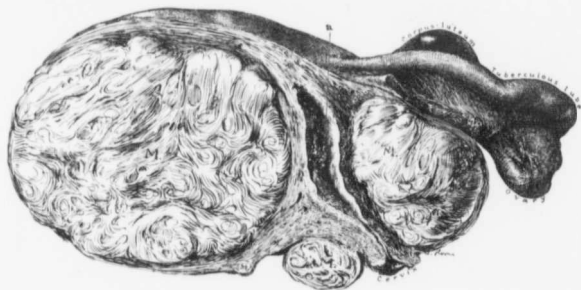


FIG. 233.—TUBERCULOSIS OF THE ENDOMETRIUM AND FALLOPIAN TUBES ASSOCIATED WITH A MYOMATOUS UTERUS. ($\frac{1}{2}$ nat. size.)

GYN. No. 3319. Path. No. 592. The myomatous uterus measured 15 x 17 x 20 cm. Situated in the posterior wall is a large myoma; in the anterior wall, a second; while just posterior to the cervix is a third. The endometrium is roughened, as indicated by a. This is due to a loss of substance caused by the tuberculosis. The left tube is thickened and tuberculous. The left ovary contains a corpus-luteum cyst.

follow this rule. In five, both tubes were involved; in a sixth case, one tube. In only one case was there no evidence of tubal tuberculosis.

The association of tuberculosis of the endometrium with uterine myomata must be regarded as a mere coincidence.

TUBERCULOSIS OF THE ENDOMETRIUM ASSOCIATED WITH UTERINE MYOMATA.

GYN. No.	PATH. No.	SIZE OF UTERUS.	CONDITIONS OF TUBES.	ENDOMETRIUM.
3319	592	15 x 17 x 20 cm. (Fig. 233).	Tuberculosis of both tubes.	Advanced tuberculosis. Commencing involvement of underlying muscle.
4965	1499	4 x 3.8 x 3 cm. Largest myoma on surface, 5 cm. Cavity small, filled with creamy fluid.	Both tubes embedded in adhesions, but not tuberculous.	Early tuberculosis of endometrium.
6991	3277	6 x 6.5 x 6 cm. Minute tubercles over surface.	Tuberculosis of one tube.	Early tuberculosis of endometrium.
8220	4403	Slightly enlarged.	Tuberculosis of both tubes.	Early tuberculosis of endometrium.
9636	5825	Myoma 8 cm., in posterior wall.	Tuberculosis of both tubes.	Early tuberculosis of endometrium.
12119	8714	7 x 8 x 7 cm. Several myomata from surface; largest, 14 x 11 x 11 cm.; minute tubercles on surface.	Tuberculosis of both tubes.	Tuberculosis of endometrium.
12866	9755	7 x 8 x 8 cm.	Tuberculosis of both tubes.	Tuberculosis of endometrium.

CHAPTER XVIII.

CONDITIONS OF THE TUBES AND OVARIES WHEN UTERINE MYOMATA ARE PRESENT.*

Although our investigations are based on over 1400 cases coming under our observation, many of the cases operated upon in the smaller hospitals could not be as carefully tabulated from a clinical and pathologic standpoint as were those observed in the Johns Hopkins Hospital. Consequently, in discussing the condition of the tubes and ovaries, we have utilized only those cases admitted to this institution.

A SUMMARY OF THE CONDITION OF THE TUBES IN 934 CASES OF UTERINE MYOMA WHERE IT WAS NECESSARY TO REMOVE THE UTERUS.

Free from adhesions	511 cases																		
Free from adhesions, but showing some other pathologic change	29 "																		
Total number in which normal tubes were present	482 cases																		
<i>Adhesions.</i>																			
Both tubes adherent	364 cases																		
One tube adherent	59 "																		
Total number in which one or both tubes were adherent	423 cases																		
Dense tubal adhesions were present in	94 of these cases																		
Hydrosalpinx..... 88 cases:	<table border="0" style="display: inline-table; vertical-align: middle;"> <tr> <td>Simple</td> <td>77</td> <td>{ 51 unilateral.</td> </tr> <tr> <td></td> <td></td> <td>{ 26 bilateral.</td> </tr> <tr> <td>Follicular</td> <td>10</td> <td>{ 6 unilateral.</td> </tr> <tr> <td></td> <td></td> <td>{ 4 bilateral.</td> </tr> <tr> <td></td> <td>1 case</td> <td>{ right, follicular.</td> </tr> <tr> <td></td> <td></td> <td>{ left, simple.</td> </tr> </table>	Simple	77	{ 51 unilateral.			{ 26 bilateral.	Follicular	10	{ 6 unilateral.			{ 4 bilateral.		1 case	{ right, follicular.			{ left, simple.
Simple	77	{ 51 unilateral.																	
		{ 26 bilateral.																	
Follicular	10	{ 6 unilateral.																	
		{ 4 bilateral.																	
	1 case	{ right, follicular.																	
		{ left, simple.																	
Hematosalpinx..... 12 cases:	{ 9 unilateral.																		
	{ 3 bilateral.																		
Chronic salpingitis..... 48 cases:	{ 43 bilateral.																		
	{ 5 unilateral.																		
Pyosalpinx..... 41 cases:	{ 19 unilateral.																		
	{ 22 bilateral.																		
Tubo-ovarian cyst..... 5 cases:	{ 1 right side.																		
	{ 4 left side.																		
Tubo-ovarian "mass"..... 5 cases:	{ 3 right side.																		
	{ 2 left side.																		
Tubo-ovarian abscess..... 14 cases:	{ 4 right side.																		
	{ 9 left side.																		
	{ 1 bilateral.																		
Tuberculosis..... 14 cases:	both tubes involved.																		
Tubal pregnancy..... 6 cases:	{ 5 ruptured.																		
	{ 1 intact.																		
Rudimentary left tube, 1 case (Gyn. No. 10917).																			
Myoma of the tube, 1 case (Gyn. No. 10237).																			

* In the tabulation of the condition of the tubes and ovaries we have exercised great care, but as in some cases one or both appendages were not removed, and only a conservative operation was performed, we have occasionally been compelled to rely entirely on the notes made at operation. In some cases these are naturally incomplete. Accordingly, it will be safer to make an allowance for possible error in the statistics of about 1 per cent.

Adherent Tubes.—From the summary it is seen that one or both tubes were adherent in 423 out of 934 cases. This is a large percentage. In many of the cases the adhesions were slight; in others sufficient to occlude the tube and produce a hydrosalpinx, while in a good many cases the tubes were densely adherent as a result of a pyosalpinx or pelvic abscess.

The friction between the tumor and the pelvic peritoneum naturally tends to cause irritation of the surfaces, with the occasional formation of slight adhesions. Again, the myomata, as they grow, may partially block the uterine cavity and force the uterine secretions or menstrual flow out through the tubes. A mild inflammation may thus be set up. Sloughing submucous myomata also are

responsible for inflammatory changes. In other cases the infection is undoubtedly introduced from without.

Being at a loss to explain the large percentage of cases in which adhesions existed, the histories were carefully examined to see how many patients were colored, as the percentage of tubal lesions is known to be much larger in the negroes:

Total number of whites	608
Adherent appendages in 216 cases (35.6 per cent.).	
Total number of colored	326
Adherent appendages in 207 cases (63 per cent.).	

The result shows that in the colored adherent appendages were nearly twice as frequent as in the white women.

Hydrosalpinx.—Hydrosalpinx was noted in 88 of the cases. In 77 of these it was of the simple variety; in 11, follicular hydrosalpinx was

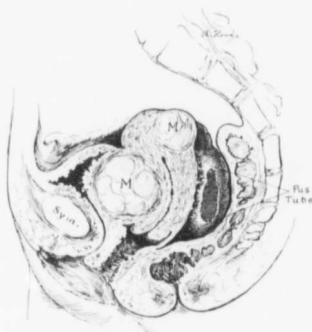


FIG. 234.—A MYOMATOUS UTERUS ASSOCIATED WITH PYOSALPINX.

GYN. No. 6381. The omentum was adherent to the abdominal wall and bladder. Situated in the anterior uterine wall, and lying partially beneath the bladder, is a myoma several centimeters in diameter. In the posterior wall is a smaller one. Lying behind the uterus and adherent to it is the right tube, which is distended with pus. It reached 2.5 cm. in diameter. The left tube also contained a purulent accumulation.

present. A very mild grade of inflammation is often sufficient to occlude the fimbriated end of the tube, and a hydrosalpinx is the natural sequence. We have frequently seen the occluded tube lying free in the pelvis, being nowhere adherent.

Hematosalpinx.—In 12 cases a hematosalpinx was noted. As a rule, a hematosalpinx is a hydrosalpinx into which a hemorrhage has taken place. If we include these two varieties, in one group we have 100 cases out of 934 showing a non-purulent accumulation of fluid in the Fallopian tube.

Salpingitis.—Salpingitis and pyosalpinx have been employed really as synonymous terms. In our cases the inflammatory changes in the tubes in the main

were chronic at the time of operation. When the tube was small, hard, and indurated, we usually termed the condition a salpingitis, but when enlarged,

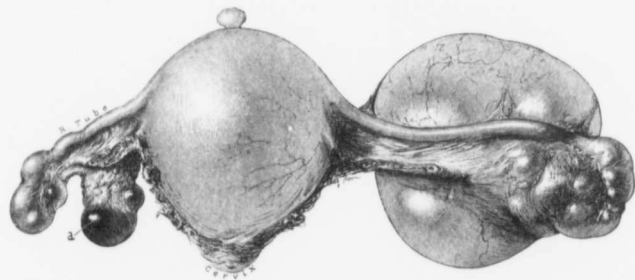


FIG. 235.—A TUBO-OVARIAN CYST ASSOCIATED WITH A MYOMATOUS UTERUS. ($\frac{1}{2}$ nat. size.)

San. No. 2968. Path. No. 11191. The large myomatous uterus is pear-shaped, and projecting from its surface is a small pedunculated myoma. The right tube is occluded and is the seat of a hydrosalpinx. *a* is a corpus luteum. The left tube, for the most part, is normal. The outer end, however, is distended and lobulated; it communicates with the ovarian cyst. The fluid filling the tube and cyst was clear and limpid.

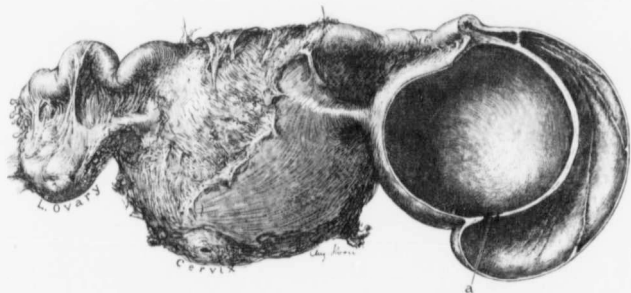


FIG. 236.—A TUBO-OVARIAN CYST AND DENSE ADHESIONS COMPLICATING A MYOMATOUS UTERUS. ($\frac{1}{2}$ nat. size.)

San. No. 858. Path. No. 3706. Fully one-half of the posterior surface of the uterus was covered with dense adhesions. The uterus contained a myoma, 5.5 cm. in diameter. The left tube and ovary were somewhat adherent, but the fimbriated end of the tube was patent. The right tube in its outer portion was much dilated, and at its outer end reached 5 cm. in diameter. The longitudinal ridges on its inner surface indicate the tubal folds. The ovary had been converted into a simple cyst which measured 7 cm. in diameter. The dilated tube and the cyst communicate at *a*. Both were filled with clear fluid. Histologic examination of the cyst indicated that it was a dilated Graafian follicle.

hard, and filled with an appreciable quantity of pus, we put it down as a pus-tube (Fig. 234) or a pyosalpinx.

In 48 cases salpingitis was found, and it is interesting to note that in 43 out of the 48 the condition was bilateral.

In 41 cases pyosalpinx was found. Thus, in 89 out of the 934 cases a definite inflammatory process existed in one or both tubes.

It is very difficult to discuss purulent changes in the tubes without the coincident consideration of inflammatory lesions in the ovaries so intimately associated with them.

In 5 cases "tubo-ovarian masses" were found. This clinical term indicates a firm inflammatory mass without macroscopic evidence of pus. In 14 other cases tubo-ovarian abscesses were present. It will thus be seen that in over 10 per cent. of the cases the appendages were the seat of purulent changes. In such cases the patient had usually suffered more pain than falls to the lot of one affected with a simple myoma. Moreover, the operative measures required are naturally more radical, and at the same time more difficult, than they would be if the appendages were free from adhesions.

The same factors that produce hydrosalpinx cause pyosalpinx, the only difference being that in the latter the inflammatory reaction is more severe.

Tubo-ovarian Cysts.

—In 5 cases of our series tubo-ovarian cysts were found. In these cases the tube is the seat of a hydrosalpinx and is intimately blended with the ovary, which is usually converted into a single cyst.

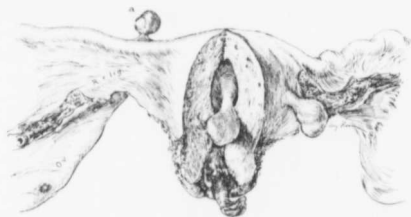

FIG. 237.—A MYOMA OF THE RIGHT FALLOPIAN TUBE. ($\frac{1}{2}$ nat. size.)

Gyn. No. 10237. Path. No. 6430. To the right was a parovarian cyst, 20 cm. in diameter; to the left, an ovary containing several large cystic follicles.

Springing from the anterior surface of the uterus near the left round ligament is a small pedunculated myoma. The uterine cavity is almost completely filled with polyp. Projecting from the upper surface of the right tube at a is a pedunculated myoma, which measured 7 x 8 x 10 mm.

On section, it is found that the distended tube communicates by a large or small opening with the ovarian cyst. The fluid filling the cavities is usually clear and limpid. In these cases there has evidently been a mild inflammation; the tube has become glued to the ovary, and a hydrosalpinx has developed. At a later date a matured Graafian follicle at the point of adhesions has been unable to empty itself, and has developed into a Graafian follicle cyst. The cyst and the hydrosalpinx have eventually opened into one another.* In Fig. 235 we have a very good example of a tubo-ovarian cyst associated with a myomatous uterus. Fig. 236 shows a somewhat similar tubo-ovarian cyst on section.

A Rudimentary Fallopian Tube.—In Gyn. No. 10917 the omentum was firmly adherent to the uterus, which contained several small myomata. The

* Thomas S. Cullen, Hydrosalpinx, Johns Hopkins Reports, 1895, Vol. 4.

right tube and ovary were normal. The left ovary was absent, and the left tube was represented by a mere remnant of a normal tube. It had evidently never fully developed.

Myoma of the Fallopian Tube.—The tubal muscle is similar to that of the uterus, and as myomata are so common in the uterus, we would consequently not be surprised if, at times, myomata should develop from the tube.

Case 10237 is, however, the only one in which any tendency toward a tubal myoma was found. In this case the patient was seventy years of age. The uterus measured 2.5 x 3 x 6 cm., had a small pedunculated myoma springing from its outer surface, and contained several polypi. On the right side was a parovarian cyst, 20 cm. in diameter. On the left, the ovary measured 3 x 3.5 x 6 cm., the increase in size being caused by several unusually large Graafian follicles. Arising from the upper surface of the right tube near the uterus was a well-defined myoma, 7 x 8 x 10 mm. (Fig. 237).

Tuberculosis of the Fallopian Tubes.—In 14* of the 934 cases the Fallopian tubes were the seat of tuberculosis, and in all these cases the disease was bilateral. In 6 of the cases the tuberculous character of the process was recognized only on microscopic examination.

In 2 of the 6 a distinct inflammatory process was present, but no tubercles were detected macroscopically, and in another of the cases (11428), although a tubo-ovarian abscess was present on the left side, no macroscopic evidence of tuberculosis was found. In the remaining 7 cases tubercles were evident, and the diagnosis was readily established when the abdomen was opened.

The presence of a thickened nodular tube with a patent fimbriated extremity is always strong presumptive evidence of tuberculosis in this situation.

In Case 4732 there was a wide-spread tuberculous peritonitis.

From the clinical histories it is evident that in only one of the 14 cases would the physician have suspected tuberculosis prior to operation, the symptoms of the myoma in each case overshadowing those of the tuberculosis. The exception was Case 12866. This patient, three years previously, had been admitted to

* Gyn. Nos. 3319, 4022, 4732, 6991, 7441, 8220, 9636, 9823, 10242, 10587, 11428, 11703, 12119, 12866.

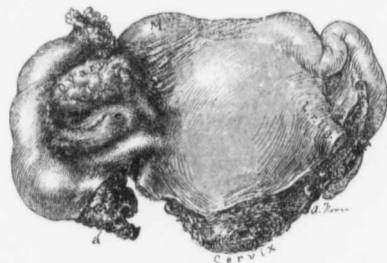


FIG. 238.—RUPTURED TUBAL PREGNANCY COMPLICATING UTERINE MYOMATA. (Nat. size.)

Gyn. No. 8985. Path. No. 5159. The uterus is moderately enlarged, owing to the presence of several myomata. The left tube was adherent. The right ovary appears normal, but the tube near its middle is considerably dilated, and at a placental tissue and clotted blood project through a rent in the anterior wall.

Dr. Halsted's service suffering from tuberculosis of the hip. When she entered the gynecological department there were definite signs of tuberculosis of the right kidney, the right ureter, and of an early tuberculosis of the bladder. The pains in the right iliac fossa naturally suggested the possible development of an early tuberculous process in this location. Thus in 13 out of 14 cases in which tuberculosis of the tubes was associated with uterine myomata, the clue as to the tubal complication clinically was absolutely wanting.

In some of the cases examination of the endometrium would have shown tuberculosis, as evidenced by the subsequent pathologic findings, but, as a rule, the operator refrains from curetting when the diagnosis of myoma is perfectly clear.

Tubal Pregnancy.—In 934 of our cases 6 tubal pregnancies were detected. From the accompanying table it will be seen that 5 were ruptured and 1 was intact.

The left tube in Case 12380 showed a globular thickening, 4 cm. in diameter, near the uterus, but the fimbriated end was intact. When the tube was opened, the typical picture of tubal pregnancy was noted.

TABLE OF TUBAL PREGNANCIES ASSOCIATED WITH UTERINE MYOMATA.

GYN. NO.	NUMBER OF YEARS MARRIED.	NUMBER OF CHILDREN.	NUMBER OF MIS-CARRIAGES.	SYMPTOMS SUGGESTING TUBAL PREGNANCY.	R. OR L. TUB. PREG. INTACT OR RUPTURED.
7795	5	0	2	Of no value.	R., rupt.
7849	10	0	0	Of no value.	L., partly ruptured.
8985	10	0	0	Of no value.	R., rupt (Fig. 238).
8990	12 (col.)	1 (twenty-one years ago).	1	Definite signs of pregnancy.	L., five months ruptured.
9243	11	0	0	Of little value.	R., rupt. (myomec-tomy).
12380	14	0	1	History slightly suggestive ("velvety feel").	L., ruptured (see "Adenomyoma of the Uterus," Fig. 66, p. 247).

This table shows that 5 of the 6 patients had never been delivered of a child at term, and 3 of the 6 had never been pregnant before.

From a clinical standpoint it is interesting to note that in 4 of the cases the symptoms attributable to the myoma completely overshadowed those of the tubal pregnancy. Consequently the surgeon was totally unaware of the condition until the abdomen was opened.

In Case 12380 the uterus was the seat of several myomatous nodules, and a firm tumor was felt to the left of the uterus. This, on palpation, differed materially from the myomata. On gentle palpation it felt soft, but when firm pressure was exerted, hard. It reminded one of a hard ball covered with velvet.*

* Thomas S. Cullen, The Velvety Feel of an Unruptured Tubal Pregnancy, Johns Hopkins Hosp. Bull., 1906, p. 154.

See Cullen, Adenomyoma of the Uterus, Fig. 66, p. 247, W. B. Saunders Co., 1908.

The soft feel was due to the pregnant sphere being surrounded by soft tubal muscle and numerous dilated blood-vessels. This sign is naturally obscured if the tube ruptures.

Mechanical Alterations in the Tubal Relations.—In the majority of the cases in which no inflammatory changes in the appendages are present the tubes present a normal appearance. When the myoma extends far out into the broad

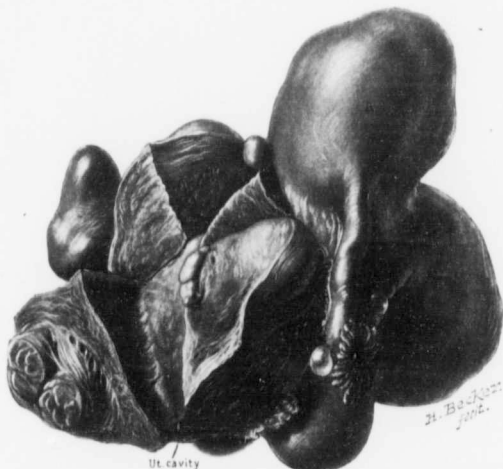

FIG. 239.—THE MEDIAN END OF A FALLOPIAN TUBE APPARENTLY TERMINATING IN A MYOMA. ($\frac{2}{3}$ nat. size.)
Gyn. No. 7063. Path. No. 3354. Scattered throughout the uterus were subperitoneal and interstitial myomata. The right tube and ovary were covered with a few delicate adhesions, but were practically normal. The left tube looked normal, but at the median end it apparently passed directly into the myoma. Even in serial sections it was impossible to trace the tube after it reached the myoma.

ligament, the tube may be greatly stretched, reaching 17 cm. or more in length. Occasionally a greatly elongated tube may be associated with a large ovary, as in Fig. 245 (p. 351).

Fig. 239 represents a multinodular uterus with a large nodule projecting directly upward from the left cornu. The left tube is normal, but apparently passes directly into the myoma.

CONDITION OF THE OVARIES IN CASES OF UTERINE MYOMATA.

From the tabulation we found that in the 934 cases the ovaries were normal in 438. In the remainder, comprising over half, the ovaries were either adherent or showed some pathologic lesion.

Free from adhesions.....	508 cases
Free from adhesions, but showing some pathologic changes.....	70 "
Both ovaries normal.....	438 cases
<i>Adhesions.</i>	
Both ovaries adherent.....	370 cases
One ovary adherent.....	56 "
Total number in which one or both ovaries were adherent.....	426 cases

In 95 of these cases the adhesions were dense. (For ovarian abscess and tubo-ovarian abscess see tabulation of diseases of the tubes, p. 337.)

Ovarian abscess apparently not associated with pyosalpinx, 6 cases. Pelvic peritonitis with abscess formation apparently independent of pyosalpinx or definite ovarian abscess, 6 cases. Tuberculosis, 3 cases (tubes primarily involved).

Cysts.

Small ovarian cysts not classified.....	44 cases:	{ 37 unilateral. 7 bilateral.
Graafian follicle cysts.....	68 cases:	{ 56 unilateral. 12 bilateral.
Corpus luteum cysts.....	34 cases:	{ 32 unilateral. 2 bilateral.
Multilocular cystadenomata.....	9 cases	
Papillocystomata.....	12 cases:	{ 10 unilateral. 2 bilateral.
Adenocarcinoma (primary).....	8 cases	
Dermoid cyst.....	17 "	
Fibromata.....	3 "	
Very large ovaries.....	2 "	
Merging of a myoma and an ovary.....	1 case	
Parovarian cyst.....	19 cases:	{ 18 unilateral. 1 bilateral.

Tubo-ovarian abscesses and ovarian abscesses are, for obvious reasons, considered with inflammatory conditions of the tubes.

In 6 cases* there was an ovarian abscess apparently not accompanied by a pyosalpinx. In each case the abscess was unilateral.

Pelvic peritonitis with abscess formation apparently independent of any tubal or ovarian abscess was noted in 5 cases.†

In 184 cases cysts of various sizes were noted. Of this number, 44 were small, unclassified ovarian cysts; 68 Graafian follicle cysts; 34 corpus luteum cysts; 9 multilocular adenocystomata; 12 papillocystomata; and 17 dermoid cysts. In addition to this number there were also 8 adenocarcinomata of the ovary, nearly all of which were cystic.

Graafian Follicle Cysts.—We know that ovarian adhesions tend to prevent the normal cycle of the Graafian follicle, and as the ovaries were adherent in 426 of the 934 cases, it is but natural that this variety of cyst should be common.

* Gyn. Nos. 2973, 3395, 5123, 5302, 9013, 12209.

† Gyn. Nos. 5010, 6199, 7320, 8008, 9678.



FIG. 240.—A MULTICULAR OVARIAN CYSTADENOMA ASSOCIATED WITH A MULTINODULAR MYOMATOUS UTERUS. (1 NAT. SIZE.)

Gyb. No. 7775. Path. No. 4083. The nodular myomatous uterus was 10 x 10 x 13 cm., and covered with numerous adhesions. The nodules varied from 0.5 to 5 cm., and the two largest were calcified. Behind the cervix was a subperitoneal myoma. The right tube was occluded and the seat of a small hydrosalpinx. The left ovary had been converted into a multicular cyst. The cysts varied greatly in size, and the largest ones had trabeculae extending from side-to-side; those were remnants of the cyst walls that had broken down. At the points indicated by a smaller cysts projected into the larger ones. At operation the pedicle of the cyst was found to have made a complete rotation from right to left.

We found in all 68 instances of Graafian follicle cysts. The smallest was 2.5 cm. in diameter, the largest, 22 cm.

Corpus Luteum Cysts.—These are also more prone to occur when pelvic adhesions exist. They were noted in 34 of the 934 cases. The smallest was 2.5 cm. in diameter, the largest, 3 x 5 x 10 cm.

Multilocular Cystadenomata.—In 9* of the 934 cases multilocular ovarian cysts were found. In 5 of these the myoma was the chief factor. In the remaining 4 the symptoms caused by the cyst completely overshadowed those due to the myomata. In Case 7775 (Fig. 240), the myomatous uterus measured 10 x 10 x 13 cm., the cyst, 15 x 20 x 25 cm. The pedicle of the cyst had formed a complete rotation from right to left.

When the cyst is relatively small, its simultaneous occurrence with the myomata should occasion few additional symptoms, but when it has reached large proportions (Fig. 241), dense adhesions are liable to give rise to very serious complications.

Case 9030 affords a striking example of such complications. The patient, aged fifty-one, at the time of operation was very weak and anemic. On opening the abdomen, in addition to the myomatous uterus, 20 cm. in diameter, we found the abdomen nearly filled with a multilocular ovarian cyst. This was everywhere very adherent to the intestines, and was separated in many places by sacrificing the cyst-wall. During its removal the cyst ruptured and a large amount of foul-smelling

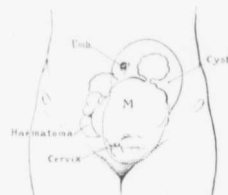

FIG. 241.—A MULTITUDE OF PATHOLOGIC CONDITIONS.

Gyn. No. 2172. The uterus is converted into a multinodular myomatous tumor which extends slightly above the umbilicus. To the right is a hematoma. To the left is a large ovarian cyst.

purulent material escaped. This was at once carefully wiped out, and the myomatous uterus quickly removed. At the end of the operation the patient was profoundly collapsed, and she died a few hours later. In this case undoubtedly the multilocular cyst and not the myoma was primarily responsible for the patient's death.

Papillocystoma of the Ovary.—In 12† of the 934 cases papilloma of the ovary was associated with uterine myomata. In 10 of the cases the process was unilateral, in 2, bilateral. In Case 10875 the left ovary had been converted into a papillocystoma, 7 x 10 x 12 cm. The right ovary was not of abnormal size, but histologic examination revealed a small cystic space containing a papillomatous mass in this ovary. The process here was an exceptionally early one.

In Cases 1455, 2172, 12034, 12912, the papillary growth had penetrated the cyst-wall and extended to the peritoneum of the surrounding structures. In Case 12034 there was also free ascitic fluid in the general peritoneal cavity.

* Gyn. Nos. 6201, 7377, 7775, 7971, 8227, 8266, 9030, 11050, 12764.

† Gyn. Nos. 1455, 2172, 3808, 6344, 6439, 8738, 10867, 10875, 12034, 12848, 12849, 12912.



FIG. 242.—AN OVARIAN CYST WITH EARLY PAPILLARY MASSES ASSOCIATED WITH METASTATIC TUBERCLE. (1½ nat. size.)

(Gib. No. 6344. Path. No. 2592. The uterus was amputated through the cervix and removed with difficulty. It contained subperitoneal, interstitial, and one submucous myoma, which almost completely filled the uterine cavity.

The right tube is lengthened out, but is normal. The ovary has been converted into one large cystic cavity. The inner lining is, for the most part, smooth, but over a considerable area has small granular projections, covering the surface. These are particularly well seen in the area between a and a'. The cyst was lined, and its projections were covered, with one layer of low cuboidal epithelium. It apparently originated from a dilated Graafian follicle. The usually branched papillary masses are missing.

In most of the cases the myomata were relatively small, and during the few months prior to operation the symptoms referable to the papillary growth equaled or overshadowed those of the myomata.

In Case 6344 (Fig. 242), however, the cyst was still small, and the tendency toward papillary formation markedly limited.

The presence of papillary masses on the outer surface of the ovary naturally handicaps the surgeon's endeavors. He wishes to be as conservative as possible, but realizes that where one ovary is extensively involved, the opposite one is prone to pick up and nurture epithelial cells that drop off from the papillary growth. If it is thought that the opposite ovary is still normal and a myomectomy is contemplated in the hope of preserving the menstrual function, the surgeon is in a quandary as to whether scattered tumor-cells may not engraft themselves upon the uterus at the point from which the myoma has been shelled out. Should both ovaries be involved, however, hysteromyomectomy with complete removal of the appendages is clearly indicated.

ADENOCARCINOMA OF THE OVARY OCCURRING WITH UTERINE MYOMATA.

No.	UTERUS.	RIGHT OVARY.	LEFT OVARY.
Path. 99	Uterus contains numerous myomata, the largest 4 x 4.5 x 5.5 cm.	Springing from a portion of the ovary is an adenocarcinomatous cyst 10 cm. in diameter.	A few papillary masses. Carcinomatous mass springing from a slightly enlarged ovary.
Gyn. 1637	Moderately small myoma to left of cervix not removed.	Adenocarcinomatous cyst contained 8500 c.c. of chocolate-colored fluid.	Ovary normal.
Gyn. 4020	Multinodular myomatous uterus, 15 x 19 x 21 cm.	Adenocarcinoma of right ovary, 5.5 x 6 x 7.5 cm. Secondary involvement of right tube.	Multicystic papillary carcinomatous masses on surface.
Gyn. 5528	Multinodular myomatous uterus, 8 x 11 x 12 cm.; later extension of ovarian carcinoma to body of uterus.	Adenocarcinoma.	Adenocarcinoma.
Gyn. 6479	Uterus contains several myomata, the largest 3.5 cm.	Apparently not implicated.	Semisolid adenocarcinoma, 7 x 8 x 9 cm.
Gyn. 9457	Uterus, 9 x 11 cm., contains two myomata, the larger 8 x 9 cm., also discrete adenomyoma.	Adenocarcinomatous cyst, 20 cm. in diam.	Adhesions, otherwise normal.
Gyn. 8675	Multinodular myomatous uterus, 6 x 8 x 11 cm. Largest myoma, 3 x 5 cm.	Contained papillary adenocarcinomatous mass, 1.5 cm. in diameter. Metastases in omentum wide-spread.	Two pedunculated budding papillomatous masses on upper border; adenocarcinomatous on histologic examination.
Gyn. 12041	Uterus 7 x 8 cm. Several myomata, the largest 4 cm.		Adenocarcinomatous; tumor small and densely adherent.

Adenocarcinoma of the Ovary.—In 8 of the 934 cases adenocarcinoma of the ovary was present. Macroscopically, it is often impossible to distinguish between papilocystomata and adenocarcinomata, and even on histologic examination one

is frequently unable to say with certainty whether or not the given specimen is really malignant.

In half of the cases the carcinoma was bilateral. From the table it will be seen that some of the carcinomata were very small and solid. Others had become cystic, and in at least two cases (Gyn. Nos. 1637 and 9457) the malignant tumors were relatively large.

In several of the cases the disease had extended to other structures. In Case 8675 the omentum was studded with secondary growths.

The uterus, in most of the cases, contained a few myomata of moderate size. Only in Case 4020 did the myomata reach large proportions.

Where carcinoma of the ovary and myomata exist, the better plan seems to be complete removal of the tubes, ovaries, and uterus. Seven of our patients were operated upon and all recovered temporarily.

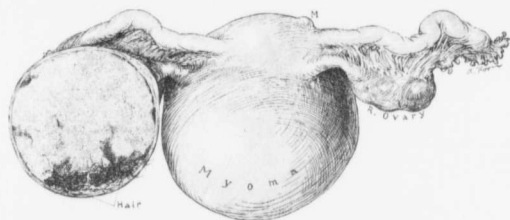


FIG. 243.—A DERMOID CYST ASSOCIATED WITH A MYOMATOUS UTERUS. ($\frac{1}{2}$ nat. size.)

Gyn. No. 3960. Path. No. 971. The specimen is seen from behind. The increase in the size of the uterus is caused by subperitoneal and interstitial myomata. The right tube and ovary are normal. The specimen has been hardened, and the left ovary cut in two. The solidified sebaceous material fills the greater part of the cyst. Projecting from the lower part of the cyst cavity are numerous black hairs.

Dermoid Cysts.—In 17* of the 934 cases dermoid cysts were encountered. They were usually unilateral, and fairly evenly distributed between the right and left ovaries.

The smallest dermoid was 3 cm. in diameter, the largest, 17 cm. The largest cyst (Case 3232) was multilocular, and nearly all the cysts were dermoids. It is a well-known fact that dermoid cysts tend to become adherent, and in fully two-thirds of our cases dense adhesions existed. In Fig. 243 we have an example of a small dermoid cyst associated with a myomatous uterus, and in Fig. 244 a multinodular uterus with a parovarian cyst on the right and a dermoid cyst of the ovary on the left.

In two of our cases (Gyn. Nos. 3008 and 10095), the patients died. In the first case the enucleation of the pelvic organs was exceedingly difficult, and the patient died with signs strongly suggestive of infection or obstruction. Death in the second case was supposed to be due to a myocarditis.

* Gyn. Nos. 3008, 3232, 3590, 3960, 4873, 6432, 7441, 7508, 7714, 7716, 8878, 10095, 10883, 10969, 11630, 11634, 12852.

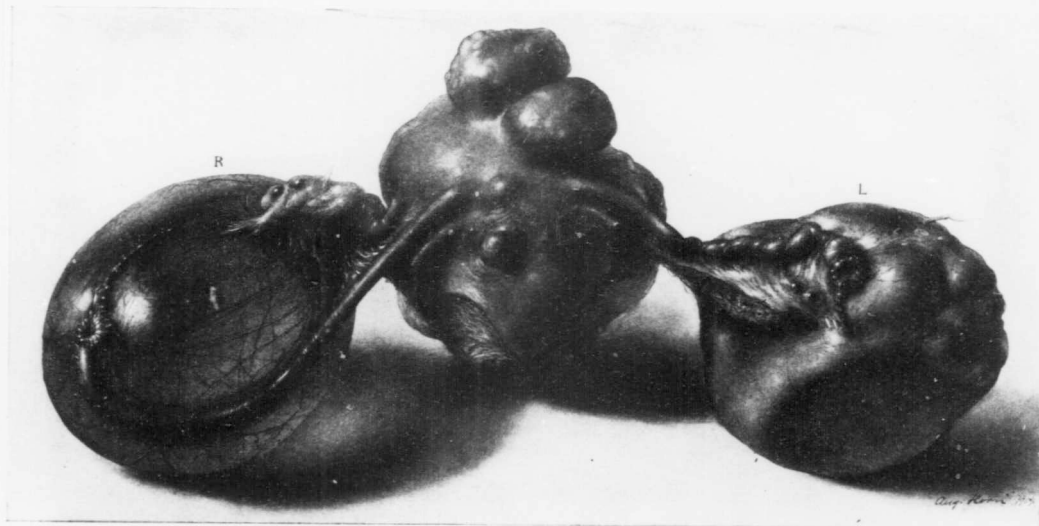


FIG. 244.—A MULTINODULAR MYOMATOUS UTERUS WITH A PAROVARIAN CYST ON THE RIGHT AND A DERMOID OF THE LEFT OVARY. ($\frac{1}{2}$ nat. size.)
 Gyn. No. 11630. Path. No. 7867. Scattered throughout the uterus are subperitoneal, interstitial, and submucous myomata. Between the tube and ovary on the right is a parovarian cyst which measures 8 x 8 x 10. The fimbriated end of the tube is carried out as a delicate fringe on the surface of the cyst.
 The left ovary measures 5 x 7 x 8 cm. It is lobulated, and presents two flat surfaces, on one of which it is resting. This flattening is due to the sagging of the cyst on the specimen dish, and this flat surface has become fixed by the solidifying of the sebaceous material, as a result of exposure to the air. It is pathognomonic of a dermoid cyst.

Fibroma of the Ovary.—In 3 out of 934 cases fibromata of the ovary were encountered and in each case the fibroma was unilateral. In Case 9090 the uterus contained several small myomata and the left ovary had been transformed into a fibroma 12 x 14 x 16 cm.

Attached to the uterus in Case 3294 was a pedunculated myoma 7 x 9 x 13 cm.; the left ovary had been converted into an enormous fibroma, 16 x 24 x 30 cm.

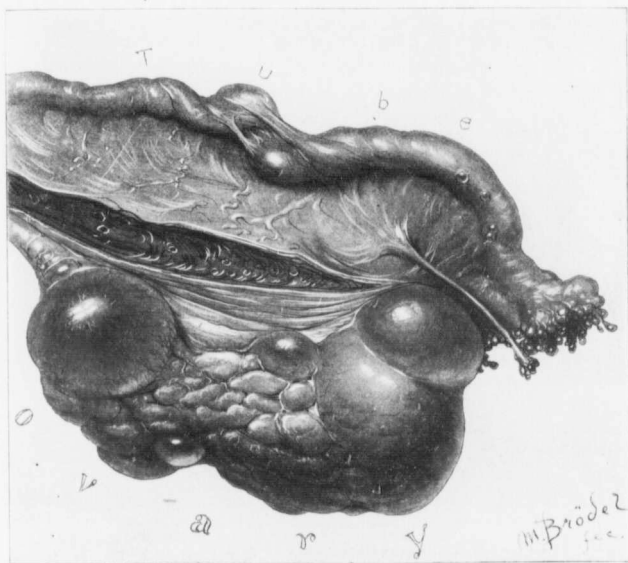


FIG. 245.—A VERY LARGE LEFT OVARY ASSOCIATED WITH A MYOMATOUS UTERUS. (Nat. size.)

Gyn. No. 5734. Path. No. 2034. The tube is much lengthened, and near its center is covered with a few bands of adhesions. The ovary measures 2.5 x 4 x 9 cm. The increase in size is in part due to the Graafian follicle, but the solid portion of the ovary is very coarse in texture and much increased in amount. (After Howard A. Kelly.)

The multinodular uterus in Case 10491 measured 10 x 17 x 20 cm.; developing from the right ovary was a fibroma 5 x 10 x 10 cm.

The occasional association of fibroma of the ovary with uterine myomata is of interest only to the pathologist and has no clinical import. If both are present, it is almost impossible to make a diagnosis before operation, and even with the specimen before him the surgeon at times mistakes the fibroma for a myoma and only after seeing its relations to the tube or on incising it does he realize the exact nature of the growth.

Alterations in the Location of the Ovaries.—With the frequent great increase in the size of the uterus, due to the continued growth of the myomata, the ovaries are gradually drawn away from their usual location. For example, in Case 4771 the left ovary and the sigmoid flexure were drawn high up on the surface of the tumor.

With the migration of the ovary there is naturally an altered relation of the ovarian vessels, and they may be found high up on the side of the tumor, as noted in Case 4022.

When the ovarian vessels supply a great deal of the nourishment to the tumor, they may reach large proportions, the veins in some cases being 1.5 cm. in diameter, as in Case 9767.

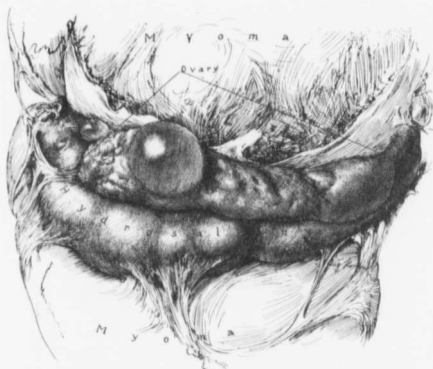


FIG. 246.—A GREATLY LENGTHENED-OUT OVARY ASSOCIATED WITH UTERINE MYOMATA. ($\frac{1}{2}$ nat. size.)

GYN. No. 10102. Path. No. 6299. The tube and ovary are wedged in between large myomatous masses. The tube has been converted into a large hydrosalpinx and is adherent to one of the myomata.

The ovary was markedly increased in size, being 3 x 13 cm. Even when pictured about half its natural length it is not only much longer than normal, but also much thicker. There is one small Graafian follicle cyst. The ovary was slightly edematous.

In some cases the great increase in size of the veins is evidently due to compression of the uterine veins between the tumor and the pelvic walls. The ovarian veins then return more venous blood than is their wont. The alterations relative to the pelvic structures must be most carefully borne in mind by the surgeon, otherwise the rectum or ureters may suffer serious injury.

Very Large Ovaries.—In two cases what might be termed gigantic ovaries were found. In Case 5734 the uterus had been converted into a nodular tumor, 14 x 19 x 27 cm. The right ovary was represented by a cyst, 6 x 8 cm. The left tube was 14 cm. long, and the ovary was much enlarged, being 2.5 x 4 x 9 cm. (Fig. 245). Part of the increase in size was due to a cystic Graafian follicle, but the ovary itself was much enlarged. In Case 10102 the abdomen, to within 8 cm. of

the costal margin, was filled with a hard myomatous tumor. The right ovary was greatly enlarged, measuring 3 x 10 cm. (Fig. 246). It contained a cystic follicle, but the great increase in size was due in part to edema.

The Merging of a Myoma into an Ovary.—This condition is exceptional. In Path. No. 4090 the uterus was 16 cm. in diameter and irregular in outline, owing to the presence of numerous myomata. The chief interest in the specimen is centered in the left ovary, which was apparently 7 cm. in length, and varied from 3 to 4 cm. in breadth. The outer end presents the characteristic lobulated appearance, but the inner end is exceedingly dense and nodular (Fig. 247). On splitting this supposedly large ovary, we found that the outer third was com-

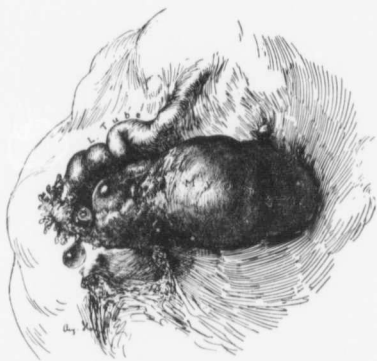


FIG. 247.—THE COALESCENCE OF A SUPERITONEAL PEDUNCULATED MYOMA WITH AN OVARY. (2 nat. size.)

Path. No. 4090. The sketch shows a small portion of a multinodular uterus, 16 cm. in diameter. The left tube is normal. Springing from the surface of the uterus, just behind the insertion of the left tube, is a pedunculated myoma, the outer pole of which has grown into and become continuous with the ovary.

posed of ovarian tissue, which, save for a Graafian follicle 1.5 cm. in diameter, presented the usual appearance. The inner two-thirds consisted of a subperitoneal myoma, which, on account of its proximity to the ovary, had burrowed into it in the manner that a ball would fit into a socket.

Parovarian Cysts.—Parovarian cysts were noted 19 times in the 934 cases of uterine myomata. In one case they were bilateral. These cysts varied from 1 cm. to 20 cm. in diameter. Fig. 244 is an excellent illustration of a parovarian cyst, as it shows clearly the relation of the cyst to the tube and ovary, and also the characteristic translucency. The opposite ovary is the seat of a dermoid cyst.

CHAPTER XIX.

CONDITIONS FOUND IN THE LIGAMENTS PASSING TO AND FROM THE UTERUS IN CASES OF UTERINE MYOMATA.

- I. Alterations in the broad ligaments.
- II. Changes in the utero-ovarian ligaments.
- III. Changes in the round ligaments.

I. ALTERATIONS IN THE BROAD LIGAMENTS ASSOCIATED WITH UTERINE MYOMATA.

As a rule, the broad ligaments show no alterations, but in a few instances we have noted marked changes. The following are those of especial interest:

1. A myoma separating the folds of the broad ligament.
2. A myoma densely adherent to the posterior surface of the broad ligament.
3. Great dilatation of the veins of the broad ligament.
4. Dilated lymph-spaces in the broad ligament.
5. Great thickening of the broad ligament, usually due to edema.
6. Abscess in the broad ligament secondary to a tubo-ovarian abscess.

Myomata of the broad ligament and adhesions to the broad ligament are discussed in the chapter on Treatment (p. 630).

Dilatation of the Vessels of the Broad Ligament.—As a rule, after splitting the peritoneum of the broad ligament the operator can readily free a myoma in this region, but in some cases great congeries of blood-vessels—chiefly veins—occupy the broad ligament and, if not gently handled, rupture and a troublesome, if not alarming, hemorrhage may ensue.

In Gyn. No. 77 the abdomen was filled with a multinodular myomatous uterus. The veins in both broad ligaments were enormously distended.

In Gyn. No. 6129 the myomatous uterus extended almost to the umbilicus. The surface of the tumor was covered with numerous vessels, and very large veins coursed over the broad ligament. Many ligatures were required to completely control the bleeding from these vessels.

In Gyn. No. 7237 the fundus was the size of a coconut and smooth. Coursing over its surface were large tortuous vessels. The broad ligaments with the greatly engorged tortuous vessels were drawn well up on each side of the tumor. When the broad ligaments were split, these veins looked like large earth-worms.

The large myoma in Case 8526 had developed chiefly in the right broad ligament, and the vessels on this side were much dilated.

The increase in size of the vessels of the broad ligament in these cases did not appear to be due in any measure to obstruction, but rather to the great vascularity of the tumor.

Parovarium.—In some cases the vessels passing between the tube and ovary are greatly enlarged. This is prone to occur when the tumor is of large proportions and requires much nourishment, or when the return of the venous flow from the uterus is retarded as a result of pressure.

Occasionally the parovarian tissue is much thickened and translucent. This may be due to edema, as in Case 3296, or to marked dilatation of the lymphatics, as in C. H. L., Case B., operated upon March 13, 1905.

Dilated Lymph-spaces in the Broad Ligament.—On p. 14 we discussed dilated lymphatics in the omentum associated with parasitic myomata, and on p. 72 dilated uterine lymphatics. If such conditions occur in the uterus, it is but natural that we should find them in the broad ligaments. A reference to Fig. 57, p. 73, will show greatly dilated lymph-vessels coursing over the surface of the uterus, and becoming lost between the tube and ovary.

In Case 5141,* in which the myomatous uterus extended far above the umbilicus, it was found that the myoma had developed to a large extent in the left broad ligament. In both broad ligaments were many dilated lymph-spaces.

The dilated lymphatics at operation stand out sharply, but after operation collapse and are readily overlooked.

Thickening of the Broad Ligament in Cases of Uterine Myomata.—Occasionally the broad ligaments are not only thickened, but also drawn upward to a considerable extent by the myoma. The thickening is usually due to edema.

In Case 6190 the uterus was enlarged and adherent, and on both sides were cystic appendages. The right broad ligament was thickened and edematous.

In Case 7528 the myomatous uterus extended 9 cm. above the umbilicus. There were broad adhesions between the ileum and broad ligament. There was extensive edema in both broad ligaments.

In Case 6863 the uterus contained several myomata and there were adhesions. Both broad ligaments were very edematous and thickened, and were drawn up over the fundus.

The myomatous uterus in Case 7064 was partially enveloped in adhesions. The left broad ligament was swollen and edematous; it contained markedly dilated veins, and was drawn up over and adherent to the fundus.

It will be noted that in each of these four cases in which edema of one or both broad ligaments existed, remains of pelvic inflammation were present.

Abscess in the Broad Ligament.—This condition, so common after a postpuerperal infection, is rarely associated with myoma. In Case 7313 the multinodular myomatous uterus contained sarcomatous nodules. The right tubo-ovarian abscess had opened into the broad ligament. It had then burrowed back to the rectum, and extended to the tissue directly beneath the vaginal mucosa. This case is reported in detail in the chapter on Sarcoma (p. 195).

Myomata themselves rarely, if ever, give rise to an abscess in the broad ligament.

* This case was reported in detail by Thomas S. Cullen, in the *Johns Hopkins Bulletin*, October, 1897.

II. CHANGES IN THE UTERO-OVARIAN LIGAMENTS.

In some cases the alterations are minor in character. For example, as a result of pressure from the enlarged uterus, the utero-ovarian ligaments may be much flattened, as in San. No. 1924. In other cases in which the uterus is much enlarged and there is hypertrophy of the uterine muscle the ligaments may be abnormally developed. This was particularly noticeable in Case 8866. The uterus measured 26 x 25 x 12 cm., the chief development being in the cervical portion; the utero-ovarian ligaments were unusually well developed.

In our experience tumors of the utero-ovarian ligaments have been of four varieties:

- (1) Cysts. (2) Myomata. (3) Adenomyomata. (4) Sarcoma (primary growth in the uterus).

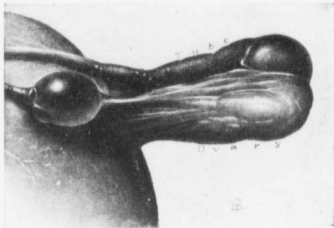


FIG. 248.—CYST OF THE UTERO-OVARIAN LIGAMENT.
($\frac{1}{2}$ nat. size.)

Gyn. No. 2763 a. Path. No. 286. Attached to a large myomatous uterus is an occluded right tube, on the surface of which are a few small subperitoneal cysts. The ovary is considerably drawn out. Incorporated in the right utero-ovarian ligament is an oval, thin-walled cyst with two small secondary cysts on its inner side. The cyst measured 4.5 by 3 cm.

were several small cysts containing a clear fluid (Fig. 249). Microscopically, these cysts were evidently dilated Graafian follicles. This is the only instance in which we have ever found the ovarian elements in the utero-ovarian ligament. When one examines the drawing carefully, it is seen that the ovary is displaced unusually far out, thus making the ligament abnormally long. Had the ovary been in its normal position, these apparently aberrant ovarian structures would in all probability have been included in the ovary.

Cysts of the Utero-ovarian Ligaments.—We have had two instances. In Case 2763 a the myomatous uterus measured 6 x 14 x 20 cm. in its various diameters. In the right utero-ovarian ligament was an oval cyst, 4.5 by 3 cm. (Fig. 248). Unfortunately, the specimen was lost, and no histologic examination could be made.

In Case 6667 the myomatous uterus was 18 x 15 x 12 cm. The right tube was normal. The ovary was drawn out, being 2 x 5 x 7 cm. The increase in size was caused by several large follicles. Situated in the utero-ovarian ligament

Gyn. No. 2763 a. Path. No. 286.

Myomatous uterus with adherent appendages and a cyst in the right utero-ovarian ligament (Fig. 248).

J. R., white, aged forty-four, married. Admitted May 4; discharged June

19, 1894. The myomatous uterus was large, irregular, and filled the pelvis and lower part of the abdomen.

Operation, May 7, 1894. Hysteromyectomy. The chief interest in the case is centered in the appendages on the right side (Fig. 248). The tube is the seat of a hydrosalpinx and the ovary is drawn out. Situated in the right utero-ovarian ligament is a cyst 4.5 x 3 cm. No histologic examination was made.

Gyn. No. 6667. Path. No. 2900.

Uterine myomata; subperitoneal, interstitial, and submucous; Graafian follicle cyst on the right side; small cysts in the utero-ovarian ligament (Fig. 249).

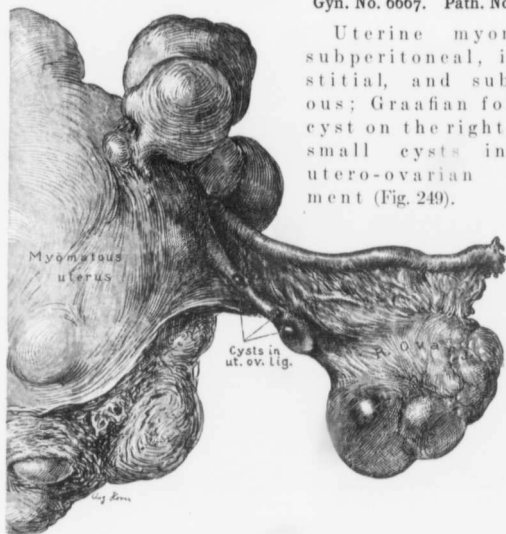


FIG. 249.—CYSTS IN THE UTERO-OVARIAN LIGAMENT. (Nat. size.)

Gyn. No. 6667. Path. No. 2900. Attached to the large multinodular myomatous uterus are the right tube and ovary. The ovary contains two dilated follicles. In the right utero-ovarian ligament are three cysts. On histologic examination they are found to be typical Graafian follicles.

A. V., colored, aged thirty-eight, married. Admitted January 27; discharged February 27, 1899.

Operation, hysteromyectomy.

Path. No. 2900. The specimen consists of the uterus, tubes, and ovaries. The uterus is a nodular tumor, 18 x 15 x 12 cm. Springing from its surface, chiefly from the fundus, are numerous pedunculated and sessile myomata, varying from 1 to 6 cm. in diameter. The uterine cavity is occupied by a large submucous myoma and two smaller ones. This large myoma is pear-shaped and 11 cm. in diameter. Our chief interest centers in the right utero-ovarian

ligament. The tube is normal, the ovary is much drawn out, and situated in the utero-ovarian ligament is an oval cyst, 2 x 1 cm. (Fig. 249.) Near the uterus is a small cyst, 7 x 5 mm. There are no adhesions. The left tube is normal. The left ovary contains a thin-walled cyst.

Microscopic sections from the small cysts in the right utero-ovarian ligament show that they are typical Graafian follicles, and that they are essentially ovarian elements.

Myomata of the Utero-ovarian Ligaments.—We have had five cases of this character, and all were associated with uterine myomata. They varied from 1 to 4.5 cm. in diameter. In Case 4609 there was a multinodular uterus, 12 cm. in diameter. Situated in the upper border of the right ovarian ligament was a myoma, 1 x 0.7 x 0.7 cm. In Case 4869 an irregularly globular myomatous uterus averaged 16 cm. in diameter. Springing from the left utero-ovarian ligament, about its middle, was a myoma about 2 x 2.3 cm. (Fig. 250).

In Case 7859 the uterus had been converted into a nodular tumor, approximately 12 x 10 x 10 cm. Histologic examination showed that the uterus was the seat of a diffuse myoma. Situated in the right utero-ovarian ligament was a myoma 2.5 cm. in diameter.

In Case 4252 the myomatous uterus was adherent to the pelvic floor and to the rectum. In the right utero-ovarian ligament was a myoma 2.5 x 2.5 cm. (Fig. 251).

In Case 9675 the myomatous uterus was free from adhesions. Springing from the anterior aspect of the right utero-ovarian ligament was a globular myomatous nodule, 4.5 cm. in diameter (Fig. 252). The right tube and ovary were normal.

On histologic examination these myomata all proved to be identical in structure, as they naturally would be, with those developing in the uterus.

Gyn. No. 4609. Path. Nos. 1307 and 1318.

Subperitoneal and interstitial uterine myomata, suppurating submucous myoma; small myoma of the right ovarian ligament; gonorrhoeal salpingitis.

M. T., white, married, aged fifty-two. Admitted August 31; died September 19, 1896. When the patient was operated upon she was in a very weakened condition; the urine contained albumin and casts.

Operation, September 14, 1896. Hysteromyectomy.

Path. No. 1318. The uterus is irregularly globular, measuring approximately 12 cm. in diameter. Springing from its surface are several firm, flattened bosses and two subperitoneal nodules, 3 cm. in diameter. The uterine walls contain numerous myomatous nodules, varying from 0.5 to 8 cm. in diameter. The largest of these is situated in the posterior wall; the central portion has been converted into two large cavities lined with a greenish yellow, exceedingly friable material. There are several submucous myomata, one greenish yellow and

suppurating. On the left side the appendages are normal. On the right side the ovary is covered with a few delicate adhesions. Situated in the upper border of the right utero-ovarian ligament is a firm myomatous nodule, 1 x 0.7 x 0.7 cm. This presents a glistening white surface and is composed of fibers concentrically arranged.

Gyn. No. 4869. Path. No. 1434.

Interstitial uterine myomata; slight pelvic adhesions; small myoma in the left utero-ovarian ligament (Fig. 250).

E. G., colored, married, aged thirty-four. Admitted December 9, 1896; discharged January 17, 1897.

Operation. Hysteromyectomy.

Path. No. 1434. The uterus is irregularly globular, averaging 16 cm. in diameter. Occupying the posterior wall, and extending down below the cervix, is a tumor 17 x 16 cm., presenting the usual myomatous appearance. On the right side the appendages are covered with a few adhesions. On the left side the tube is several centimeters long, and the fimbriae are slightly adherent to one another. The ovary is covered with a few vascular adhesions. Springing from the left utero-ovarian ligament about its middle is a myoma, 2 x 2.3 cm. (Fig. 250).

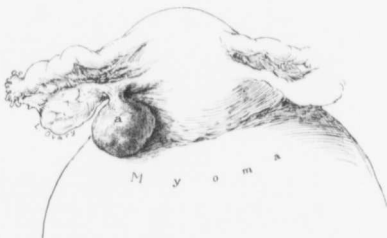

FIG. 250.—MYOMA OF THE UTERO-OVARIAN LIGAMENT. (1 nat. size.)
Gyn. No. 4869. Path. No. 1434. Situated on the posterior surface of the left utero-ovarian ligament near its middle is a myoma (a). This measures 2 x 2.3 cm.

Gyn. No. 7859. Path. No. 4122.

Multinodular myomatous uterus; diffuse adenomyoma of the body; numerous adhesions; right hydrosalpinx.

Springing from the right utero-ovarian ligament is a small myoma, 2.5 cm. in diameter. This case is reported in detail in "Adenomyoma of the Uterus," p. 109.

Gyn. No. 4252.

Myomatous uterus with a myoma in the right utero-ovarian ligament (Fig. 251).

A. C., aged forty, married. Admitted March 28; discharged May 9, 1896.

Operation. Hysteromyectomy. The myomatous uterus was retroflexed

and adherent to the pelvic floor. Situated in the right utero-ovarian ligament was a myoma, 3.5 by 2.5 cm. (Fig. 251).

Gyn. No. 9675. Path. No. 5870.

Uterine myomata; myoma of the right utero-ovarian ligament (Fig. 251).

N. B., aged forty-three, white, single. Admitted May 27; died June 3, 1902.

On admission she was suffering from chronic nephritis.

Operation. Hysteromyectomy. The uterus extended as high as the umbilicus. Situated in the right utero-ovarian ligament was a myoma, 4.5 cm. in diameter. In this case the fatal result was due to the nephritis.

Adenomyoma of the Utero-ovarian Ligament.—This condition is an exceedingly rare one, and we have had only one example (San. No. 1872). The uterus was 14 cm. in length and 13 cm. broad. Projecting from its surface were myomata varying from 2 to 9 cm. in diameter. Histologic examination showed that the mucosa manifested a definite tendency to extend into the muscle.



FIG. 251.—MYOMA OF THE RIGHT UTERO-OVARIAN LIGAMENT.

Gyn. No. 4252. To the left is a small portion of the myomatous uterus. Occupying the central portion of the right utero-ovarian ligament is a myoma which measured 2.5 x 3.5 cm.

Lying perfectly free from the uterus, and attached to the utero-ovarian ligament, was a pear-shaped myoma, 6 cm. in length, and varying from 3 to 4 cm. in thickness. Projecting slightly from its surface were cysts, one of which reached 1 cm. in diameter. On section, numerous cystic spaces were found scattered throughout the myoma. Some of these were filled with old coagulated blood and had a brown lining. Scattered here and there throughout the tissue were light-brown, porous areas, suggesting mucosa. Even macroscopically the diagnosis of adenomyoma was easy.

On histologic examination some of the cysts were found to be dilated glands; others were distended miniature uterine cavities. The porous areas were masses of typical uterine mucosa.

The case is described in detail in "Adenomyoma of the Uterus," p. 140 (Figs. 41 and 42).

Secondary Sarcomatous Nodule in the Utero-ovarian Ligament.—In Case 8610 (described in detail in the chapter on Sarcoma, p. 231) the uterus was approximately 12 x 14 cm., and was studded with sarcomatous nodules. Histologic examination strongly indicated that the sarcoma had resulted from a malignant change in the myomata. Situated in the right utero-ovarian ligament was a

sarcomatous nodule, 1.5 cm. in diameter. This on section was perfectly white in color, homogeneous in consistence, and resembled the sarcomatous uterine nodules.

III. CHANGES IN THE ROUND LIGAMENTS IN CASES OF UTERINE MYOMATA.

With the increased size of the uterus it is but natural that alterations in one or both round ligaments should be met with. We have found the following interesting conditions in our series:

1. An altered relation of one round ligament to the opposite one.
2. The round ligament as a tense band.
3. Great lengthening of the round ligament.
4. Hypertrophy of the round ligament.

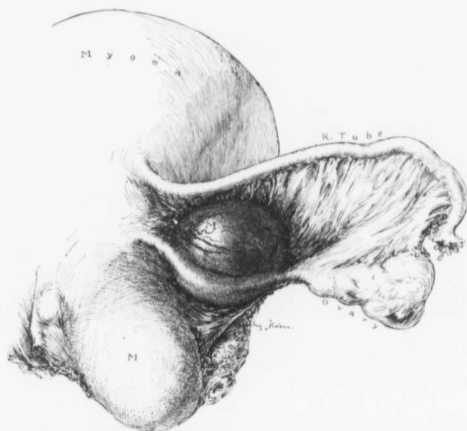

FIG. 252.—MYOMA OF THE UTERO-OVARIAN LIGAMENT. ($\frac{1}{2}$ nat. size.)

Gyn. No. 9675. Path. No. 5870. The right tube and ovary are normal. Growing from the anterior aspect of the right utero-ovarian ligament, and free from the uterus, is a globular myoma, 4.5 cm. in diameter.

5. Myoma of the round ligament.
6. Adenomyoma of the round ligament.

Altered Relations of One Round Ligament to its Fellow.—The relation of the ends of the round ligaments to one another is often an important point in the diagnosis between pregnancy and myoma. In some cases, on opening the abdomen, the surgeon, from the general contour of the uterus, cannot exclude pregnancy, although the clinical history in no way suggests it. Often a glance at the uterine insertion of the round ligaments will show that they are not over a few

centimeters apart, although the uterus is as large as that of a six months' pregnancy. This will usually indicate that the enlargement is due to a tumor situated in the posterior wall. In other cases when a myoma is developing in one side of the uterus the corresponding round ligament is drawn far up and is apparently inserted at a higher level than its fellow opposite. When pregnancy exists, there is usually an equable enlargement of the uterus, and although the distance between the round ligaments increases, their points of uterine attachment remain on the same level.

In Case 8371, when the abdomen was opened, we at first suspected pregnancy, but a glance at the round ligament at once solved the problem.

The Round Ligament as a Tense Band.—As a rule, bimanual examination will enable one to get only a general idea of the contour of the myomatous uterus and to determine whether the tumor is freely movable or fixed. Occasionally, as in Case 13025, the ligament may be outlined as a tense cord. In this case the tumor had developed from the fundus on the right side, and had drawn the right cornu high up into the abdomen. The right round ligament was 6 inches in

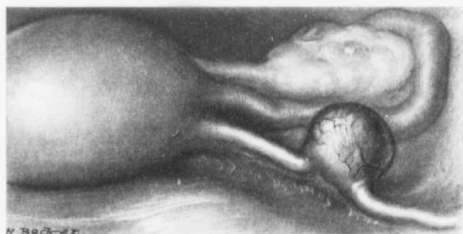

FIG. 253.—MYOMA OF THE ROUND LIGAMENT. (Nat. size.)

B. H., December 5, 1908. The uterus is normal in size, but the left tube is slightly thicker than usual. Springing from the upper border of the left round ligament, about 2 cm. from the uterus, is a myoma over 1 cm. in diameter. It was freely movable.

length, and on bimanual examination, with the patient under ether, it was felt as a tense band running from the right inguinal ring to a point near the summit of the tumor.

Great Lengthening of the Round Ligaments.—As one end of the round ligament emerges from the inguinal canal and the other merges into the lateral and anterior aspect of the uterus, it is but natural that any uterine tumor that enlarges or draws up the uterus should at the same time cause a lengthening of the round ligament. In our experience increased lengthening of the round ligaments has not caused a corresponding diminution in their diameters.

In Case 6915 the left round ligament was enormously lengthened out and almost lost in the tumor.

In C. H. I. (McA.) an 89-pound subperitoneal myoma filled the abdomen.

The uterus lay near the liver, and the round ligaments were greatly lengthened.

Hypertrophy of the Round Ligaments.—As a rule, the round ligaments are of the usual diameters, even when myomata exist. Occasionally, however, they are greatly hypertrophied.

In Case 8024 the uterus was about the size of that of a six months' pregnancy. Both round ligaments were greatly hypertrophied.

Both round ligaments were greatly lengthened and thickened in Case 5103, in which the lower half of the abdomen was filled with a multinodular myomatous uterus.

From an operative standpoint, it is always wise to be particularly careful that the round ligament is properly ligated. On several occasions we have seen the round ligament slip away from its ligature during the course of the operation, and considerable oozing follow. When there is much hypertrophy, the vessels are often of goodly size, and if not carefully tied, may later give rise to alarming bleeding.

Myoma of the Round Ligament.—Four of our myomatous uteri have been associated with myoma of the round ligament. In Case 8713 the multinodular myomatous uterus was the size of a child's head, and situated in the right round ligament was a myomatous nodule.

In Case 10669, Path. No. 6908, the nodular uterus was 10 x 6 x 6 cm. Situated in the right round ligament was a myoma 7 cm. in diameter.

Quite recently another myoma of the round ligament was found; this is shown in Fig. 253.

The myomatous uterus in San. No. 1058 (Path. No. 4616) was 20 x 20 x 12 cm. Situated in the right round ligament was a myoma, 6 x 3 x 3 cm., separated from the uterus by at least 1 cm. of normal round ligament.

The muscle of the round ligament is identical in character with that composing the uterus, and myomata of the round ligament accordingly present the same gross and histologic pictures.

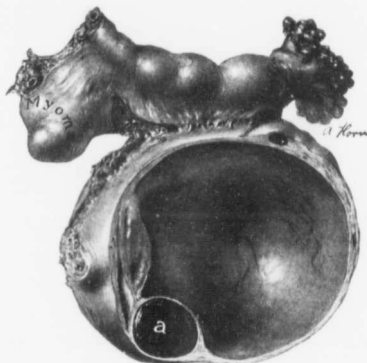


FIG. 254.—A MYOMA LYING FREE FROM THE UTERUS AND SITUATED BETWEEN THE TUBE AND OVARY. (Nat. size.)

Path. No. 8432. The tube is thickened, owing to a sacculated salpingitis. It is rare to have the fimbriated end open when such a condition exists. The ovary has been converted into a corpus luteum cyst. *a* is a small corpus luteum. Situated between the tube and ovary, and lying near the inner end of the tube, is a small nodular myoma.

Adenomyomata of the Round Ligament.—This condition is exceedingly rare. It fell to our lot to record the first case of this character.*

Vaginal examination did not indicate any increase in size of the uterus. Occupying the upper part of the right labium was an irregular mass, about 2 cm. in diameter. On removal it proved to be an adenomyoma of the round ligament. About eighteen months later another myoma was removed from the left round ligament in the inguinal region. This case is reported in detail in "Adenomyoma of the Uterus," p. 250.

Small Myoma Unattached to the Uterus and Situated between the Tube and Ovary.—In Path. No. 8432 we have a tube that is the seat of a mild inflammation, but nevertheless has a patent fimbriated end. The ovary contains a corpus luteum cyst. At the inner end of the tube, and lying between it and the enlarged ovary, is a small myoma (Fig. 254). It is entirely free from the uterus.

* Thomas S. Cullen, Adenomyoma of the Round Ligament, Johns Hopkins Hospital Bulletin, May and June, 1896. Further Remarks on Adenomyoma of the Round Ligament, Johns Hopkins Hospital Bulletin, June, 1898.

CHAPTER XX.

THE BLADDER IN CASES OF UTERINE MYOMATA.

POSITION OF THE BLADDER.

In the majority of our cases the bladder had retained its normal position; nevertheless, not infrequently* it had been carried up into the abdomen. This displacement of the bladder is dependent upon two main factors: (1) Upward pressure by subvesical myomata. (2) The gradual ascent of the bladder with the continued growth of the myomatous uterus.

The Upward Pressure of Subvesical and Intraligamentary Myomata.—When a myomatous nodule develops in the lower segment of the uterus and spreads

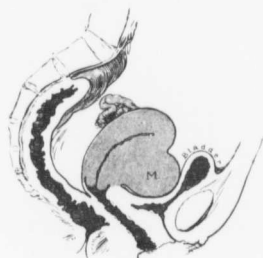

FIG. 255.—A SUBVESICAL MYOMA.
GYN. No. 4340. Projecting from the anterior surface of the uterus and encroaching on the bladder is a subvesical myoma which measured 4 x 4.5 x 8.5 cm. A myomectomy was done.

Although the nodule greatly diminished the mobility of the bladder, there were no local symptoms.

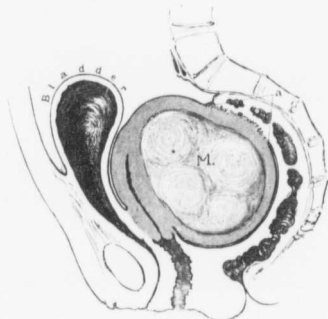


FIG. 256.—A BLADDER FORCED OUT OF THE PELVIS BY AN INCARCERATED MYOMATOUS UTERUS.

GYN. No. 7630. Occupying the posterior wall of the uterus is a large myomatous nodule. The uterus is firmly fixed in the pelvis by rectal adhesions, as indicated by a. The bladder, even when emptied, extends to within 4 cm. of the umbilicus. Its walls are much thickened.

out beneath the bladder, the latter is naturally carried upward on its surface. A similar condition may also be produced by a large myomatous uterus becoming impacted in the pelvis; much pressure is then exercised in all directions and the bladder is forced into the abdomen.

* Displacement upward of the bladder was noted in Cases 1682, 1703, 1752, 2777, 2822, 3113, 3133, 3218, 3340, 3445, 3842, 3882, 4020, 4022, 4285, 4293, 4340, 4771, 4801¹, 4832, 4902, 5086, 5332, 6178, 6206, 6376, 6582, 6628, 6863, 6915, 7049, 7064, 7226, 7237, 7240, 7397, 7630, 7832, 8008, 8368, 8866, 10778, 10969, 11180, 11792, 12194, 12520, 12841, 12864, and 13016. Displacement was undoubtedly present in other cases in which no note was made at operation.

In Fig. 255 we have an example of a subvesical myoma encroaching on the bladder and greatly diminishing its power of equable distention. As it fills, it must naturally dilate in its upper portion.

Fig. 256 shows a bladder that is becoming mainly an abdominal organ, as Douglas' sac is filled with a large myomatous nodule that has become incarcerated and has grown fast to the rectum.

A distinct subvesical myoma is not very common. In Case 2822 the myomatous uterus measured 23 x 25 cm. There was also a subvesical myoma, 8 x 12 cm.

In Case 4832 there was extensive subvesical development and several myomatous nodules.

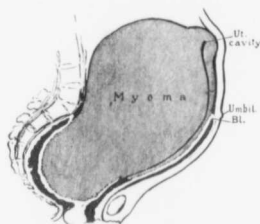


FIG. 257.—A BLADDER CARRIED AS HIGH AS THE UMBILICUS BY A LARGE MYOMATOUS UTERUS.

GYN. No. 1682. The fundus is recognized as a slight prominence high in the abdomen. The posterior wall is involved in a large myomatous growth, and the uterine cavity is greatly lengthened. The bladder is firmly pressed against the anterior abdominal wall, and has been carried upward on the surface of the tumor as far as the umbilicus.

The peritoneal reflection anteriorly only reached the umbilicus; posteriorly, the sacral prominence. The pelvic portion of the tumor was in reality extraperitoneal.

In such a case the abdominal incision should be commenced well above the umbilicus, as there is great danger of injuring the bladder.

limited space, and naturally carries the bladder with it.

Fig. 257 affords a good illustration. The entire posterior wall of the uterus is implicated in the myomatous growth. The upper part of the tumor has outgrown the pelvic confines and stretches high into the abdomen. The bladder has been carried upward on the surface of the myoma until it reaches the umbilicus. In such a case, if the operator attempted to open the abdomen below the umbilicus, he would at once enter the bladder. In some of these cases the lower limit of the abdomen is practically the umbilicus—the peritoneum from the abdominal wall being reflected back on to the tumor at this point.

The Rôle Played by Vesical Adhesions.—For marked displacement upward of the bladder it is usually necessary to have extensive development of the tumor,

In Case 7226 the bladder was drawn high up over the surface of a myoma, about 7 cm. in diameter, which had developed on the anterior surface of the uterus at the junction of the cervix and body.

In Case 11180 a nodule about 6 cm. in diameter projected into the bladder-wall.

It will thus be seen that the development under or the projection into the bladder by a myomatous nodule will materially alter the shape and position of this viscus.

The Gradual Ascent of the Bladder with the Continued Growth of the Myomatous Uterus.—When the myomatous development is in the upper part of the uterus, the bladder usually remains in its normal position, but if the growth involves the greater part of the uterus, with the growth of the tumor the entire mass is forced out of the pelvis, owing to the

but if the bladder has become adherent to the uterus early, it may be carried upward with it.

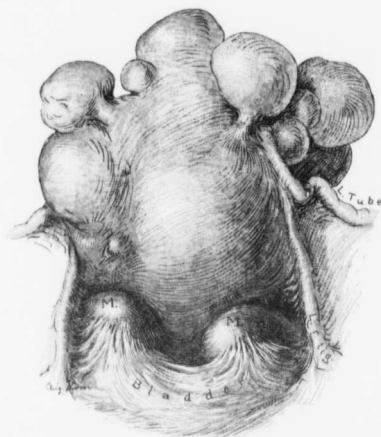


FIG. 258.—A BLADDER ADHERENT TO TWO MYOMATOUS NODULES.

Gyn. No. 6667. The body of the uterus is occupied by numerous myomatous nodules, and the round ligaments are taut. The bladder presents a festooned appearance, being drawn up at two points where it has become adherent to small myomatous nodules.

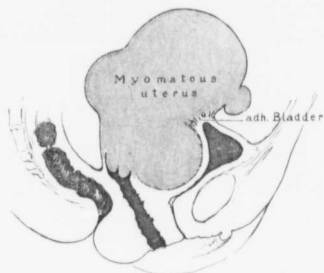


FIG. 259.—ADHESIONS BETWEEN THE BLADDER AND A MYOMATOUS UTERUS.

Gyn. No. 2777. The uterus contains several myomata and, just above a large subvesical nodule which presses the bladder against the symphysis, the bladder has become adherent. Naturally, with the increase in the size of the tumor, the bladder would be lifted higher and higher.

Fig. 258 shows a freely movable multinodular myomatous uterus. The bladder has become adherent to two small myomata, and with the growth of these is being gradually lifted up into the abdomen.

In Fig. 259 a slightly more advanced condition is seen. In the cleft just above a subvesical myoma the bladder has become firmly adherent to the myomatous uterus, and, as the tumor grows, will be carried higher and higher.

Fig. 260 shows another example of the effect of vesical adhesions. Here almost the entire anterior surface has become fixed to the uterus.

In Case 4020 (Fig. 261) the bladder lies plastered on the anterior surface of the tumor, and can be lifted well out of the abdomen.

In Cases 6863 and 7064 the bladder formed a complete mantle over the anterior surface of the uterus.

In Case 4022 (Fig. 262) the bladder was spread out on the lower half of a large myomatous uterus, and large vesical branches passed to the tumor. When

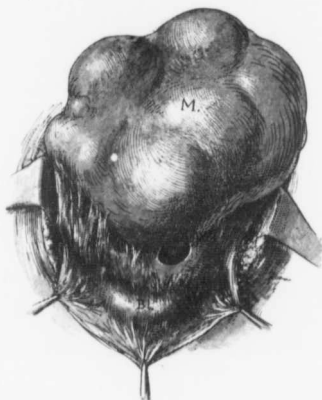

FIG. 260.—ADHESIONS BETWEEN THE BLADDER AND THE MYOMATOUS UTERUS.

GYN. No. 13629. The bladder peritoneum is firmly fixed to the anterior surface of the large myomatous uterus. At one point is a sickle-shaped opening where no adhesions existed. The ureters in this case were also displaced.

the bladder is intimately adherent to the tumor, the utmost care must be exercised in freeing it, and sometimes it is necessary to literally dissect it away. In such cases if the bladder be peeled down with the stalk sponge there is great danger of injuring it.

Downward Displacement of the Bladder.—When, as a result of a myomatous growth, the bladder is displaced, it is usually carried upward, but occasionally it may be displaced downward into the vagina. In Case 4761 the entire pelvis was choked with a hard globular myomatous uterus. A submucous myoma, approximately 12 x 15 cm., was removed through the vagina. In this case the bladder was displaced downward into the vagina, and micturition and defecation were interfered with.

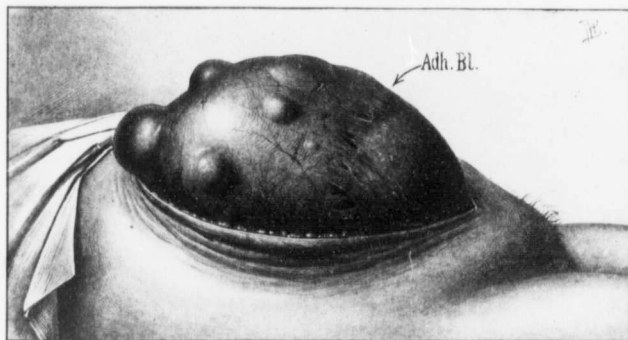


FIG. 261.—MARKED UPWARD DISPLACEMENT OF THE BLADDER.

GYN. NO. 4020. Path. No. 1009. The large globular myomatous uterus extended to within 8 cm. of the xiphoid. The bladder was adherent to the tumor, and with the increase in size of the uterus had been lifted high into the abdomen. (After H. A. Kelly.)

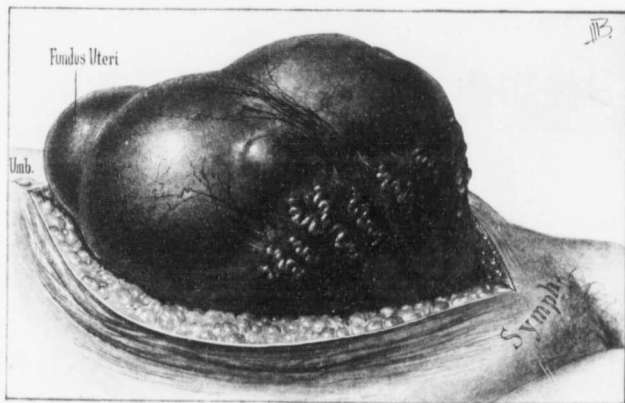


FIG. 262.—THE BLADDER LIFTED HIGH INTO THE ABDOMEN BY A MYOMATOUS UTERUS.

GYN. NO. 4022. Path. No. 1012. The nodular myomatous uterus extends upward to the umbilicus. The bladder has been lifted high into the abdomen. Its upper limits are clearly indicated at the point at which the enlarged and tortuous vesical vessels end. For nine months prior to operation the patient had difficult micturition. At times there was stoppage of urine, as if the bladder was being pressed upon by the tumor. (After H. A. Kelly.)

CONDITION OF THE BLADDER WALL WHEN THE VISCUS IS DRAWN UPWARD BY THE MYOMATOUS UTERUS.

In nearly all the cases the walls of the bladder, apart from adhesions on the outer surface, were perfectly normal. In five of our cases, however, some alteration was noted.

Hypertrophy of the bladder wall, 4 cases.

Hypertrophy with sacculation, 1 case.

In Case 3445 the patient had frequent micturition, and once it was necessary to catheterize. At operation the bladder reached to within 3 cm. of the umbilicus. Its walls were much hypertrophied, thick, and rigid. After operation, on account of the residual urine, it was necessary to catheterize almost until the time the patient left the hospital.

In Case 6178 a myomatous uterus extended almost to the umbilicus. Micturition was difficult at night, but after the patient had been up and about during the morning, she could void with ease. At operation the bladder was found to extend 14 cm. above the symphysis. Its walls were much thickened and its vessels large. When emptied, it fell into folds instead of contracting uniformly. For four days after operation it was necessary to catheterize.

In Case 6582 the pelvis was filled with a retroflexed myomatous uterus. For some time the patient had had frequent micturition, and on three different occasions during the previous six months it had been necessary to catheterize on account of retention. The bladder extended half-way to the umbilicus and had greatly thickened walls.

In Case 7630 a myomatous uterus was incarcerated and adherent in Douglas' cul-de-sac. For nine months the patient had had frequent micturition and marked constipation for some time. The bladder was hypertrophied and felt and looked like the body of a large uterus, but was more flabby. When emptied, it extended to within 4 cm. of the umbilicus.

In Case 11422 there was a small myomatous uterus. For two months there had been difficulty in starting the flow of urine. When catheterized prior to operation, the bladder contained 1400 c.c. The patient was watched for several days, and on no occasion did she completely empty the bladder. At operation the bladder was found well up in the abdomen and was sacculated. Three uterine nodules, the largest 5 cm. in diameter, were enucleated, and the round ligaments shortened. After the operation a severe cystitis developed. A vesicovaginal fistula was accordingly made, and after the inflammation had subsided, the bladder opening was closed.

In some of the cases the myomatous uterus undoubtedly pressed upon the bladder and rendered micturition difficult; the bladder had to exert more force than usual and hypertrophy naturally followed. In other cases the hypertrophy was an accidental accompaniment of the myomata. Thus, in Case 11422, the bladder condition completely overshadowed the few symptoms due to the relatively small uterine myomata.

ENCYSTED PERITONITIS SUGGESTING A FULL BLADDER.

In Case 5697 there were a densely adherent and rather small myomatous uterus and double pus-tubes. So firmly fixed were the pelvic structures that a point of cleavage was obtained with the greatest difficulty. Lying nearly where the bladder should have been was a pocket that resembled a full bladder. It was noted, however, that the peritoneum at one point was especially thin, and clear fluid could be seen immediately beneath it. It proved to be a pocket due to an encysted peritonitis.

INJURY TO THE BLADDER DURING OPERATION FOR REMOVAL OF UTERINE MYOMATA.

The injury usually consists in an accidental opening into the bladder. In many cases the bladder has been displaced up into the abdomen, and as a result the operator may cut through into this viscus, thinking he is opening up the abdominal cavity. In other cases the bladder has become intimately adherent to the myomatous uterus, and as it is pushed down prior to the hysterectomy, it may be torn. In a few cases the usual landmarks are lost and during dissection the bladder may be accidentally cut into.

Accidental Opening into the Bladder.—Case 1579 belongs to the early days of the hospital. The pelvis was filled with a globular mass, 12 cm. in diameter. During an exploratory operation an incision one inch long was accidentally made into the bladder. As the myomatous uterus was firmly fixed, hysterectomy was not attempted. The bladder opening was closed, and the patient recovered with no untoward symptoms. No urinary symptoms developed as a result of the injury.

In Case 8437 the uterus contained a globular myoma, about 11 cm. in diameter; the bladder was drawn far up, and as the abdominal incision was made, it was accidentally cut. The opening was closed without difficulty, and hysterectomy performed. The bladder injury in no way retarded the recovery.

Injury to the Bladder During Hysterectomy.—In Case 3113 there was a myomatous uterus, approximately 25 cm. in diameter, and the bladder was drawn high into the abdomen. During the removal of the tumor a piece of bladder, 3 x 6 cm., was accidentally brought away with the tumor. The ureters were at once catheterized through the bladder opening, and this alone saved them. The bladder was sewed up immediately with interrupted sutures and the abdomen drained. There were no untoward bladder symptoms during convalescence.

The myomatous uterus in Case 3319 was approximately 15 x 17 x 20 cm., and choked the pelvis. During its removal the bladder was accidentally incised. The opening was closed with catgut, and the patient made a good recovery.

In Case 3590 the patient was fifty-nine years of age and colored. The lower abdomen was markedly distended with a nodular tumor which reached the umbilicus. An exploratory section was done, and on account of the dense adhesions hysterectomy was abandoned. A second attempt was made a few months

later. Although adhesions were everywhere present and the heart was intermittent, hysterectomy was deemed advisable. During the enucleation dense adhesions were encountered and the bladder was accidentally torn for a distance of 12 cm. As one ureter lay near the tear it was catheterized and the bladder wound then sewn up. The pelvis was drained, and a retention catheter left in the bladder. The temperature reached 103.8° F. on the third day. When heard from nearly two years later the patient said she had been in perfect health since the operation, and that she had no discomfort of any kind.

In Case 3842 there was a densely adherent myomatous uterus and the bladder reached almost to the umbilicus. Dense adhesions existed between the uterus and the bladder, and during the separation of the bladder a piece, 1 x 6 cm., was excised with the tumor. The opening was closed with mattress sutures of silk. Intestinal and rectal adhesions were also present. The pelvis was drained. The patient was discharged on the thirtieth day.

During the removal of a myomatous uterus (12 x 14 x 19 cm.) and double pus-tubes in Case 5647 the bladder was accidentally opened. It was at once sutured, and a retention catheter introduced. The patient made a good recovery.

In Case 6915 the patient was forty-nine years of age and had a very large intraligamentary myoma on the left side. The body of the uterus was on a level with the umbilicus, and the bladder was likewise pushed up until it nearly reached this point. Enucleation was begun on the right side, and the large mass of ovarian veins lifted and tied with difficulty in the narrow space between the tumor and the pelvic brim. After section of the right round ligament the bladder was dissected off on the right side, revealing a large mass of knotted veins going from the bladder to the uterus. The right uterine vessels were tied, and the cervix was cut across. As the uterus was carefully lifted up there was suddenly an almost uncontrollable hemorrhage. Nothing remained but to enucleate as rapidly as possible in spite of the tremendous bleeding. With the uterus partly rolled out on the left side a large spurting vessel was caught and ligated. During the rapid dissection the bladder was torn from the trigonum to the symphysis. The opening in the bladder was at once closed with interrupted catgut sutures, going down to but not catching the mucosa. The highest postoperative temperature was 99.8° F. On the twenty-third day a mild phlebitis developed in the left leg; otherwise convalescence was perfect.

In Case 7049 a white woman, aged fifty-one, had an enormous myomatous uterus, 23 x 25 x 31 cm., with extensive subvesical development. The bladder peritoneum reached almost to the umbilicus. The incision was continued downward to the symphysis, but great care was exercised to avoid injuring the bladder. After much difficulty the left ovarian vessels were found and ligated. An attempt was then made to get a point of cleavage between the tumor and the bladder, but in doing so the bladder was accidentally opened for a distance of 12 cm. on the right side. The dissection was continued; the right uterine vessels were controlled on the outer side of the ureter, which was firmly adherent to the tumor

for a distance of 6 cm. It was now possible to pass a finger beneath the bladder, and the posterior surface was thus gradually separated from the tumor. After removal of the uterus the rent in the bladder was closed with twelve interrupted catgut sutures, extending to but not including the mucosa. These were reinforced with a second row of catgut. The highest postoperative temperature was 101° F. on the fourth day. She had a "heat-stroke" on the twelfth day, the temperature reaching 105.8° F. She was discharged well.

In Case 8836 bisection of the uterus was resorted to on account of the adhesions, and as the patient was in an alarming condition. During bisection the bladder and rectum were purposely opened. They were at once closed as soon as the uterus had been removed, but the patient never rallied, dying a few hours later. The tumor proved to be sarcomatous. The case is reported in full on p. 229.

In Case 10204, while gently pushing the bladder down from the myomatous uterus prior to doing a hysterectomy, we opened the bladder for a distance of 3 cm. It was at once sutured. Subsequently the patient developed a bronchopneumonia. She was discharged well on the forty-first day.

In Case 10916 the pelvis and lower abdomen were filled with a myomatous uterus. During the separation of many adhesions a large vein in the mesosigmoid was torn and profuse bleeding followed. As the bladder was pushed down it was torn for two inches. After removal of the uterus the tear in the bladder was closed with catgut and a vaginal drain introduced. The pulse rose steadily, and forty-eight hours after operation was 148. The highest postoperative temperature was 101.4° F. For four days there was a profuse vaginal discharge and bloody urine. After that the convalescence was normal.

In Case 11013 the patient, aged forty-nine, white, had first noticed her abdominal tumor fourteen years before admission. She had had severe and prolonged uterine bleeding, for two years had suffered from frequent urination, and during the last six months there had been an almost constant dribble. The urine had a foul odor, and at times contained pus. On admission she was in a state of chronic invalidism. The pelvis and abdomen as far as the ensiform cartilage were occupied by a multinodular myomatous uterus. During separation of the bladder from the surface of the tumor it was accidentally opened in two places, the error being due to not getting the proper layer of cleavage. After removal of the uterus the bladder openings were closed, and an extraperitoneal drain introduced down to the bladder. The highest postoperative temperature was 100.5° F. The patient was stupid and rather irrational for several days after the operation. She insisted on going home on the thirtieth day, although still weak.

In Case 12864 there was a very large myomatous uterus (see p. 239). After liberation of omental adhesions the tumor was lifted up and found to be firmly adherent in the pelvis. On account of its softness sarcoma was suspected. Satisfactory exposure was impossible, and during an attempt to dissect the tumor free on the left side the bladder was accidentally opened. It had been lifted

high up and been pushed forward by a retrovesical nodule. After removal of the uterus the bladder was controlled with continuous catgut and the pelvis drained. The patient was catheterized at first every hour. She was improving rapidly when discharged on the thirty-first day.

In San. No. 1049 the patient was sixty-five years of age and white. The large myomatous uterus, which extended almost to the costal margin, was firmly anchored behind to the rectum, in front, to the bladder and anterior abdominal wall. The tumor was bisected transversely, and the dense bladder and abdominal adhesions were attacked from the under surface. Many raw and bleeding surfaces were left, and a hole 2 cm. in diameter was found at the apex of the bladder. This was closed with catgut. The large raw area on the abdominal wall was approximated as far as possible. The patient made a good recovery. It is of interest to note that an exploratory operation had been done thirty years before and the case pronounced inoperable.

In the chapter on Treatment it has been noted that few vaginal hysterectomies have been performed, and hence the bladder injuries complicating vaginal hysterectomy have been correspondingly limited. In only one case was the bladder accidentally opened.

In Case 2754, during removal of a small myomatous uterus, the base of the bladder was opened for 4 cm. It was at once sutured. The patient complained of pain in the bladder for several days after operation, but made a good recovery.

From our study of the relation of the bladder to the uterus and the various accidents that have occurred to it during hysterectomy some valuable data may be derived:

(a) The bladder should always be carefully palpated with a catheter while the urine is being withdrawn on the operating table, to determine if it is of normal size or not. If it reaches up into the abdomen, the incision should be made up near the umbilicus. After section, a finger in the abdomen serves as a guide as to the location of the bladder.

(b) In freeing the bladder from the uterus very little force should be used with the stalk sponge, and if it seems fixed, it is better to carry out the dissection with the knife, the cutting edge being, of course, directed toward the tumor and not toward the bladder.

(c) After all hysteromyomectomies it is important to carefully examine the bladder and rectum to see if they have been injured.

(d) If the bladder is accidentally opened, the tear may be closed with interrupted or continuous catgut sutures, catching up all but the mucosa. This row of sutures should be covered in with a continuous fine Pagenstecher or silk suture. The greatest care must be exercised not to pierce the vesical mucosa, as the suture might form the nidus for a subsequent calculus. If the tear be near the ureter, it is wise to outline clearly the ureter by means of a ureteral catheter while the sutures are being introduced; and if the ureteral orifice is too close to the incision, a slit 1 cm. long may be made in it.

(e) As injuries of the bladder are usually associated with dense pelvic adhesions, it is frequently advisable to drain through the vagina.

(f) We realize the shortcomings of a retention catheter, but notwithstanding its drawbacks, we unhesitatingly recommend its use for the first two or three days in cases in which the bladder has been accidentally opened.

(g) Injury to the bladder, if recognized and attended to, does not materially increase the risks. In only one of our cases did death follow, and here the fatal issue was due to immediate shock.

Injuries to the bladder are bound to occur, especially in the presence of dense adhesions, where the viscus is displaced, and we deem ourselves fortunate that this accident has not befallen us more frequently. In desperate cases, when the patient is exceedingly weak or when alarming hemorrhage is going on, the speedy removal of the uterus is infinitely more important, even if the bladder is injured, than a careful dissection of the bladder with the collapse and probable death of the patient before the operation is completed. As our class of myoma cases is becoming more and more difficult each year, we must naturally expect a continuance of a certain number of injuries to the bladder.

HYSTEROMYOMECTOMY WITH THE SUBSEQUENT PASSAGE OF A SILK LIGATURE FROM A UTERINE ARTERY INTO THE BLADDER.

Case F., seen in consultation with Dr. A. Trego Shertzer at the Church Home and Infirmary, August 10, 1902. The operation was very difficult. There was a very large strangulated umbilical hernia and a huge myomatous uterus with its lower portion molded to the pelvis (Fig. 94, p. 120). The patient made a good recovery.

Months after she brought to one of us (Cullen) a small loop of thread which she had just passed from the bladder. It was a silk ligature from one of the uterine arteries. The loop was perfect, and the two ends of the ligature were intact. The ligature had evidently lain in the bladder some little time, as it was partly incrustated. The stump of one of the uterine arteries had evidently lain in contact with the bladder, and the ligature had gradually worked its way through. It had occasioned the patient little or no inconvenience.

A VESICAL CALCULUS ASSOCIATED WITH UTERINE MYOMATA.

Vesical calculus was noted in only one instance. In Case 5946 the patient, aged fifty-two, white, had a large myomatous uterus which almost filled the abdomen. For the previous year she had had attacks of pain in the bladder and frequent micturition, hematuria, tenesmus, and sudden stoppage of urine. The vesical symptoms had been almost continuous for the nine weeks prior to operation.

A catheter introduced into the bladder at once came in contact with a calculus. An attempt was made to remove the stone through the urethra, but it

was found necessary to extract it through a vesicovaginal incision. The opening was at once closed, and a retention catheter introduced. Recovery was satisfactory.

BLADDER SYMPTOMS ATTRIBUTABLE TO THE MYOMATA.

In the greater number of the cases the patient gives no history suggestive of bladder disturbance. In a certain small percentage, however, definite vesical symptoms are present. These and their order of frequency may be stated as follows:

1. Frequent urination.
2. Frequent and painful urination.
3. Retention of urine.
4. Loss of control.

Frequent urination is the most common bladder symptom. It is evidently due, in many instances, to the encroachment of the myomatous uterus upon the bladder, which necessitates the more frequent emptying of this viscus. This increased frequency in micturition differs entirely from that due to cystitis. In many cases there is absolutely no pain, and getting up at night to void is most uncommon. Out of 109 cases in which there was frequent and painful micturition, only 6 of the patients had to rise at night.

Frequent and Painful Urination.—There is often a feeling of discomfort or weight, rather than pain, in the bladder during micturition. Some patients, however, have definite vesical pain and tenesmus when voiding. The pain is evidently due to the fact that the tumor pushes the two bladder-walls together, and in those cases in which the bladder has become adherent to the tumor and has been drawn far up into the abdomen, it is impossible for it to contract properly and satisfactorily empty itself. This naturally tends to produce tenesmus.

Retention of Urine.—In 20 cases* partial or complete stoppage of urine was noted. Sometimes there was difficulty in starting the flow, as in Case 10991; in others sudden obstruction, as in Case 12293. In Case 13016 there was acute obstruction for twenty-four hours. In Case 2073 catheterization was also necessary. The retention is undoubtedly due to the tumor shifting in such a manner that the urethra or bladder is so jammed against the symphysis that escape of urine is impossible. The stoppage of urine rarely lasts over twenty-four hours. It may be periodic, as in Cases 516 and 9057. When the tumor has passed high into the abdomen, the tendency to retention is diminished.

Loss of Control.—In Cases 7063, 7583, 9798 the patients had a feeling of pressure on the bladder or had frequent micturition, and at times great difficulty in preventing the urine from dribbling out.

In Cases 1039, 3133, 5421, and 11587 there was at times complete loss of control. In each of the 7 cases the pressure of the tumor on the bladder seemed to be the cause of the disturbance.

* Retention was noted in Cases 516, 1495, 1499, 1716, 2073, 3038, 4022, 4168, 5332, 5987, 6854, 6992, 9057, 9612, 10969, 10991, 12154, 12257, 12293, and 13016.

CYSTITIS ASSOCIATED WITH UTERINE MYOMATA.

Despite the fact that the bladder may be displaced and altered in its shape by the myomata, vesical inflammation is rarely found. In only two of our cases was it particularly prominent.

In Case 4599 there was a marked cystitis on admission, and in Case 11013 a constant dribble of offensive urine.

The fact that the bladder mucosa is usually normal in myoma cases has a definite surgical import. If the bladder be accidentally opened, we know that if it be properly sutured the accident has in no way increased the tendency toward infection.

CHAPTER XXI.

THE URETERS IN CASES OF UTERINE MYOMATA.

1. Position.
2. Double ureter.
3. Pressure on the ureters.
4. Accidental ligation.
5. Injury to the ureter during operation.
6. Removal of a tuberculous kidney and ureter shortly after hysteromyectomy.
7. Locating the ureters during operation.

POSITION OF THE URETERS IN CASES OF UTERINE MYOMATA.

When uterine myomata spread out from the surface of the uterus and lie free in the abdominal cavity, as a rule, little anxiety need be felt about the ureters,

but if an interstitial myoma spreads out between the folds of the broad ligament, the ureter may be dislodged, and at times lie on the surface of the tumor. A similar condition is occasionally noted when cervical myomata reach large proportions.

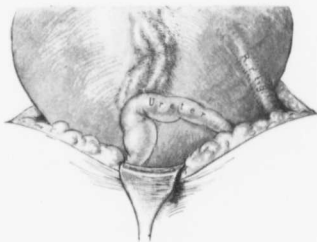

FIG. 263.—DISLOCATION AND DILATATION OF A URETER DUE TO A LARGE MYOMATOUS UTERUS.

Gyn. No. 2899. Only a small part of the uterus, which filled the entire abdomen, is seen. To the right is the right round ligament. The right ureter is much dilated, and was displaced so high that a portion of it was brought out of the abdomen with the tumor. It might readily have been mistaken for a dilated lymphatic vessel (see Fig. 57, p. 73) and severed. The congeries of vessels just above the loop of the ureter are the ovarian vessels.

Both ovaries and the left ureter were also lifted high into the abdomen.

pelvis. The left ureter was ligated, but not cut. Later, the mistake was recognized and the ureter liberated. The ureter on the right side was detected early in the enucleation and was not injured.

In Case 3133 the abdomen was filled with a myomatous uterus. The fundus lay near the ribs in the median line. The bladder rose 8 cm. above the symphysis, and the ovarian veins were greatly distended. The sigmoid was adherent to the tumor, about 8 cm. above the pelvic brim. After this had been freed, the left ovarian vessels were ligated. The left ureter was found adherent to the posterior surface of the tumor, and was freed. The left uterine vessels were then ligated. The right ureter as it entered the broad ligament was compressed, and its upper portion was about 2 cm. in diameter. It was dissected down to the bladder.

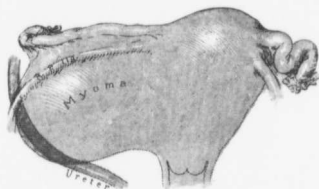


FIG. 264.—A MYOMA IN THE BROAD LIGAMENT DISPLACING THE RIGHT URETER UPWARD AND FORWARD.

Gyn. No. 3971. Occupying the right broad ligament is a large myomatous nodule. The right ureter has been lifted upward and forward, and crosses just at the point where one would naturally tie the right ovarian vessels.

Fig. 264 shows the altered position of the ureter due to a broad-ligament myoma. In this case (Gyn. No. 3971) it was so situated that it might readily have been tied with the right ovarian vessels.

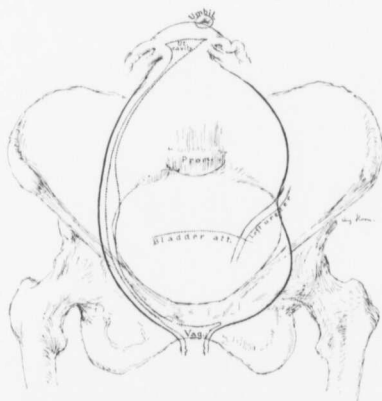


FIG. 265.—DISLOCATION UPWARD AND FORWARD OF THE LEFT URETER BY A MYOMATOUS UTERUS.

Gyn. No. 6017. The myomatous uterus reaches the umbilicus, and the greatly lengthened-out uterine cavity can be traced by the dotted lines to the vagina.

The left ureter passes over the surface of the tumor at the level of the pelvic brim, and is inserted into the bladder, which is lifted high up into the abdomen. In reality it does not enter the pelvis at all.

free for a distance of from 8 to 10 cm. before the removal of the uterus was begun.

In Fig. 265 (Case 6017) we see the bladder and left ureter lifted high up by a myoma which filled the pelvis and reached to the umbilicus. The ureter was recognized and carefully freed.

In Case 9457 the uterus was the seat of a diffuse adenomyoma and the right ovary was replaced by a large cyst containing cancerous areas. Each ureter, after passing over the pelvic brim, ran almost a straight course to a point near the corresponding uterine horn. Both ureters were dissected

the removal of the uterus

Fig. 266 shows a ureter passing directly across from the pelvic brim to the bladder without dipping into the pelvis.

Dislocated ureters were also noted in Cases 3281, 4168, and 8391. This by no means represents the total number, but only those especially mentioned in the notes made at operation.

Dr. J. H. Mason Knox,* in 1900, published an excellent article on the effect of

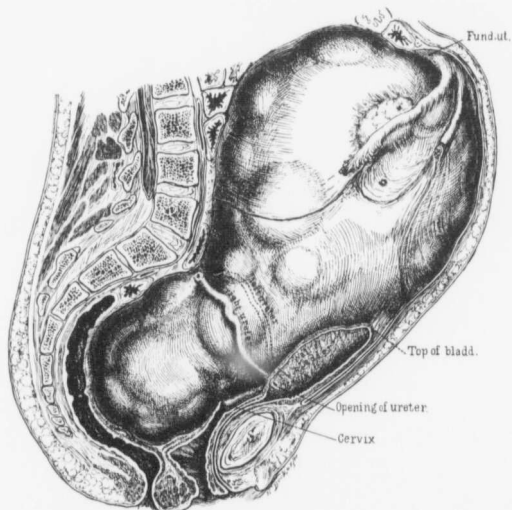


FIG. 266.—MARKED DISLOCATION OF THE URETERS WHERE THE ABDOMEN WAS FILLED WITH A MYOMATOUS UTERUS.

The fundus is situated high in the abdomen, and the right ureter is seen plastered on the surface of the tumor. Starting near the fimbriated end of the tube is the peritoneal reflection. This can be followed backward to a point a short distance above the sacral prominence. Anteriorly, it reaches a little below the umbilicus; thus more than half of the tumor is extraperitoneal.

The bladder is raised high up, and the right ureter passes directly across the pelvic brim to the bladder. The left ureter is seen at a slightly higher level, as indicated by the dotted lines.

This operation was rendered more difficult from the fact that the lower portion of the myoma filled the pelvis so snugly. (After Howard A. Kelly.)

pressure of myomata on the ureters, and discussed fully most of those cases that had been observed in the gynecological department of the Johns Hopkins Hospital prior to that date.

* J. H. Mason Knox, Compression of the Ureters by Myomata Uteri, *Amer. Jour. Obst.*, 1900, vol. xlii, No. 4.

DOUBLE URETER.

In case C. H. I. 949, while dissecting out the left ureter, we found two ureters instead of one. They ran side by side to within about 1.5 cm. from the bladder, and then entered the bladder as a single ureter. It is well to bear in mind the possible existence of a double ureter. If there is a double ureter and one is ligated, the portion of the kidney connected with the ligated ureter will naturally be thrown out of function.

PRESSURE ON THE URETERS EXERTED BY UTERINE MYOMATA.

In Chapter XXIII (p. 396) we have described the condition of the ureters in cases of uterine myomata coming to autopsy. Here we will briefly refer to the deviations from the normal noted at operation.

Before performing an abdominal hysteromyomectomy the urine is carefully examined, and if any marked evidence of renal infection exists, when possible, operation is avoided. Consequently, we would not expect to find any serious alterations in the ureters in the operable cases.

As a result of the pressure of the myoma, one or both ureters may be so flattened or kinked that above the point of obstruction a hydro-ureter develops.* In our experience the right ureter is more frequently implicated than the left. In a few cases, as in No. 2899 (Fig. 267) and 8391, both ureters were dilated.

The obstruction may be in the pelvis or just at the pelvic brim. The size of the ureter will depend, of course, on the degree of obstruction. It may be twice its natural size, as in Case 6418; it may reach 1.3 cm. in diameter, as in Case 7597, or 1.8 cm., as in Case 8391. Occasionally the size may be enormous, as in Case 10204, in which the left ureter above the pelvic brim formed a sac 4 cm. in diameter. Such a large ureter may at first be mistaken for a loop of small bowel, but it has no mesentery, has thin walls, and contains transparent fluid.

*Hydroureter was noted in Cases 2703, 2899, 3426, 4020, 6418, 7537, 7597, 7832, 8391, 10204, and 10462.

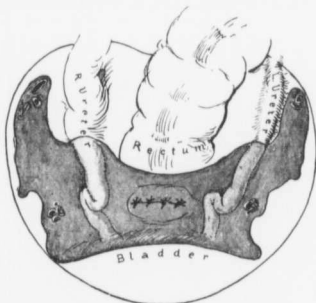

FIG. 267.—HYDROURETER DUE TO PRESSURE.

Gyn. No. 2899. The abdomen was, to within 4 or 5 cm. of the ensiform cartilage, filled with a hard myomatous uterus. Both ureters were lifted high out of the pelvis. The left was accidentally tied, but later discovered and released.

The sketch shows the pelvis after removal of the uterus. The right ureter is markedly dilated; the left also to a limited degree.

ACCIDENTAL LIGATION OF THE URETER DURING HYSTEROMYOMECTOMY.

We have records of several cases in which one ureter was accidentally tied, either when the uterine artery was being controlled at the side of the cervix or when, owing to marked displacement, the ureter lay close to the point at which the ovarian vessels were ligated.

In Case 659 a large, densely adherent cystic myoma filled the abdomen. It was impossible to remove the growth, but the ovarian and uterine vessels on both sides were ligated. The patient did fairly well after the operation, but died suddenly on the eighth day. Aut. No. 188 showed a very large cystic myoma and general anemia; one kidney was the seat of hydronephrosis, the other of pyelonephrosis with renal abscesses. The left ureter was occluded by a ligature. The abdominal condition was in itself sufficient to cause the fatal issue, but death was undoubtedly hastened by the accidental ligation of the ureter.

In Case 2899 the entire abdomen was filled with a myomatous uterus. The tubes, ovaries, and ureters were lifted high out of the pelvis. Both ureters were dilated. The left was accidentally ligated, but the error was later discovered, and the ureter was released. The patient recovered.

In Case 3272 a globular myomatous uterus filled the pelvis. The right ureter was tied. Later, the mistake was discovered and the ureter released. The patient recovered.

During the removal of a large myomatous uterus complicated by an ovarian cyst in Case 6344 (Fig. 242, p. 347) the left ureter was accidentally included in the ligation controlling the left uterine vessels. After removal of the uterus the left ureter was located at the pelvic brim, and followed down to the cervix. After the ureter had been freed, the uterine vessels were retied. The patient recovered.

In Case 8321 the myomatous uterus, which filled the pelvis, was removed from left to right. During ligation of the right uterine artery the ureter was included. The error was discovered and rectified. The patient recovered.

In C. H. I. R., October 24, 1902, the patient was very anemic. The pelvis was filled with a multinodular myomatous uterus, and occupying the vagina was a large globular submucous nodule. On the right side the ovarian vessels were controlled with the utmost difficulty on account of their distorted position. After removal of the uterus the right ovarian stump was examined and the ureter found included in the ligature. It was released without much difficulty, and the patient made a perfect recovery.

From the foregoing we see that in only one case did we fail to discover the ligated ureter before the abdomen was closed. In this case death followed. Temporary ligation does not seem to materially injure the ureter.

INJURY TO THE URETER DURING HYSTEROMYOMECTOMY.

In two of our cases the ureter was accidentally cut during the hysteromyomectomy. In both cases a uretero-ureteral anastomosis was done, in one case with failure, in the other with success.

Gyn. No. 11989.

Hysteromyomectomy; accidental cutting of the left ureter; uretero-ureteral anastomosis; failure; subsequent removal of the left kidney; recovery.

R. R., white, aged thirty-five. Admitted March 23, 1905. For several years she had had frequent urination and had been forced to get up several times at night to void. There had been pain and pressure over the bladder.

During the removal of the myomatous uterus, which reached to the umbilicus, the left ureter was cut. The ureter was at once anastomosed into itself, and an extraperitoneal drain carried down to the ureter.

On the day following it was evident that the urine from the left kidney was not reaching the bladder, and as none escaped along the extraperitoneal drain, the vaginal vault was opened, nitrous oxid anesthesia being employed. A small

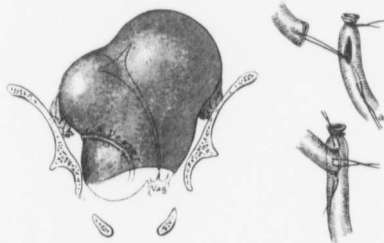


FIG. 268.—DISPLACED RIGHT URETER MISTAKEN FOR A DILATED VEIN; LIGATED AND CUT; SUCCESSFUL END-TO-SIDE ANASTOMOSIS.

Gyn. No. 1946. The dotted line indicates the course of the uterine cavity. The right ureter had been lifted high on the side of a myomatous nodule, and being mistaken for a vein, was ligated and cut.

a indicates one of the two traction sutures by means of which the upper end of the ureter was drawn down into the slit on the side of the lower end of the ureter and held in place until the ten approximation sutures had been introduced and tied. The traction sutures were then removed as they entered the lumen of the ureter, and later might have become incrustated.

amount of blood-tinged fluid escaped. The patient gradually improved. An (ether) examination revealed the fact that the fistulous tract leading from the previous ureteral anastomosis had made its way down and out through the stump of the cervix.

It was thought that it might be possible to go in extraperitoneally and reanastomose the ureter. There was, however, too much peri-ureteritis to warrant such a procedure. The urine from the bladder and from the drainage tract had been carefully examined for urea. It was found that the right kidney was secreting from 1000 to 1200 c.c., with about 10 gm. of urea to the liter. This was thought sufficient to allow the removal of the left kidney, and as the patient refused to go home and wait for two or three months to see if the fistulous tract would close of its own accord, removal of the left kidney was undertaken. The highest postoperative temperature was 100° F., and the patient made a good recovery.

Gyn. No. 1946.

Accidental severance of the displaced right ureter during hysteromyomectomy. Successful uretero-ureteral anastomosis (Fig. 268).

F. M., aged twenty-five, colored. Admitted April 26; discharged June 13, 1893. During the removal of a large myomatous uterus what appeared to be a large vein on the right side was ligated and cut, when it was found to be the ureter. The upper end of the ureter was invaginated into the opening made in the side of the lower portion, the invagination being accomplished by means of two temporary sutures (Fig. 268). Accurate approximation was now obtained with ten fine silk sutures. A gauze drain was inserted in the pelvis and the patient made an uninterrupted recovery.

REMOVAL OF A TUBERCULOUS RIGHT KIDNEY SHORTLY AFTER A HYSTEROMYOMECTIONY.

The following case shows clearly what extensive operations even a weak patient may be able to stand.

Gyn. No. 12866. Path. No. 9755.

L. T., aged thirty-nine, white, married. Admitted April 23; discharged July 26, 1906. The patient entered the hospital complaining of pain in the bladder, rectum, and back.

Three years before she had been under treatment on the surgical side of the hospital for tuberculosis of the right hip. At that time the joint was aspirated and a cast was put on. She remained in the hospital for three months.

Urination had been very frequent and painful for the last year, and there was much vesical tenesmus after voiding.

Cystoscopic examination revealed extensive ulceration of the vertex posteriorly, and also on the right side. The right ureteral orifice was much reddened. The left ureteral orifice was retracted, and from it pus was exuding.

On pelvic examination the right ureter was palpable, hard, and prominent. A firmly fixed myomatous uterus filled the pelvis.

On section of the abdomen the omentum was found adherent. Many adhesions were found in the region of the cecum, and several small tubercles were detected on the cecum and scattered over the loops of small bowel in the vicinity. The appendix was not seen. After much difficulty the adherent uterus with its appendages was removed.

The right ureter was much thickened and indurated. The right kidney was movable, and about twice its natural size. The liver was fixed to the anterior abdominal wall. The left kidney was normal in size. The tuberculous process in the abdomen seemed to be limited to the right iliac fossa.

Path. No. 9755. Examination of the pelvic contents revealed interstitial and submucous uterine myomata, tuberculosis of the endometrium, tuberculosis of both tubes, and general pelvic peritonitis.

Right Nephrectomy.—Thirty-six days after the hysteromyomectomy the right kidney was removed, the sufficiency of the excretion from the left kidney in the meantime having been fully established.

When the patient left the hospital, the old sinus at the hip had not yet entirely healed. The bladder mucosa, although still red and showing many tubercles and some areas of superficial necrosis, was considerably improved.

LOCATION OF THE URETERS DURING HYSTEROMYOMECTOMY.

The one question that haunts the operator most after difficult hysteromyomectomies is: Have I tied one or both ureters? With the gradual development in the operative technic the operation has become not only easier, but also more simple, and if the operator is in the least worried, he can answer his question at once before the abdomen is closed. We now make it a rule to examine carefully the ureters in any case in which there is the slightest possibility that they have been injured.

In some of our early cases the ureters were catheterized prior to operation. In the first place this is a doubtful procedure, since a foreign body in the ureter for a half to an hour or more may cause injury to it, and, in the second place, because in the very cases in which we most desire to outline the course of the ureters, they are so displaced and distorted by the myomata that catheterization of them is almost impossible.

One of us (Kelly) years ago noticed the *vermicular contraction of the ureters* on manipulation. We accordingly gently stroke the peritoneum at the pelvic brim, just where the ureter should be, with a pair of blunt forceps, and the ureter will usually be seen to begin its snake-like contraction. It is then dissected out down to the cervix, care being taken not to loosen it from its peritoneal covering, as its blood-supply might be interfered with. This point has been very clearly brought out by Sampson.*

The opposite ureter is then exposed in the same way.

One of us (Cullen) found it necessary to isolate the ureters in this manner in three cases in a single morning.

Occasionally, a fold of peritoneum may simulate a ureter, but it lacks the vermicular contraction and is not covered with the delicate tracery of vessels so characteristic of the ureter.

Sometimes the peritoneum of the pelvis over the ureter has become densely adherent to the myoma, as in Case 7049, or to an accompanying cyst, as in Case 7181. It is then liable to be much thickened, and detection of the ureter is much more difficult.

If the operator is unable to locate the ureter and feels relatively sure that it has been tied, as a last resort he can split the bladder and introduce a renal catheter through the ureteral orifice. This will not lengthen the operation over fifteen or twenty minutes, and may be a life-saving procedure. The ureters were located in this manner in Cases 3113 and 3590.

*J. Sampson, Johns Hopkins Hosp. Bull., 1904, xv, p. 39.

CHAPTER XXII.

THE RECTAL FINDINGS IN CASES OF UTERINE MYOMATA.

Adhesions between the uterus and rectum.
Upward displacement of the rectum.
Injury to the rectum during operation.
Resection of a portion of the sigmoid.
Perforation of the rectum found at autopsy.
Passage of an enema into the abdominal cavity.
Rectal prolapsus.
Perirectal abscess.
Carcinoma of the sigmoid.

ADHESIONS BETWEEN THE MYOMATOUS UTERUS AND THE RECTUM.

In a moderate number* of the cases slight or dense adhesions are found between the tumor and the rectum. These adhesions may occur when the appendages



FIG. 269.—DENSE ADHESIONS BETWEEN THE SIGMOID AND A MYOMATOUS UTERUS.

Gyn. No. 1499. The sigmoid is lifted up and densely adherent to the posterior surface of the uterus. The appendix is also firmly glued to the posterior surface of the tumor.

are normal, but are usually associated with general pelvic adhesions and are particularly prone to occur when a pelvic abscess exists. The rectal adhesions may be low down near the cervix or may be limited to the sigmoid flexure. Fig. 269 is a good example of a sigmoid densely adherent to the posterior surface of the myomatous uterus. Fig. 270 shows dense adhesions of the sigmoid and also of the small bowel to a tubo-ovarian abscess complicating a myomatous uterus. For adventitious vessels passing from the rectum to the myomatous uterus see p. 42.

UPWARD DISPLACEMENT OF THE RECTUM BY UTERINE MYOMATA.

If the myoma pushes out beneath the mesosigmoid, with the continued growth of the tumor the sigmoid will be carried up on the surface of the myoma. This was the case in Gyn. No. 1499 (Fig. 269). In Case 4828 the redundant portion of the sigmoid was carried upward beyond the umbilicus. In some cases it seems as if the pelvic structure were dragged upward *en masse* by the myomatous uterus.

*Rectal adhesions were noted in Gyn. Nos. 2207, 2638, 2706, 2800, 3107, 3357, 3552, 3661, 3844, 4097, 4334, 4370, 5014, 5325, 6607, 6863, 7266, 7511, 7597, 8115, 9118, 9694, 9769, 107494, 11647, 12520, 12779, 12841, C. H. I. 382.

For example, in Case 4097 both the bladder and rectum were carried high into the abdomen. In Case 1682 the bladder reached 15 cm. above the symphysis, while the sigmoid flexure had been carried out of the pelvis and lay over the surface of the tumor. In Case 3133 the condition was even more pronounced. Not only had the bladder and the rectum been carried upward, but one ureter was adherent to the posterior surface of the tumor.

INJURY TO THE RECTUM DURING OPERATION.

Injury to the rectum during operation has occurred in several cases. In all of them the myomatous uterus has been firmly adherent to the rectum, and during the liberation the bowel has been torn.

The rectal tears are naturally divisible into two groups:

1. Tears involving the muscular coats only.
2. Tears extending into the lumen of the rectum.

Tears Implicating the Circular Coats.—Tears of the longitudinal and in some instances also of the circular coats were noted in Cases 2706, 4097, 4370, 5325, 6607, 8115, and 12841. Some were very slight in extent, others 5 cm. long and 4 cm. broad.

Tears into the Rectal Lumen.—In five cases the lumen of the bowel was exposed during removal of the tumor—four times accidentally, and once when it was deemed necessary to remove a piece of the bowel.

In Case 9694, after bisection and removal of the densely adherent myomatous uterus, a hole 1.5 cm. in diameter was torn in the rectum during the liberation of adherent right appendages.

In Case 12520 the myomatous uterus was enveloped in dense pelvic adhesions and there was a pelvic abscess. In liberating the inflamed left appendages a tear, two inches long, was made in the rectum.

The injury to the bowel in Case 5014 was very extensive (Fig. 271). During

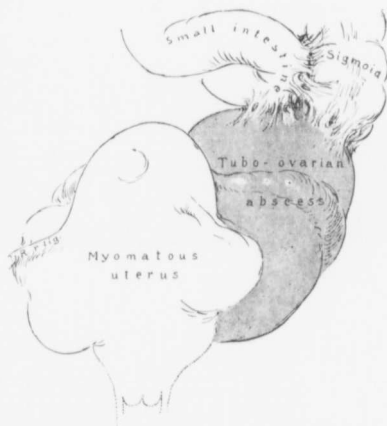

FIG. 270.—DENSE ADHESIONS OF THE SIGMOID FLEXURE AND OF A LOOP OF SMALL BOWEL TO A TUBO-OVARIAN ABSCESS.

GYN. NO. 4370. The uterus contains several myomatous nodules. On the left is a large tubo-ovarian abscess, to the upper portion of which the sigmoid and a loop of small bowel are adherent. The chief difficulty in these cases consists, however, in liberating the lower part of the rectum from the abscess wall.

removal of the universally adherent myomatous uterus the bowel was torn for two-thirds of its circumference. The opening was at once closed with fine silk sutures.

The operation in Case 12779 was exceedingly difficult as a result of the adhesions. On the left side was a tubo-ovarian abscess, the lining of which closely resembled bowel mucosa. During liberation of the right appendages the rectum was opened for $1\frac{1}{2}$ inches. It was impossible to free the rectum from the cervix, owing to the dense adhesions. A flap of the cervix, attached to which was a torn piece of the bowel, was dissected free and turned back on the bowel to close the rectal deficiency.

At operation in Case 11647 the pelvic growth was thought to be carcinomatous. Complete hysterectomy was performed and, as the rectum was densely adherent to the cervix and the tissue much indurated, an elliptic piece of the rectum was removed with the uterus, and the opening closed with a row of silk sutures first, and then with a row of catgut sutures.

Whenever feasible, it is well to get at the rectal adhesions from the under side. This may be accomplished by bisecting the uterus (Fig. 357, p. 610), or by first dissecting back the bladder and amputating through the cervix (Fig. 363, p. 616), before tying off the broad ligaments. In this way the partially obliterated Douglas' sac is at once exposed. When it is necessary to liberate the rectum and it is impossible to dissect it free, a thin shell of the tumor should be left attached to the

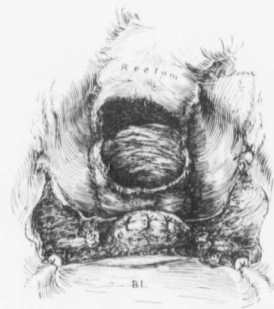

FIG. 271.—AN EXTENSIVE RECTAL TEAR.

Gyn. No. 5014. During the removal of a very adherent myomatous uterus the bowel was torn for two-thirds of its circumference. The opening in the rectum was sutured, and the cervix carefully covered over with peritoneum. The patient recovered satisfactorily.

rectum. This raw area is then turned in on itself and sutured, leaving a perfectly smooth surface. This procedure was successfully carried out in Case 6607.

Where only the outer coats of the bowel are torn, one or more continuous catgut sutures are all that are necessary to bring the raw surfaces together. But if the lumen of the bowel is entered, the opening should be closed with fine silk or Pagenstecher sutures, and then reinforced with a second continuous suture of catgut. A vaginal drain should then be introduced for safety. It should be very small, and so placed that it does not lie on the suture line, as it may lead to suppuration and the development of a fecal fistula.

Under no circumstances should rectal enemas be ordered where an incomplete or complete rectal tear exists.

In all of these cases the rectal wounds healed perfectly, and the patients made a good recovery.

RESECTION OF A PORTION OF THE SIGMOID AND REMOVAL OF A MYOMATOUS UTERUS.

The multinodular myomatous uterus (Fig. 272) was of moderate size. On the right side was an ovarian cyst; on the left, a tubo-ovarian abscess, adherent to

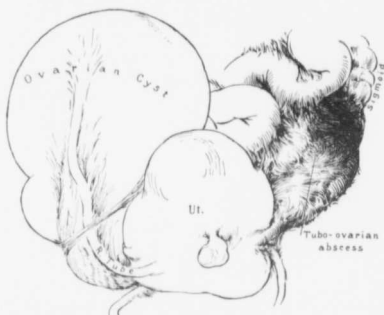


FIG. 272.—A MULTINODULAR MYOMATOUS UTERUS, COMPLICATED BY AN OVARIAN CYST ON THE RIGHT AND A DENSELY ADHERENT TUBO-OVARIAN ABSCESS ON THE LEFT.

Gyn. No. 8738. Path. No. 4935. The uterus contains several myomatous nodules; it measures 8 x 10 x 12 cm. The cyst on the right was 16 cm. in diameter, and had a twisted pedicle. It was multilocular and had papillary masses springing into its cavity.

On the left side is a tubo-ovarian abscess, densely adherent to the small bowel, and plastered down to the rectum. For the intimate relation between this inflammatory mass and the sigmoid see Fig. 273.

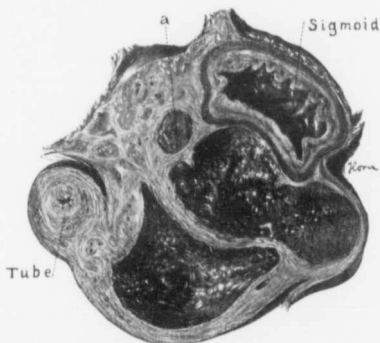


FIG. 273.—A TUBO-OVARIAN ABSCESS, DENSELY ADHERENT TO THE SIGMOID FLEXURE.

Gyn. No. 8738. Path. No. 4935. For the general relations of the abscess see Fig. 272. The abscess sac has been cut in two. To the left is a cross-section of the greatly thickened tube. The two large irregular cavities are loculi of the abscess and are lined with granulation tissue. *a* is a small abscess surrounded by dense new connective tissue. The bowel at this point is so intimately blended with the abscess-wall that it would be absolutely impossible to dissect it off.

the small bowel and sigmoid flexure. So dense were the adhesions of the sigmoid

(Fig. 273) that a resection of a portion was necessary. The recovery was naturally slow.

Gyn. No. 8738. Path. No. 4935-

A. H., single, aged thirty-seven, white. Admitted May 10; discharged August 6, 1901.

Three years ago the patient had an attack of abdominal pain, which was supposed to be due to appendicitis. Six months later she had a similar attack, accompanied by an inability to void. About this time a small tumor was noted in the left side.

Operation, May 11, 1901. Hysteromyomectomy; resection of a portion of the sigmoid flexure. The uterus was symmetrically enlarged. This, together with the ovarian cyst on the left side, was removed. In order to enucleate the tubo-ovarian mass on the left side it was necessary to resect about 12 cm. of the sigmoid flexure. A gauze drain was carried down through the inguinal incision to the point of resection. The patient was much shocked. After the operation the patient hicoughed a good deal and had much nausea and abdominal pain. It was impossible to move the bowels. On the sixth day an inguinal colostomy was done in order to relieve the obstruction. The patient improved rapidly. Several days later an attempt was made to close the fistulous opening under cocaine, but the stitches tore out. The patient made a slow recovery.

PERFORATION OF THE RECTUM FOUND AT AUTOPSY, NINE DAYS AFTER HYSTERECTOMY FOR A DENSELY ADHERENT MYOMATOUS UTERUS, ASSOCIATED WITH PYOSALPINK AND AN OVARIAN ABSCESS.

The accompanying history does not render it clear whether the rectal perforation was a result of the operation or merely a part of the ulcerative process found in other portions of the bowel. Had it been due to the operation, the acute manifestations would in all probability have developed earlier.

Gyn. No. 5302. Aut. No. 954.

E. H., single, aged forty-six, colored. Admitted May 29; died June 19, 1897.

The lower two-thirds of the abdomen was filled with a solid tumor, irregular in outline. Hysteromyomectomy was performed. The appendix was involved in an abscess. There were dense adhesions to the pelvic floor, rectum, colon, and anterior abdominal wall. The operation was a very difficult one.

After operation the urine showed many casts—an exacerbation of an old nephritis. Saline infusions were given twice daily. There were nausea and vomiting, the feces began to pass involuntarily, and the patient died in a comatose condition on the ninth day. Her highest postoperative temperature was 102° F. on the day of her death.

Aut. No. 954. On section of the abdomen perforation of the sigmoid flexure was found. There were a localized purulent peritonitis and an acute general

peritonitis, arteriosclerosis, chronic diffuse nephritis, chronic adhesive pleuritis, and ulceration of the large intestine.

THE PASSAGE OF AN ENEMA INTO THE ABDOMINAL CAVITY.

In Case 10749 $\frac{1}{2}$, described in detail on p. 675, the patient suddenly collapsed on the third day after a simple enema had been given. At autopsy on the following day it was found that there was a hole 3 cm. long in the rectum, and through this the enema had passed into the general cavity, at once setting up a peritonitis.

RECTAL PROLAPSUS.

This would naturally seem to be a frequent accompaniment of uterine myomata, but it was noted only twice in our series.

In Case 5987, in which the uterus had been converted into a nodular tumor, 11 x 12 x 17 cm., a small mass had protruded from the anus for a year.

In Case 5249 the patient had consulted her physician five years before operation, on account of prolapsus of the rectum, and was then told that she had a uterine tumor.

PERIRECTAL ABSCESES.

Pelvic abscesses are not infrequently associated with uterine myomata, and the rectum under such conditions is often implicated in the general process. The two following cases are, however, very unusual.

In Case 5697, after removal of a small, densely adherent myomatous uterus, which was associated with chronic salpingitis on both sides, and with a small pelvic abscess, another abscess was accidentally discovered behind the rectum, just as the abdomen was about to be closed. This sac was wiped out and drained through the vagina. Had this abscess not been discovered, recovery might have been greatly retarded.

In Case 6199 a small myomatous uterus was associated with pelvic inflammation. The infection had extended to the rectovaginal septum, which was fully 3 cm. in thickness.

In Case 8264, shortly after abdominal myomectomy, the patient underwent three successive operations for ischiorectal abscess. The rectal condition in this case must be considered merely as a coincidence.

CARCINOMA OF THE SIGMOID FLEXURE ASSOCIATED WITH UTERINE MYOMATA.

On p. 417, in the autopsy chapter, are described two cases of cancer of the lower bowel associated with uterine myomata. In the first the carcinoma was situated in the sigmoid flexure; in the second, within 1 cm. of the anal orifice. In neither case was operation feasible.

In the following case the patient entered with signs of obstruction. After a large myomatous uterus had been removed, a carcinoma of the sigmoid flexure

was discovered (Fig. 274). This was at once excised, and the patient enjoyed fair health for several weeks. On her return to the hospital wide-spread abdominal metastases were found.

Gyn. No. 12000. Path. No. 8447.

Acute intestinal obstruction; a large myomatous uterus wedged in the pelvis; unsuspected adenocarcinoma of the sigmoid flexure. Hysterectomy; resection of the diseased bowel; temporary recovery.*

E. S., colored, aged forty. Admitted March 26; discharged June 9, 1905. One of us (C.) saw this patient in consultation with Dr. Clement A. Penrose. On admission she was suffering from intestinal obstruction. This was thought to be caused by a myoma which had been known to exist for fifteen years. Twelve years before she had had a severe attack of abdominal pain. This was sharp and shooting in character, but there was no intestinal obstruction. For the past six weeks she had noticed sharp shooting pains in the abdomen, intermittent in character, and limited to the left side. The bowels had not moved for several days. There had been no blood noted in the stools prior to the obstruction.

The abdomen was at once opened. After removal of the myomatous uterus (Fig. 274) the rectum was found to contain what appeared to be a malignant growth. The rectal tumor was loosened as carefully as possible from the cervix. It lay entirely below the pelvic brim, was approximately 7 cm. in diameter, and about 8 cm. in length. The tumor was removed, and an end-to-end anastomosis done. In order to give the anastomosis complete rest, a left inguinal colostomy was done. The patient was very weak when returned to the ward, but in fairly good condition, considering the severity of the operation. She gradually improved, and was discharged on June 9th.

Path. No. 8447. The myomatous uterus has been amputated through the cervix. It is approximately 11 x 12 x 16 cm. (Fig. 274).

Our chief interest is centered in the growth of the sigmoid flexure. The piece of tissue is 9 cm. in length. The outer covering of the bowel looks fairly normal, except for some slight whitish elevations. Occupying the entire thickness of the bowel near the center is a hard, light-colored growth (Fig. 274, c). This is 4 cm. in length, and extends throughout the entire thickness of the bowel. The growth itself, with the indurated adipose tissue surrounding it, is fully 3 cm. in thickness.

Histologic examination shows that the tumor of the bowel is a typical adenocarcinoma.

Gyn. No. 12204. The patient was readmitted on June 24, 1905. Until a week previous she had been in good condition. The bowels, however, became constipated; there were frequent attacks of pain in the abdomen, and during the last

*This case is reported in detail in "A Series of Intestinal Anastomoses," Thomas S. Cullen, Canadian Jour. of Med. and Surg., July, 1906.

seven days there had been no movement. For the last two or three days the abdominal pain had increased in severity, but there had been no vomiting. The patient gradually grew weaker, and died July 3, 1905.

Aut. No. 2558. The autopsy revealed a recurrence of the carcinoma at the

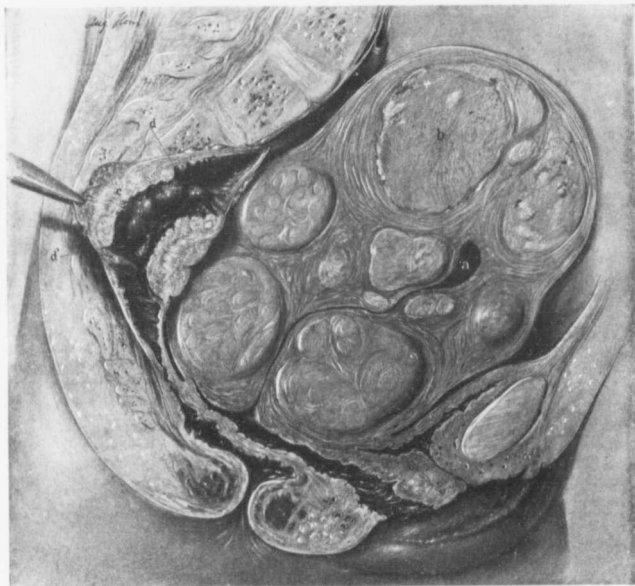


FIG. 274.—CARCINOMA OF THE SIGMOID FLEXURE ASSOCIATED WITH A MYOMATOUS UTERUS.

Gyn. No. 12000. Path. No. 8447. After sketching a longitudinal section of the pelvis, the artist drew the uterus and growth in the bowel from nature. The uterus measures 11 x 12 x 16 cm., and almost completely fills the pelvis, leaving little room for the bladder or rectum. It contains numerous interstitial and a few submucous myomata. The uterine cavity is slit-like, but at *a* is slightly dilated. The light patches, *b*, in the myoma are areas of calcification.

Occupying the sigmoid is the carcinomatous growth, *c*, which almost completely fills the lumen of the bowel. Its confines are indicated by *d* and *d'*. (After Thomas S. Cullen.)

point of anastomosis. There was also some narrowing of the bowel at this point. There were metastases in the peritoneum and a fibrinopurulent peritonitis, apparently arising in the upper right abdominal quadrant, at a point far removed from the site of the anastomosis.

CHAPTER XXIII.

ANALYSIS OF THE CASES OF UTERINE MYOMATA FOUND AT AUTOPSY
IN THE PATHOLOGICAL LABORATORY OF THE JOHNS HOPKINS
HOSPITAL FROM THE OPENING OF THE HOSPITAL, IN 1889, TO
JULY 1, 1906.

Through the kindness of Professor William H. Welch the autopsy records of the Johns Hopkins Hospital have been placed at our disposal. From the opening of the hospital, in 1889, to July 1, 1906, there have been 2740 autopsies. In 2729 cases complete data are available. The accompanying tabulation gives the relative number of males and females, and also the ratio of white and blacks:

Males, white.....	1102
Males, black.....	659
Females, white.....	537
Females, black.....	431

It will be seen that the number of males nearly doubles that of females, and that the ratio of black to white women is 1 to 1.25.

As myomata are rarely present in women under twenty years of age, we have only included autopsies upon women of twenty or over. Of these, there were in all:

On white females of twenty years of age or over.....	431
On black females of twenty years of age or over.....	311
Total.....	742

In 148 of these cases the uterus contained one or more myomata; in other words, in about 20 per cent. of the autopsies in women of twenty years of age or over the uterus was the seat of a myomatous growth. This is certainly a remarkable showing.

The following table gives the number of cases according to decades:

In patients between 20 and 30 years of age myomata were found in 14 cases.										
"	"	"	30	"	40	"	"	"	"	38
"	"	"	40	"	50	"	"	"	"	52
"	"	"	50	"	60	"	"	"	"	29
"	"	"	60	"	70	"	"	"	"	10
"	"	"	70	"	80	"	"	"	"	4
"	"	"	80	"	90	"	"	"	"	1 case.

Of the 148 patients, 43 were white and 105 black. In other words, 33.7 per cent. of all the black women twenty years of age or over coming to autopsy had uterine myomata, while only 10 per cent. of the white patients were affected in this way.

The myomata varied from 0.5 to 27 x 17 x 13 cm. in diameter, the largest being found at autopsy No. 1969. In some of the cases only one myoma was present. Usually the uterus contained several nodules, and in one case fifteen were noted.

Fig. 275 shows a small myomatous uterus removed at autopsy from a patient ninety years of age.

Site of the Tumors.—In 30.4 per cent. only subperitoneal nodules were found.

In 26.3 per cent. only interstitial nodules were noted.

In 15 per cent. subperitoneal and interstitial nodules were found.

In only a few were submucous nodules detected. Subperitoneal or interstitial myomata, when not large enough to occasion any pressure symptoms, in the majority of cases cause little trouble and consequently the patient rarely comes to the surgeon for treatment.

Adhesions.—In 48.6 per cent. old pelvic adhesions were found.

In 7.6 per cent. pelvic and abdominal adhesions were noted.

In all, 56.2 per cent. of the cases were complicated by adhesions of some character.

Degeneration.—In 12.2 per cent. portions of the myomata were necrotic.*

In 15.5 per cent. calcareous deposits were present.†

Of course, in these cases showing calcareous deposits areas of necrosis had preceded the deposition of the calcium salts, so that at one time or another in 25 per cent. of the cases necrosis was present in one or more of the myomata.

Cystic or hyaline changes were detected in 8 cases (about 5.5 per cent.)—Nos. 288, 54, 85, 188, 1113, 1206, 1969, 2080.

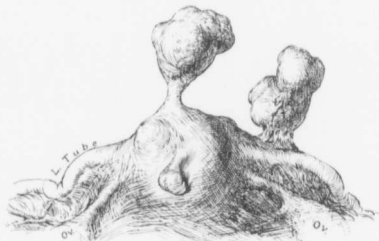

FIG. 275.—MYOMATA IN OLD AGE. (½ nat. size.)

M. S. Aut. No. 1823. Path. No. 5471. This uterus was removed from a patient ninety years of age, dead of an intercurrent affection. The organ is enlarged only slightly. Occupying the fundus are a few small interstitial nodules; projecting from the fundus are three small, irregular, nodular myomata, all of which appear to have undergone some atrophy.

CONDITION OF THE TUBES AND OVARIES NOTED IN MYOMA CASES AT AUTOPSY.

In 56.2 per cent. of all the myoma cases pelvic or abdominal adhesions were found. Naturally, then, we should expect to find numerous minor pathologic lesions in the tubes and ovaries.

* Aut. Nos. 69, 136, 188, 277, 322, 474, 532, 610, 653, 680, 689, 700, 722, 1085, 1754, 2080, 208F, 2202.

† Aut. Nos. 23, 69, 117, 519, 579, 682, 700, 722, 901, 908, 1310, 1337, 1363, 1593, 1666, 17C3, 1823, 1869, 1898, 2088, 2230, 2404, 2426.

Hydrosalpinx, unilateral.....	5 cases
Hydrosalpinx, bilateral.....	5 "
Hematosalpinx.....	1 case
Pyosalpinx.....	4 cases
Tuberculosis of the tube (Aut. No. 1898).....	1 case
Carcinoma of the Fallopian tube (Aut. No. 810), secondary to carcinoma of the uterus.....	1 "
Small cyst "in the broad ligament".....	6 cases
Multilocular cystadenoma of both ovaries.....	1 case
Dermoid cyst.....	2 cases
Ovarian abscess.....	4 "
Tubo-ovarian abscess.....	1 case
Primary carcinoma of the ovary (Aut. Nos. 474 and 1371).....	2 cases
Carcinoma of the ovary associated with carcinoma of the stomach*.....	2 "

The small cysts noted in the broad ligament are chiefly inflammatory in origin, being due to accumulations of peritoneal fluid.

From a study of this table it will be seen that in two of the cases there were primary malignant changes in the ovaries, and in one case tuberculosis of the Fallopian tube.

CHANGES IN THE URETER ASSOCIATED WITH MYOMATA.†

The following table shows that in these cases one or both ureters were dilated, giving rise to hydroureter:

AUT. NO.	SIZE OF UTERUS.	ADHERENT.	RIGHT OR LEFT HYDROURETER.	CAUSE.
288	Large, filling pelvis.	Yes.	Double.	Myoma.
451	3 myomata, 5 cm. in diameter.	—	Right. Was associated with diffuse nephritis and cardiac hypertrophy.	Myoma.
653	Pelvis filled.	Yes.	Double.	Myoma.
908	9 x 7 cm.	—	Double.	Myoma (jammed).
994	Rises 13 cm. above pelvic brim.	—	Right.	Myoma.

The situation and the size of the tumor are to a great extent responsible for pressure upon the ureter sufficient to cause dilatation. A myoma just large enough to fill the pelvis and snugly tied down by adhesions can very readily produce sufficient pressure to cause hydroureter, while a very large tumor may be so situated as to exert little or no effect upon the ureter.

In the removal of an 89-pound tumor in the week during which we were gathering this data we did not find the slightest evidence of any interference with

*The intimate relationship between primary carcinoma of the stomach and secondary growths in the ovaries was made clear by Professor Welch several years ago (Pepper's System of Med., vol. ii, p. 533).

†In several other cases ureteral and renal changes were found, but as they were evidently caused by other pathologic conditions, these cases have been omitted.

the ureter. About the only way in which the myoma can bring about the necessary pressure on the ureter is to get it firmly wedged against the bony wall of the pelvis. As a rule, the larger the myoma becomes, the more room it requires, and hence its ascent into the general cavity.

In Aut. No. 451 the combined myomatous masses with the associated adhesions seem to have been the causative factor.

In Aut. Nos. 653, 908, and 994 the evidence is in favor of the myomata as the distinct cause of the hydroureter.

There was one more case in which hydroureter was found at autopsy (No. 188). Here the ureter had been accidentally tied during operation, and had remained so until several days later, when it was discovered at autopsy. This case is described in full on p. 382.

In one case (Aut. No. 69) there was a double pyoureter associated with an ascending infection and implication of both kidneys. The large myomatous tumor was sufficient to cause dilatation of the ureters, but the accompanying infection could not be directly attributed to the uterine tumor.

CHANGES IN THE KIDNEY ASSOCIATED WITH UTERINE MYOMATA.

Aut. No. 288, double hydronephrosis.

Aut. No. 653, double hydronephrosis.

Aut. No. 994, dilatation of the right pelvis.

Aut. No. 1745, dilatation of the right pelvis.

Aut. No. 69, double pyelonephrosis.

Aut. No. 1112, miliary abscesses of the kidney (Staphylococcus aureus, sloughing submucous myoma).

In Aut. Nos. 288 and 994 the dilatation of the ureter seemed to have been caused by pressure exerted by the myomata, which was likewise probably responsible for the dilatation of the renal pelvis.

In Aut. No. 1745 the coexistence of the myoma with dilatation of the right kidney was a mere coincidence.

The dilatation of the kidney in Aut. No. 69 was primarily due to pressure exerted by the tumor, but the subsequent infection cannot be attributed to the presence of the myomatous uterus.

The general picture in Aut. No. 1112 strongly suggests that the sloughing submucous myoma was responsible for the acute endocarditis, with the secondary manifestations, as seen in the miliary abscesses in the kidney.

Taken as a whole, the alterations in the ureters and kidneys caused by myomata are chiefly mechanical, and may to a great extent be relieved by operation. Only in those cases in which there is a sloughing submucous myoma or necrotic and sloughing interstitial or subperitoneal myomata need purulent changes be looked for in the ureter or the kidney.

AUTOPSIES SHOWING CARCINOMA AND MYOMATA IN THE SAME UTERUS.

In 8 cases this condition was found at autopsy. In 2 cases the carcinoma was situated in the cervix; in 6 cases, in the body of the uterus.

Carcinoma of the Cervix and Uterine Myomata.*—In Aut. No. 689 (Case 3490) the cervix had been invaded with cancer, which had extended not only to the lateral structures, but also to the vagina. Situated in the body of the uterus was a sloughing submucous myoma, 6.5 x 4.5 x 2 cm.

The uterus in Aut. No. 926 (Case 5092) presented a striking picture. The cervix had been entirely eaten away by the carcinomatous growth, and the body of the uterus was markedly encroached upon. Scattered throughout the uterus were subperitoneal, interstitial, and submucous nodules, and the carcinoma had riddled the contiguous portion of the myomata (Fig. 278, p. 403). It is little wonder that the large carcinomatous surface gave rise to a fatal hemorrhage.

The cases operated upon in which carcinoma of the cervix was associated with myomata will be found on p. 262.

Gyn. No. 3490. Aut. No. 689.

Extensive carcinoma of the cervix; sloughing submucous myoma.

Aut. No. 689. K. R., white, aged forty-four. Admitted May 7; died July 18, 1895. Anatomic diagnosis: general infection with the gas bacillus; carcinoma of the cervix extending to the vagina and lateral structures; metastases in the liver, both layers of peritoneum, and inguinal and retroperitoneal lymph-glands; arteriosclerosis; chronic diffuse nephritis; chronic perisplenitis; chronic adhesive and acute peritonitis; sloughing myomata in the uterine cavity.

On opening the abdomen 900 c.c. of greenish, foul-smelling fluid were found free in the peritoneal cavity. The cervix had almost entirely disappeared, its site in the upper part of the vaginal wall being infiltrated by the carcinoma, which laterally extended to the pelvic wall. The growth was sloughing and necrotic. In the uterine cavity was a hard nodule, 6.5 x 4.5 x 2 cm., which showed a necrotic surface. This was a sloughing submucous myoma. Both Fallopian tubes were thickened and adherent to the posterior surface of the uterus.

Histologic examination showed that the growth and the metastases were composed of carcinomatous tissue. The records, however, do not say whether it was a squamous-celled growth or an adenocarcinoma.

Gyn. No. 5092. Aut. No. 926. Path. No. 1631.

Umbilical hernia; squamous-celled carcinoma of the cervix (Fig. 276) extending to the vagina, body

*In Aut. No. 810 (Case 4374) the cervix was extensively invaded by the carcinomatous tissue, which was also wide-spread in the lateral structures. Two small interstitial myomata were present in the body of the uterus. These nodules were too small, however, to justify the inclusion of this case in the group.

of the uterus, bladder (Fig. 277), rectum, broad ligament, tubes and ovaries, and forming metastases in the pelvic, inguinal, retroperitoneal, mesenteric, and bronchial glands; also in the lungs, pleuræ, and

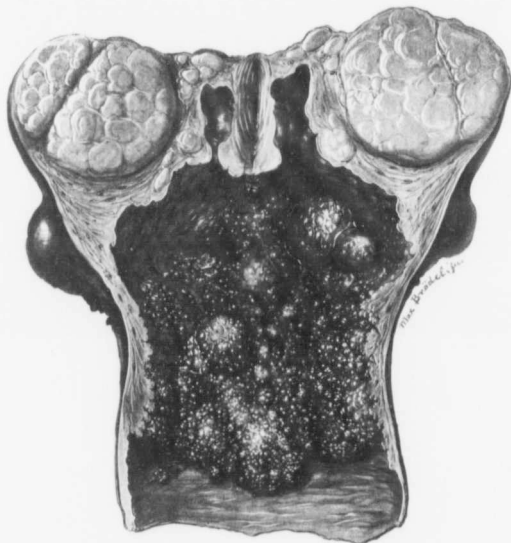


FIG. 276.—SQUAMOUS-CELLED CARCINOMA OF THE CERVIX ASSOCIATED WITH MULTIPLE UTERINE MYOMATA.
(J. H. S. S. S.)

Path. No. 1631. The uterus is much enlarged. Projecting from its surface are numerous large and small bosses, which on section are seen to consist of subperitoneal, interstitial, and submucous myomata. Note how prominent the myomatous nodules are on section, owing to the recession of the uterine muscle. The lower part of the vagina presents the normal appearance, but occupying the upper part of the vagina, the site of the cervix, and also the greater part of the uterus is a ragged and friable looking growth, composed of smooth, dome-like elevations, varying from a pin's head to 2 cm. in diameter. The larger ones are slightly lobulated. Over the smooth inner surface the tissue is almost entirely necrotic. The uterine walls have been invaded nearly to the peritoneal surface, and present a very ragged outline. The small nodules in the muscle of the fundus are myomata. The growth on microscopic examination is found to have penetrated the muscle between them, and has invaded a small myomatous nodule, as seen in Fig. 278. (After H. A. Kelly.)

the serosa of the intestines. Interstitial and subperitoneal uterine myomata; double hydroureter; anemia of all the organs; focal fatty degeneration of the liver; interstitial nephritis; sudden death following uterine hemorrhages.

L. S., aged fifty-four, colored. Admitted March 11, 1897. Complaint, frequent uterine hemorrhages and an offensive discharge.

The patient has been married twenty years, and has had two children and one miscarriage. Her menses commenced at thirteen, were regular and profuse, lasting three or four days, and very painful. Seven years ago the periods diminished in frequency, occurring once in every three or four months, though there was frequently a bloody discharge. In August, 1895, the bloody discharge reappeared and became constant, but not excessive; it continued until January, 1896. Since then she has had copious hemorrhages, and after one in January, 1896, she fainted. The last severe hemorrhage prior to her admission occurred in September, 1896. Since then at times she has had a bloody discharge, slight in amount, and accompanied by no pain, but very offensive and irritating.

On admission the discharge is yellowish white and profuse. The family history is negative.

The only noteworthy fact in her previous history was that in the summer of 1896 she had no stool for two weeks.

Present sickness: The patient did not know that she had an abdominal tumor until so informed by her physician; she thinks that the growth has diminished in size. There has been little pain in the abdomen, except for the accumulation of flatus. Enlargement of the inguinal glands was first noticed in June, 1896. These, she says, have not increased in size, but during the last four weeks have been very painful. She has lost much in weight, although she has a very good appetite. The bowels are costive, and defecation is accompanied by much pain and occasionally by bleeding from hemorrhoids. The urine is sometimes scalding and occasionally blood-tinged.

Abdominal Examination.—The abdomen is dome-shaped, the most prominent point being the umbilicus. The patient has an umbilical hernia, the pouch being 3 cm. in diameter, and projecting 3.5 cm. from the surface. The hernial ring easily admits the end of the index-finger.

The abdominal tenderness is most marked below and to the left of the umbilicus. Over an area about 5 cm. in diameter in this vicinity the tissue is very edematous, and pits readily on pressure. Owing to the tenderness it is difficult to outline the abdominal tumor, which, however, is very smooth and does not extend above the umbilicus in the median line. In both inguinal regions the glands are as large as walnuts and are movable. Those on the right side are tender.

The right leg is much swollen and pits on pressure, especially below the knee. The left leg also is swollen. The glands of the neck and the epitrochlears are palpable.

Vaginal Examination.—The outlet is considerably relaxed, and the upper part of the vagina is occupied by a necrotic, offensive tissue which rapidly breaks down under the examining finger.

Further examination is impossible on account of the extreme tenderness. On the morning of March 27, 1906, the patient had a profuse uterine hemor-

rhage, and, as nearly as could be estimated, lost about one pint of blood. So far as the pulse and respiration were concerned, the loss of blood caused little change, but there was a slight tendency to drowsiness. At 3.30 p. m. she had a second hemorrhage, more profuse than the first, was restless, complained of severe pain in the back, and had a pulse of 136. The mucous membranes were quite pale. The respirations were not increased. Morphine was given with good effect. At 11.15 p. m. she had a third hemorrhage, much more severe than the two

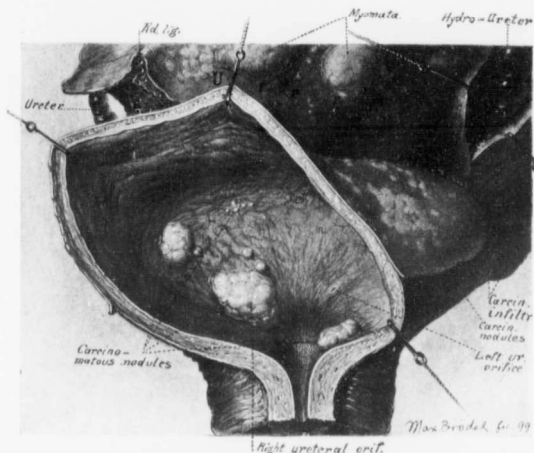


FIG. 277.—CARCINOMA OF THE BLADDER SECONDARY TO SQUAMOUS-CELLED CARCINOMA OF THE CERVIX.

Path. No. 1631. Scattered over the peritoneal surface of the bladder are many small white, flat, isolated carcinomatous nodules. Some also have united to form conglomerate masses. The bladder-walls are of the usual thickness. Just within the inner urethral orifice is an elongated nodule, about 1 cm. in length, which rises abruptly from the surface, is sharply defined, and presents slight lobulation. The left ureteral orifice is normal, but the right is situated in the center of a lobulated carcinomatous nodule, nearly 2 cm. in length. Behind this are several other carcinomatous outgrowths, some of which are not more than 1 mm. in diameter. The bladder mucosa, except where it is involved in carcinomatous nodules, is normal. Above the bladder is the enlarged myomatous uterus, with two myomata on its surface and numerous small, flat carcinomatous nodules covering the peritoneum. To the right is the dilated right ureter. The left ureter is also distended, being constricted below by carcinomatous infiltration. (After Thomas S. Cullen.)

preceding. The pulse was 140, and at 1 A. M. the patient was unconscious and gasping for breath. She died at 2.40 A. M.

Aut. No. 926. The body is that of a colored woman, small in stature, and somewhat emaciated. In both inguinal regions are prominent nodular swellings, the largest about the size of a hen's egg; all are freely movable, and the largest gives a slight fluctuation. Extending upward to the inguinal rings are indurated masses. Just below the umbilicus is a firm, movable mass, about the size of a child's head.

The right lung is bound by fibrous adhesions to the chest-wall at about the middle third, and again posteriorly near the base. The parietal pleura on the right side shows a grayish-white nodule, 6 mm. in diameter, and there are small groups of similar nodules on the surface of the diaphragm. Where the lung is bound down at its base posteriorly there is marked induration, due to superficial metastatic tumor deposits. These form a conglomerate mass of small round nodules, which are beginning to undergo softening in their centers. On section, they are of a uniformly pale yellow color. The surface is dry, but the central portions are soft, and can be readily squeezed out. There are also five similar nodules scattered over the surface of the lung.

The left lung has several nodules, each about 1 cm. in diameter, scattered over its surface.

The anterior mediastinal glands are not enlarged, but the bronchial glands are much increased in size, owing to metastatic deposits.

Spleen negative.

The liver contains no metastases.

The kidneys are of moderate size; the capsules strip off readily; scattered over the surface of each kidney are minute clear cysts.

Both ureters are dilated, especially the left, which along its lower third is nearly 1 cm. in diameter; at the junction of the lower and middle third is a kink, above which the dilatation is not so marked.

On opening the abdomen a portion of the somewhat fatty omentum was found in the small hernial orifice at the umbilicus; it was readily withdrawn by gentle traction. The orifice was 1.5 cm. in diameter.

Both layers of peritoneum are smooth in the upper abdomen, save for nodules about the size of peas, which here and there stud the surface of the intestines.

The prominent and enlarged fundus is slightly adherent to the parietal peritoneum in the median line below the umbilicus. The peritoneum in the lower part of the abdomen is studded with single or grouped whitish nodules, some of which are as large as beans; the tissue on both sides of the pelvic brim is much thickened, and has nodules over its entire surface.

The iliac glands are enlarged, one on the left side reaching about 4 cm. in diameter, and in its center containing a clear, odorless, straw-colored fluid looking much like urine. The smaller glands are softened in their central portions. The largest inguinal gland on the left side contains a fluid material resembling creamy-white pus. The glands at the bifurcation of the aorta are 4 cm. in diameter and necrotic. The mesenteric glands are enlarged and necrotic, as are also the retroperitoneal glands. The stomach and the large intestines have small white nodules scattered over their peritoneal surfaces.

Frozen sections from the small nodule in the posterior mediastinum show it to consist of dense fibrous tissue infiltrated with broad, irregular plugs of epithelial cells. These plugs show a tendency to break down in their central portions.

The liver shows considerable fatty degeneration, especially about the periphery of the nodules.

Examination of the Pelvic Organs.—Path. No. 1631. The uterus is converted into a large, nodulated tumor mass, approximately 21 x 17 x 15 cm. Projecting from the fundus anteriorly is a large rounded boss, 8 cm. in diameter. Both the anterior and posterior surfaces also present similar but less prominent elevations. On pressure, these nodules are firm and resistant. Studding the surface of the uterus are small flattened tumors or confluent masses of whitish, soft material. Covering the large nodules are tags of adhesions. On cutting open the uterus a large sloughing cavity is found (Fig. 276); this is 14 cm. in length, 8 cm. in its greatest diameter, and includes the upper part of the vagina, the broken-down cervical canal, and the greatly enlarged uterine cavity. The cervix is represented by a deep excavation, whose walls consist of a greenish, necrotic material, but in a few places, where the degenerative process is not so advanced, a papillary arrangement of the tissue can be easily recognized. The new-growth, which has evidently originated in the cervix, has extended to the vaginal vault, and has involved to a moderate degree the rectum and bladder. Projecting into the uterine cavity are several irregular, dome-shaped nodules, varying from 1 to 5 cm. in diameter. The entire cavity is lined with necrotic tissue, but here and there, as in the cervix, fine papillary outgrowths are occasionally visible.

The broad ligaments, mesosalpinx, tubes, and ovaries are studded with isolated or confluent masses, which are whitish in color and soft; they correspond with those covering the surface of the uterus. The ovaries are nearly twice the natural size. The bladder mucosa is everywhere smooth, but in the region of the trigonum is a whitish elevation, 2 cm. in diameter, to the left of which is a second but smaller one. Both of these are tumor growths (Fig. 277).

Histologic Examination.—Sections from the original tumor and from

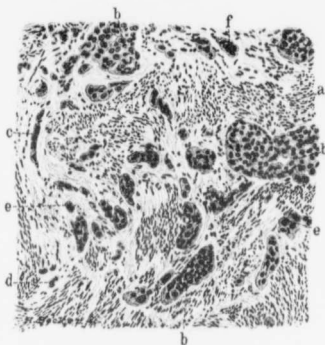


FIG. 278.—INVASION OF A MYOMA BY A SQUAMOUS-CELLED CARCINOMA OF THE CERVIX. ($\times 90$ diam.)

Gyn. Path. No. 1631. The section is composed of typical myomatous tissue and bunches of muscle-fibers cut longitudinally and transversely, and separated from one another by connective tissue which is poor in nuclei. At a the muscle-fibers are cut obliquely. At b, b, and b typical nests are seen, composed of cells that, as a rule, are uniform in size and contain vesicular nuclei. At c is a row of cancer-cells lying isolated in the stroma between muscle-bundles. A cross-section of such a row gives the picture seen at d and e, where single cancer-cells are visible. The growth also forms giant-cells, as seen at f, where there is a large irregular plaque of protoplasm containing a lobulated, deeply staining mass of chromatin. The extension to the myoma has been by continuity. (After Thomas S. Cullen.)

various points show typical squamous-celled carcinoma. They also show quantities of very large cells and plaques of irregular, deeply staining chromatin lying loose in the tissue or surrounded by large masses of protoplasm.

Definite nests are to be made out in the tubes and ovaries.

Sections from the myomata show that the carcinomatous process has extended by continuity into them, and that various portions of the myoma are being replaced by nests of epithelial cells (Fig. 278).

The complete histologic findings in this case are given in "Cancer of the Uterus," p. 139.

UTERINE MYOMATA ASSOCIATED WITH CARCINOMA OF THE BODY OF THE UTERUS DETECTED AT AUTOPSY.

All these patients entered the hospital too late for any extensive operative procedure; in fact, some of them died shortly after admission.

In Aut. No. 1605 the anterior uterine wall contained a myoma, 6 x 4 x 4 cm., while the body of the uterus was the seat of a far-advanced carcinomatous process that had been widely disseminated through the lymph-channels. In this case the myoma played an important rôle in the differential diagnosis, as judged by the bimanual examination.

The uterine enlargement in Aut. No. 117 was due chiefly to the presence of the myomata,—a calcified nodule, 3.5 cm. in diameter, and on the left side a myoma 19 x 15 cm.,—the carcinoma being relatively small. It is just in this class of cases that the malignant growths escape detection.

In Aut. No. 505 the uterus contained several myomata, the largest the size of a hen's egg. In this case, as a result of the exploratory laparotomy, metastatic nodules were found in the omentum and the peritoneum of the abdominal wall. The growth in the uterus, as the metastases would indicate, was far advanced.

The clinical picture in Aut. No. 1407 was confusing. There were not only several myomata and a carcinoma of the body of the uterus, but also a sloughing submucous myoma and a pyometra. Clinically, the sloughing myoma, the carcinoma, and the pyometra each might give the same symptoms, and only on an examination of the curettings could a positive diagnosis be established.

Aut. No. 1220 was given in detail in Cullen's "Cancer of the Uterus," p. 466. When I saw the patient in consultation, I diagnosed uterine myomata and advised hysterectomy. When the patient entered the hospital a few days later it was found that the inguinal glands had suddenly enlarged, and as the possibility of malignancy was thought of, I advised the removal of an inguinal gland for examination, not wishing to subject the patient to an abdominal operation if the growth should prove to be malignant. As will be noted from the history, Dr. Stokes found the inguinal gland the seat of cysts containing papillomatous masses identical with those found developing in the ovary. The patient rapidly lost weight and soon died.

Not until autopsy did we suspect carcinoma of the body of the uterus,

although it was far advanced and had caused wide-spread metastases. This is another example of the manifold pathologic processes that may be present in the pelvic organs of the same women.

Undoubtedly, the most instructive in our series is Aut. No. 277. In the early days of our myomectomy operations we did not hesitate to remove myomata, even though the uterus might be bound down by adhesions. In this case a myoma the size of an orange was removed from the anterior wall, but a nodule, 5 cm. in diameter, in the posterior wall could not be enucleated on account of adhesions. The patient died on the sixth day of peritonitis. The source of infection in all probability was the adenocarcinoma in the body of the uterus, which was unsuspected and which was not detected until the autopsy.

The uterus also contained a small submucous myoma. This case emphasizes the extreme care that must be exercised to determine the probable condition of the uterine mucosa, and also that of the tubes when myomectomy is contemplated. It also demonstrated the fact that a submucous myoma, 1.5 cm. in diameter, cannot always be palpated, even when the uterus is carefully examined by the operator after the abdomen has been opened.

REPORT OF CASES OF UTERINE MYOMATA COMPLICATED BY CARCINOMA OF THE BODY OF THE UTERUS AS FOUND AT AUTOPSY.

Gyn. No. 2634. Aut. No. 505. Path. Nos. 204 and 222.

Adenocarcinoma of the body of the uterus, with extension of the growth to the uterine myomata (Fig. 279); secondary involvement of the peritoneum, the inguinal, pericardial, bronchial, and cervical lymph-glands; carcinoma of the omentum; chronic endocarditis of the mitral, aortic, and tricuspid valves, and acute endocarditis of the mitral valves. Giant-cells in the carcinomatous glands.

E. S., aged fifty; colored. Admitted March 6, 1894. Complaint, abdominal enlargement, with soreness in the region of the umbilicus.

The patient had one miscarriage ten years ago, but has had no children. Her family history is not important, and with the exception of an attack of rheumatism a year ago she has always been well. The menstrual history is normal; the last period commenced February 22.

In the latter part of December, 1893, she began to complain of some abdominal pain, and on putting her hand on her abdomen discovered a lump about the size of the end of the finger just above the umbilicus. This nodule, which was at first hard and non-sensitive, has gradually become larger, and is now quite tender. The patient on admission is fairly well nourished, and apart from the abdominal enlargement, feels well.

Operation, March 10, 1894. Exploratory celiotomy. On opening the abdo-

men the peritoneum was found covered with numerous small nodules; similar tumors were also attached to the intestines, tubes, ovaries, and to the posterior surface of the uterus. The omentum was rolled up, forming a firm, nodular mass just beneath the costal margin. The peritoneal cavity contained about 2000 c.c. of turbid fluid. For several days after the operation the patient did well, but died on March 23.

Path. No. 204. A large amount of dark-yellow, muddy-looking fluid from the abdominal cavity, and two small, papillary-like masses from the omentum, each measuring 1 x 1 cm., were sent for examination. A note was made that similar masses were attached to the abdominal wall, intestines, pelvic organs, and mesentery, and, in fact, to the peritoneum everywhere.

On microscopic examination these small nodules are found embedded in adipose tissue. They consist of glands lined with one layer of low cylindrical epithelium.

In many of the cells nuclear figures are visible, and the gland epithelium has proliferated so as to completely fill the cavity. The stroma between the glands is moderate in amount and poor in cellular elements. The picture is that of an adenocarcinoma.

Aut. No. 505. Path. No. 222. An abstract from the protocol is as follows: The abdomen is somewhat distended, and in the peritoneal cavity is a considerable accumulation of yellowish serum. Extending completely across the abdominal cavity, in the region of the umbilicus, is a large tumor mass which covers the anterior surface of the transverse colon. This tumor is lobulated, light in color, and opaque. It corresponds to the greater part of the omentum. The right edge of the omentum is thicker than the left; the gastrocolic portion is relatively free from tumor involvement. In the peritoneum, at the hilum of the spleen, are several small white nodules; the lymphatics around the portal vein also contain small nodules. All these appear to be metastatic. Covering the peritoneum and the large intestine are numerous metastases, varying from a millet seed to a pea in size. They cover the peritoneum everywhere, and are especially abundant in the pelvis. The lymph-glands beneath the pericardium are enlarged and contain tumor metastases. The vagina and cervix are apparently normal. The uterus contains several myomata, the largest of which is submucous and pedunculated, being the size of a hen's egg.

The mucosa covering one-half of the surface of this nodule is congested and hemorrhagic; it presents a mottled appearance and suggests carcinoma. The second myoma is subperitoneal, and also appears to have been invaded by the tumor occupying the uterus. The inner surface of the uterus is grayish in the upper portion, and in places presents a yellowish mottling. The mucosa appears to extend for some depth into the muscle. The ovaries do not show any involvement.

Histologic Examination.—Sections from the uterus show that the muscular coat has been invaded by bunches of glands which are small, circular, and have

a lining of cylindric epithelium. In some of the cells two or more nuclei appear. A few of the glands contain giant-cells. At many points the gland epithelium has proliferated so that, instead of a bunch of glands, there is merely a large mass of cells having no definite arrangement. The centers of such masses often show nuclear fragmentation, but no inflammatory reaction. The myoma, which is involved in the new-growth, to a great extent has undergone hyaline changes. The principal part consists of hyaline tissue, with here and there

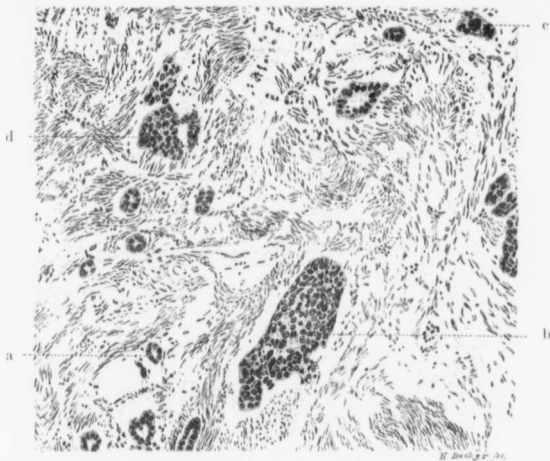


FIG. 279.—ADENOCARCINOMA IN A MYOMA, SECONDARY TO ADENOCARCINOMA OF THE BODY OF THE UTERUS.
($\times 125$ -diam.)

Path. No. 222. Aut. No. 505. The section consists of typical myomatous tissue. The majority of the muscle-fibers have been cut longitudinally, and wind in and out in all directions, not showing the regular arrangement so characteristic of normal uterine muscle. Moreover, there is an excess of connective tissue. Scattered abundantly throughout the myoma are groups of carcinoma cells. In the majority of places they appear as glands lined with one layer of cuboidal epithelium (a), but in a few places the glands have become filled, as at b, or the cells form large solid masses as seen at c. d is an irregular mass of cells showing a tendency to branch. On the whole, the nuclei of the epithelial cells are fairly uniform in size, but at c are seen a few large nuclei. The growth has extended by continuity. (After Thomas S. Cullen.)

tufts of non-striped muscle-fibers. Other portions of the myoma contain glands arranged singly or in bunches. Some show a single lumen, while others are completely filled with cells (Fig. 279). This growth is merely a continuation of that in the uterine muscle. Portions of the myoma have undergone coagulation necrosis. Just beneath the capsule of the liver, and attached to the surface of the kidneys, are small tumor masses. The glands of the neck show marked carcinomatous involvement, the typical glandular type being here well preserved.

The complete histologic description of this case is given in "Cancer of the Uterus," p. 434.

Gyn. No. 6439. Aut. No. 1220. Path. No. 2808.

Subperitoneal and interstitial uterine myomata (Figs. 280 and 281); adenocarcinoma of the body of the uterus, with secondary growths in the peritoneum, omentum, mesentery, liver, pancreas, left adrenal body, pleuræ, and lungs; papillocystomata of both ovaries, with extension by continuity to the corresponding inguinal glands; hydrosalpinx in the inner part of the left tube, due to a kink, the fimbriated extremity being patent.

M. H., aged fifty, colored. Admitted October 14, 1898. Complaint, an abdominal tumor accompanied by general weakness.

The patient has been married twenty-seven years, has had no children and no miscarriages. Menstruation commenced at twelve years, and was usually regular, lasting from three to seven days, but always excessive. At forty-one the flow ceased. One year ago a hemorrhagic discharge commenced, and has been practically continuous. For many years there has been an irritating leukorrheal discharge. The family history and previous history are unimportant.

About ten years ago the patient noticed a lump, about the size of an egg, in the left lower abdomen. This was not painful and caused no inconvenience. In August, 1897, the same nodule, although not enlarged, became quite tender, and the patient noticed that the abdomen at times was somewhat distended. As above noticed, the uterine hemorrhage began at this time. The abdominal pain has been more or less constant of late, sometimes dull and aching in character, at other times sharp and cramp-like. There has been considerable swelling of the lower extremities and also shortness of breath. At present she is apparently a strong, well-nourished woman; her temperature is 100.3° F., the pulse is 116. The bowels are constipated, and defecation and micturition are painful. The lungs and heart are apparently normal.

October 16th. The abdomen is much enlarged, and just above the umbilicus measures 115 cm. in circumference. The most prominent point lies midway between the umbilicus and the ensiform cartilage. The abdominal wall just above the pubes is much thickened and pendulous. The distance from the umbilicus to the pubes is 18 cm.; from the umbilicus to the ensiform cartilage, 27 cm.; from the right anterior superior spine to the umbilicus, 32 cm.; from the left anterior superior spine to the umbilicus, 32 cm.

Vaginal Examination.—The labia are large and flabby. The vaginal outlet admits two fingers, and it is just possible to touch the tip of the cervix, which lies far back and is apparently continuous with the tumor filling the abdomen. Occupying the left groin is an immovable mass, 6 x 3 cm. This has a somewhat elastic feel, and suggests a metastasis.

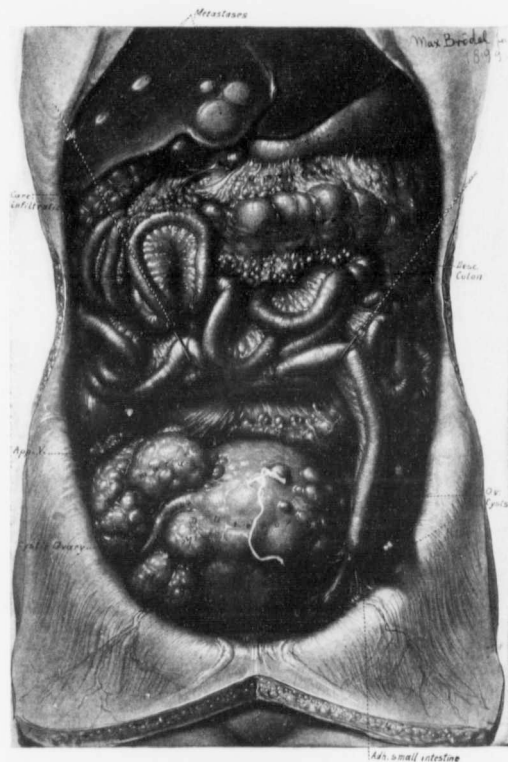


FIG. 280.—A LARGE MYOMATOUS UTERUS CHOKING THE PELVIS; SMALL OVARIAN CYSTS ON BOTH SIDES; THICKENING AND RETRACTION OF THE OMENTUM. METASTASES IN THE LIVER SECONDARY TO AN ADENOCARCINOMA IN THE BODY OF THE UTERUS.

Path. No. 2808. Aut. No. 1220. The figure shows the appearance of the abdominal cavity as seen at autopsy. Filling the pelvis, and projecting into the general cavity, is a large, irregular myomatous uterus (Fig. 281). Springing from the surface of the organ are large and small subperitoneal myomata. The right tube is seen passing outward in a depression between several of the largest myomata. On the right side, the edge of a small ovarian cyst is seen. On the left are two cysts springing from the left ovary. The lower one has very thin walls and is translucent. On the left a loop of small intestine has dropped down, and become firmly adherent to the growth in the inguinal region. Studding the mesentery of the small intestine are minute whitish nodules, which are secondary growths from the adenocarcinoma in the body of the uterus. The tip of the vermiform appendix is also embedded in carcinomatous nodules. As a result of cancerous infiltration the omentum is drawn up and forms a dense mass between the stomach and transverse colon, and just below the gall-bladder the adipose tissue is also greatly involved. Studding the right lobe of the liver are five carcinomatous nodules, one of which, even in the reduced drawing, is nearly 1 cm. in diameter. All are sharply defined, whitish in color, and are slightly umbilicated. There were also minute nodules, both in the substance and on the surface of the organ. The hepatic nodules were secondary to the carcinoma of the uterus. (After Thomas S. Cullen.)

Operation, October 17, 1898. Partial excision of the glands in the left inguinal region. Before opening the abdomen Dr. Ernest Stokes thought it advisable to explore the mass in the left inguinal region. As soon as an incision had been made through the skin over the most prominent portion of the tumor, a thin watery fluid escaped. Small cysts, lined with a pale, glistening membrane, were found in the deeper portions. Many of these contained papillomatous masses. In the face of such findings, associated with an abdominal tumor, it was deemed advisable to abandon any further operation. A small drain having been placed in the lower angle of the wound, the latter was closed. The patient recovered satisfactorily from the effects of the slight operation, so that on October 29th she sat up in a wheel-chair. The lower extremities, however, gradually became edematous; she grew weaker, and died on December 17, 1898.

Aut. No. 1220. The body is 163 cm. long; rigor mortis is not marked. There is an extreme degree of edema of the lower extremities, and of the trunk as far as the shoulders. The abdomen is markedly distended, and fluctuation can be elicited. Filling the lower part of the abdomen is a large tumor mass, while an oval, deeply seated tumor is found in the left inguinal region (Fig. 280). The body presents an anemic appearance; the muscles are very pale, but an abundance of adipose tissue is present. The peritoneal cavity contains about 3000 c.c. of a fairly translucent, yellow fluid. The parietal peritoneum has lost its glistening appearance, and over a large area is covered with rough, irregular, translucent deposits. This condition is especially marked over the diaphragm and over the right side. The bowels are very much contracted throughout their entire extent, and the small intestines average from 1.5 to 2 cm. in diameter. Studding the mesentery of the small intestines are many small white tumor metastases; the mesentery itself varies from 5 to 6 mm. in thickness. On the left side a loop of ileum is adherent to the large tumor filling the lower part of the abdomen. The omentum is drawn up and contracted into a firm mass between the stomach and transverse colon. Everywhere it contains tumor deposits. Attached to the rolled-up omentum is a part of the ileum, which makes it appear as if the transverse colon passed through a canal. The ascending as well as the descending colon is firmly adherent to the posterior abdominal wall, being bound down by tumor metastases. Studding the intestine at various points are small tumor nodules.

The pericardial cavity contains a slight excess of clear yellow fluid, but there are no adhesions. The outer muscle is rather pale and soft; its vessels are tortuous. The coronary arteries contain yellow patches of atheroma. The pleural cavities, each of which contains 400 c.c. of clear yellow fluid, are free from adhesions. Small, translucent, carcinomatous nodules are found on the costal pleure.

Both lungs are emphysematous, and at their bases show marked edema. Scattered throughout both lungs are yellowish-white tumor masses, some reaching 1 cm. in diameter. The arteries of the right lung contain several definite

organizing thrombi. The spleen weighs 70 grams; attached to its surface are a few translucent tumor masses; its substance shows nothing of interest.

The liver is rather small, measuring approximately 25 x 16 x 9 cm. It is pale; the surface is fairly smooth, whitish in color, translucent, and somewhat umbilicated (Fig. 280). Several of the nodules are cystic, and the cyst-spaces contain a clear reddish fluid. Numerous nodules and cyst-like spaces, having corrugated walls, are scattered through the substance of the organ. There are numerous minute nodules on the surface and in the substance of the liver. On the under aspect of the liver the nodules are surrounded by areas of congestion.

The periportal glands apparently contain metastases. The gall-bladder is distended, evidently owing to pressure at its neck, resulting from impaction of the adjacent lymph-glands.

Both kidneys present the usual appearance, but on the surface of the right kidney is a small tumor nodule, 2 mm. in diameter. The ovaries are normal in size. The right adrenal is apparently normal, but the left about its middle portion contains a definite tumor nodule, 1 cm. in diameter. The pancreas is enveloped in adhesions, and at its tail contains a small tumor nodule. The stomach at the pyloric orifice is surrounded and compressed by a mass of enlarged glands; the greater curvature is intimately adherent to the tumor mass, lying between it and the transverse colon. The vermiform appendix in its last 2 cm. is entirely occluded by secondary growths. The external iliac vein on the left side shows a partial thrombosis. Many of the veins below Poupart's ligament are also thrombosed. The right femoral vein is completely occluded by a firm thrombus, pale brown in color.

In the inguinal regions the large tumor masses are intimately connected with the veins; the mass on the left side is the larger, and is composed of many cysts of considerable size, from which a slightly turbid fluid escapes. The mass on the right side is much firmer. The thyroid gland on both sides of the median line is much enlarged. A lymph-gland in the anterior axillary line, 10 cm. below the axilla, contains a cystic tumor. The bone-marrow of the femur is dark red in color, but fairly firm. The brain and cord are apparently normal.

Path. No. 2808. The specimen consists of the pelvic contents and of tissue from the inguinal region. The vagina presents the usual appearance, and the vaginal portion of the cervix is unaltered. The uterus measures 18 x 16 x 13 cm. (Fig. 281). The anterior surface of the fundus and the posterior wall are studded with myomatous nodules, varying in size from that of a pea to 7 cm. in diameter. Nearly all the nodules are sessile. Attached to the posterior surface of the uterus are several broad, fan-like adhesions. The uterine walls vary from 5 to 6 cm. in thickness, owing to the presence of myomatous nodules, which are sharply circumscribed and can be shelled out readily. One of them encroaches to a slight extent on the uterine cavity. The cervical canal is rather short, but the mucosa presents the usual appearance. The uterine cavity is 12 cm. in length, and the mucosa in the lower part has a slightly granular appearance, due to the

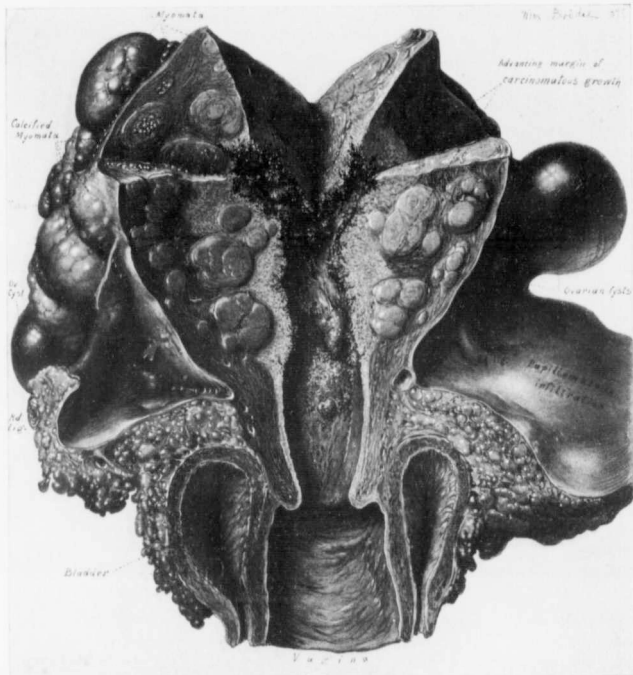


FIG. 281.—AN ENLARGED MYOMATOUS UTERUS. ADENOCARCINOMA OF THE BODY OF THE UTERUS. PAPILLO-CYSTOMATA OF BOTH OVARIES, WITH EXTENSION BY CONTINUITY TO THE INGUINAL GLANDS. ($\frac{1}{2}$ nat. size.)

Path. No. 2808. Aut. No. 1220. The bladder is contracted but normal. The uterus is much enlarged, irregularly pear-shaped, and has springing from its surface numerous subperitoneal myomata, some of which are calcified. The uterine walls are greatly thickened. They contain many small interstitial myomata. The vaginal mucosa is normal, and the vaginal portion of the cervix presents the usual appearance. The cervical mucosa in the lower part is unaltered, but near the internal os the mucosa covering the posterior wall is uneven and roughened, owing to the many minute, finger-like processes springing from the surface. In the body of the uterus the normal mucosa is no longer recognizable, being replaced by a ragged looking growth, from the surface of which spring myriads of delicate, finger-like processes. The growth is whitish in color, friable in appearance, and has invaded the uterine muscle to a marked degree; in places it completely encircles the myomatous nodules. At another level it was found penetrating some of the myomata, and had extended almost to the peritoneal surface, a distance of fully 5 cm. On the right side a small portion of an ovarian cyst can be seen. Springing from the outer and inner surfaces of these cysts are papillary masses, the papillary growth extending by continuity into the inguinal glands. On the left side is a small, multilocular ovarian cyst, from the inner surface of which arise papillary growths. The marked thickening and infiltration of the left inguinal region are due to papillary growths in the left ovary. A section through the thickened area would show large and small cyst-like spaces containing tree-like ingrowths. (After Thomas S. Cullen.)

short, finger-like outgrowths. In its upper portion the cavity shows no normal mucosa. The walls are somewhat ragged, and are implicated in a new-growth which in places infiltrates the tissue to a depth of at least 5 cm., penetrating the entire thickness of the uterine wall. The growth consists of delicate trabeculae, in the meshes of which is a fine, crumbly material.

The right tube is 9 cm. long, considerably curved, and throughout the greater part of its course lies in a depression between the myomatous nodules. It averages 1 cm. in diameter, and has a patent fimbriated extremity. The ovary is converted into a semicystic tumor, 6 cm. in diameter. Its outer surface is in places covered by adhesions, but springing from it at several points are delicate papillary projections or warty outgrowths. On section, the tumor is seen to be made up to a great extent of large and small thin-walled cysts. The semisolid portion consists for the most part of a somewhat friable papillary growth, which projects into the cyst cavities. The contents of the smaller cysts are gelatinous.

The left tube is 8 cm. in length, averages 6 mm. in diameter, and terminates in an occluded fimbriated extremity. Its outer surface is covered with dense adhesions that bind it to the posterior surface of the uterus. On more careful examination it is found that the point of occlusion is situated a short distance from the fimbriated extremity of the tube, and that the fimbriae are free; then we have a hydrosalpinx, and at the same time a patent outer extremity. The occlusion is due to dense adhesions.

Springing from the outer pole of the ovary is a smooth-walled cyst, 5 cm. in diameter. Its walls vary from 1 to 2 mm. in thickness; its anterior surface is, for the most part, smooth, but over an area 2.5 x 2 cm., and corresponding to the ovarian attachment, large clusters of papillomatous masses project into the cavity. Springing from the small portion of the ovary that remains are similar outgrowths.

The bladder mucosa presents the usual appearance, and no changes can be noted in the rectum. Both broad ligaments are markedly thickened, and areas of induration can be traced down to and are directly continuous with the growths in the inguinal region. On pressure they are somewhat elastic. The entire inguinal growth on the left side on section is found to consist of cyst-like spaces, some fully 5 cm. in diameter, which contain a gelatinous material. Springing from the partitions between the cysts are complicated papillary outgrowths. Such sections remind one very much of a papillocystoma of the ovary.

Histologic examination demonstrated that the growth involving the inner walls of the uterus was a typical adenocarcinoma, and that this had given rise to wide-spread metastases especially prominent in the liver. The tumors on either side of the uterus were papillocystomata, ovarian in origin. The growth on the left side had extended by continuity to the inguinal glands. For the complete histologic picture in this case see "Cancer of the Uterus," p. 468.

This case is of importance on account of the intimate relationship between the myomata and the adenocarcinoma. From the clinical examination alone the

case would have been considered as one of myomata. Still more interesting is the coexistence of the carcinoma of the body of the uterus and of papillocystomata of both ovaries. When an incision was made over the prominence in the left inguinal region, the papillary nature of that growth was clearly perceptible to the naked eye; and even if one had previously thought of the possibility of an adenocarcinoma of the uterus, the mind would have been entirely set at rest on that point, inasmuch as uterine carcinomata originating in the cervix or body never give rise to such metastases. The combination of the uterine myomata, the adenocarcinoma of the body of the uterus, and the papillocystomata of both ovaries is, of course, merely a coincidence. It may be well, however, to remember, when considering the advisability of removing an ill-defined pelvic tumor, that independent malignant growths may exist in the uterus and ovaries at the same time.

Gyn. No. 8147. Aut. No. 1605.

Anatomic Diagnosis.—Myoma and adenocarcinoma of the body of the uterus; metastases in the lymph-glands and adjacent peritoneum, pleuræ, mediastinal glands, and spleen; extension into the broad ligament; chronic endocarditis of the aortic and mitral valves; cardiac hypertrophy; edema and congestion of both lungs; infarction of right kidney; double hydroureter; general arteriosclerosis; perisplenitis.

The peritoneal cavity contains about 600 c.c. of a deep red fluid, mostly blood. The surface of the peritoneum is smooth. The uterus is markedly enlarged. Occupying the anterior wall of the uterus is a rounded myoma, 6 x 4 x 4 cm., which distorts considerably the shape of the organ. Projecting from the fundus behind the first tumor is a second smaller mass, which merges gradually with the body of the uterus. Situated upon the anterior surface, and also upon the adjacent surface of the bladder, are small, firm, grayish-white masses, with irregular and slightly nodular surfaces. Similar nodules are present in the posterior cul-de-sac and in the wall of the rectum. The uterus is 9 cm. in length, and on section the tumor in the anterior wall proves to be a typical myoma. The cavity of the uterus is 7 cm. in length and 1.5 cm. in width. It contains freshly coagulated blood, and the walls, especially the posterior portions, are irregular and ragged. Extending from the cavity and occupying the entire fundus and greater portion of the posterior wall is a soft, grayish-white tumor mass, in many places studded with opaque yellowish areas. There is marked thickening of the broad ligament, and the tubes and ovaries are densely adherent to the uterus, but there are no adhesions to the wall of the pelvis. Both ureters are embedded in the thickened broad ligament and show some slight dilatation. Examination of the wall of the rectum shows that the tumor masses mentioned above have invaded only the serous and muscular coats.

Microscopic examination of the tumor mass in the fundus shows it to be an adenocarcinoma.

Gyn. No. 7102. Aut. No. 1407.

Adenocarcinoma of the body of the uterus associated with subperitoneal and submucous uterine myomata.

L. R., aged fifty-three. Autopsy, August 18, 1899. Anatomic diagnosis: adenocarcinoma of the uterus; sloughing submucous myoma; pyometra; suppurating parametrium; vaginal implantation with carcinoma; extension to the peritoneum and the surface of pleura; thrombosis of the femoral veins; embolic plugging of both pulmonary arteries; infarction of the right lung; thrombosis of the vesical veins; cardiac hypertrophy and dilatation; chronic diffuse nephritis (small granular kidney); cholelithiasis.

The abdominal cavity contained a large amount of fluid. The intestines were slightly matted together, the coils being studded with small tumor nodules. The uterus was globular, extended 12 cm. above the symphysis, and was adherent to the abdominal wall. The tubes and ovaries were buried in adhesions. The uterus was pear-shaped, measuring 18 x 14 cm. The bladder was adherent to it. Attached to the uterus at the cornu was a pedunculated myoma, 3 cm. in diameter. Similar but smaller nodules were found on the posterior surface of the uterus. The uterine cavity was full of grayish-looking pus. The mucous membrane was 2.5 cm. in thickness, and apparently had grown into the uterine wall. The appearance strongly suggested carcinoma. Scattered throughout the uterine wall were numerous submucous myomata, the largest 6 cm. in diameter, and sloughing.

Histologic examination showed the growth to be a typical adenocarcinoma.

Gyn. No. 278. Aut. No. 117.

Carcinoma of the body of the uterus associated with large and small uterine myomata.

M. L. K., white, aged sixty-five. Admitted July 13, 1890. The patient has had no children and no miscarriages. The menopause was passed about fifteen years ago. For the last year she has complained of a constant bloody vaginal flow and of pain in the back, and during the last four months of pain in the right groin. She has noticed swelling of the feet and ankles for the last week. Filling the lower part of the abdomen is an oblong mass, apparently adherent to the abdominal wall. The umbilicus is slightly retracted. The vaginal outlet is intact; the cervix is small. The pelvis is full of small nodules. The patient has been delirious for the last few days. The urine contains a considerable amount of albumin.

Aut. No. 117 (July 27, 1890). On the anterior wall of the uterus is a partly calcified myoma, 3.5 cm. in diameter, and on the left side a myoma, 19 x 15 cm.,

grayish in color. This tumor is easily shelled out from the uterus. The left tube is dilated and elongated. It is 4 cm. in diameter and 24 cm. in length. The right tube is likewise closed; it is 2 cm. in diameter and 18 cm. in length. The body of the uterus contains several fungus-like, friable masses, and the upper part of the cavity is filled with projections resembling villi over an area 5 cm. in diameter.

Histologic examination shows the growth to be a typical carcinoma of the body of the uterus. The autopsy was an incomplete one, but sufficiently thorough to show that there were a chronic diffuse nephritis and hypertrophy of the left ventricle of the heart.

Gyn. No. 1173. Aut. No. 277.

Incomplete myomectomy, one nodule having been removed, others left behind on account of dense adhesions. Death resulted from general peritonitis. Unsuspected carcinoma of the body of the uterus was found at autopsy.

A. B., single, aged forty-three, colored. Admitted January 26, 1892. Menstruation began at fourteen, was regular, painful, profuse, and lasted from three to four days. Three and one-half weeks ago the patient noticed a lump in the left iliac region. For a few months previous she had had some pain. In November, 1891, in New York, she had two small myomata removed by the vagina. At the present time there is a growth down in the right ovarian region, and the patient has a slimy, watery vaginal discharge, with occasional burning. She is very anemic.

Vaginal Examination.—The outlet is relaxed. The cervix is near the outlet and is intact. Filling the entire pelvic cavity is a hard and immovable mass, a nodular portion, the size of two fists, occupying the left side of the pelvis.

Operation, February 13, 1892. Myomectomy.

The uterus apparently contained two myomatous masses, the anterior one the size of an orange, the posterior one a little larger. After the release of a few intestinal and omental adhesions the anterior myoma was enucleated. The posterior one could not be shelled out on account of the dense adhesions.

The patient vomited a great deal after the operation. The abdomen soon became distended; the pulse grew rapid, and the temperature rose to 103° F. on the fifth day, but dropped to 101.5° F. on the sixth. The patient at this time was covered with a cold, clammy sweat; she voided her urine involuntarily, and died on the same day. She had definite signs of peritonitis.

Aut. No. 277. Anatomic diagnosis: Acute purulent peritonitis following abdominal myomectomy; subperitoneal and submucous uterine myomata; unsuspected carcinoma of the body of the uterus; general arteriosclerosis; cardiac hypertrophy; chronic diffuse nephritis; emphysema of both lungs; bronchopneumonia of the right lung.

In the peritoneal cavity is a considerable accumulation of turbid fluid that has a decidedly fecal odor. There are slight intestinal adhesions. In the pelvic cavity is a sloughing area corresponding to the point of myomectomy. The tubes and ovaries are bound down by adhesions. The uterine cavity is filled with sloughing tumor masses, which seem to be infiltrating the uterine wall. The cervix is free. Scattered throughout the uterus are several small myomata. Sections from the uterine wall revealed adenocarcinoma of the body. Cultures from the peritoneal cavity showed a pure growth of *Staphylococcus pyogenes aureus*.

CARCINOMA OF THE RECTUM ASSOCIATED WITH UTERINE MYOMATA.

In one of these cases the carcinoma was situated in the sigmoid flexure. Both ovaries were the seat of cystic tumors, and the uterus contained myomata. In this case fatal peritonitis developed. On p. 392 is described in detail a case in which a carcinoma of the sigmoid was accidentally discovered after the removal of a large myomatous uterus. A portion of the bowel was resected, and the patient lived for several months.

In the second case here described the myomatous uterus was large. One ovary was the seat of an abscess, and all the tissues were densely matted together by pelvic adhesions. Examination of the rectum revealed a carcinoma involving the entire lumen of the bowel, situated 1 cm. from the anal orifice. In neither of these cases was an operation feasible.

Gyn. No. 12656. Aut. No. 2671.

Carcinoma of the sigmoid flexure, uterine myomata, bilateral adenocystomata of the ovary; secondary peritonitis.

E. C., colored, single, aged thirty. Admitted January 25; died February 8, 1906. The patient has complained of pain in the abdomen for the past three years. At present she has four or five stools daily, which show the presence of blood. This symptom has been noted for nearly a year, although the patient has no hemorrhoids. She appears to be very ill, and is extremely emaciated.

A week after admission to the hospital there was considerable abdominal distention, and a rather definite tumor mass could be felt in the right hypogastrium. She died five days later. On account of the extreme weakness a satisfactory examination could not be made.

Aut. No. 2671. Anatomic diagnosis: Bilateral ovarian adenocystomata; multiple uterine myomata; carcinoma of the sigmoid flexure; perforation of the bowel; gangrenous peritonitis.

The contents of the abdominal cavity are crowded high up into the cavity by two large tumor masses which extend upward from the pelvis; one lying in the median line extends to 1.5 cm. above the symphysis pubes; the second lies in the left flank and extends to the costal border. Between the two masses

is a cavity containing a tarry, greenish-black material, with a mixture of blood and having a distinctly gangrenous odor. The tumor masses are covered with a thick fibrous membrane outside the capsule, which apparently represents a reflected peritoneal fold. The intestines are bound down to the tumor masses by fibrous adhesions, and to each other by a firm fibrinopurulent exudate. The diaphragm reaches to the third rib on the right side, and to the fourth interspace on the left. The pelvic viscera and tumor masses were removed in one mass. On section, the uterus seems normal in size; it has been pushed forward and to the left by the tumor. Rising from its fundus is a pedunculated tumor, 7.5 x 4 cm. in diameter. This tumor is slightly lobulated; it is firm, and on section shows interlacing bundles of tissue in a somewhat translucent background. A similar but smaller tumor, measuring 2.5 x 1.5 x 1 cm., lies just beneath the serosa. In the anterior surface of the uterus a third tumor, 8.5 cm. in diameter, is present. They all present the typical myomatous appearance. The large tumor masses described earlier are attached to the uterus by an ovarian ligament; one occupies the position of the right ovary, the other the left. The mass corresponding to the right ovary measures 19 x 12 x 12 cm. It is firm, and on section has a light yellowish-pink color, and on close inspection is seen to have a honey-combed structure, the surface showing many small cavities, 1 to 3 mm. in diameter, containing colloid material. The cut surface is somewhat uniform in appearance. The capsule has been in no way invaded by the growth. The mass in the position of the left ovary measures 15 x 10.5 x 10 cm.; in the upper part of the tumor it abuts on the gangrenous peritoneal cavity mentioned. This cavity, which appears as a deep ragged space, is filled with foul-smelling, softened, grayish-black material. Except for this and a somewhat general greater degree of softness, this tumor resembles that found in the sigmoid flexure. There is a fungating tumor mass in the bowel, 16 cm. from the anal opening. This mass is made up of numerous large nodules of irregular shape, projecting into the lumen—at one point for a distance of 2.5 cm. These masses surround a crater-like depression where there has been a perforation of the intestinal wall. The perforation leads upward between the tumor masses into the cavity above described. On section of the tumor mass the muscular coat of the intestine is found to be invaded by a somewhat opaque growth. Above the ulceration the intestine is dilated and its mucosa shows numerous ulcers. Its wall is hypertrophied.

Microscopic examination of the uterine nodules shows them to be typical myomata without degeneration. Sections from the solid portions of the ovarian cysts show the tumors to be made up of alveoli containing a colloid material. The alveoli are lined with a single layer of uniformly staining epithelial cells. Portions of the section show some necrosis, but no signs of malignancy are present. In one necrotic area there is leukocytic invasion. Sections from the tumor in the sigmoid flexure show the growth to consist of large alveoli lined with

irregularly shaped and stained cells, lying usually in a single row. The growth has invaded the muscular coat as far as the peritoneum.

This case is very interesting on account of the multiplicity of the pathologic processes detected in the pelvis. Not only are there the myomatous uterus, and the large ovarian cysts, but also the carcinoma of the sigmoid flexure, which in itself would have been sufficient to cause death.

Gyn. No. 562. Aut. No. 172.

Carcinoma of the rectum; uterine myomata.

J. Z., white, admitted February 3; died February 17, 1891. The patient is forty-eight years of age. She has been married twenty years, but has never been pregnant. The menstrual periods have been regular during the past year. The patient complains of pain in the left flank, with alternating attacks of constipation and diarrhea, with occasional bloody stools. She has lost considerably in weight during the past two years. During this same time she has suffered considerably from pain and diarrhea, but these symptoms have been especially troublesome during the past three months. During the past six months blood has frequently been found in the stools. In the past three months there has been pain in the left iliac region, and also in the lower abdominal zone. Palpation in this region elicits considerable tenderness. On vaginal examination the uterus is found to be markedly enlarged, hard, and fixed; it fills up the whole lower portion of the pelvic cavity. On manipulation a free bloody discharge comes from the uterus. Owing to marked tenderness, examination is exceedingly difficult.

Aut. No. 172. The pelvic viscera were removed *en masse*. Douglas' pouch was obliterated by fibrous adhesions between the rectum and the uterus. The inner wall of the rectum, 1 cm. from the anus, is occupied by an ulcerated new-growth which implicates the entire circumference of the bowel and is 7 cm. long. The ulcerated surface of the growth is whitish; its margins are elevated and of a soft, grayish appearance; intermingled are areas of hemorrhage. The whole presents a crater-like appearance. The wall of the rectum has been entirely destroyed. Over the central ulcerated area it measures 5 cm. in diameter. The muscular wall of the rectum is hypertrophied above the growth.

The posterior wall of the uterus is firmly embedded in adhesions to the cancerous part of the bowel, and is the seat of several interstitial myomata. The largest on the right side is 5 cm. in diameter. There is a soft, pedunculated sub-mucous myoma, 1.5 cm. long, and in the right lateral vaginal wall a cyst, 4 cm. in diameter. The left ovary contains an abscess 7 x 8 cm., and from it escapes green, foul-smelling pus.

Cultures from the abscess of the ovary show a colon-like bacillus, and sections from the rectal tumor prove that it is an adenocarcinoma of the bowel.

SARCOMATOUS TRANSFORMATION OF MYOMATA DETECTED AT AUTOPSY.

In only one case was a primary sarcoma detected in a myoma at autopsy. (Gyn. No. 6045. Aut. No. 1085.) This case was carefully described by the late Dr. Louis Livingood, and is given in detail (page 224) with a series of similar growths detected at operation.

SARCOMA OF THE BLADDER ASSOCIATED WITH UTERINE MYOMATA.

As this condition is exceedingly rare, a short history of the case is given.

Gyn. No. 832. Aut. No. 211.

L. G., aged forty, colored. Admitted to the Johns Hopkins Hospital June 24; died July 12, 1891. She had been married twenty-five years and had had four children and one miscarriage. For the previous month she had been complaining of incontinence and painful micturition. The urine was very strong in odor and of a dirty, muddy color, and material resembling grit had been passed. These pieces at times were as large as beans. She had complained of pain in the lower part of the abdomen for the last two months, and said that it burned like fire. She had had fever and chills, and had lost in weight.

The patient on admission appeared anemic and had a worn expression. The abdomen was slightly swollen, and she complained of sudden attacks of pain. On examination the outlet was found to be relaxed, the anterior vaginal wall was tense and sensitive, and there was a mass the size of a closed fist just behind the symphysis. It moved up and down in the pelvis and had a markedly solid feeling. The uterus was retroflexed. The patient gradually lost ground, and died July 12, 1891.

Aut. No. 211, July 13th. Anatomic diagnosis: Sarcoma of the bladder, no metastases; extensive diphtheric cystitis, pyelitis, some pyelonephrosis, especially of the left kidney, chronic diffuse nephritis, apparently limited to the left kidney, moderate atheroma, slight cardiac hypertrophy, moderate pulmonary emphysema, uterine myomata.

The bladder-walls are much thickened, measuring on an average 0.8 to 1 cm. in thickness. The muscular coats are hypertrophied. The mucous membrane of the bladder has been almost entirely replaced by extensive diphtheric ulceration. From the inner surface of the bladder project several soft, grayish-white masses. The free surface in some places is covered with a slight opaque grayish-white necrotic tissue, and the tissue beneath is almost homogeneous, appearing like mucous membrane. The growths vary in size from 0.3 to 1.5 cm. in diameter, and project in places as far as 1 cm. into the bladder. They have broad basal attachments, and are most abundant in the posterior wall of the bladder, near its middle portion. The vaginal mucosa is coated, over a large part of its extent, with a grayish, coherent false membrane, which in places can be scraped off without

loss of substance, while in other places the mucosa itself seems to be nothing more than necrotic membrane.

The uterus is 7 cm. long and contains in its walls myomata, the largest of which is 2 cm. in diameter. The myomata are submucous, interstitial, and sub-peritoneal. The left ovary and tube are surrounded by old adhesions.

Histologic Examination.—The free surface of the bladder growth is covered with a necrotic layer containing many bacilli and some chromatin particles. The new-growth is composed of closely packed cells, varying in size and shape. In general they are large and somewhat fusiform, not mistakable for smooth muscle-fibers. In other places there are epithelioid cells, round, oval, or polygonal in shape. There are also cells with large, well-staining vesicular nuclei, and a protoplasm that is somewhat granular. The cells in the growth are separated from one another by a scant amount of a finely fibrillated substance. Sometimes the cells occur in clumps, apparently in lymph-spaces, but there is no regular alveolar arrangement. Strands of the same kind of tissue extend out between the bundles of smooth muscle tissue, or they often spread out into the layers. This invasion of the muscle extends in places throughout the entire thickness of the bladder-wall, but the main mass of the tumor lies inside of the muscular coat, in the situation of the mucosa or submucous coats, which are not to be recognized.

The tumor is a mixed large-celled sarcoma, with a predominance of large fusiform cells, often arranged in bundles, especially along the blood-vessels. The presence of the uterine myomata in association with sarcoma of the bladder is, of course, a mere coincidence.

TUBERCULOSIS OF THE UTERUS ASSOCIATED WITH MYOMATA.

There was only one case in which tuberculosis of the uterus coexisted with uterine myomata. In Aut. No. 136 on a patient thirty-two years of age pulmonary tuberculosis was found. The mesenteric glands were implicated. In the left uterine cornu was a myoma, 3 cm. in diameter, that showed areas of degeneration. The body of the uterus was occupied by a grayish mass which projected into the canal, and scattered throughout it were tubercles. In this case the tuberculous process in the uterus was undoubtedly secondary to the pulmonary lesion.

AUTOPSIES IN WHICH HEART LESIONS WERE FOUND, POSSIBLY ATTRIBUTABLE TO UTERINE MYOMATA.

We have two cases in which it seemed that the myomata directly or indirectly had been responsible for the cardiac lesion. In the one case there were vegetations on the heart-valves; in the other, degenerative changes were found in the heart muscle.

Gyn. No. 6185. Aut. No. 1112. Path. No. 2441.

Multiple myomata of the uterus, with one large sloughing submucous nodule. Acute vegetative aortic and mitral endocarditis; septic infarction of the left lung, acute localized pleurisy, old pleuritic adhesions, chronic interstitial splenitis, subacute glomerular nephritis, recent miliary abscesses in the renal pyramids, chronic adhesive pelvic peritonitis.

The patient was fifty-four years of age, colored. Admitted June 21; died June 25, 1898. She was in a precarious condition, and had to be operated upon at once. On examination under ether an ovoid tumor was found projecting from the vulva. It was yellowish brown or greenish in color, and cystic. It had a pedicle 2.5 cm. in diameter, and sprang from the cervix on the left side. A smaller and similar mass was also seen projecting from the cervix. The uterus was the size of that of a four months' pregnancy, hard, and fixed in the pelvis. The pulse was very rapid, and the temperature 101.8° F. The submucous nodules were removed in the usual way, but the patient steadily grew worse. Her maximum temperature on the day of her death was 106.2° F.

Aut. No. 1112. The myomatous uterus was found firmly bound down in the pelvis by numerous adhesions. The aortic and mitral valves were the seat of fresh vegetations. Septic infarction was found in the left lung, and there were evidences of old adhesions in the pleural cavity.

The kidneys were the seat of a subacute inflammation, and as evidences of the recent infection miliary abscesses were found in the pyramids of the left kidney. The offending organism was *Staphylococcus pyogenes*.

Path. No. 2441. The submucous nodule removed from the uterus at operation was 12 cm. long and 7 cm. in diameter. Its surface was slightly roughened; otherwise it presented the typical myomatous appearance. Sections from the surface of the tumor showed no trace of mucosa. The surface was covered with polymorphonuclear leukocytes and necrotic tissue. Beneath was a very vascular zone, composed of large and small blood-vessels. So abundant were these blood-vessels that in places they occupied half the field. Some of the vessels contained organizing thrombi. The surrounding stroma showed considerable hemorrhage, but was covered with many polymorphonuclear leukocytes. The tumor was composed of non-striated muscle-fibers running in various directions. It was an ordinary submucous myoma, the surface of which had become necrotic and had gradually disintegrated. In this case a general infection had probably developed from the sloughing submucous myoma, and might account for the vegetations on the cardiac valves and for the recent miliary abscesses in the kidney.

Gyn. No. 77. Aut. No. 69.

Myoma of the uterus with central necrosis, pyonephrosis due to pressure on the ureters. Chronic passive congestion of the lungs, displacement of the diaphragm and abdominal viscera by pressure of the tumor, hypertrophy and hyaline degeneration of the heart (Figs. 282 and 283).

An abstract of the case reported by Dr. Ernest K. Cullen in the Johns Hopkins Bulletin, 1906, vol. xvii, p. 267, is quoted here:

The patient was admitted January 6, 1890. No satisfactory history could be obtained on account of her condition. She, however, first noticed a tumor in the abdomen about four years ago. This had gradually increased in size. The abdominal wall was uniformly distended by a large tumor, which on palpation presented two smaller nodules in the lower abdominal zone. The patient had a slight but exceedingly fetid vaginal discharge. She was examined by Dr. Osler, who, apart from the pressure symptoms due to the tumor, found nothing abnormal. The patient gradually grew weaker and died on January 31st.

Aut. No. 69. The uterus is 19 cm. in length, anteflexed, and occupies the anterior portion of the tumor. The tumor is nodular, and divided into two distinct lobes. On section, it presents a triangular cavity, which at its base measures 11 cm. It is filled with a slightly blood-stained fluid, and dense masses of firm white elastic tissue. The lymphatics in the lower abdomen are greatly dilated and contain a brownish colored fluid.

The left kidney is enormously dilated and turned toward the front. The capsule is adherent. The surface is irregular and lobulated. Beneath the capsule are numerous whitish areas, while surrounding the kidney are purulent foci. The pyramids are flattened. The pelvis is generally smooth and hard, and covered with a fibrinopurulent exudate. The ureters are dilated and closely adherent to the posterior surface of the tumor. The right kidney is about the same size as the left, and presents essentially the same features.

The bladder mucosa shows ecchymoses, is deeply injected, and contains a small amount of turbid urine.

The heart is slightly enlarged, and weighs 245 grams. The pericardial surfaces are smooth. With the exception of a slight contraction of the mitral orifices, the valves appear to be normal. A few pale patches are seen scattered throughout the endocardium. The wall of the left ventricle measures 17 mm., and that of the right 4 mm. in thickness. The heart muscle is tolerably firm and dark brown in color. On section of the left ventricular wall, small foci are visible immediately beneath the endocardium. The orifices of the coronary arteries are dilated.

Histologic appearances of the heart muscle. Scattered throughout the wall of the left ventricle, especially near the endocardium, are numerous isolated groups of opaque, deeply staining fibers, which appear to have undergone calci-

fication (Fig. 282). These areas are composed of adjacent fibers ranging in number usually from three to twelve. Such fibers in most instances are well defined, but occasionally appear irregular in outline, as if disintegrating. They have lost both their cross and longitudinal striations, and appear rather homogene-

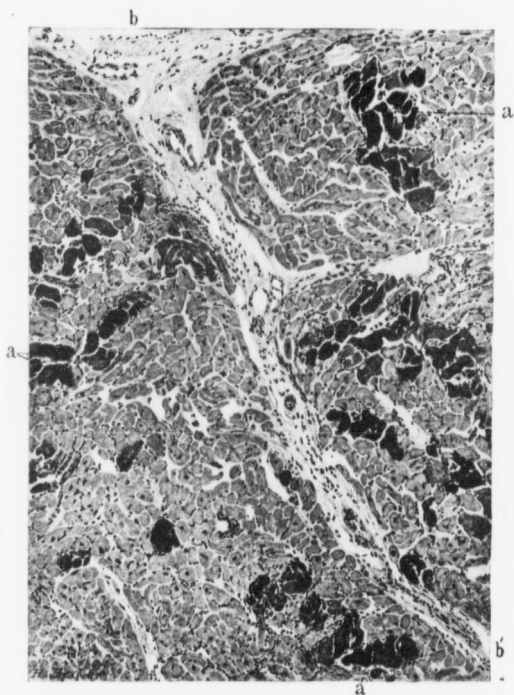


FIG. 282.—CALCIFICATION OF THE HEART MUSCLE ASSOCIATED WITH UTERINE MYOMATA. ($\times 125$ diam.) Aut. No. 69. The dark areas represent calcified muscle-fibers. The most characteristic of these are indicated by a. The stroma between the muscle-fibers shows some small-celled infiltration. (After Ernest K. Cullen.)

ous and opaque, staining deeply with methylene-blue and hematoxylin. No nucleus is discernible within the fiber, but fine, small, oval or round nuclei are situated about it. In the interventricular septum the process appears to be much less extensive. Single fibers (Fig. 283) are observed, which present a homogeneous, granular appearance, and with the eosin stain are differentiated from the sur-

rounding fibers. Such fibers are stained faintly brown in color, and the nucleus is absent. Definite calcification is observed in small groups of fibers which, in general appearance, resemble those in the wall of the left ventricle. In sections taken from other parts of the heart no alteration of the fibers was visible.

At the time of the autopsy Professor Welch studied the microchemical reaction of these altered fibers in the fresh specimen, and found, on the addition of glacial acetic acid to those fibers which contained a highly refractive substance, a slow dissolution of this material without the evolution of gas. This refractive material dissolved rapidly in hydrochloric and nitric acid, also without the evolution of gas. As it dissolved the fibers swelled and lost their refractive

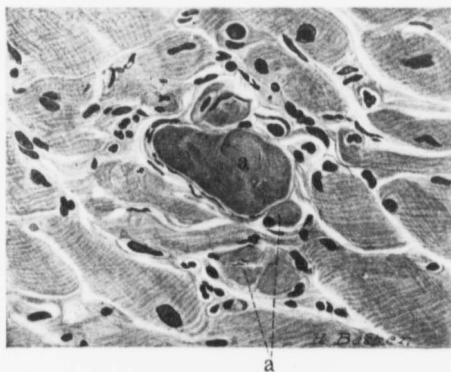

FIG. 283.—HYALINE DEGENERATION OF HEART MUSCLE, ASSOCIATED WITH UTERINE MYOMATA. ($\times 650$ diam.)

AUT. NO. 69. The section is from the interventricular septum. Some of the muscle-fibers (a) have undergone typical hyaline degeneration, and the stroma surrounding them shows some small-round-celled infiltration. (After Ernest K. Cullen.)

property and appeared hyaline. This substance was insoluble in strong caustic potash and ammonia. In the frozen section left over night in an aqueous solution of potassium dichromate the refractive material dissolved slowly. The most interesting reaction was observed in the specimen treated with strong sulphuric acid. The refractive material changed without the evolution of gas into beautiful clumps and rosettes of narrow, rhombic crystals of calcium sulphate. Smaller crystals, usually single, appeared in the fluid close by, but no such reaction was evidenced in specimens from other parts of the heart.

Ernest Cullen says further: "The etiology of the cell necrosis in this case cannot be definitely determined, but it is possible that the etiologic factor concerned in the production of the existing pyonephrosis may also be responsible

for the lesion in the myocardium. The pressure exerted upon the heart by the large abdominal tumor may also have entered into the causation."

As noted in the history, no definite account of previous illness could be obtained. The myoma caused pressure on the ureters, infection followed, and then necrosis in the heart muscle, with subsequent deposit of calcium salts. It is quite possible that if no myoma had existed no pyonephrosis would have developed, and consequently no cardiac lesion would have followed. In any event the presence of the myoma was a predisposing factor.

In neither of these cases is there clear presumptive evidence that the myomata were responsible for the cardiac lesion, but the clinician will certainly gather the impression that if the myoma had been removed several years before, the danger of cardiac lesion would have been materially less.

DEATH DUE DIRECTLY TO MYOMATA.

All surgeons are familiar with the marked pallor seen in patients suffering from continued and severe hemorrhages when submucous myomata are present, and also with the elevation of temperature and other septic phenomena which accompany foul-smelling and sloughing submucous myomata.

In Gyn. No. 11337 the patient entered the hospital complaining of weakness and loss of blood. Her hemoglobin was only 12 per cent., and she died within four days. The autopsy findings were those that might have been expected after excessive hemorrhage.

In Gyn. No. 6185 the symptoms were those of exhaustion from hemorrhage, combined with sepsis due to absorption from the foul, sloughing submucous myoma; the secondary cardiac and pulmonary foci were a natural sequence to the local necrotic and sloughing myoma.

A study of Gyn. No. 10337 shows that the patient was suffering from emaciation and marked toxemia, evidently in large measure due to a sloughing submucous nodule. Both kidneys contained retention cysts. These probably hastened the patient's death, but the changes may likewise have been primarily due to the myoma.

In the fourth case, Gyn. No. 77, there were a fetid discharge from the vagina and central necrosis of one of the myomata. The abdominal contents had been much displaced by the tumor, and the ureteral dilatation was caused by pressure exerted by the tumor. In this case the death was in all probability immediately due to the pus kidney, but primarily to the tumor.

A careful perusal of these cases will certainly convince the reader that if the myomata had not been present, or if they had been removed before the nodules had become submucous, the outlook for the patients would have been greatly improved.

CASES IN WHICH MYOMATA CAUSED DEATH.

Gyn. No. 11337. Aut. No. 2319.

Intramural myoma; hemorrhage from the uterus; extreme secondary anemia; fatty degeneration of the heart and other organs; focal necroses in the liver; double hydrosalpinx; ovarian cysts; healed infarct of spleen.

B. H., colored, aged thirty-eight. Admitted June 6; died June 10, 1904. She complained of weakness and bleeding.

She was married ten years ago, but has had no children. Six months ago she began to have hemorrhages. The flow lasted about three weeks. From that date there has been almost constant bleeding, and she has been in bed for three months. When the bleeding is not present, there is a very foul discharge. The patient is very weak and short of breath. There is considerable nausea and vomiting. The mucous membranes are very pale; the hemoglobin is 12 per cent. Red blood-corpuscles, 1,828,000. In making a blood examination the patient bled so much from the prick in her ear that compresses had to be put on to stop the bleeding. Adrenalin had no effect.

Vaginal Examination.—A mass is felt extending a hand's-breadth above the symphysis. The cervix is smooth and normal. There is a mass the size of a cocoonut occupying the fundus.

The patient gradually lost ground, and died the fourth day after her admission. Her temperature varied between 102° F. on admission and 103° F. on the second day; on the fourth day, the day of her death, it reached normal. The uterine cavity was irrigated and packed with gauze, but this procedure did not in any way check the bleeding.

At autopsy it was found that the uterus contained three myomata. The chief bleeding had come from the submucous myoma, and there were marked anemia of the various organs, fatty degeneration of the heart, and focal necroses in the liver.

In this case the death seems to have been due primarily to the excessive uterine hemorrhages.

Gyn. No. 10337. Aut. No. 2088.

Uterine myomata with a sloughing submucous nodule; marked emaciation and profound toxemia. Retention cysts in the kidneys.

J. McC., aged forty, colored. Admitted March 17; died March 22, 1903. Her history was obtained from her sister-in-law, as the patient was unconscious. Fifteen years ago she had an attack of typhoid fever and was insane. Recovery took place after two months. Since then she has been a little queer at times. Ten years ago an abdominal tumor was first noticed. This has grown

slowly. Three weeks ago she was taken ill, but no further history could be elicited.

On admission she was very irrational and much emaciated. The temperature was 96° F.; the pulse, 100. She was drowsy most of the time, apparently profoundly toxic. The lung-sounds were normal. There was a loud systolic murmur at the apex, transmitted to the axilla and over the entire chest. The abdomen was symmetrically enlarged below the umbilicus, and on the upper surface of the tumor were three nodules. The patient's condition gradually grew worse, and she died five days after admission.

At autopsy a sloughing submucous myoma was found, and the uterus also contained numerous nodules. In both kidneys retention cysts were encountered. There were marks of old rachitis, and apparently mucoid degeneration of the sub-pericardial fat.

Grayish opaque flecks were found in the myocardium.

In this case the cause of death seems to have been the sloughing submucous myoma, associated with the results of pressure.

For the details of Gyn. No. 6185 (Aut. No. 1112) see p. 422, and for the findings in Gyn. No. 77 (Aut. No. 69) see p. 423.

SUMMARY OF THE AUTOPSY FINDINGS IN WHICH UTERINE MYOMATA WERE PRESENT.

The following tabulation gives the more essential autopsy findings as viewed from the surgeon's standpoint:

Tuberculosis of the Fallopian tube associated with uterine myomata (Aut. No. 1898).....	1 case.
Carcinoma of the ovary (primary) associated with uterine myomata (Aut. Nos. 474 and 1371).....	2 cases.
Sarcoma of the bladder associated with uterine myomata (Aut. No. 211).....	1 case.
Carcinoma of the sigmoid flexure associated with uterine myomata (Aut. Nos. 172 and 2671).....	2 cases.
Tuberculosis of the uterus associated with uterine myomata (Aut. No. 136).....	1 case.
Carcinoma of the cervix associated with uterine myomata (Aut. Nos. 689, 926).....	2 cases.
Carcinoma of the body of the uterus associated with myomata (Aut. Nos. 117, 277, 505, 1220, 1407, 1605).....	6 cases.
Sarcomatous transformation of uterine myomata (Aut. No. 1085).....	1 case.
Cases in which sloughing myomata were directly the cause of death (Aut. Nos. 69, 1112, 2088, 2319).....	4 cases.

According to this table, in 8 cases carcinoma of the uterus complicated the myomata. In all but one of these cases the myomata were of sufficient size to obscure the diagnosis. In one case the myomata had become sarcomatous. Thus, out of 148 autopsies, in 6 per cent. the myomata were associated with malignant changes in the uterus.

In two cases the ovaries were the seat of primary carcinoma. In one instance primary sarcoma of the bladder existed, and in two primary carcinoma of the

sigmoid flexure was found. Thus in 14 out of 148 cases primary malignant changes were present either in the uterus or in one or other of the pelvic organs.

In 4 cases death was directly attributable to the uterine hemorrhage, and as a result of the necrosis and sloughing of the myoma. Accordingly, in 18 cases out of 148, death was primarily due to changes in the pelvic organs. In this connection we have purposely excluded one case in which tuberculosis of the body of the uterus existed; one case of tuberculosis of the tube, and those cases in which the myomata by pressure caused changes in the ureters and kidneys.

The diagnosis of uncomplicated uterine myomata is, as a rule, simple, but when other pathologic processes develop in the adnexa, bladder, or rectum, it becomes impossible for the operator to determine the exact condition until he carefully dissects the tumor in the laboratory. We do not wish to make any deduction from this large percentage of cases in which changes in the pelvic organs were the primary cause of death, but would suggest that the reader carefully review the data, in order to determine in what percentage of cases he thinks he would have been likely to have made an accurate diagnosis, and then decide for himself whether it is wise to let myomata alone or to remove them.

CHAPTER XXIV.

THE CAUSE OF UTERINE MYOMATA.

In searching* for a clue as to the origin of uterine myomata we have approached the subject from three main avenues:

1. Heredity.
2. The clinical course of myomata.
3. The microscopic appearance of very early myomata.

Heredity.—In the accompanying tabulation are embodied the findings relative to the family history in 1245 cases. Naturally, it is often impossible to determine the exact nature of the growths, hence it has been thought advisable to give all the available data concerning tumors of every kind mentioned as having occurred in relatives.

It will be noted that in 11 cases one or more of the patient's sisters had had uterine myomata. In 3 of these, two of the patient's sisters had had myomata.

FAMILY HISTORY IN 1245 CASES OF UTERINE MYOMATA.*

Grandmother:	Carcinoma, 9 cases (uterine in 1 case).									
Mother:	Carcinoma, 20 cases (uterine in 6 cases).									
	Sarcoma of jaw, 1 case.									
	"Ovarian tumors," 2 cases.									
	"Abdominal tumors," 10 cases (1 myoma). Death was due to the tumor in 7 of the 10 cases.									
Aunt:	Carcinoma, 21 cases.									
	Abdominal tumor, 5 cases.									
Sister:	Carcinoma, 8 cases:	<table style="border: none; margin-left: 2em;"> <tr> <td style="padding-right: 1em;">Uterus</td> <td style="text-align: right;">2</td> </tr> <tr> <td style="padding-right: 1em;">Breast</td> <td style="text-align: right;">1</td> </tr> <tr> <td style="padding-right: 1em;">Stomach</td> <td style="text-align: right;">1</td> </tr> <tr> <td style="padding-right: 1em;">"Cancer"</td> <td style="text-align: right;">1</td> </tr> </table>	Uterus	2	Breast	1	Stomach	1	"Cancer"	1
Uterus	2									
Breast	1									
Stomach	1									
"Cancer"	1									
	"Tumor of womb," 4 cases.									
	"Abdominal tumor," 3 cases.									
	Ovarian tumor, 1 case									
	Myomata, 11 cases:	<table style="border: none; margin-left: 2em;"> <tr> <td style="padding-right: 1em;">2 sisters (besides patient)</td> <td style="text-align: right;">3 cases</td> </tr> <tr> <td style="padding-right: 1em;">1 sister</td> <td style="text-align: right;">7 "</td> </tr> <tr> <td style="padding-right: 1em;">1 half-sister</td> <td style="text-align: right;">1 case</td> </tr> <tr> <td></td> <td style="text-align: right; border-top: 1px solid black;">11 cases</td> </tr> </table>	2 sisters (besides patient)	3 cases	1 sister	7 "	1 half-sister	1 case		11 cases
2 sisters (besides patient)	3 cases									
1 sister	7 "									
1 half-sister	1 case									
	11 cases									
Grandfather:	Carcinoma, 4 cases.									
Father:	" 24 " (11 gastric).									
Uncle:	" 11 " "									
Brother:	" 4 " (2 gastric).									

*In the majority of the cases of carcinoma in relatives it was not mentioned whether the patient came from the maternal or paternal side.

A glance at the foregoing table must at once impress the reader with the fact that heredity plays little or no rôle in the development of uterine myomata, although in a few cases one or more of the patient's sisters may have had myomata of the uterus.

The Clinical Course of Myomata.—From the table on p. 434 we learn that myomata are most common during the child-bearing period, and from p. 457 that of 1149 women, 584 were sterile. Of the sterile patients, 295 were married women and 289 single. The impression gained by us after a critical examination of the histories was that the uterus must have something to do, and that if it is not kept relatively busy as a result of frequent pregnancies, it may tend to show its activity in another direction, namely, in the formation of myomata.

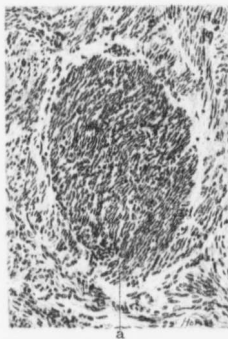


FIG. 284.—A VERY EARLY MYOMA. ($\times 135$ diam.)

Gyn. No. 3385. Path. No. 634. The myomatous uterus filled the pelvis. Occupying the center of the field is an oval-shaped myoma. The muscle fibers in the myoma as yet show no tendency to form whorls. At the nuclei of the myoma gradually merge with those of the surrounding muscle.

On the other hand, it may be possible that the unknown factor which stimulates the development of myomata may in itself tend to cause the sterility.

The Microscopic Appearance of Very Early Myomata.—Where large myomatous tumors exist, it would naturally be impossible to determine the source of origin, and only from an examination of the minute myomata can we hope to gain any definite clue as to their mode of development.

It has been claimed that the myomata primarily develop around blood-vessels, and we have carefully examined many small nodules to see if the vessels really bore any causal relation.

In Fig. 284 we have a very early myoma. It forms an oval nodule and is sharply defined from the surrounding muscle. Its nuclei are closely packed together, and thus the myoma apparently stains more deeply than does the

surrounding muscle. At one point the nodule gradually shades off into the surrounding tissue. There is nothing in the picture to in any way suggest an origin from blood-vessels.

In Fig. 285 we have a myoma slightly larger in size. The muscle-fibers in the myomatous area show a marked tendency to curl up in bands or to assume irregular forms. Otherwise there is no deviation in appearance from the sur-

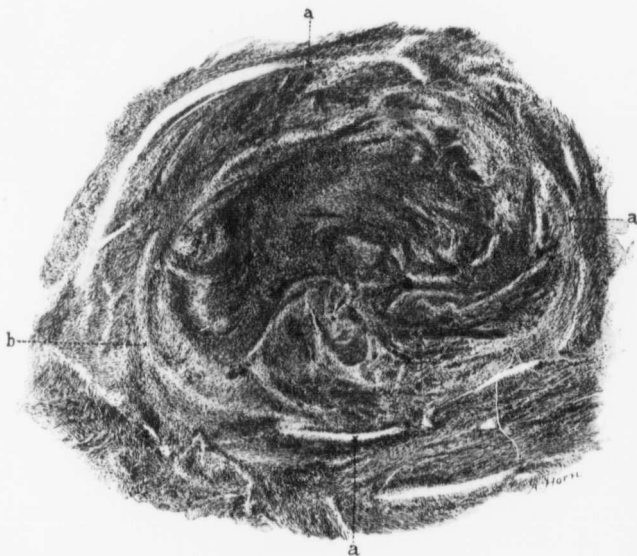

FIG. 285.—AN EARLY MYOMA. ($\times 35$ diam.)

Gyn. No. 2699. Path. No. 246. The large multinodular myomatous uterus was 14 x 16 x 17 cm. Occupying the greater part of the field is a myoma, recognized by the wavy arrangement of its muscle-bundles. Its confines are not sharp, but can be definitely made out at a. At b the myomatous tissue blends imperceptibly with the surrounding muscle. No blood-vessels are to be seen in the tumor.

rounding muscle. In this myoma also there is not the slightest evidence of the tumor having developed around blood-vessels.

Fig. 286 represents an early myoma from a pregnant uterus. Here, as a result of the pregnancy, the contrast between the uterine muscle and the nodule comes out sharply. The nodule is approximately spheric, and composed of interlacing bundles of muscle-fibers. It has no blood-vessels of any appreciable size. At some points it gradually blends into the surrounding muscle.

In none of the myomata thus far studied have we ever seen any conclusive evidence that the tumor had developed around blood-vessels.

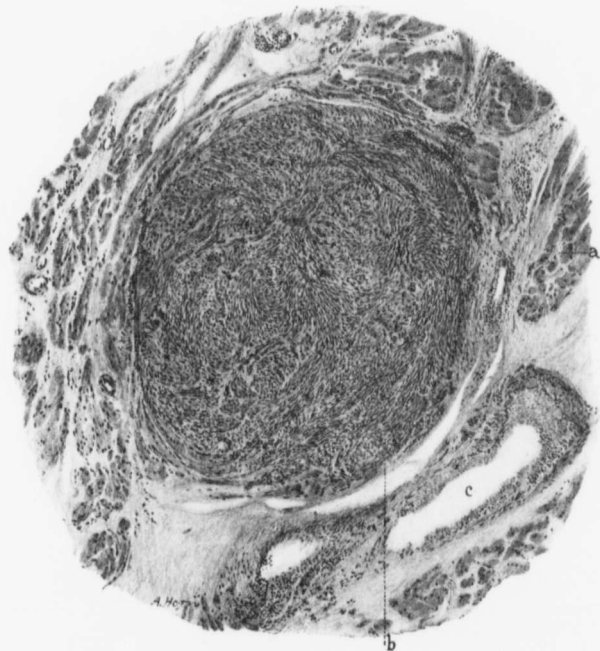

FIG. 286.—AN EARLY MYOMA. (X 60 diam.)

Gyn. No. 2434. Path. No. 186. In this case Cesarean section followed by hysterectomy was done at term on account of a large pelvic myoma.

An early spheric myoma occupies the center of the field. It consists of closely packed muscle-bundles cut lengthwise and transversely. It is sharply defined from the surrounding muscle. The muscle-fibers of the uterus (a) are swollen as a result of the pregnancy. At b the myoma is separated from the muscle by a definite cleft. c is a blood-vessel.

We still know practically nothing as to the origin of uterine myomata.

CHAPTER XXV.

THE SYMPTOMS ASSOCIATED WITH UTERINE MYOMATA.

In this chapter the clinical phenomena occurring in our cases have been carefully analyzed, but a complete survey of the literature has not been attempted.

Age.—In 1307 of our cases we have definite data as to the age of the patient on admission to the hospital. Of course, this is no index as to the length of time the tumors had existed.

The greater number had been developing for several years, but had not been detected until they had reached goodly proportions.

From the table it will be noted that the youngest patient (Gyn. No. 9637) was only nineteen years of age, and that 26 patients were under twenty-five years. The oldest patient coming for operation was seventy-one. In our experience the great preponderance of the cases came to operation between twenty-eight and fifty-two years of age.

TABULATION OF AGES OF 1307 CASES OF UTERINE MYOMA ON ADMISSION TO THE HOSPITAL.

AGE (IN YEARS)	NUMBER OF CASES.	AGE (IN YEARS)	NUMBER OF CASES.
19.....	1	46.....	52
20.....	3	47.....	34
22.....	2	48.....	43
23.....	6	49.....	33
24.....	14	50.....	34
25.....	12	51.....	20
26.....	14	52.....	21
27.....	15	53.....	10
28.....	28	54.....	15
29.....	28	55.....	4
30.....	31	56.....	11
31.....	21	57.....	4
32.....	47	58.....	4
33.....	46	59.....	8
34.....	50	60.....	4
35.....	61	61.....	3
36.....	62	62.....	1
37.....	47	63.....	1
38.....	77	64.....	2
39.....	65	65.....	2
40.....	93	66.....	1
41.....	49	67.....	1
42.....	53	68.....	0
43.....	60	69.....	0
44.....	50	70.....	1
45.....	62	71.....	1
Total.....			1307

In Case 9637 the patient, a mulatto, was only nineteen years old. She had married early, had had one child and one miscarriage. On admission to the hospital a small myoma, 2.5 cm. in diameter, was removed from the right uterine horn.

In Case 12216, a colored woman, twenty years old, married, entered complaining of abdominal pain. At operation a multinodular uterus, 12 x 12 cm., was found, and a subperitoneal pedunculated myoma, 8 x 8 x 10 cm. This was adherent to the anterior abdominal wall and had suppurated (Fig. 104, p. 136).

In Case 9652, a white woman, also twenty years old, had a myomatous uterus about 11 cm. in diameter, and reaching to the umbilicus. In Case 4382 the patient, a white woman, was twenty years old. She had married early and had had one child. For one month there had been profuse uterine hemorrhages. At operation a submucous myoma, about 6 x 7 cm., was removed.

In Gyn. No. 2042 the patient, a white woman, was twenty-two years old. The uterus was the size of that of a five months' pregnancy, owing to the presence of a large interstitial nodule in the posterior wall. This was removed, and fourteen years later the patient was in good health and had had four children since the operation.

In Case 11927 the colored patient was twenty-two years old. She had had a child at eighteen. On pelvic examination the appendages were found adherent, and what appeared to be a myomatous mass, 7 cm. in diameter, was situated to one side of the cervix. As the patient developed measles she was transferred to the medical side and no operation was performed.

We have sketched the histories of those cases in which uterine myomata were recognized at an early age in order that the reader may get an idea as to the size and location of the tumors. It will be noted that several of the patients were colored. In these cases there is always an element of uncertainty as to the correct age. Such a mistake is, however, less likely to occur in the young colored women than in the old. In the case of a white woman there is less room for doubting the accuracy of the patient's statement as to her age.

From the findings at operation it is evident that some of the tumors had existed for several years prior to operation. Accordingly, in a few of the cases the patient's uterus must have been the seat of myomata when she was still in her teens.

Duration of Uterine Myomata before Operation.—It is very difficult to determine with any degree of accuracy just how long it has taken a given tumor to develop, unless, perchance, at a previous abdominal operation a small nodule has been discovered in the uterus, but for some reason has not been enucleated. Patients frequently consult the surgeon for some ill-defined abdominal discomfort, while they are totally unaware that the pelvis is filled with a nodular myomatous uterus. On the other hand, if a patient is thin, and the myoma springs from the fundus, it is often felt by the woman herself. In some cases the tumor is detected and then cannot be found for some months, as in Case 3974. This

is due to an alteration in the position of the uterus. When once the patient is under the physician's care, the data as to the gradual or rapid increase in the tumor's dimensions become more accurate.

In C. H. L. B., April 28, 1904, we have a good example of the gradual increase in size of the myomata, the uterus having reached half-way to the umbilicus at the end of five years.

Many patients give a history of an abdominal tumor of several years' standing. Some develop gradually, and later increase rapidly in size; others grow with great rapidity when first noticed, and then later become quiescent.

In Case 694 the tumor had apparently entirely filled the abdomen by the end of one year; in Case 1628 the growth had trebled in size in twelve months.

In Case 1682 the tumor had apparently been increasing in size for twenty-seven months, but during the three months before the patient's admission apparently had been quiescent.

In Cases 1664, 2800, 3449, the increase in size had been marked during the few weeks or months previous to operation.

Many of the patients gave a history indicating that the uterine enlargement had commenced from one to ten or more years before surgical intervention was sought, and in a few cases the tumor had existed for a period varying from ten to thirty or more years. For example, in Cases 2899 and 3426 the tumor had been recognized twelve years; in Cases 3340, 3440, and 3774, fourteen years; in Cases 4617 and 12864, fifteen years; in Cases 3281, 3394, and 5946, twenty years before.

Examples of long-standing tumors are furnished by the three following cases: In Case 7460 the tumor had been recognized twenty-two years before; in San. No. 1049, for over thirty years; and in Case 10969, for thirty-six years.

San. No. 1049 is particularly interesting, as in this case an exploratory operation had been performed thirty years before. The surgeon pronounced the case inoperable, and said that the tumor sat right down flat on the womb, without even a particle of a pedicle.

When the tumor reaches very large proportions, it usually remains quiescent unless a malignant process is developing, but in C. H. L. McA., the tumor had existed for over twenty years, and had kept on increasing in size until it had reached a weight of 89 pounds.

The Abdominal Contour.—The general abdominal outlines, when uterine myomata exist, are dependent upon several factors:

1. The location of the tumor.
2. Its size.
3. The abundance or sparsity of the adipose tissue. A tumor may completely fill the pelvis and yet not project into the general cavity; in such a case the contour of the abdomen is little altered.

When the myoma emerges into the abdomen, the general symmetric lines are changed. The shape of the abdomen will depend upon the size and location of

the tumor. If it be unimodular and globular, there may be a dome-like elevation, as in Fig. 287, where the tumor stands out sharply on all sides. In some cases, for example, Case 7220, the abdomen may be "obliquely" distended, the tumor occupying the entire right upper half and the lower left portion.

When the abdomen is uniformly distended by a myomatous tumor, as in Fig. 316 (p. 513), and the ribs are pushed far outward, the appearance strongly suggests the presence of an ovarian cyst.

In those cases in which parasitic myomata are present and ascitic fluid has been poured out, the flanks also are distended, and the abdominal contour bears a marked resemblance to that found in cases of fibroma of the ovary with ascitic fluid or a malignant ovarian tumor with free abdominal fluid.

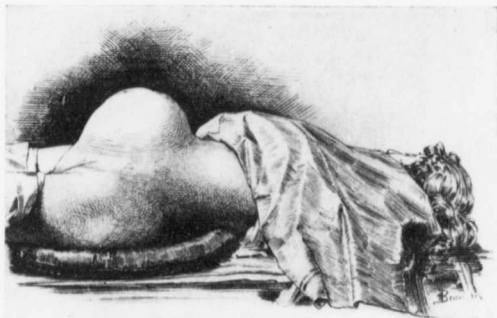


FIG. 287.—THE ABDOMINAL CONTOUR CAUSED BY A GLOBULAR MYOMATOUS UTERUS.

The patient is stouter than in Fig. 288. The tumor produces a dome-like elevation. The ascent from the symphysis to the umbilicus is gradual; the descent from the umbilicus toward the xiphoid more abrupt. There is no sagging in the flank. The only other abdominal tumor likely to give such a contour would be an ovarian cyst. In the latter case percussion would, in most instances, yield fluctuation. (After Howard A. Kelly.)

In some cases from the abdominal contour it is difficult to get a clear idea of the condition, but in others a glance at the abdomen will warrant the diagnosis of a myomatous condition. Such an abdomen is pictured in Fig. 288. The growth is clearly multinodular, has "precipitous edges," as was noted in Gyn. No. 9057, and there is no bulging in the flanks. When the patient is very thin, as in this case, the outlines of the tumor are much more in evidence. A thick mantle of adipose tissue, as found in so many cases, naturally obscures the sharp outlines of the tumor.

Enlargement of the Abdominal Veins Associated with Uterine Myomata.—Dilated veins are frequently noted when ovarian cysts or malignant ovarian tumors exist. If, in addition to the ovarian growth, ascites is found, marked enlargement of the veins may be looked for.

On the other hand, an increase in the size of the abdominal veins, associated with myomata, is rare. The venous dilatation, when present, is due chiefly to an interference with the usual avenues of circulation, and the myoma, as a rule, does not exert much pressure on the abdominal vessels. In a few cases, however, the abdominal veins are enlarged. This was noted in Case 3113; the myomatous uterus extended above the umbilicus, and was densely adherent; the abdominal veins were distended.

The Condition of the Vagina in Cases of Uterine Myomata.—Some of the patho-

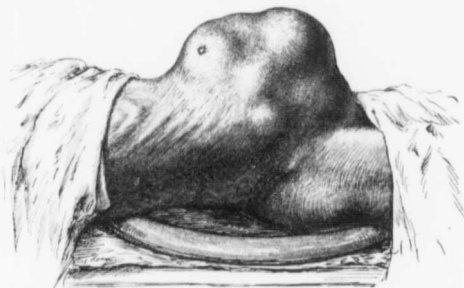


FIG. 288.—THE ABDOMINAL CONTOUR CAUSED BY A MULTINODULAR MYOMATOUS UTERUS.

GYN. No. 13626. The patient is very thin, the outlines of the ribs being quite prominent. The tumor rises abruptly from the abdomen, is markedly lobulated, and there is no sagging in the flank. In this case the clue furnished by the abdominal contour alone would almost warrant a definite diagnosis of myoma.

logic conditions found are dependent upon the myomatous condition, but the majority, as will be noted, must be considered merely coincidental.

1. Labial cyst.
2. Shallow vagina.
3. Bluish mucosa.
4. Vaginal cyst.
5. Vaginal myoma.
6. Vaginal phleboliths.
7. Ulceration of the vagina.
8. Induration of the vaginal vault.

Labial Cyst.—Only one labial cyst has come under our observation. In Case 12681 the uterus was the seat of a diffuse adenomyoma. Lying in the left labial fold, and nearly on a level with the clitoris, was a cyst 2 cm. in diameter. It was firmly attached to the skin, but was freely movable on the underlying structures. Projecting into the cyst cavity was a pedunculated papillomatous mass made up of smaller masses.

Path. No. 9473. Microscopically, the papillomatous masses are seen to be

covered with one layer of cylindric epithelium which, in places, tends to form glands. There is nothing suggestive of malignancy.

Alterations in the Size and Shape of the Vagina.—If a submucous myoma is expelled, the vagina must needs dilate sufficiently to accommodate the tumor, which is sometimes large enough to almost completely fill the pelvis.

A large intraligamentary or submucous myoma wedged in the pelvis may render the vagina so shallow that the finger cannot be carried over 1 or 2 cm. straight inward, but in such cases it can be introduced backward toward Douglas' sac or forward toward the bladder. C. H. I. No. 1205 affords an example of complete occlusion of the upper part of the vagina. This patient was forty-two years old and single. The myomatous uterus extended as high as the umbilicus. The vagina was greatly narrowed, and half-way up there was complete occlusion. With the finger it was possible to separate the vaginal walls from one another, and the cervix was then encountered.

With the advent of old age the vagina naturally contracts considerably. In Case 12681 the contraction was very marked. This patient, although the mother of eight children, had a vagina that would not admit two fingers.

The Bluish Color of the Vaginal Mucosa.—The vaginal mucosa usually takes on a bluish tinge in pregnancy. The same color is often presented when the patient is under the influence of nitrous oxid gas, or if the ether or chloroform has been pushed too far. In the unanesthetised patient this blueness always suggests pregnancy.

In Case 7361 the myomatous uterus reached almost to the umbilicus; the outlet was markedly relaxed, and there was slight protrusion of the anterior and posterior vaginal walls. The mucosa of the anterior wall was bluish in color. When pregnancy exists, the bluish tinge is found over all parts of the vaginal mucosa, and is not limited to a certain area, as in this case.

In Case 8008, a negress, married, aged forty-one, had a myomatous uterus that filled the pelvis. There was marked blueness of the vaginal mucosa. In this case there was also a pelvic abscess which was possibly responsible for the bluish color, although, as a rule, a pelvic abscess does not cause such a discoloration of the mucosa.

Vaginal Cysts.—The association of vaginal cysts with uterine myomata is merely a coincidence. In Case 5846 a small cyst was detected in the posterior vaginal wall, close to a sear in the sulcus.

In Case 6855 a cyst, 3 x 1.4 cm., was found in the left lateral wall, just within the hymen.

The cyst in Case 8844 was 2.5 cm. x 1.5 cm., ovoid in shape, and situated in the anterior vaginal wall under the urethra.

All these cases were reported in detail in the Johns Hopkins Hospital Bulletin for 1905.*

* Thomas S. Cullen, Vaginal Cysts, J. H. Hosp. Bull., 1905, vol. xvi, p. 207.

A Vaginal Myoma.—Myomata in this situation are rare, and we have only found one case in which a vaginal myoma was associated with uterine myomata.

In Case 1558 the uterus contained numerous myomata, and wide-spread sarcomatous metastases were detected in the mesenteric and peripancreatic lymph-glands, in the peritoneum, omentum, mesentery, intestine, stomach, liver, lungs, and pleura. The original source of the sarcoma could not be detected.

Situated in the posterior vaginal wall, and loosely embedded in the tissue, was a myoma 2 x 4 cm. This was shelled out with ease.

Phleboliths in the Vaginal Wall.—In Case 7600 the uterus contained several small myomata. Situated in the left vaginal wall were several phleboliths. The uterus was cureted and the phleboliths were readily dissected out. The presence of "vein stones" in the vagina is exceptional, as evidenced by the fact that we detected the condition only once in between 1400 and 1500 cases.

Ulceration of the Vagina.—In Case 12036 a small flat myoma was removed from the posterior surface of the uterus near the cervix. Histologic examination of this (Path. No. 8579) showed that it was a typical subperitoneal adenomyoma. Several interstitial myomata were also shelled out. A right inguinal hernia was then repaired.

Situated in the posterior vaginal vault, two inches from the outlet, was a granulating area, 8 mm. in diameter. As the vaginal ulcer was not excised, but treated locally, we cannot be sure of its exact nature. The Fallopian tubes were normal.

Induration of the Vaginal Vault Associated with Uterine Myomata.—This condition can usually be easily differentiated from myomata projecting into the vagina. Where myomata encroach on the vagina, the mucosa covering them is perfectly smooth, stretched, and gives the sensation of being relatively thin. Where there is marked induration, the sharply curved outlines are lost, and the vault has a dense, board-like feel; and where abscess formation is far advanced, there may be areas of softening or fluctuation scattered throughout the board-like tissue. The differences are analogous to the contrast between the sharply outlined picture presented by a fibroma of the skin and the hard, brawny, and rather indistinct contour of a boil.

A reference to Chapter XVIII (p. 337) will show that inflammation of the tubes is a very common accompaniment of uterine myomata, and that the inflammation not infrequently goes on to abscess formation.

The Condition of the Cervix as Detected by Digital Examination.

1. Normal cervix. (a) In the usual position. (b) Carried up.
2. Cervix almost obliterated or flush with the vaginal vault.
3. Cervix jammed down on the perineum or up behind the symphysis.
4. Eilema.

5. Elongation and hypertrophy of the vaginal portion of the cervix.
6. Dilatation of the cervix caused by submucous myomata.
7. Carcinoma of the cervix.

Normal Cervix.—The shape and position of the cervix will to a great extent depend on the size and situation of the myomata. If the myoma has developed in such a manner that the uterus is not encroached upon, the cervix will usually be of the normal size and in its proper place; but when the uterus is uniformly enlarged, it gradually rises into the abdomen and carries the cervix up with it.

Again, when many myomata are growing at the same time, the uterus is occasionally found completely surrounded by the tumor. In such cases also it may be carried high into the abdomen, and the cervix can with difficulty be palpated by the finger in the vagina.

Cervix Almost Obliterated.—When the myomatous development has been particularly pronounced in the cervical region, the cervix may be encroached upon to such an extent that it is almost completely unfolded, the edges merging almost imperceptibly into the vaginal walls (Fig. 40, p. 57).

In Case 6198 the cervix was flush with the vaginal vault. In Case 3493 it was almost obliterated, and in Case 8106 represented by a small pit. The encroachment of the myoma on the cervix in Case 4370 was so pronounced that the "cervix shaded off into a large abdominal mass wedged tightly in the pelvis."

Cervix Jammed Down on the Perineum or up Behind the Symphysis.—When, as a result of adhesions or of subperitoneal development, the upward course of the myomatous growth is interfered with, the tumor pushes its way downward. In such cases the vagina may be greatly shortened; the cervix may press down upon the perineum or be carried upward and forward, and be jammed against the symphysis. In such cases it may be difficult to reach with the examining finger, and can be recognized as a slightly altered cervix, a half-moon-shaped slit (as in Case 5141), or as a mere button (Case 4731).

Edema of the Cervical Lips.—In Case 1610 the uterus was partially inverted as a result of the traction of a submucous myoma, and the cervical lips were edematous.

Elongation of the Vaginal Portion of the Cervix.—In four cases we have records of marked hypertrophy of the cervix associated with uterine myomata. In Case 5843 there was prolapsus, elongation of the cervix, and a small adherent myomatous uterus.

In Case 4441 the adherent myomatous uterus measured 6 x 9 x 11 cm. There was prolapsus of the uterus and hypertrophic elongation of the cervix, with slight cervical ulceration.

In Case 7441 the patient, although married eight years, had never been pregnant. The vaginal portion of the cervix was 7.5 cm. in length, and protruded 3.5 cm. from the vulva. The uterus contained a myoma about 7 cm. in diameter.

The most remarkable hypertrophy of the cervix we have ever encountered was in Case 6240. There was marked prolapsus and enlargement of the cervix; the body of the uterus was correspondingly enlarged as a result of a diffuse adenomyoma.*

It will be seen that in each of these cases there was prolapsus of the uterus, and further that the myomatous condition was apparently in no way responsible for the hypertrophy of the cervix.

Dilatation of the cervix due to submucous myomata is described on p. 61; carcinoma of the cervix associated with uterine myomata on p. 262.

A Thrill Felt on Vaginal Examination.—In C. H. I. W. (Path. No. 6421) a large globular myomatous uterus was present. A definite thrill was felt along the course of the left uterine artery. The same sensation was transmitted to the finger each time a vaginal examination was made.

Elongation of the Supravaginal Portion of the Cervix Associated with Uterine Myomata.—In Case 12599 the uterus was considerably thickened, owing to the presence of a diffuse adenomyoma. The cervix was lengthened to such an extent that a total hysterectomy would have been exceedingly difficult. As soon as malignancy was excluded, the uterus was amputated through the cervix.

The uterus in Case 11944 was several times the natural size, being 15 cm. in diameter. The cervix, which was 10 cm. long, was at first mistaken for a senile uterus.

Excessive elongation of the cervix is illustrated in Fig. 289. Here the fundus is occupied by an irregular globular myomatous tumor, while the cervix is drawn out until it is as long as a normal uterus.

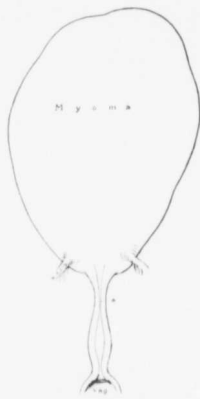

FIG. 289.—MARKED ELONGATION OF THE SUPRAVAGINAL PORTION OF THE CERVIX.

Aut. No. 1689. The fundus of the uterus is greatly enlarged and rather irregular in outline, owing to the presence of myomata. Passing off from the lower and anterior surface of the uterus are the round ligaments. The cervix is greatly lengthened out, extending from the external os to a, where it is much attenuated.

It is in just such a case as this that torsion of the cervix might be expected.

deals with the general distribution of uterine myomata, and to Chapter XVII, in which the condition of the uterine mucosa in myoma cases is dealt with in detail.

Uterine discharges are naturally divisible into two main groups:

1. Menstrual. 2. Intermenstrual.

* This case is reported in detail in "Adenomyoma of the Uterus," and the condition is illustrated in Fig. 56 (p. 201) of that publication.

MENSTRUATION.—In the vast majority of cases the menstrual function is in no way influenced by the presence of myomata, and the flow may even be diminished. In carefully tabulating the cases in which the menstrual flow was excessive, and often associated with an intermenstrual discharge, we have been struck by the great regularity with which the myomata were of the submucous variety. In the more pronounced cases these submucous tumors were recognized before operation; in other cases only after the uterus had been opened.

After carefully weighing the clinical and pathologic findings, we have not the slightest hesitancy in saying that in nearly every case the uterine bleeding is due to the encroachment of one or more myomata on the uterine mucosa. The mucosa is put on tension, there is an increased blood-pressure, and the large veins, which naturally once a month pour out their quota of menstrual blood, are now likely to yield a moderate quantity between periods and an excessive amount during the period. No matter how large the myomatous uterus, provided the contour of the uterine cavity is unaltered and the mucosa in no way impinged upon by the myomata, there will rarely be any disturbance in the menstrual function.

If it is possible to exclude the presence of uterine polypi, which frequently cause hemorrhage, of diffuse adenomyomata, which are associated with profuse menstruation but little or no intermenstrual bleeding, and adenocarcinoma,* which occasionally accompanies uterine myomata, one can say with almost absolute certainty that the uterine hemorrhage which occurs in association with the myomatous uterus is due to a tumor of the submucous variety.

Menstrual History.—In these cases the patient usually gives the history of a gradual increase in the loss of blood at the periods. In some, menorrhagia has been noticed for only a few months, and in others for ten years or more. The length of time usually varies inversely with the rapidity with which the myoma has become submucous and with which the uterus has expelled it into the vagina. The increase in amount may be so unexpected or sudden that the flow really amounts to a hemorrhage, as happened in Case 2709½. It may be continuous or come in gushes, as was noted in Case 3154. In some instances it is so excessive and persistent that the patient has to remain in bed to prevent flooding, and even this precaution may not stay the bleeding. For example, in Case 11944 the hemorrhage was so excessive that it became necessary to pack the uterine cavity. Any increase in blood pressure may bring on a hemorrhage.

Where bleeding was free, little pain was experienced, but if the blood came away in clots, or if it was temporarily dammed back, the discomfort was usually severe.

When the myomata do not impinge on the uterine mucosa, the menopause will usually occur at the normal time, but if at a later date the myomata become submucous, bleeding is likely to occur.

* Of course, in such a case as No. 1691, in which the submucous myoma was associated with adenocarcinoma of the body, a satisfactory deduction could not be drawn. This case is reported in detail on p. 288.

Intermenstrual Bleeding.—In some cases the periods are so long that the intermenstrual interval is very short or almost wanting. In other cases there is a continuous slight hemorrhage, or oozing of blood, and the periods are recognized as exacerbations of the flow. In some of the cases this continuous flow had existed for a few months, in others it had been present for three or four years.

When the intermenstrual period is of some duration, there is liable to be a leukorrheal discharge. This is whitish or yellowish in color, and is often bloodtinged just before and after the period. In some cases the discharge is watery and may be irritating.

If the submucous myoma is undergoing disintegration, the discharge tends to be more profuse, and at times is fetid. This watery discharge associated with some of the submucous myomata is almost nauseating, and cannot be distinguished from that accompanying a far-advanced carcinoma of the cervix.

Pruritus Vulvæ.—This distressing symptom is rarely caused by uterine myomata, even those of the sloughing submucous variety. In only one of our cases was it in any way pronounced. In Case 2606 the patient entered the hospital complaining chiefly of pruritus vulvæ. The external genitals showed excoriations and a few raw areas. The uterus contained a myoma, 11 cm. in diameter. A hysterectomy was performed, and the patient was at once completely relieved of the pruritus. The itching in this case was undoubtedly due to the irritating discharge. The myoma was of the submucous variety, but on histologic examination the mucosa covering it, aside from some thinning out, appeared perfectly normal.

Bleeding into the Abdominal Cavity after Bimanual Examination of Subperitoneal Pedunculated Myomata.—The surgeon is often impressed by the ease with which a subperitoneal pedunculated myoma can be torn away from the uterus. When severance takes place, there is naturally free hemorrhage. This tendency for the myoma to tear away should always be borne in mind when making a bimanual examination.

Some years ago one of us (Cullen) was demonstrating a case of multinodular uterus, and several students examined the patient. The abdomen was opened about ten minutes later for removal of the uterus. One of the examining group had evidently used too much force, as a subperitoneal nodule, about 10 cm. in diameter, had been partially torn away from the uterus, and even in a few minutes several hundred cubic centimeters of blood had escaped into the abdomen. In this case the outcome was perfectly satisfactory, but if this examination had been made in a private house and not just prior to operation, the hemorrhage might have proved fatal.

In Chapter II it has been pointed out that, when parasitic myomata exist, large free vessels plunge into the tumor. In such cases also the bimanual examination must be made most gently.

Mobility.—In estimating the mobility of the tumor in any given case the

variety of myoma with which we are dealing must naturally be taken into consideration. If the myoma is submucous, the degree of mobility will depend upon that of the uterus. When the myoma is large, the round ligaments are pulled taut, and only a limited excursus of the uterus is possible. If the tumor is interstitial and not very large, less traction will be exerted on the ligaments and the uterus will be more movable. Subperitoneal nodules, if pedunculated, can often be pushed from one side of the abdomen to the other, and in thin individuals can sometimes be lifted up in the hands.

When the patient has had children, the broad ligaments and the vagina are naturally more lax, and the degree of mobility is consequently greater than in the nullipara.

The following cases exemplify the marked degree of mobility that may exist in some instances. In Case 2005, in which the multinodular uterus extended to the umbilicus, the patient noticed that the tumor changed its position with any alteration of her own. Case 9953 was that of a very intelligent physician, thirty-two years of age. The uterus was hard and nodular, and on pelvic examination was found to extend half-way to the umbilicus. She noticed that the tumor moved about the abdomen; in the morning it would be well up toward the umbilicus, but after she had walked about for some time it settled more into the pelvis. A myomectomy was performed, and the patient, writing from India five years later, reported herself as feeling perfectly well. In Case 10555, a subperitoneal tumor, 10 cm. in diameter, sprang from the posterior surface of the uterus. The enlarged uterus "could be displaced to any part of the abdomen"; in fact, so mobile was it that it was thought to be an ovarian cyst.

When pelvic adhesions exist, the mobility of the uterus is usually much restricted.

A bimanual examination with the patient anesthetized often proves of the greatest assistance to the surgeon. He at once learns the relative degree of mobility of the tumor, and can determine with some accuracy whether the operation will be easy or difficult. The discovery of a large cervical myoma that has unfolded the cervical canal, or a pelvis packed with myomata and a marked narrowing of the vagina, usually indicates that enucleation will prove difficult. On the other hand, when, with the finger in the vagina and the hand over the abdomen, one is able to lift the entire mass well up into the abdomen, the pelvic portion of the operation, at least, is likely to be easy. Occasionally, however, even with dense pelvic adhesions, the pelvic contents can be moved upward and downward *en masse*.

Constipation.—Constipation is frequently associated with uterine myomata. Many of the patients give a history of constipation dating from a few months to two or three years prior to their admission to the hospital, although before that time the bowels had been regular. Other patients have been constipated for many years, but during the last six months or a year the constipation has

been more obstinate. In Case 6381 the patient at times went for two weeks without a movement.

In many instances the myomata are the direct cause of the constipation. Patients frequently complain of severe pressure in the rectum (Case 4959), or that the constipation is due to something coming down when they go to stool.

Myomata of moderate size that accurately fill the pelvis often exert a very firm pressure on the rectum, and more frequently cause constipation than do the larger tumors, which, on account of their size, are carried up out of the pelvis.

When the tumors not only fill the pelvis, but are also firmly fixed by adhesions, the tendency to constipation is naturally increased.

With the shifting of the tumor in the pelvis or its outgrowth from the confines of the pelvis and extension to the general abdominal cavity the existing constipation may cease. In Case 6441 the patient had been constipated until four months before her admission. This change is to be explained by the fact that the tumor altered its relations, which allowed the bowels again to become regular.

In some cases constipation is evidently due to partial intestinal obstruction. In Case 12811 the bowels were prone to be constipated, "especially when the tumor swelled," the swelling evidently indicating distention of the bowel due to its inability to empty itself.

Hemorrhoids.—Constipation is frequently associated with uterine myomata, the sluggish bowel action in large measure being due to pressure of the tumor upon the rectum. This obstructive condition naturally retards the return flow in the rectal veins, and might favor the development of hemorrhoids. Nevertheless, only rarely are these associated with myomata.

When a cervical myoma is fixed in the pelvis, as in Case 11243, hemorrhoids are almost certain to develop. If the myoma that has previously caused dilatation of the rectal veins alters its position, the hemorrhoids may disappear, as was noted in Case 6376, in which they vanished one year before the patient's admission to the hospital.

If hemorrhoids are present at the time a hysterectomy is performed, but are of a relatively mild grade, nature will usually take care of them, and they will disappear spontaneously after the obstruction is removed. If, however, they are of an aggravated type, removal at once is the wiser procedure, provided the patient is in good condition after the abdominal operation.

Painful Defecation.—This is usually associated with constipation, and may be intermittent or accompany each stool. When hemorrhoids exist, the cause of the pain is clear. In most cases it seems to be due to the pressure of the tumor on the rectum, and any pelvic adhesions that may be present are apt to aggravate the discomfort. We have noted a certain constancy with which frequent and painful micturition and painful defecation occur together.

Pruritus Ani.—The occurrence of this symptom with uterine myomata appears to be most unusual, as only one patient in our entire series complained

of it. In Case 8462 the patient, aged forty-one, for two years prior to admission had noticed a persistent and annoying itching in and around the anal orifice. So severe was it that her hands were tied each night to prevent her scratching the parts.

On visual examination nothing could be detected. Pelvic examination revealed a multinodular myomatous uterus (Fig. 318, p. 516). Thirteen myomata were enucleated. The pruritus ceased immediately after operation and never returned. Over six and one-half years have now elapsed since the operation. In this case the pressure of the enlarged uterus was evidently responsible for the pruritus.

Nausea and Vomiting.—As is well known, in the early months of pregnancy, when the uterus is undergoing a gradual dilatation, nausea and vomiting are not infrequent, and since the rapid development of myomata sometimes greatly alters the shape and size of the uterus, a certain amount of reflex nausea and vomiting might be expected. In only two of our cases, however, was there a history of nausea.

In Case 4203 the uterus was about the size of that of a three months' pregnancy and free from adhesions. The patient suffered from nausea and back-ache, more pronounced at the menstrual period. In Case 1787 the uterus filled the lower abdomen and the patient complained of irregular attacks of nausea and vomiting.

On the whole, then, myomata have little or no tendency to cause nausea or vomiting. Of course, when the small bowel becomes densely adherent to the enlarged uterus, kinking may follow and vomiting may occur as a result of intestinal obstruction.

Partial Intestinal Obstruction Prior to Operation.—In view of the numerous cases in which intestinal adhesions are present (see p. 633) it is hardly a matter of surprise to find that in a certain proportion partial intestinal obstruction has existed prior to operation.

In Case 6521, a negress, aged forty-three, had had definite signs of partial obstruction before coming to the hospital. At operation the adherent myomatous uterus, an ovarian cyst, and an adherent appendix were removed. The intestines were greatly distended and everywhere adherent. The patient was exceedingly weak before operation. The intestinal obstruction increased after operation and she died on the eighth day.

In Case 8698 a white woman, aged thirty-eight, had noticed a certain degree of obstruction of the bowels for two years. At operation several myomata were removed. There were no intestinal adhesions. The obstruction had probably been due to pressure of the myomatous uterus on the bowel.

In Case 12216, a negress, aged twenty, four months before admission had partial obstruction. The abdomen was swollen for three or four weeks. She had some vomiting, and experienced difficulty in securing a movement. At operation a loop of small bowel was found adherent to the anterior abdominal

wall at the point at which a suppurating subperitoneal myoma had become adherent. The patient died of intestinal obstruction a few days after operation. This case is reported in detail on p. 135.

In Case 12000 the woman entered the hospital as an emergency patient on account of acute intestinal obstruction. It was thought that the pressure of the myomatous uterus, which was firmly wedged in the pelvis, had caused the obstruction. At operation the narrowing of the bowel was found to be due to a coexisting carcinoma of the sigmoid (Fig. 274, p. 393).

Pain.—In the majority of cases of uterine myomata little or no pain is experienced by the patient.

When the tumor is adherent, the adhesions naturally often give rise to a good deal of distress, but at the present time we are chiefly interested in those cases in which the discomfort is due mainly to the tumor itself.

Our histories go to show that tumors of moderate size cause the most pain. Sometimes very small myomata located in the pelvis give rise to a good deal of discomfort, but very large ones are forced into the general abdominal cavity and cause relatively little pain.

A patient will often consult her physician without any idea that she has a tumor, although complaining of a heavy weight in the lower abdomen, as in Case 4526; or she may be suffering from a severe bearing-down sensation in the lower abdomen after exertion. In Case 337 the patient experienced much abdominal pain on stooping over. Other patients suffer from a constant soreness in the lower abdomen, as was noted in Case 9013. Others have paroxysmal pain in the lower abdomen, or a sharp pain may radiate throughout the entire abdomen, as in Case 1151. Coitus may cause pain, as was noted in Case 2772.

Pain referable to uterine myomata may be divided into two classes:

1. Pain in the uterus itself.
2. Pain as a result of pressure on the surrounding pelvic structures.

Pain in the Uterus Itself.—The uterine pain may be intermittent or continuous, and is usually most severe at, or just before, the menstrual period.

In Case 4972 the uterus was exquisitely tender, and in Cases 4975 and 6133 it was painful at or near the menstrual period.

Labor-like pains were experienced in Cases 1551, 1966, 2052, 3066, 3111, 4168, 5289. In Case 5289 they occurred when the hemorrhage was severe. In Case 4168 the patient said that when the pains came on she felt "just as if the child's head was about to be born."

Pressure Pains.—In addition to an ill-defined abdominal discomfort and general abdominal pain, we may find many definite pressure symptoms. Pain in the back and hips is frequent. Where there is much pressure, there is liable to be localized pain, as in Cases 2158 and 2838, in which the patients experienced severe pain in the region of the left thigh and hip. The pain may be dull and boring in character, as in Case 5014, or sharp and lancinating.

Continued pressure on the pelvic nerves causes discomfort in one and sometimes in both legs. For example, in Case 4016 there were cramp-like pains in the legs and feet; in Case 13016 there was aching in both legs. In Case 9924 the pain in the right leg was so severe that the patient at times was forced to remain in bed.

The pain in the leg and foot has been mistaken for rheumatism, as in Case 8943.

In other cases the pressure interferes with the sensation of the extremities. Thus in Case 3583 the patient complained of numbness in the right leg; in case 8266 in the outer side of the left leg, and in Case 1329 in both legs. In Case 694 the pressure was so severe that there was loss of sensation in the left leg.

Only in rare instances does the pressure of the tumor become excessive, but in Case 3199 the pelvic pain was so severe that the patient was compelled to give up work and remain in bed for eleven days, and in Case 1212 the patient was confined to her bed for five months.

In Case 3338 the paroxysms of pain were so severe that the patient had convulsive attacks, and in Cases 3353 and 4828 there was loss of consciousness also.

The effects of pressure on the bladder and on the rectum will be discussed under Micturition and Defecation.

In only one instance (Case 12369) was there pain in the breasts.

Condition of the Breasts in Cases of Uterine Myoma.—In the vast majority of cases the breasts show no change, and the myomata seem to have little or no influence on these organs.

The following changes have been noted:

1. Colostrum in the breasts.
2. Small benign breast nodules.
3. Carcinoma of the breasts.

Colostrum in the Breasts.—In two of our cases the breasts contained fluid, apparently colostrum.

In Case 11392 a negress, aged thirty-four, had been married three years but had never been pregnant. The myomatous uterus was the size of that of a seven months' pregnancy; the cervix was hard. The breasts were hard, but contained colostrum.

In Case 12154, a negress aged thirty-seven, although married several years, had never been pregnant. A multinodular myomatous uterus reached 4 cm. above the umbilicus. The cervix was very soft and displaced downward and backward. The breasts contained colostrum.

We are at a loss to account for the colostrum, as in neither case did pregnancy exist. The diagnosis between a uniformly enlarged and soft myomatous uterus and pregnancy is often difficult, and the presence of colostrum in the breasts is strong presumptive evidence of pregnancy. Nevertheless, in rare instances colostrum may be present when no pregnancy exists.

Small Benign Breast Tumors.—In Case 1558 a small, semi-fluctuant, and apparently benign tumor was found in the left breast. The uterus contained numerous myomata, and there was sarcoma of the peripancreatic lymph-glands (Aut. No. 353). No operation was performed on account of the debilitated condition of the patient.

In Case 1637 there was a small myomatous uterus and a large ovarian cyst showing irregular carcinomatous changes. The patient had had a small tumor in one breast for twenty years.

Carcinoma of the Breast.—In Case 3426 the patient entered the hospital with a sloughing submucous myoma. This was removed, but the patient died on the seventh day. Autopsy showed that death was due to rupture of a preëxisting pus-tube. Eighteen months prior to her admission one breast had been removed for carcinoma.

In Case C. H. I. No. 78 the patient entered the hospital on account of the pressure symptoms produced by a pelvic tumor which proved to be a myoma undergoing sarcomatous transformation (p. 184).

She also had carcinoma of one breast, but refused to have it removed. Four years later she returned with inoperable growths in both breasts.

Carcinoma of the breast must be looked upon as an accidental accompaniment of uterine myomata, the one being in no way responsible for the other.

Effect of the Tumor on Respiration.—With the increase in the size of the tumor the patient often notices that her clothes are getting tight. Later, the tumor may interfere with walking, and when the myomatous uterus almost fills the abdomen, the abdominal organs so impinge on the diaphragm that the lungs are partially compressed and the patient complains of shortness of breath.*

In Case C. H. I. McA., in which the myoma weighed more than the patient (Fig. 316, p. 513), it was impossible for her to lie on her back. If by chance she got over on her back, she had at once to call for assistance on account of almost complete suffocation. When the interference with breathing is due to the tumor, respiration becomes normal as soon as the growth is removed.

The shortness of breath may also be due to the excessively low hemoglobin, caused by great loss of blood from the myomatous uterus. (See p. 453.)

Edema of the Lower Extremities.—In 45 cases edema was noted. Sometimes it involved one foot or ankle, and in severe cases the knee; in other cases both legs were swollen. The edema appeared to be due chiefly to the following factors:

1. Pressure exerted by the tumor upon the pelvic veins.
2. A low hemoglobin percentage, with a weak heart's action.
3. Renal insufficiency.

Pressure.—When the edema of the legs was due to pressure by the tumor upon the pelvic veins, the swelling was sometimes unilateral; in other cases both legs were involved. In Case 8542 the edema was confined to the right

*Shortness of breath was noted in Cases 121, 659, 1672, 1862, 2073, 2713, 2822, 3111, 4314, 4828, 5617, 5987, 6418, 9786, and 9915.

leg. In Case 4599, at first the right leg alone was edematous, but with the increase in size of the tumor the swelling came to involve both legs. In Cases 8368, 9138, 9928, and 11944 the edema was limited to the left leg.

Myomata often move about to a limited extent, and as a consequence the pressure upon the pelvic veins may be temporarily or permanently relieved, and the edema disappear. In one case edema of the ankles had been noted seven years before the patient's admission, but with the increase in the growth of the tumor the edema had disappeared permanently.

In Cases 6441 and 10199 the edema also completely disappeared with the alteration in position of the tumor.

The relief of the pelvic veins from pressure may be intermittent—hence the occasional edema noted in Cases 1685 and 3444.

A Low Hemoglobin Percentage.—Submucous myomata often cause alarming uterine hemorrhages, and as a result the percentage of hemoglobin rapidly diminishes. In Case 12234 the hemoglobin was 25 per cent.; in Case 9678, 23 per cent.; in Case 9707, 22 per cent.; in Case 9786, 20 per cent., and in Case 9593, 10 per cent. With a very low hemoglobin the heart muscle cannot receive the necessary nourishment, and a more or less marked grade of cardiac dilatation, with edema in the extremities, is the natural consequence. That the cardiac murmurs due to the dilatation are merely functional is clearly shown by the rapid recovery of patients after the removal of the cause of the hemorrhage. Thus, in the absence of organic cardiac disease, after a few weeks the change in the patient is marvelous, and in the course of a month or two the cardiac area becomes normal in extent, the heart's action regular, and all the murmurs vanish. In Cases 6017, 9593, 9678, and 12154, in addition to a low hemoglobin percentage, there were definite cardiac symptoms.

When the edema is the result of a lack of hemoglobin, both legs are usually enlarged.

Renal Insufficiency.—In three of our cases the edema was apparently attributable to renal insufficiency. In Case 1383½ the urine contained albumin, but no casts were detected. Edema was present, and the abdominal cavity contained over 14,000 c.c. of ascitic fluid.

In Case 2713 the abdominal walls were edematous, and the urine contained hyaline and epithelial casts.

In Case 0 (Hebrew Hospital, July 14, 1902) the patient's legs for several days had been greatly swollen and had turned purple. The urine contained quantities of albumin and was loaded with casts.

The Condition of the Heart.—Much has been said about the various cardiac changes that are due to or associated with uterine myomata, and a great deal of confusion exists as to the rôle played by myomata in the development of heart lesions.

In 92 of our cases we have data indicating impaired cardiac action.

Variety of Cardiac Sounds.—The abnormal cardiac sounds

have been manifold and varied. In Case 7859, for instance, a soft systolic murmur could be heard over the entire precordial area. In Case 7688 the first sound over the entire heart had a rather snapping, hollow, tympanitic quality. In Case 13039 a soft, blowing murmur was heard all over the base of the heart. The murmur was very intense in the second left intercostal space, and was probably diastolic. A diastolic rumble was noted in Case 7240. Soft, systolic, pulmonic murmurs were noted in Cases 6722, 7266, and 7295, and a loud, systolic, pulmonic murmur in Case 9769.

Systolic murmurs at the base were also found in Cases 6843, 7630, 12165, 12234, 12293, and 12964.

Reduplication of the first sound over the pulmonic area was detected in Case 7216, and at the apex in Case 7014.

In Case 13025 the heart was enlarged, no thrill could be detected, but there was a prolonged, blowing, systolic murmur at the apex.

We have cited a few cases to demonstrate the great variety in the character and location of the heart-murmurs.

In the majority of the cases, however, an apical systolic murmur was all that could be detected. This murmur was usually very soft in character. In some it was limited to the apex, but in others could be traced to the axilla, and in some patients to the base of the heart.

In a few cases the murmur was harsh. In Case 8495 the prominent systolic murmur at the apex was associated with a goiter. This patient complained of palpitation and shortness of breath.

In Case C. H. I. 392 and Gyn. No. 7569 presystolic murmurs were present at the apex.

Cause of Murmurs.—Among the first writers to mention the association of myomata and cardiac lesions were Hofmeier* and Fehling.†

In many of the cases studied by them there was cardiac dilatation, especially of the right auricle, while the heart muscle showed brown atrophy and fatty degeneration.

On referring to the chapter on Autopsies (p. 394), it will be seen that in two of our cases myocarditis was present, but that in neither of them was it clear that the myoma had been the causative factor. Our clinical material, however, sheds much light on the subject. In nearly all the cases in which cardiac lesions were present the patient gave a history of menorrhagia, often associated with intermenstrual bleeding. These patients, as a rule, stood the anesthetic and the operation well, and in a comparatively short time they had gained much in strength, and their cardiac murmurs had disappeared. Some authorities claim that the myoma in itself brings about cardiac changes. If such were the

* "Zur Lehre vom Shock," *Zeitsch. f. Geb.*, 1885, xi, 8. 366.

† "Beiträge zur operativen Behandlung d. Uterusmyome," *Württemberg. med. Correspondenzbl.*, 1887.

case, then the larger the myoma, the more pronounced should be the cardiac murmurs. This has not been our experience. The largest tumors have not been associated with any cardiac symptoms, but the heart complications have almost invariably been associated with copious bleeding from the uterus.

Most of the murmurs noted in our cases were, at the time, considered to be functional. With the continued loss of blood the patient's vitality is lowered, and the amount of hemoglobin materially decreased. The coronary vessels accordingly furnish the heart muscle with an inferior quality of blood, and, as a result, the heart is not able properly to cope with the situation, and there is, in consequence, a slight dilatation of the chamber, causing the murmurs. After operation there is naturally no more hemorrhage. A relatively normal percentage of hemoglobin is soon reached, and the heart muscle once more receives a healthy blood-supply. The heart contracts to its normal size, and the hemic or functional murmurs disappear.

Our experience coincides with the view expressed by Leopold,* that the cardiac changes are usually functional and are a direct result of the anemia caused by the uterine hemorrhage.

There are, of course, a certain number of cardiac lesions that are in no way caused by myomata. These still persist after operation.

In Cases 7569 and 13039 the previous history of "acute rheumatic fever" was given, and in Case 6272 the cardiac lesion was associated with nephritis and ascites. In Case 5010 there was a chronic pericarditis. This patient was in a precarious condition on entering the hospital. An attempt was made to build her up, but she grew rapidly worse. Operation was undertaken as a last resort, but the patient died on the table.

In only a few cases has a cardiac lesion been so severe that operation could not be undertaken with safety.

A Low Hemoglobin Percentage Associated with Uterine Myomata.—In the accompanying table we have given 22 cases in which the hemoglobin was 40 per cent. or less at the time of admission to the hospital. The loss of hemoglobin in nearly all the cases is due directly to the frequent and often continuous uterine hemorrhages caused by the myomata.

MYOMA CASES SHOWING A VERY LOW PERCENTAGE OF HEMOGLOBIN.

GYN. NO.	HEMOGLOBIN.	PRESENCE OF SUBMUCOUS MYOMATA.	OPERATION.	RESULT.	REMARKS.
2744.	39 per cent.	Multiple myomata. Adenomyoma.	Hysterectomy.	Recovery.	
3066.	24 "	Submucous.	Vaginal myomec-tomy.	Recovery.	
6615.	30 "		Hysterectomy.	Recovery.	
7438.	19 "	Submucous.	Hysterectomy.	Recovery.	

* Archiv f. Gyn., 1890, Bd. xxxviii, S. 1.

MYOMA CASES SHOWING A VERY LOW PERCENTAGE OF HEMOGLOBIN.—(Continued.)

GYN. NO.	HEMOGLOBIN.	PRESENCE OF SUBMUCOUS MYOMATA.	OPERATION.	RESULT.	REMARKS.
7615.....	39 per cent.	Submucous.	Vaginal myomec- tomy.	Recovery.	
8804.....	20 "	Submucous, fever for two weeks; later clotted blood in uterine cavity.	Evacuation of uterine con- tents.	Died eigh- teen hours later.	In desperate condition when brought to hospital.
8936.) ..	15 "				
9203.) ..	Returned with hemoglobin 46 per cent.	Submucous.	Hysterectomy.	Recovery.	
8951.....	35 per cent.		Hysterectomy.	Recovery.	
9593.....	10 per cent.; after iron and arsenic, 21 per cent.	Submucous.	Hysterectomy.	Recovery.	Hemoglobin 48 per cent. on discharge.
9678.....	23 per cent.	Submucous.	Hysterectomy. Evacuation of tubo-ovarian abscess.	Recovery.	
9707.....	22 "	Submucous.	Hysterectomy.	Recovery.	Hemoglobin 45 per cent. on discharge.
9786.....	20 per cent. on admission; before opera- tion, 43 per cent.	Submucous.	Hysterectomy.	Recovery.	Hemoglobin 52 per cent. on discharge.
10172.....	20 per cent.; tonics, rest in bed; 44 per cent. before operation.	Submucous.	Hysterectomy.	Recovery.	Hemoglobin 53 per cent. on discharge.
11139.....	28 per cent.		Hysterectomy.	Recovery.	
11337.....	12 per cent. Severe bleed- ing from need- le-prick.	—	No operation.	Died in ten days.	
11889.....	14 per cent. Delirium; temperature 104°; respira- tions, 40; seemed mori- bund.	Submucous, in- fected.	Partial removal of submucous tumor.	Recovery.	
12234.....	25 per cent.	Multinodular, al- so submucous.	Hysterectomy.	Recovery.	
12890.....	25 "	Submucous.	Hysterectomy.	Recovery.	Hemoglobin 55 per cent. on discharge.
San. 1837	30 "	Interstitial.	Hysterectomy.	Died on fifth day. Par- alysis of small bow- el.	
San. 1868	30 "	Multinodular, al- so submucous.	Hysterectomy.	Recovery.	
San. 1944	40 "	Adenomyoma.	Hysterectomy.	Recovery.	
Path. 6421	30 "	Submucous, sar- comatous de- generation.	Hysterectomy.	Recovery; well for two years.	

One cannot safely rely on the patient's general appearance for an index of the anemia. For example, in C. H. I. 728 the patient was very thin, pale, anemic, and apparently had a hemoglobin of approximately 40 per cent. Tests, however, showed it to be 79 per cent.

In 14 of the tabulated cases the hemoglobin (taken with the Dare instrument), on admission to the hospital, was under 30 per cent., and in 4 of this number 15 per cent. or under. For example, in Case 8936 it was 15 per cent.; in 11889, 14 per cent.; in 11337, 12 per cent., and in 9593, only 10 per cent.

Dr. Henry T. Hutchins, formerly Resident Gynecologist in the Johns Hopkins Hospital, has gone very carefully into the subject of the "Clinical Effects of Surgical Anesthesia and Operation upon Anemic Patients,"* and by his tabulation has shown clearly how by rest, fresh air, and careful nourishment, supplemented by Bland's pills, Fowler's solution, tincture of nux vomica, etc., the patient's hemoglobin may be much increased in the course of a few weeks or months.

In Case 9593, although the hemoglobin on admission was only 10 per cent., by the above methods it was increased to 21 per cent. before operation. Similarly, in Case 8936 it was increased from 15 per cent. to 46 per cent., in Case 9786, from 20 per cent. to 43 per cent., and in Case 10172, from 29 per cent. to 44 per cent.

All such patients need especial care on the part of the surgeon. Some enter the hospital just after a period which has been exhausting, and an operation would be fraught with great danger. With the appropriate treatment there is a steady increase in the hemoglobin, but if the operation is too long delayed, the next period may be so excessive that the patient may be even weaker than when admitted to the hospital.

In some cases immediate operation often affords the only chance for saving the patient's life. In Case 11889, for example, reported in full on p. 577, the patient entered the hospital almost moribund. There was marked delirium, a temperature of 104.2° F., with a pulse of 140 and respirations of 40. The hemoglobin was 14 per cent., and the heart showed marked signs of insufficiency. She was stimulated for a few hours, and the necrotic and offensive portions of a submucous myoma were then removed. Two years later the patient wrote: "My health is better than ever." This case demonstrates what brilliant results may occasionally be obtained even under most adverse circumstances.

In Case 11337 we have an example of the profound anemia that sometimes results when an intact or sloughing submucous myoma is present. Six months before the patient's admission uterine hemorrhages had commenced and had been almost continuous, and for the last three months she had been forced to remain in bed. On admission the mucous membranes were very pale, the hemoglobin was 12 per cent., and the red corpuscles were 1,828,000; there were functional cardiac murmurs and a temperature of 102° F. When blood was drawn from the ear for making the blood count, the needle-prick bled so profusely that a

* Henry T. Hutchins, *J. H. H. Bull.*, 1904, vol. xv, p. 339.

compress had to be applied, and even adrenalin did not stop the flow. Operation was impossible, and the patient died on the fourth day. Autopsy revealed fatty degeneration of the heart and other organs, focal necroses in the liver, and a healed infarct of the spleen.

In Case 8804 for nearly four years the patient had had frequent uterine hemorrhages, and for three weeks prior to admission continuous bleeding. Since that time she had grown progressively weaker, and for the last two weeks had had fever. On admission she looked desperately ill, the respirations were shallow, and there was a blowing systolic murmur over the apex; hemoglobin, 20 per cent. The abdomen was greatly distended by the myomatous uterus. The uterine discharge was so offensive and free that under light anesthesia the cavity was irrigated, and about a liter of foul clots brought away. Toward evening the pulse became weaker and weaker, and the respirations shallow and labored. Death soon followed.

In San. No. 1837 the patient had a mitral systolic murmur, a hemoglobin of 30 per cent., and a temperature of 100° F. A simple abdominal hysterectomy was performed. The patient did not do well from the first, and died on the fifth day. At autopsy the intestines were much distended, but there was no evidence of infection. For some unaccountable reason there had evidently been a paralysis of the bowels.

From the above it will be seen that, as a rule, the simple lowering of the amount of the hemoglobin in itself need not deter the surgeon, especially as by operation he is going to completely remove the cause of the hemorrhage, which, if it persists, may speedily cause a fatal issue. When infection is associated with a very low hemoglobin, the outlook is very gloomy.

Loss of Weight.—The presence of myomata, as a rule, has little or no influence on the general appearance. Some patients are very thin because they have always been of a frail build. Others are very stout and have been so for years. Still others put on flesh while the tumor is developing.

A few patients give a history of a gradual or rapid loss of weight in the few months or years prior to applying for treatment. For example, in Case 9593 the patient said she was losing weight and growing weak. In Case 4903 there had been a loss of 15 pounds in weight in the previous four months, and in Case 4877, of thirty-five pounds in two years. An inquiry into the history of such cases will almost invariably show that the loss of weight has been due to the excessive uterine bleeding, and that the hemorrhage has been caused by one or more submucous myomata. The loss of weight in Case 7158 was due to a sloughing submucous myoma, and in Case 9078, in which the patient had lost 30 pounds in six months, it was found that a suppurating subperitoneal myoma had opened into the cecum. With the removal of the tumor the patient's health was again restored to the normal.

When sarcoma or carcinoma is associated with the myoma, it is only natural that the vitality should be rapidly undermined.

Profound Weakness.—When there is great weakness associated with uterine myomata, it may be assumed that either a submucous myoma is giving rise to profuse uterine bleeding, or that some other independent process is sapping the patient's vitality. In Cases 1879, 2902, and 3437 the patients complained of excessive weakness, and in Cases 4285, 9786, and 10618, in addition to the weakness there were fainting spells. These were especially prone to occur at or just after the excessive period.

In Case 9707 the menorrhagia was so profuse that the hemoglobin was reduced to 22 per cent., and the patient had blurred vision following the periods.

In all the cases in which we found such marked lowering of the vitality the asthenia was due to excessive bleeding.

The loss of blood may be so marked that the patient suffers from air-hunger, as was noted in Case 9786. In a few of the cases the patient, on account of the continuous foul discharge and of the continuous dribbling, may become bed-ridden. Such a condition existed in Case 11013, and the patient had taken large quantities of morphin.

Temperature.—Uncomplicated myomata are rarely accompanied by any rise in temperature. When fever exists, it is usually due to absorption from a necrotic submucous myoma or a suppurating myoma, to an infection from an accompanying accumulation involving the adnexa, or to some complicating intercurrent affection.

The Fertility of Women Who Develop Uterine Myomata.—In 1149 cases we have definite data as to marriage and pregnancy. Of this number, 757 were white women and 392 colored.

Number married, 842:	{ White.....530
	{ Colored.....312
Number single, 307:	{ White.....227
	{ Colored..... 80

All but five of the married patients were married before they were forty years of age.

Out of the total number of cases—

584 were sterile.
75 had had miscarriages, but no full-term labor.
490 had had children.

Total.....1149

Sterile Patients.—Of these, 295 were married (187 white; 108 colored); 289 were single.

Length of married life of the 295 sterile patients:

Less than six months.....	5 cases
Six months to one year.....	10 "
One to five years.....	55 "
Six to ten years.....	70 "
Eleven to twenty years.....	94 "
Twenty years or over.....	43 "
Data not obtainable.....	18 "
	295 "

Miscarriages.—In addition to the 75 patients that had miscarried but had never been delivered of a full-term child there were 165 others that, besides going to term, had also miscarried, thus making a total of 240 patients who had had miscarriages.

Tabulation of the number of miscarriages per patient:

1 miscarriage	in each of	153 cases
2 miscarriages	" " "	51 "
3 "	" " "	15 "
4 "	" " "	8 "
5 "	" " "	6 "
6 or more miscarriages	" " "	6 "
Several miscarriages	" " "	1 case
		Total, 240 cases

In the great preponderance of the cases there was only one or at most two miscarriages, demonstrating that there was no decided tendency to abort, except in a few of the cases.

Tabulation of the approximate age of the fetus at the time of the miscarriage:

Miscarriages occurring during the first month	3
" " " " second "	41
" " " " third "	45
" " " " fourth "	18
" " " " fifth "	7
" " " " sixth "	11
" " " " seventh "	5
130	
In 110 cases the month was not given	110
240	

As seen from the tabulation, the greater number of miscarriages apparently occurred during the second and third months.

In order to study the effect of myomata on conception we have made a tabulation of the length of time between the miscarriage and the patient's entrance to the hospital for operation.

Miscarriages occurring within five months of the operation	13 cases
" " " six to eleven "	10 "
" " " one year before "	4 "
" " " two years "	10 "
" " " three " "	10 "
" " " four " "	9 "
" " " five to ten years before "	56 "
" " " eleven to twenty years before operation	59 "
" " " twenty years before operation	26 "
Data not given	43 "
240 "	

In only six of these was any cause assigned for the miscarriage. In three of these it was instrumentally induced, and in the remaining three was ascribed to a fall.

The table seems to indicate that, as the myoma increased in size, the tendency to conception lessened.

PATIENTS WHO HAD BORNE CHILDREN PREVIOUS TO OPERATION FOR
UTERINE MYOMATA.

TABLE OF THE NUMBER OF CHILDREN.

1 child	each in	184 cases
2 children	" "	104 "
3 "	" "	59 "
4 "	" "	51 "
5 "	" "	26 "
6 "	" "	15 "
More than 6	" "	51 "
			490 "

In only seven out of the 490 cases was a child born within a year prior to operation.

In Case 12725 the patient had had two children, one miscarriage, and an extra-uterine pregnancy.

The foregoing statistics are interesting in a general way, demonstrating that over half of all the patients had never been pregnant. After excluding the 307 who on account of their being single were of necessity sterile, we still have 277 out of a total number of 842 who were married and yet remained sterile. We have seen on p. 337 that in myoma cases the appendages are adherent in a large percentage of cases, and as this in itself would account for the sterility, we are still unable to say with any degree of certainty that the myoma *per se* was the direct cause of the sterility.

CHAPTER XXVI.

OTHER PATHOLOGIC CONDITIONS IN SOME OF OUR MYOMA CASES.

Goiter Associated with Uterine Myomata.—In one of our cases (No. 8306) there was a slight enlargement of the thyroid, and in five other cases* one or both sides of the thyroid showed a considerable increase in size. In only one case was there any definite sign of exophthalmos.

In four of the cases abdominal hysterectomy was performed, and in one case a sloughing submucous myoma was removed by the vagina.

In one case (No. 4801½) the patient had a large goiter on the right side. Hysterectomy was performed on account of the myomatous uterus, which filled the lower half of the abdomen. The pulse on the second day was 148; on the third day it ranged between 136 and 144, and on the fourth day between 118 and 132. A maximum temperature of 101° F. was noted on the third day.

In Case 8495 the patient had lost much blood from the vagina. She was anemic, had a slight protrusion of the eyeballs, palpitation of the heart, shortness of breath, and bilateral enlargement of the thyroid gland. A soft systolic murmur was heard at the apex. This replaced the first sound and was transmitted to the axilla. The lower abdomen was filled with a myomatous tumor.

On account of the patient's condition spinal anesthesia with cocain was attempted, but ether had to be resorted to. The hysterectomy was a simple one, but the patient on leaving the table had a very rapid pulse and shallow respiration. The pulse the same evening and the next day ranged between 180 and 200, and then gradually came down. Later a severe diarrhea appeared. Convalescence was considerably retarded, but the patient was discharged after four weeks in a better condition than before operation.

The acceleration of the pulse in both of these cases seems to have been in a large measure due to the goiter, but the final results were satisfactory.

Prolapsus of the Uterus Associated with Uterine Myomata.—It is but natural that prolapsus and myoma should be associated in a certain number of the cases.† The descensus may be slight, moderate, or complete. With the increase in size of the uterus the organ often is carried out of the pelvis into the abdomen, and as a consequence the prolapsus may disappear in part or completely unless there be marked elongation of the cervix. The prolapsus is usually associated with small myomatous uteri.

In Case 12452 there was an irreducible prolapsus. The cervix projected 6 cm.

*Gyn. No. 4801½, 8495, 10565, 12079, 12557.

†Prolapsus was noted in Cases 362, 1852, 3172, 4341, 4537, 5248, 6577, 9335, 11169, 12063, and 12452

from the vagina, and the pelvis was filled with a hard globular mass. At operation this mass was found to be densely adherent posteriorly, and irreducible.

Lipoma of the Abdominal Wall Associated with Uterine Myomata.—In Case 7460 the pelvis was filled with a myomatous uterus. The abdominal walls were so thin that the intestinal movements could be seen readily. In the left abdominal wall was a tumor which extended from the costal margin to the level of the umbilicus. It was 22 cm. long, 12 cm. broad, and on removal proved to be a lipoma.

The Condition of the Umbilicus in Cases of Uterine Myomata.—If the myomatous uterus does not reach above the pelvic brim, it should have little or no effect on the umbilicus. But when the tumor assumes large proportions, the abdominal wall is stretched, and its weakest point, namely, the umbilicus, is likely to yield.

Obliteration of the Umbilical Depression.—This condition was noted in Cases 362 and 659.

In Case 362 a subperitoneal myoma, 17 x 17 cm., was adherent to the abdominal wall, and also to the surrounding structures. It is probable that in this case the tugging of the abdominal adhesions had gradually unfolded the navel.

The abdomen in Case 659 was greatly distended by an inoperable cystic myoma. There was marked bulging in the flanks, and total effacement of the umbilical depression.

Retraction of the Umbilicus.—Only once in our series was this phenomenon noted. In Case 7549 the pelvis and lower two-thirds of the abdomen were occupied by a myomatous growth. The tumor was apparently freely movable, but on moving the patient from side to side the umbilicus would retract to the side to which the tumor moved. When the abdomen was opened, dense adhesions were encountered, and the upper part of the tumor had become infected and had opened into the transverse colon.

Umbilical Hernia.—Small umbilical hernia* are not infrequently associated with uterine myomata. The opening is usually small, sometimes just admitting the tip of a finger, but may reach large proportions, as in Cases 5123, 8354, and C. H. I. F.

As a rule, the hernial sac is not very sensitive, but if the omentum is incarcerated, manipulation will occasion considerable pain.

Occasionally the incarcerated omentum may become strangulated and undergo necrosis. In C. H. I. F., described on p. 120, and shown in Fig. 94, the abdomen was markedly distended by a large myomatous uterus. The umbilicus was the seat of a large hernial sac. The central portion of this was dark red, and the surrounding tissue very edematous.

When the abdominal wall is rather spare and the hernial ring not plugged with omentum, a finger can be carried through the opening and the surface of the myoma palpated over a considerable area. This procedure was carried out in Cases 5092 and 12155.

* Umbilical hernia was noted in Cases 1920, 4869, 5092, 5123 (Fig. 381, p. 640), 5946, 7330, 7460, 7508, 7583, 8270, 8354, 9457, 11006, 12155, 12696, and C. H. I. F. (Fig. 94, p. 120).

When an umbilical hernia complicates a myomatous uterus, it is well to begin the incision in the median line above the hernia. With the finger in the abdomen as a guide the entire hernial sac can be dissected out rapidly and without risk of cutting any incarcerated omentum. With the sac lying free it can be readily cut away from the omentum, and the hysterectomy completed in the usual manner.

A Small Cyst at the Umbilicus.—In Case 7688 the lower part of the abdomen was filled with a myomatous uterus. At the umbilicus was a small cyst which, at first sight, suggested an incarcerated hernia. As the specimen was lost we are, unfortunately, not able to give its histologic peculiarities.

Femoral Hernia Associated with Uterine Myomata.—In only three of our myoma cases have we records of a femoral hernia. In two it was on the left side, in one, on the right.

In Case 3416 the incarcerated myomatous uterus did not rise out of the pelvis. In Case 6129 the uterus reached almost to the umbilicus, and in Case 11984 the uterus was as large as that of a six months' pregnancy. It will thus be seen that in none of the cases was the uterus large enough to cause any great tension on the abdominal walls. The hernia in each case must be looked upon as an accidental accompaniment.

Inguinal Herniæ Associated with Uterine Myomata.—The accompanying table gives the records of 7 cases in which, in addition to uterine myomata, an inguinal hernia was found. In two it was on the right, in two on the left, and in three cases herniæ were present on both sides. In none of the cases did the myomata reach large proportions.

It is clearly evident that the association of the myomatous uterus and the hernia in each of these cases was purely accidental.

INGUINAL HERNIA ASSOCIATED WITH UTERINE MYOMATA.

GYN. NO.	MYOMATOUS UTERUS.	HERNIA.	OPERATION.
2763a.....	Size of that of a six months' pregnancy.	Left inguinal.	Abdominal hysteromyomectomy.
2772.....	Myoma, 6.5 x 5 x 4 cm.	Left inguinal.	Abdominal myomectomy; removal of appendages.
4967.....	Uterus adherent, globular, approximately 15 cm. in diameter.	Right and left inguinal.	Abdominal hysteromyomectomy, double herniotomy.
5871.....	Reached umbilicus.	Right and left, apparently inguinal.	Abdominal hysteromyomectomy.
9457.....	Small adenomyoma of uterus; large cyst of ovary, probably carcinomatous.	Right and left inguinal, also umbilical hernia.	Abdominal hysterectomy, also cystectomy; obliteration of hernia from within. Radical cure of umbilical hernia.
11067.....	Myoma, 11 cm.	Right inguinal.	Abdominal hysteromyomectomy; modified Bassini operation.
12036.....	Small uterus with several very small myomata.	Right inguinal.	Abdominal myomectomy; radical cure of hernia.

Strangulated Inguinal Hernia.—In Case 1852 there was complete eversion of the anterior vaginal wall; the fundus of the uterus was enlarged, and posterior to it was an ovoid myomatous mass, 6 x 7 cm. Vaginal hysterectomy was performed.

On the nineteenth day a radical operation for a strangulated inguinal hernia was performed.

A Myomatous Nodule Filling a Postoperative Hernial Sac.—One patient (Case 6628) entered the hospital giving a history of a previous exploratory abdominal operation. The entire lower abdomen was filled with a multinodular myomatous mass. The abdominal scar was 20 cm. long, and in one place reached 5 cm. in width. The walls had given way at some points, and there were several hernial protrusions in the scar. On excising the scar many omental adhesions were encountered, and one subperitoneal myoma was found to be extra-abdominal and occupying one of the hernial sacs.

Notwithstanding the universal adhesions, a successful hysterectomy was accomplished.

Cysts of the Urachus Associated with Uterine Myomata.—In two of our cases cysts of the urachus were encountered during operation for myomata. In Case 6722 the cyst was very small—only 3 mm. in diameter.

The bladder in Case 7295 reached 4 cm. above the symphysis. In this case also a small cyst of the urachus was found. It was situated just above the bladder.

Descensus of the transverse colon was found in Case 11251. This condition may occasionally be successfully overcome by looping up this portion of the bowel, but the chances for permanent relief are slight.

Appendicitis.—In the cases operated upon in the early nineties mention of the condition of the appendix was rare, but in recent years the appendix has been systematically examined in nearly all the cases.

The appendix was removed in at least 83 cases. In only one instance (Case 12369), was there an acute appendicitis. In three a subacute inflammation was noted.

In Case 2129 the appendix was adherent to the right tube. In Case 2806 it was adherent to the posterior surface of the uterus, and in Cases 9078 and 11392 it had grown fast to the myoma.

In several other cases the appendix had grown fast to the right appendages, where there was a tubo-ovarian cyst, a salpingitis, or a pelvic abscess.

In C. H. I. 793, in addition to the appendicitis there was a marked chronic colitis, limited chiefly to the transverse and descending colon.

The myomatous uterus does not seem in any way to predispose to the development of an appendicitis. In fact, it really looks as if an acute and well-defined appendicitis is a very rare occurrence when myomata exist.

The question the surgeon naturally asks himself is, "Shall I remove the appendix or not?" If little or no evidence of a definite inflammation is present,

our opinion is that, when myomectomy is performed, it is wiser not to remove the appendix, as despite all precautions the danger of infection in myomectomies is great.

When hysterectomy is performed, appendectomy is indicated if there is the slightest evidence of inflammation, and if the hysterectomy has been a simple one, even a normal appendix is better out. We have had at least one case (C. H. I., A.) in which, several years after hysterectomy, it became necessary to operate upon the patient for an acute appendicitis.

Tuberculous Peritonitis and Uterine Myomata.—The association of tuberculous peritonitis and uterine myomata has, in our experience, been rare. In Case 6991 the uterus contained several small myomata. It was densely adherent, and tubercles were widely disseminated throughout the abdominal cavity and also implicated the adnexa. The uterus with the appendages and the appendix were removed.

Findings in the Mesentery in Myoma Cases.—**Calcareous Nodules.**—In Case 7011, after removal of the multinodular myomatous uterus, a calcareous nodule, 2 x 2.5 x 3 cm., was carefully shelled out of the mesentery of the ileum, about 10 cm. from the ileocecal valve. Two similar but smaller ones were removed from the mesentery a short distance further on. The three openings were closed with catgut, great care being exercised to avoid injury to the blood-vessels.

An Abnormally Long Mesentery.—In Case 69 the woman died five days after the hysteromyomectomy. The mesentery of the ileum was very long. Volvulus had taken place, with the subsequent development of peritonitis.

Abnormal Conditions of the Liver and Gall-bladder.—**Thickening of the Left Lobe.**—In Case C. H. I., W. (Path. No. 6421), a secondary operation was performed on account of sarcoma in the cervical stump two years after the primary operation (Fig. 130, p. 191). We examined the liver to see if it contained metastases. The edge of the left lobe was sharp and clean cut, but the right lobe was thickened and had blunt edges. We at first thought we were dealing with hepatic metastases, but on inspection none were found.

Adhesions Between the Liver and the Tumor.—In Case 3440, in which the tumor weighed 30 pounds, a subperitoneal myoma was adherent to the abdominal walls, to the omentum, and to the suspensory ligament of the liver.

In Case C. H. I., McA., in which an 89-pound myoma was removed, the tumor was so intimately adherent to the liver that a piece of hepatic tissue came away with it.

Gall-bladder.—In Case 6432 the myomatous uterus filled the entire abdomen. The tumor was adherent to the omentum, mesocolon, to the hepatic flexure of the colon, and also to the gall-bladder.

In Cases 6792, 8514, 8667, and 8713, after removal of the myomatous uterus, the gall-bladder was opened on account of gall-stones.

Glycosuria.—In only two of our cases of uterine myomata was glycosuria noted prior to operation. In Case 12291 there was a multinodular myomatous uterus which reached 3 cm. above the umbilicus. On account of the large amount of sugar contained in the urine, operative interference was considered inadvisable.

In Case 2108 the patient had a multinodular myomatous uterus which extended almost to the costal margins. She had profuse uterine hemorrhages and suffered from constant pain in the right flank and down the right leg. The urine at first contained much sugar, but after the patient had been kept under observation for two and a half weeks the sugar disappeared completely. Three weeks later the abdomen was opened; the intestines were densely adherent to the uterus and to one another, and bled freely on liberation. The appendages were also inflamed and adherent. On account of the condition of the patient and the desperate chances attending a hysterectomy, the abdomen was closed. The patient made a satisfactory recovery.

Shortly after the operation the glycosuria reappeared, lasted several days, and then again disappeared. Had the symptoms been distressing and the uterus free from adhesions, we would certainly have removed it, inasmuch as patients suffering from diabetes often stand operations remarkably well.

Misplaced Kidneys in Cases of Uterine Myomata.—Prolapsus of the kidney is very common, and we should not be surprised to find it frequently associated with uterine myomata. When the myomata reach any considerable size, the abdominal capacity is naturally diminished, and there is not the same chance for a general enteroptosis; consequently in very few of our cases has prolapsus of the kidney been noted where the myomatous uterus has been large.

In Case 8197 the myomatous uterus was small and the lower pole of the right kidney reached to the level of the umbilicus.

The dislocation of the kidney in Case 891 was most marked, and naturally led to confusion on bimanual examination. The uterus was studded with small myomata, and what was supposed to be a pedunculated subperitoneal nodule was felt behind and to the right of the uterus. This supposed pedunculated myoma proved to be the right kidney, which lay within the pelvis, being entirely below the sacral promontory.

Nodules Studding the Left Kidney.—In Case 7438, a white woman, aged forty-three, had a myomatous uterus which filled the pelvis. After its removal the kidneys were examined. Both were much enlarged, and the left was studded with nodules varying from 2 to 5 mm. in diameter. They were confined chiefly to the lower half of the kidney. No enlarged lymph-glands could be found, nor was there any evidence of growths elsewhere in the abdominal cavity. Of course, no microscopic examination of the nodules could be made, and we

are in the dark as to their nature. The patient made a good recovery. Her hemoglobin at the time of operation was 19 per cent.

Renal Colic.—In only one case did a patient with uterine myomata give a history suggestive of renal colic. In Case 3113, the woman, aged fifty-two, had had what appeared to be definite symptoms of renal colic once or twice a year for twelve years before operation. She had violent pain, commencing in the left kidney and passing down the course of the ureter. No calculus was detected, but the urine at these times was tinged with blood. The wax-tipped catheter and the *x*-rays at that time had never been employed.

CHAPTER XXVII.

DIFFERENTIAL DIAGNOSIS.

To describe adequately the various pathologic conditions that might have to be differentiated from uterine myomata would necessitate a careful consideration of nearly every pelvic lesion that can occur in women, and many abdominal lesions would also require a detailed description. In the limited space at our disposal we shall merely describe those cases in which we have personally found difficulty in arriving at a correct diagnosis.

PREGNANCY

At times the differentiation between myoma and pregnancy is clinically almost impossible, and even after the abdomen has been opened, it is often difficult to decide whether the uterine enlargement is due to a myoma or pregnancy. The difficulty is especially apt to occur when the uterus is uniformly enlarged.

Menstruation.—In myoma cases the menstrual period is usually regular; for pregnancy, cessation of the period affords strong presumptive evidence. In some cases, however, the flow may be perfectly regular throughout the period of gestation.

Breasts.—In pregnancy the breasts afford signs that are characteristic and that are usually wanting in myoma cases. But, as noted on p. 449, the breasts in some instances are enlarged and contain fluid. In all these cases the possibility of a pregnancy with an associated myomatous condition must be remembered.

The Cervix.—The characteristic softness of the cervix in pregnancy is usually sufficient to establish the diagnosis, but in a few cases the cervix may be hard and firm, and lead one to infer that no pregnancy exists.

The flail-like manner in which the body of the uterus can be moved backward and forward on the cervix is most characteristic of pregnancy, but in rare instances this may be simulated in the case of a myomatous uterus when the cervix has been greatly lengthened out and attenuated (see p. 442).

Inspection of the Uterus.—Prior to opening the abdomen the operator has carefully considered all these possibilities, and yet on seeing the uterus its regularity may be so pronounced that he is still suspicious of pregnancy.* Where pregnancy exists, the uterus is usually of a bluish hue, due to the marked vascularity, and very different from the pinkish color usually seen in the myomatous uterus.

*In the following additional cases the myomatous uterus strongly suggested a pregnancy. Gyn. Nos. 1579, 4203, 5687, 7059, 7237 8247, and 9678.

In pregnancy also the vessels passing to and from the uterus are greatly enlarged and engorged.

When pregnancy exists, the insertions of the tubes and round ligaments bear their normal relations to the uterus. This may or may not be the case if the enlargement is due to a myoma.

Where the cervix is rather broad and hard and the tubes and round ligaments are inserted closer to the center than they would ordinarily be in cases of pregnancy (Fig. 290), myoma will usually be found. On the other hand, if the insertions be at the relatively normal site considering the size of the uterus, it may be necessary, as a last resort, to split the uterus to determine the cause of the

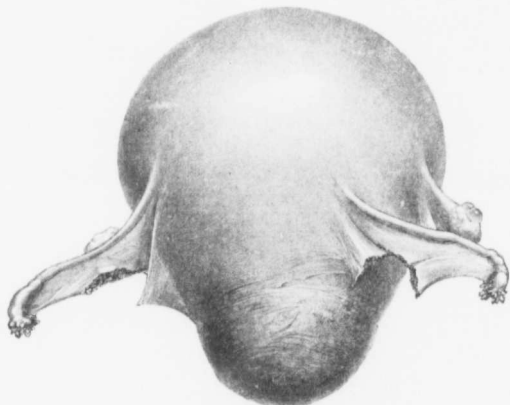


FIG. 290.—A MYOMATOUS UTERUS CLOSELY RESEMBLING A PREGNANT UTERUS IN ITS GENERAL CONTOUR.
($\frac{1}{2}$ nat. size.)

Although the uterus resembles a pregnant organ, the right tube and right round ligaments are inserted at a higher level than are the left tube and round ligament. On the other hand, the ovary is attached at a lower level than the ovary on the left. The enlargement was due to an interstitial myoma in the posterior wall. (After Howard A. Kelly.)

enlargement. This we did in several instances, and in each case found the myomatous tumor.

In Case S., C. H. I. (June 9, 1903), the uterus on inspection strongly suggested a four months' pregnancy, although the history in no way indicated it. On the one hand, we did not want to disturb a normal gestation, and, on the other hand, did not deem it fair to close the abdomen when another operation would in all probability be necessary a few weeks later. We accordingly carefully split the uterine wall and at once encountered a cystic myoma, 10 cm. in diameter. This projected slightly into the uterine cavity. A myomectomy was done and the uterus saved.

In Case M., C. H. I. (January 18, 1900), the uterus reached to the umbilicus and strongly resembled a pregnant organ, although there was no history suggestive of it. The uterus was carefully cut into, and the enlargement found to be due to a partially submucous myoma. The myoma was removed, but the organ left.

On several occasions when examining the enlarged uterus in the laboratory we have opened the organ with fear and trepidation that the operator had possibly removed a pregnant uterus. In each case, however, the softness was due to the fact that the myoma was edematous or had undergone cystic changes.

A MYOMATOUS UTERUS IN CONTOUR RESEMBLING A FETUS.

Occasionally, the myomata may be so arranged that they resemble a fetus. This was the case in Gyn. N^o. 3198. The clinical history in no way suggested pregnancy, neither did the uterus look like a pregnant organ, but in its general outlines the tumor bore a strong resemblance to a child (Fig. 291).

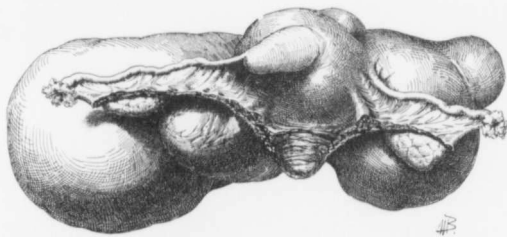


FIG. 291.—A MYOMATOUS UTERUS RESEMBLING A FETUS IN ITS CONTOUR.

Gyn. No. 3198. Path. No. 533. The greatly enlarged uterus measured 11 x 13 x 21 cm. The nodule just behind the left ovary might readily have been mistaken for the head on palpation, and the large one behind the right ovary for the buttocks. The appendages were normal. The right tube apparently emerges from a small myoma. (After Howard A. Kelly.)

The nodule to the left might readily be mistaken for the head, the one to the right for the buttocks, and the central portion, consisting of the uterus and several smaller nodules, for the trunk with the hands and feet.

DEFINITE BALLOTTEMENT WITH UTERINE MYOMATA.

This sign is most exceptional apart from pregnancy. In Case 3387, however, it was clearly made out. The uterus contained several myomata of goodly size, and attached to its surface were two pedunculated myomata, the larger 6 x 8 x 10 cm. One of the three nodules had four large omental vessels entering it (Fig. 24, p. 34), and the abdomen contained 7000 c.c. of ascitic fluid. Several of the nodules gave a distinct ballottement on bimanual palpation. This was undoubt-

edly due to the fact that they were pedunculated and floated easily in the ascitic fluid. The ballottement was the only sign that in any way suggested pregnancy.

DEATH OF FETUS WITH SUPPURATION; PERFORATION OF UTERINE WALLS; SUPRAVAGINAL HYSTERECTOMY; RECOVERY.*

This case demonstrated how nature, if left alone, may successfully ward off an attack of general peritonitis. Here there were suppuration in the uterine cavity, numerous perforations of the uterus,—fortunately situated entirely in the anterior wall,—and then a successful walling off by the abdominal wall becoming adherent to the uterus.

A. P., colored, aged twenty-one, was admitted to the Cambridge Hospital March 4, 1906. The patient had been thought to be pregnant one year before. She had been carefully watched for some time, but no further development had taken place. She had had some slight fever, but nothing more definite could be learned. When one of us (Cullen) examined her the cervix was soft; the uterus was globular, and lay half-way between the umbilicus and the xiphoid. The growth was apparently somewhat movable.

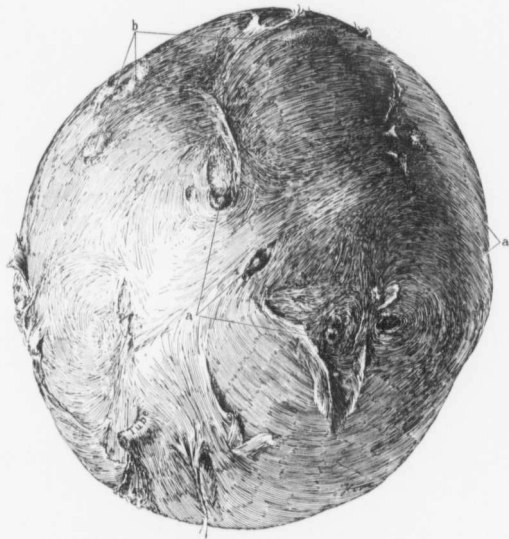
Operation: I made an incision over the growth and immediately came in contact with what looked like grumous material, which suggested a suppurating ovarian cyst. As the tissues were densely adherent, the incision was continued upward and the general peritoneal cavity opened. On loosening the other adhesions we found the omentum adherent. This was clamped and cut. The tumor was intimately blended with the thickened abdominal peritoneum. It was shelled out as rapidly as possible, but pus oozed from the surface in various directions (Fig. 292). I thought that I was dealing with an ovarian cyst, but was surprised to find that it was the enlarged and globular uterus. I amputated through the cervix. The tubes and ovaries were covered with a few slight adhesions, but were otherwise normal and were left behind. It was with the greatest difficulty that enough peritoneum was obtained to close the abdomen, as so many raw areas had been left where the uterus had been adherent to the abdominal wall. A gauze drain was introduced into the lower part of the incision. The patient improved rapidly, and left the hospital feeling perfectly well.

Description of the Uterus.—Path. No. 9810. The specimen consisted of an irregular and globular mass, approximately 18 x 17 x 15 cm. Its surface was everywhere covered with adhesions, and at numerous points were openings irregular in shape, and varying from 3 to 5 mm. or more in diameter. Through these openings quantities of pus welled out during the operation. The pedicle or cut surface was 4 cm. in breadth, 3 cm. across, and in the central portion of this was the cervical canal. On opening the specimen after it had been hardened we

*Thomas S. Cullen, A Series of Interesting Gynecologic and Obstetric Cases, Jour. A. M. A., May 4, 1907.

found that this tumor was the uterus (Fig. 293). The walls varied from 1.5 to 4 mm. in thickness.

Fetus.—Snugly filling the entire cavity was a fetus. Its length from elbow to axilla was 7 cm., from elbow to shoulder, 8 cm. Its breadth in the axillary line was 13 cm. Other measurements could not be made on account of the distortion of the child, but it appeared to be an eighth-month fetus. The skin was somewhat macerated. The child was evidently a mulatto, as in many places the



Dr. C. W. Clark

FIG. 292.—THE PERFORATED PREGNANT UTERUS AS SEEN ON REMOVAL.

Path. No. 9810. The surface is everywhere rough and covered with adhesions. In the lower part of the field is the stump of one tube. At a, a, are perforations of the uterus, whence pus was seen oozing out; at b, the walls are very thin; there have been many adhesions, and pus is lying on the surface. One would not for a moment take this to be the uterus, except for the presence of the tube. For the interior of the uterus see Fig. 293.

mottled appearance was still present. At other points, however, the outer skin had been rubbed off, and the surface had the pale appearance of a white child. The hair, which was matted up against the uterine wall, was curly and black and several centimeters in length.

Placenta.—The placenta occupied the lower quadrant of the uterus, and projected over the cervix; there had been a partial placenta previa. The placenta at the thickest portion was 2 cm. in thickness. Attached to the surface

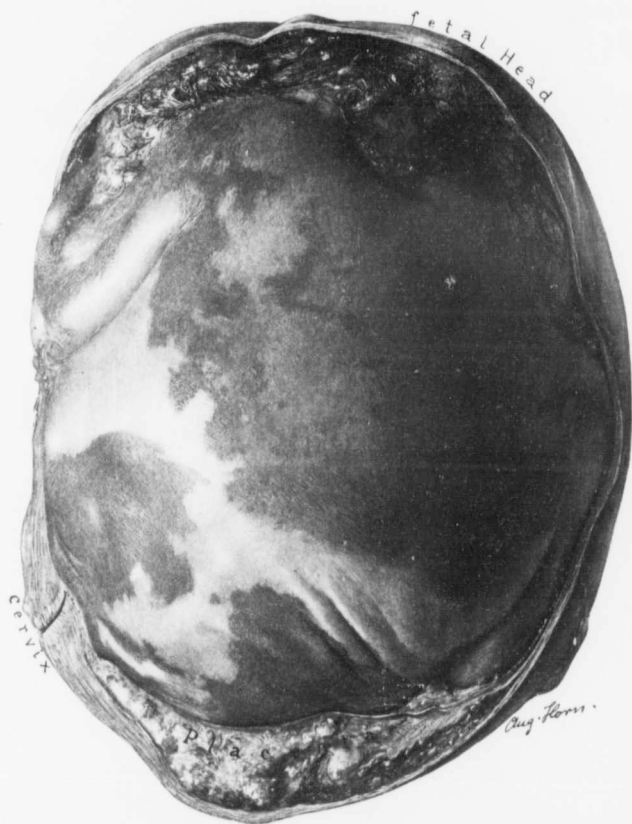

FIG. 293.—A PREGNANT UTERUS, WITH THE FETUS AND PLACENTA INTACT. (Nat. size.)

Path. No. 9810. For the exterior of the uterus see Fig. 292. After the uterus had been well hardened, the anterior surface was removed. The cervix presents the usual appearance, and the uterus is firmly contracted around the fetus. The head lies in the upper portion. The left arm is firmly adherent to the left side of the chest, and the skin is macerated to some extent. Situated in the lower part is the placenta, which extends slightly over the internal os.

of the child, especially in the vicinity of the hair, was much friable, yellowish material that looked very much like inspissated pus. It was from the surface of the uterus at the points of perforation that the purulent discharge came during the operation.

Sections from the uterine wall showed that the outer surface, at certain points, particularly where it was adherent to the abdominal wall, was covered with numerous adhesions. On the protected side cuboid cells were visible. The muscle in such areas showed a great deal of small-round-celled infiltration. The inner lining of the uterus was much altered. There were areas of canalized fibrin, and also regular ribbons of hyaline and canalized fibrin. Just beneath the surface, and on both sides of this, were numerous small round cells and polymorphonuclear leukocytes. At a few points calcified villi could be made out. Decidual cells were still in evidence, but they had become smaller. There had evidently been a chronic inflammation of the inner surface of the uterus, coupled with an inflammatory process on the outer surface at the points where the uterus was adherent to the abdominal wall.

In this case there had been death of the fetus from some unknown cause, and discharge or absorption of the liquor amnii. Suppuration had taken place in the uterine cavity. At some points the uterine walls had become perforated, and the pus had trickled out over the surface. Fortunately no intestines lay in the way, and the pus had glued the uterus to the anterior abdominal wall. This is certainly one of the rarest conditions met with in the literature.

A DEAD FETUS RESEMBLING A MYOMATOUS UTERUS.

Occasionally the patient may be totally unaware that she has been pregnant. If the fetus dies, the cervix becomes hard, the uterus contracts materially, and there is often a slight bloody discharge. In such cases, if no definite history is obtainable, myoma may be suspected. A feeling of malaise and chilly sensations, however, suggests a dead fetus, and dilatation and curettage will settle the diagnosis.

ABDOMINAL PREGNANCY AND UTERINE MYOMATA.*

In the following case there was a typical history of a pregnancy going on apparently to term. Labor pains developed and soon ceased, and the patient retained the tumor for nearly four years without any marked discomfort. Little credence was given to her statements, as it appeared doubtful if she knew exactly what had happened. On bimanual examination the diagnosis lay between a myomatous uterus and a dermoid cyst, and even when one of us removed the tumor, we thought that it was a dermoid cyst. It was only when the hardened specimen was opened in the laboratory that pregnancy was detected. A glance

*Thomas S. Cullen, A Series of Interesting Gynecologic and Obstetric Cases, Jour. A. M. A., May 4, 1907.

at the contour of the tumor, as seen in Fig. 294, will show that it closely simulated a myoma in its general outlines.

Gyn. No. 13272. Path. No. 10417.

Abdominal Pregnancy of Four Years' Duration.—J. A., colored, married, aged twenty-eight, was admitted to the Johns Hopkins Hospital September 27, 1906, complaining of pain and swelling in the abdomen.

Her general health had always been good, and she had never consulted a physician before. Her menstrual history was unimportant. She had been married fifteen years and had had four children, the eldest nearly fifteen years old. The second child was deficient mentally, but lived five years. The third was ten, and the youngest eight, years of age. Her labors had all been normal; there had never been any miscarriages. For some years she had had a slight amount of thick, white, foul-smelling discharge, more marked before and after her menstrual periods than at any other time. For several years she had been constipated, the bowels not moving for two or three days at a time. She had passed no blood or mucus.

Present illness: About four years ago she noticed a small lump, the size of a baseball, situated below and to the left of the umbilicus. The tumor increased in size at a uniform rate, and the patient thought she was pregnant. At the end of nine months the tumor reached above the umbilicus. The breasts were enlarged and contained colostrum. The patient had had no nausea or vomiting. Her menstrual periods had been regular, although she had had a very scanty flow. She was certain that she had felt movements of the child. About the time that labor should have come on she had bearing-down pains, beginning in the evening and lasting until early morning. The pains then ceased and never returned. The patient thinks that she has never had any other signs or symptoms since that night. The breasts gradually become soft and dried up. The tumor seemed to decrease slightly in size. No movements were felt, and the patient suffered no discomfort. She became convinced that she had a tumor.

Until about a year ago she could go about her work without difficulty, but then she noticed a little soreness, and the tumor "began bothering her." In the few months previous to admission she had felt an increase in the amount of soreness. She had had headaches at times, her tongue had been coated, she had frequently felt nauseated, but had not vomited. After walking a good deal there was a burning sensation in the lower part of the abdomen, and during the last two months the headaches had been quite severe. The patient had to stop work on account of the burning pain that would come and go, but was eased by lying down. She slept well, but her appetite was poor, and she said she did not gain in weight. There was no pain or burning on defecation or urination.

Examination.—Dr. Hutchins, the resident gynecologist, found the patient rather emaciated. The abdomen was distended rather more on the left than on

the right side by a tumor which rose from the pelvis and reached 4 cm. above the umbilicus in the median line. The tumor felt cystic; it was movable, dull everywhere on percussion, and no fluid wave was noted. On vaginal examination no evidence of infection could be found. The cervix was firm. There was slight bilateral laceration. The uterus was in ante-position, normal in size, and apparently in no way connected with the abdominal tumor. Movement of the tumor did not draw the cervix upward. Clinically, the tumor was thought to be an ovarian cyst or a myoma, but no definite diagnosis could be made.

Operation. One of us (Cullen), after making a long abdominal incision, found that the abdominal cavity was occupied by a large "tumor of the left ovary," to which were adherent the omentum, the entire transverse colon, a portion of the sigmoid, and the ascending colon. The uterus was densely adherent on the right side. The omentum was tied and cut, a portion being left attached to the tumor, the proximal portion being reflected backward with the transverse colon. In doing this the thin wall of the tumor was ruptured, and an ounce or two of thick, creamy, yellowish material escaped. This was rapidly sponged up, and further escape controlled by pressure with gauze. In order to avoid infection, as far as possible, the right tube, which had been converted into a pus sac and was adherent to the cystic tumor, was liberated. The broad ligament on the left side was clamped and cut, so that the tumor could be shelled out of the pelvis and tipped over to the left side. In this way the grumous contents of the cyst were prevented to a great extent from escaping into the abdominal cavity. After the tumor was shelled out there was a great deal of bleeding from the mesocolon. This was checked as far as possible by sutures, and the transverse colon was then curved in on itself, so that the mesocolon formed a funnel. A gauze drain was introduced into this as it dropped down on the pelvic brim and was brought out through the vagina. In this way we were able to check the bleeding almost completely. The abdomen was closed without drainage from above. The patient made a very satisfactory recovery and was discharged October 21, 1906.

Path. No. 10417. The specimen consists of an abdominal tumor which was connected with the left broad ligament and the left tube and ovary. It was absolutely free from the uterus, which was not removed. The specimen in the hardened state measures 24 cm. in length, 18 cm. in breadth, and 16 cm. in its anteroposterior diameter. Attached to its right side are a pus-tube and the right ovary. To its left are the tube and ovary, which are plastered down on it. Covering almost the entire upper surface of the tumor is omentum, which is densely adherent to the mass and furnishes a large part of its blood-supply. The walls of this tumor vary from the thickness of paper to two or three millimeters. From this tumor grumous material, like fat mixed with pus, escapes, and at several points hair can be seen. When a window is cut out (Fig. 294), the interior is found to be filled with a fetus, which is of at least seven or eight months' growth. On account of the distorted condition it is difficult to get the exact age,

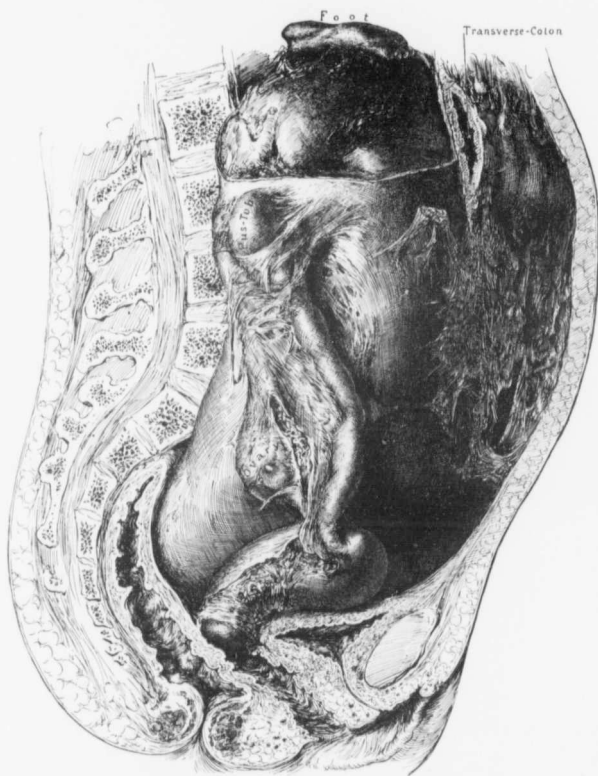

FIG. 294.—ABDOMINAL PREGNANCY OF FOUR YEARS' DURATION.

Gyn. No. 13272. Path. No. 10417. The illustration is an exact reproduction of the abdominal contents, and has been drawn from the specimen. Attached to its right side is a large pus-tube, which is densely adherent to the sac. On the left side the structures are not clearly outlined, as the broad ligament was intimately attached to the sac. Passing over the anterior surface of the sac in its upper portion, and considerably flattened, is the transverse colon. Densely matted to the surface of the sac is the omentum. In the upper part of the sac a window has been cut out, and to the left a hand, at the top a foot, and between these two, and lying in the vicinity, numerous tufts of hair represented in black may be seen. The sac passes down and almost completely fills Douglas' pouch. This tumor had lain in the abdomen about four years. Apart from the adhesions to the transverse colon, the intestines were perfectly free.

but the sole of the foot measures 6.5 cm. in length and looks mature. The other parts are correspondingly large. The hair of the child is black and curly. There are several points where slight ulceration of the surface has taken place. These correspond to the very thin areas noted in the outer covering. The right tube, which was so firmly glued down that it was thought necessary to remove it, in the hardened state measures 10 cm. in length. It is entirely covered with adhesions, and at its fimbriated end reaches 2.5 cm. in diameter. The ovary is also covered with adhesions, but is not enlarged.

The left ovary is very much flattened and covered with adhesions. The tube runs over into the tumor mass and is lost. It is flattened out, and at one point measures 8 mm. in diameter. The placenta is attached to the left side of the mass.

Histologic Examination.—The sac inclosing the fetus shows that where the omentum has been adherent it has been transformed almost entirely into new and old connective tissue; even the outer adhesions, which contain islands of adipose tissue, are for the most part made up of dense fibrous tissue. Passing inward the fibrous tissue looks older, and then hyaline areas are seen which in size and form closely resemble placental villi. Between these are many small round-cells and spindle-cells. The inner portion is composed of similar hyaline areas, surrounded by a zone of brown pigment that has evidently resulted from an old hemorrhage. The inner surface is lined with necrotic tissue which is especially rich in canalized fibrin, containing chiefly polymorphonuclear leukocytes. In no place is there evidence of muscle-fibers, and it looks as if the case was one of an abdominal pregnancy in which the sac, which was partly supported by the omentum, had gone on to new connective-tissue formation.

EXTRA-UTERINE PREGNANCY.

In several instances we have found it impossible to differentiate between an adherent myomatous uterus and a tubal pregnancy that has been ruptured for several weeks. The ruptured tube is not only enlarged and surrounded by partly organizing clots, but is likewise adherent to the adjacent structures. Where definite multiple myomatous nodules can be felt on the surface of the uterus, or where a submucous myoma can be felt or has been passed, the diagnosis of myoma can be made with a fair degree of certainty, but it must be remembered that tubal pregnancy occasionally accompanies a myomatous uterus, as noted on p. 342. The cessation of the period for one or two months, followed by continuous bleeding and definite pains on one side of the uterus, is, of course, strong presumptive evidence of tubal pregnancy.

A RUPTURED CORNUAL OR INTERSTITIAL PREGNANCY SIMULATING A MYOMATOUS UTERUS.

Several years ago Dr. T. A. Ereck, of Philadelphia, sent us a specimen from a patient that had had a pelvic tumor. It somewhat closely simulated a myoma.

Mrs. G. J., aged twenty-three, married six years. Had one child three years ago. The labor was normal. Her last period began December 22, 1903, and continued four days. On March 7, 1904, she lifted a heavy wash-boiler and was taken with sudden abdominal pain, vomiting, and a bloody vaginal discharge. She went to bed, continued to have intermittent pain, and the next day passed a clot as large as a fist. Thinking she had miscarried, she remained in bed a week and then resumed her household duties. Two weeks later she again had much pain in the hypogastrum and frequent vomiting spells. She dragged along for several weeks without medical attention, but was finally admitted to one of the Philadelphia hospitals on June 19, 1904. The surgeon, on making an examination, diagnosed pregnancy, with probably a large cystic adherent ovary. The patient was discharged on June 22d. In a short time there was recurrence of her pain and vomiting and she was admitted to another hospital, where she remained in bed four weeks but refused operation.

On August 8, 1904, she reentered the hospital, and at this time had much pain and frequent vomiting. Her abdomen was distended. A hard irregular mass could be felt extending from the pelvis to a point above the umbilicus. Vaginal examination disclosed a soft cervix. The uterus was fixed and crowded to the left side by a mass occupying the right. The temperature was 99° F., the pulse 116.

August 10, 1904: The abdomen was opened and omental adhesions to the parietal peritoneum were separated. The omentum covered the pelvic organs and was adherent to the bladder, the inner surface of the broad ligament, and the mass in Douglas' cul-de-sac. After the adhesions had been freed, a fetus was found enveloped in omentum and intestines to the left of the umbilicus. The pelvis was now cleared of a large amount of old blood-clot, and the placental sac was found to project from the right cornu of the uterus (Fig. 295). Both tubes and ovaries were intact. The right tube continued into the mass without any point of rupture. The ovarian artery was ligated on the pelvic side and cut. The mass was then removed from the uterine wall, and the raw area in the uterus closed with a continuous silk suture. The uterus after operation looked one-sided. The patient made an uneventful recovery.

The specimen consists of the right uterine cornu, greatly distended, ruptured, and containing a partially extruded placenta, to which a fetus is attached. Clinging to the side of the cornu are the right tube and ovary. The portion of the cornu present is 8 cm. in its anteroposterior diameter, 5 cm. from right to left, and 7 cm. in length. The cornu has been attached to the uterus by a muscular band, 5 cm. broad and 2 cm. in its anteroposterior diameter.

The placenta is 12 x 7 cm. and two-thirds of it has escaped from the cornu through a rent approximately 7 cm. in diameter. The wall of the cornu varies from 1 to 3 mm. in thickness. The tube is 6 cm. in length, and where attached to the cornu is exceedingly small. It is covered with a few adhesions. The ovary is 4.5 x 2.5 x 2 cm. It is likewise covered with a few adhesions. The

fetus, doubled on itself, is 13 cm. in length, with the thigh flexed upon the abdomen (Fig. 296). It is partially covered with adherent membrane. There is malformation of the hand and foot on the right side, and also of the left foot. The left hand is adherent to the membrane and is also distorted.

On histologic examination at the site of amputation a definite portion of the uterine cavity is found. The mucosa here is 1 mm. in thickness. The gland elements are perfectly normal. The surrounding muscle shows a good deal of

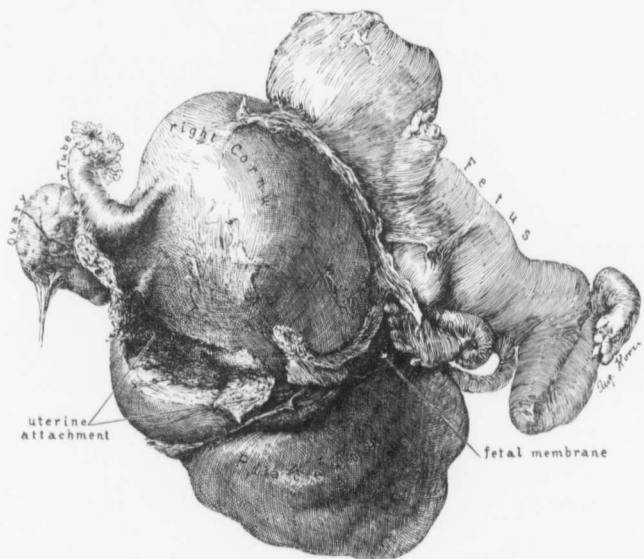


FIG. 295.—A RUPTURED CORNUAL PREGNANCY.

The right tube is normal. The ovary is slightly adherent. The right cornu is considerably enlarged, and attached to its inner aspect is a distorted fetus. Its extremities have become adherent to the body, and it is still partially covered with the fetal membranes. The placenta has been partially extruded. (Specimen sent by Dr. T. A. Erek, of Philadelphia.)

proliferation of the endothelium of the capillaries, and the muscle-cells themselves are considerably swollen. The outer wall of the sac is composed of uterine muscle, and in the outer muscular layers there is dilatation of the capillaries, with some edema of the muscle. The sac contains a quantity of placental tissue. That lying close to the muscle has to a great extent undergone necrosis. We are, no doubt, dealing with a cornual pregnancy. Sections through the Fallopian tube and through the uterine horn show that they are perfectly normal.

HYDATIDIFORM MOLE.*

The following case illustrates very well how a hydatid mole giving rise to a uterine enlargement may be mistaken for a myoma. Whenever a hydatid mole is detected, however, there has been the history of a recent cessation of the period and, on dilating the uterus and curetting, the characteristic small cystic dilatations of the placental villi, as seen in Fig. 297, at once clinch the diagnosis.

The patient was referred to me by Dr. Ernest Johnston, of Berkeley Springs, W. Va., on April 8, 1901. On admission to the Church Home and Infirmary it was learned that five months previous to the examination she had missed her period for two months, and since then there had been a continuous, very dark-red vaginal discharge. The uterus was uniformly enlarged, and the size of that of a three or four months' pregnancy, but the cervix was very hard and the os small. Myoma was first suspected, but we decided to explore the uterine cavity, as the temporary cessation of menstruation, followed by the very dark discharge, was strongly suggestive of a dead fetus. On dilatation of the cervix and introduction of the curet fully half a liter of cyst-like bodies was removed. These varied from 1 mm. to 2 cm. or more in diameter. The patient made a prompt recovery.

Path. No. 4851. The specimen consists of about half a liter of small transparent cysts, varying from 1 mm. to 2 cm. in diameter. They have thin walls and immediately remind one of small subperitoneal cysts. They are traversed by a delicate network of blood-vessels. The exact relation of the majority of the cysts cannot be determined, as they were brought away with the curet. Here and there, however, we have been fortunate enough to obtain large pieces of the growth. At such points we find shreds of membrane, and attached to these by delicate pedicles, varying from 1 mm. to 2 cm. in length, are these small cysts (Fig. 297). On further examination of these cysts some of them are found to be pear-shaped instead of round. Accompanying the cysts are large and small shreds of solid tissue, no doubt portions of the decidua.

Histologic Examination.—Sections from the cyst show that the outer surfaces in places have a covering of syncytium, very scant in amount. At most points, however, this is wanting. The walls consist of spindle-shaped cells, and the inner surface has clinging to it coagulated fluid. There is no layer of

* Thomas S. Callen, Johns Hopkins Hospital Bulletin, 1902, vol. xiii.

FIG. 295.—RUPTURE OF THE RIGHT CORNU OF A BICORNATE UTERUS WITH ESCAPE OF THE FETUS. (1 nat. size.)

The fetal membrane seen in Fig. 295 has been severed, so that the relations can be more readily followed. The cornu had partially ruptured, and the fetus was held in contact with the uterus only by the membrane. More than half of the placenta has been extruded from the ruptured wall, and the muscle at this point is greatly thinned out. The fetus is macerated. The left leg is flexed and has grown fast to the thigh. The left arm is adherent to the chest, and has become firmly attached to the membranes. The right arm and leg also showed marked distortion. (Specimen sent by Dr. T. A. Ersk. of Philadelphia.)

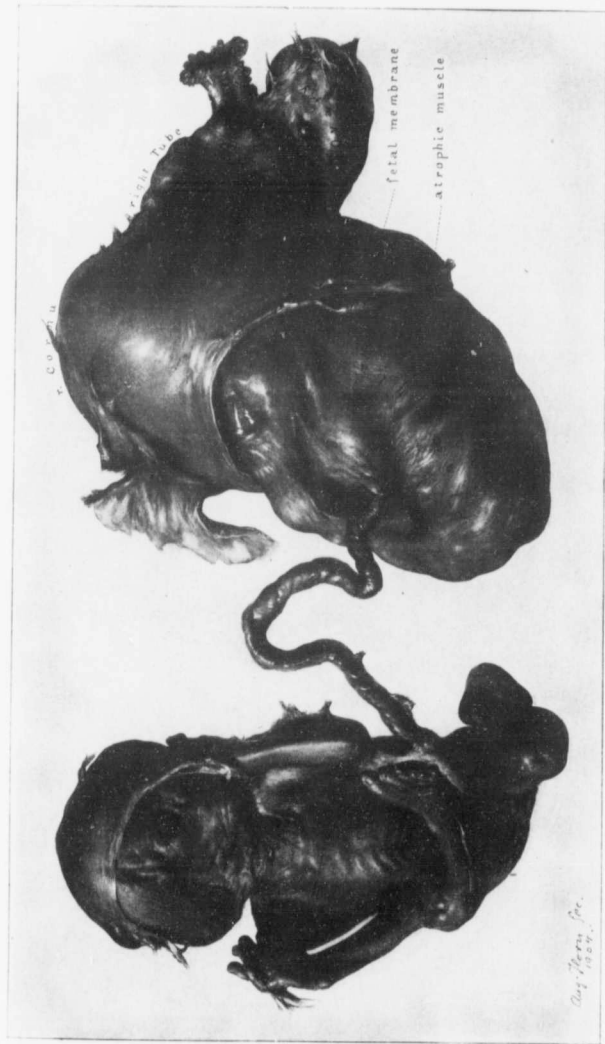

FIG. 296.

cells lining the inner surface of the cyst. These small tumors are due to cystic dilatation of the stroma of the villi, and hence are not true cysts. In some places typical villi are demonstrable. Covering the outer surface of some of the villi, and in close proximity to the cysts, are masses of cells somewhat resembling decidua cells. They are, however, much larger than ordinary decidua cells. The nuclei are also larger, irregular, and stain deeply. All gradations, from those of normal size to the large and irregular ones, can be followed. While the majority of these cells are probably decidua in origin, some of them are undoubtedly altered syncytial cells, as the direct transition can be traced.

The patient was perfectly well six years after operation.

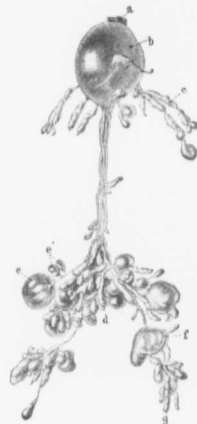

FIG. 297.—A SMALL FRAGMENT OF A HYDATIDIFORM MOLE. (1 nat. size.)

Path. No. 4851. The specimen has been floated out in water, in order that the ramifications may be followed. *a* corresponds to the basal attachment, and *b* is a large cystic dilatation of a villus. At *c* we have rows of small oblong cysts. The main stem continues downward, and spreads out into the conglomerate mass of cysts (*d*), but just above this point it gives off a small stem of stroma which ends in a cystic terminal (*e*) after having given off two terminal twigs (*e'*) with cystic ends. At *f* is a cystic dilatation in the continuity of a villus, a short distance further on followed by the terminal bunch of cysts, *g*. (After Thomas S. Cullen.)

CHORIO-EPITHELIOMA.

In the following case* a chorio-epithelioma on bimanual examination suggested a large myomatous uterus, and not until the abdomen was opened were we aware of the exact condition.

In all such cases, however, if an accurate history is obtainable, it will be found that the patient has either recently had a miscarriage or a normal labor, and in all these cases a curettage will yield the characteristic growth, or at least necrotic material which would at once put the operator on his guard.

Gyn. No. 13204. Path. No. 10278.

Chorio-epithelioma with the uterus the size of that of a five months' pregnancy; hysterectomy; temporary recovery.

The patient was admitted August 31, and was discharged September 25, 1906. On examination, Dr. Rushmore found the abdomen somewhat distended by a firm mass, which rose out of the pelvis and extended as high as the umbilicus, rather more prominently on the left than on the right side. The mass

was slightly movable, and not tender, except just above Poupart's ligament on the left side. It was regular in outline, and on deep inspiration its upper border

*Thomas S. Cullen, A Series of Interesting Gynecologic and Obstetric Cases, Jour. A. M. A., May 4, 1907, vol. xlviii.

was obliterated by the surrounding intestines. The vaginal outlet was moderately relaxed, the cervix was high in the vaginal vault, lying far back and pointing downward. The cervical lips were not hypertrophied; the os was slightly patulous. There was no induration suggestive of a new-growth. The mass in the pelvis was uniformly fixed. On examination under ether the tumor was freely movable, but suggested a myoma about six inches in diameter, with a cystic mass on the left. The breasts contained colostrum.

On exposure of the enlarged uterus the appearance suggested pregnancy very strongly. The vessels were much dilated. No definite nodules could be made out in the fundus, but on the posterior surface was a slight prominence, with a curious yellowish discoloration of the tissue beneath, and there were numerous dilated vessels suggestive of a malignant new-growth. As a definite diagnosis could not be made from palpation, we decided to incise the uterus over the prominence, at the same time carefully walling it off so that the general cavity would be protected. On incision, a vascular new-growth was immediately seen. This had a spongy appearance, and immediately suggested a malignant growth, differing entirely from carcinoma and sarcoma. Dr. Cuthbert Lockyer, of London, Eng., a man who has contributed largely to our knowledge of this subject, was with me (Cullen) at the time, and corroborated the diagnosis of chorio-epithelioma. The incision was immediately closed, and the uterus removed. The liver was carefully examined for metastases, but none could be detected.

In this case there was no positive history of a recent miscarriage, although the possibility cannot be excluded. The contour of the uterus on pelvic examination strongly suggested a myomatous uterus, and with the abdomen opened it was impossible for one to exclude pregnancy.

Path. No. 10278. The specimen consists of a greatly and uniformly enlarged uterus, measuring 20 cm. in length, 13 cm. in breadth, and 12 cm. in thickness. The anterior surface is smooth and glistening; the posterior is covered with many adhesions, thin and fan-like. Attached near the left cornu is a tag of omentum. On section, the uterine cavity is found to be 15.5 cm. in length. The uterine walls vary from 3 to 6 cm. in thickness. The outer portion of the wall consists of muscle, varying from 1 to 1.5 cm. in thickness. Lining the entire uterine cavity is a spongy, porous growth (Fig. 298). The uterine mucosa as such is not recognized, but is represented by hills and hollows. The projections into the cavity are dome-shaped, and vary from 0.5 to 2 cm. in depth. Here and there on the surface are cyst-like depressions, with narrowed bands of tissue stretching from side to side. There are also numerous cavernous spaces, bridged over by bands of the growth. This growth involves the entire uterine wall, both anteriorly and posteriorly. The great thickness in the wall is due to the presence of the growth, which varies from 1 to 6 cm. in thickness. At the fundus it extends almost to the peritoneal covering. The growth in no way resembles either a carcinoma or a sarcoma. One is instantly reminded of the growth that

occasionally occurs after a miscarriage. The cervix is somewhat flattened, is 6 cm. in breadth, and its lips appear to be normal.



FIG. 298.—CHORIO-EPITHELIOMA. ($\frac{1}{2}$ nat. size.)

Gyn. No. 13204. Path. No. 10278. The specimen consists of a uniformly enlarged uterus. The cervix is normal; the body is as large as that of a five months' pregnancy. Occupying the entire body of the uterus is a new-growth with many depressions and cystic spaces extending into the wall. The growth itself presents a peculiar porous appearance (b), and the finger-like processes so characteristic of carcinoma are absent. In the lower part of the uterus the outer muscular walls are still clearly seen, but in the upper part of the cavity the growth has extended almost to the peritoneal surface. The growth could hardly be mistaken for anything else. It is remarkable to see so uniform an involvement of the entire uterine wall, a indicates clearly the sharp line of demarcation between the malignant growth and the outer muscular covering.

Histologic examination shows the growth to be a typical chorio-epithelioma. After some months the patient commenced to lose ground, and soon died with metastases.

ENLARGEMENT OF THE UTERUS DUE TO A RETAINED MENSTRUAL FLOW.

In 1906 we received word from one of the most careful practitioners in the State saying that he was going to send a patient with a uniformly enlarged and globular uterus for operation, and that the enlargement was apparently caused by a myoma. During the long railroad ride the patient lost much blood, and when one of us examined her at the hospital the uterus showed little enlargement. From the history, it will be seen that as the result of an endometritis the vaginal walls had become irritated and later agglutinated. Successive menstrual flows had thus been retained, and the uterus had become distended. The jolting over a poorly ballasted railroad had been sufficient to partially separate the adherent vaginal walls; the fluid contained in the upper part of the vagina and distending the uterus had escaped, and the supposed uterine tumor disappeared.

P., admitted to the Church Home and Infirmary June 17, 1906. The patient was fifty years of age. For several months she had had no periods, but recently there had been an excessive amount of pain in the lower abdomen. The enlargement was apparently due to a myoma. Her physician found a globular and enlarged uterus. During a long railroad journey she had had a profuse bloody discharge, and the abdominal pain had to a great extent disappeared. We examined the patient under ether, and found the vagina closed half-way up, but there was just a small opening. This could readily be dilated with the finger, and there was an immediate escape of old blood, ropy in character. The cervix was considerably dilated. Pressure on the uterus increased the flow. We stretched the cervix and curetted the uterus, but obtained little mucosa.

On histologic examination of the mucosa we found that it was the seat of acute inflammation. In this case there had been an acute endometritis. The vaginal surfaces had become glued together, and complete occlusion had taken place. There had been an accumulation of secretion in the uterine cavity, giving rise to the supposedly globular myomatous uterus, and at the same time causing a great deal of discomfort from the distention.

CARCINOMA OF THE UTERUS.

Before considering the difficulties in diagnosing carcinoma of the uterus from myoma, it may be well to glance at Chapter XVI, p. 274, in which many cases of carcinoma of the body associated with uterine myoma are described.

When the carcinoma commences in the vaginal portion of the cervix, the differential diagnosis between a malignant growth and a myoma is usually easy, but in some cases, when a sloughing submucous myoma protrudes from the cervix and partially fills the vagina, it may be mistaken for a cauliflower-like carcinomatous mass. The pedicle of the myoma is usually attached high up in the cervical canal or in the body of the uterus, and the finger can be carried around it on all sides. When carcinoma of the cervix is present, the growth

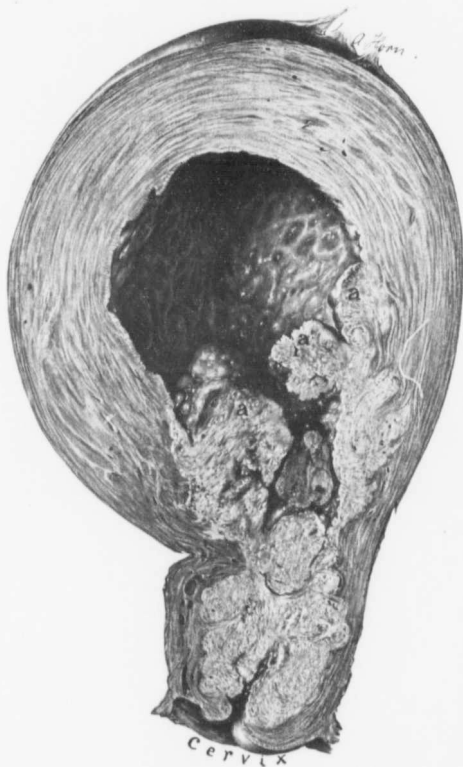

FIG. 299.—CARCINOMA OF THE CERVIX AND LOWER PART OF THE BODY OF THE UTERUS CLINICALLY SUGGESTING A MYOMATOUS ORGAN. (Nat. size.)

GYN. No. 10490. Path. No. 6727. The uterus was globular and about the size of that of a four months' pregnancy. The vaginal portion of the cervix was normal. The greater part of the cervix and the lower portion of the body of the uterus were occupied by carcinomatous tissue. Masses of it are seen projecting into the uterine cavity at a, a, a. The cervical canal had been blocked, and the body of the uterus had become much distended and was filled with pus. The mucosa has been replaced by granulation tissue, as recognized by the undulating surface so often noted where a suppurating membrane exists. From the normal appearance of the cervix, the uniform contour of the body and the firmness of the tissue, myoma was naturally diagnosed. Had carcinoma been suspected, curettage would have at once established the true diagnosis.

springs from the cervix itself, is exceedingly friable, and bleeds very much more freely on manipulation than the submucous myoma. If the diagnosis cannot be established, histologic examination of the tissue may at once afford the proper diagnosis.

If the carcinoma be far up in the cervical canal or in the body of the uterus, considerable confusion may arise.

The following cases are very good examples of the difficulty in deciding between myomata and carcinoma of the uterus.

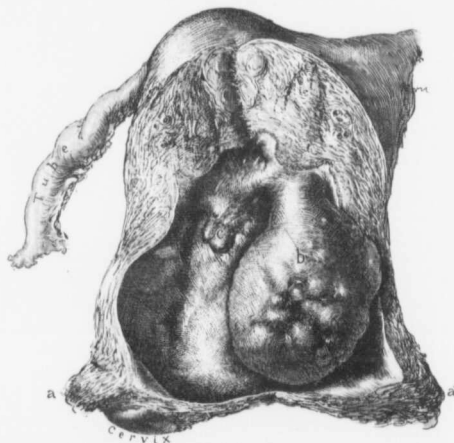


FIG. 300.—A SUBMUCOUS MYOMA CLINICALLY SUGGESTING CARCINOMA OF THE CERVIX. ($\frac{1}{2}$ nat. size.)

Gyn. No. 13498. Path. No. 10776. The clinical history strongly suggested carcinoma of the uterus. On examination the vaginal portion of the cervix was found to be normal, but the greater part of the cervix was much enlarged and hard. So sure was the operator of the malignancy of the growth that he did a complete hysterectomy. In the illustration the small vaginal portion of the cervix is intact. The uterine cavity has been opened and unfolded. With the uterus closed, points *a* and *a'* would come together. The great hardness in the lower part of the uterus was due to the polynodulated submucous myoma *b*. This also gave rise to the suspicious discharge. *c* is a small polyp. Scattered throughout the uterine walls are a few small interstitial myomata.

The uterus in Gyn. No. 10490 (Path. No. 6727) formed a globular mass, about the size of that of a four months' pregnancy. Myoma was diagnosed. On opening the supposedly myomatous uterus, the cervix and lower part of the body were found filled with carcinomatous tissue (Fig. 299); the cavity of the uterus was full of pus. A glance at the cervix will show that on vaginal examination it appeared perfectly normal. Curettage in this case would have cleared up the diagnosis at once, but, as a rule, where the condition is supposedly one of simple myoma, one hardly deems it wise to curet unless some important

information seems to be promised. Whenever carcinoma is suspected, scrapings should by all means be examined prior to attempting the hysterectomy.

On the other hand, a myoma may simulate a carcinoma, as was noted in Case 13498 (Fig. 300). The operator found a small external os and an apparently much enlarged and densely hard cervix. So sure was he that the growth was carcinomatous, that he made a rather extensive and complete abdominal hysterectomy. The enlargement and denseness of the cervix were due to a submucous and pedunculated myoma (*b*).

In Gyn. No. 10440 the patient was exceedingly stout, and had a relatively

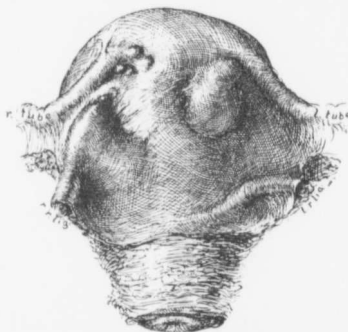


FIG. 301.—ADENOCARCINOMA OF THE BODY OF THE UTERUS WITH SUBPERITONEAL NODULES. (1 nat. size.)

GYN. No. 10440. Path. No. 6644. The specimen is viewed from the front. The right round ligament is drawn upward by a cancerous nodule situated at its junction with the uterus. Scattered over the surface of the uterus are cancerous nodules, varying from a few millimeters to 2 cm. or more in diameter. The insertion of the left round ligament is at a much lower level than is that of the right. The general contour of the enlarged and nodular uterus closely resembles that of a myomatous organ. (After Thomas S. Cullen.)

The menses stopped at forty-nine. Four years ago uterine hemorrhages commenced and lasted several months. Since then they have been irregular. There is a continual leukorrhœal discharge, with some odor.

On vaginal examination we found the uterus about twice its natural size. Scattered over its surface were numerous nodules. As the patient was in good condition and had a nodular uterus, which in general contour closely resembled a myomatous uterus, we made a diagnosis of myoma (Fig. 301), especially as the hemorrhages could readily be accounted for by the presence of myomata and the vaginal discharge was but slightly offensive.

* Thomas S. Cullen, A Series of Mistaken Gynecologic Diagnoses, J. A. M. A., November 19, 1904.

small uterus. One of us,* on thorough bimanual examination, clearly felt nodules on the surface of the uterus, and accordingly made a diagnosis of multiple myomata. A glance at the accompanying history of the case will show that the growth was primarily a carcinoma of the body, with extension by continuity to the peritoneal surface.

Gyn. No. 10440; Path. No. 6644.

Diagnosis: Myomatous uterus. Actual condition: adenocarcinoma of the body of the uterus, with secondary subperitoneal nodules (Fig. 301).

M. C., aged fifty-eight, white. Admitted April 22, 1903. The patient has had three children.

At operation we found the uterus as I have described it, but the supposedly myomatous nodules represented points at which the cancer of the body of the uterus had extended to the peritoneal surface. They were raised nodules beneath the surface, and at several points had become attached to the intestines. Complete hysterectomy was performed. The patient made a good recovery, and was in perfect condition five years later. In this case curettage, even without a microscopic examination, would have been sufficient to establish the diagnosis.

In Path. No. 4479 (Fig. 180, p. 286) we did a supravaginal hysteromyomec-tomy. Myomatous nodules were scattered over the surface of the uterus, and the entire growth seemed to be myomatous in character. On examination of the specimen in the laboratory the greater part of the enlargement was found to be due to a carcinoma of the body of the uterus. If the operator, with the abdomen open, sometimes fails to differentiate between carcinoma and myoma, there is certainly abundant excuse for the general practitioner, who has to rely on the bimanual examination.

In Case 3693 we have another example of the difficulties in deciding between myoma and carcinoma. On referring to Fig. 302 it will be noted that the uterus is nodular and several times its natural size. The cervix is enlarged, but intact; the cavity is lined with nodular masses that bear some resemblance to the myomata which sometimes pave the uterine cavity. Further, it will be noted that although the patient had had a profuse leukorrhœal discharge, there was no hemorrhage. Scrapings in such a case would at once yield carcinomatous tissue.

Gyn. No. 3693; Path. No. 828.

An unusual carcinomatous uterus, bearing considerable resemblance to a myomatous organ* (Fig. 302).

N. G., aged seventy-six, white. Admitted July 30; discharged September 8, 1895. The menses ceased twenty-five years ago. The patient has always been healthy. One grandfather died of cancer, and several relatives of tuberculosis. For the last year she has had a profuse bloody vaginal discharge, and has experienced sharp shooting pains all through the abdomen. For the relief of these during the last six months she has taken a good deal of opium. At no time has she had uterine hemorrhages. Her general condition is poor; she eats very little; her tongue is red and fissured; the bowels are constipated. On vaginal examination the cervix is found to be intact, but enlarged; the uterus is about the size of that of a three months' pregnancy, and somewhat nodular. A complete hysterectomy was done.

Path. No. 828. The specimen consists of the uterus and appendages intact. Both anteriorly and posteriorly the organ is smooth and glistening. Projecting

* This case was reported in full in Contributions to the Science of Medicine, by the Pupils of William H. Welch, 1900, page 401.

from the anterior surface, about 2.5 cm. from the fundus, are two subperitoneal nodules. These are irregular in contour, whitish yellow, and covered with peritoneum (Fig. 302). They do not project more than 2 mm. from the surface. Just posterior to the right cornu is a similar elevation, 2.5 cm. in diameter.

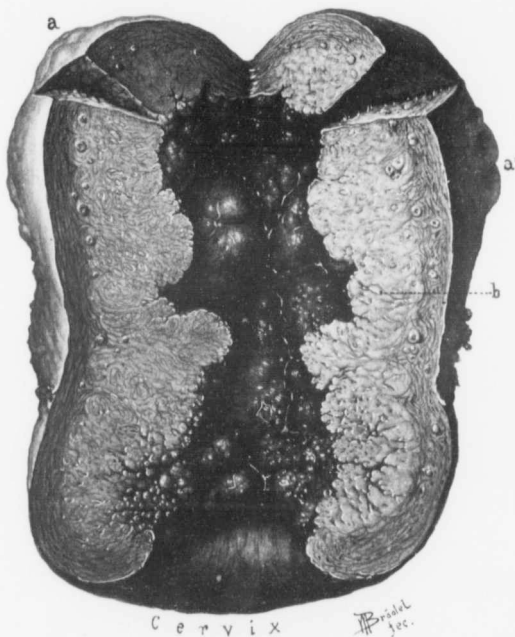

FIG. 302.—A RARE FORM OF ADENOCARCINOMA OF THE UTERUS. (Nat. size.)

Path. No. 828. The uterus is nearly three times its natural size; it presents a nodular surface, as noted at *a* and *a'*. The cervix is greatly thickened, but the vaginal portion and the external os are still intact. The organ, from the external os to the fundus, is occupied by a new growth which entirely obliterates the normal landmarks. The uterine cavity is lined with large and small dome-like masses, consisting almost entirely of necrotic tissue. The new-growth has invaded the cervix and body uniformly, extending in most places to within 5 mm. of the peritoneal covering, and at *a* and *a'* reaching the outer surface. The growth is whitish in color, very friable, and stands out in sharp contrast to the uterine muscle. (After Thomas S. Cullen.)

On palpation the uterus seems to contain many areas which present a stony hardness. The cervix is 3.5 cm. in diameter, and is intact. It feels somewhat soft to the touch, but at the same time one obtains the impression that there are deeper areas which are very dense.

On section, the cervical mucosa presents the usual appearance for a distance of 5 mm., but above this point it is practically impossible to distinguish between the cavity of the cervix and that of the body, both being of equal breadth. The combined cavity is 10 cm. in length. Almost from the external os to the fundus the walls are composed of necrotic-like tissue, which is gathered up into large and small dome-like masses. Covering the inner surface is a dirty greenish or reddish material. The uterine walls from cervix to fundus have been invaded by a new-growth which penetrates the muscle to within from 8 to 2 mm. of the surface; the wall has been invaded throughout its entire thickness, these areas being nothing more than a continuation of the growth.

The cervix and body are almost uniformly implicated, although the former, perhaps, has suffered a little more extensively.

Histologic examination shows this growth to be a carcinoma of a most unusual type. It is described and pictured in detail in "Cancer of the Uterus," p. 588.

HISTOLOGIC CHANGES IN MYOMA SUGGESTING CARCINOMA.

Sarcomatous changes in myomata are by no means rare. (See Chapter XIV, p. 169.) For the primary development of a carcinoma in a myoma it is absolutely

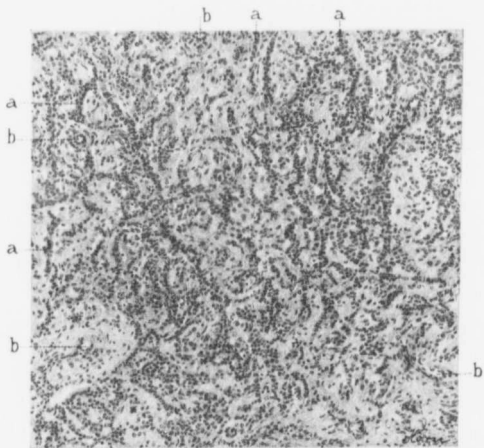


FIG. 303.—A PECULIAR ARRANGEMENT OF MUSCLE-FIBERS SUGGESTIVE OF CARCINOMA. (X 110 diam.)

Gyn. No. 12591. Path. No. 9349. The specimen is from the center of a submucous myoma. The pale areas are due to hyaline degeneration. The remaining muscle-fibers are arranged in straight, irregular or curved groups, as indicated by a. At b are capillaries, some of them surrounded by a zone of hyaline. The picture at first suggests carcinoma, but all the muscle-nuclei are of the usual size and there is no epithelium.

necessary to have had preëxisting glands, and these are found only in an adenomyoma. Nevertheless, we may have the muscle-fibers arranged in such a way that they closely resemble alveoli. In Case 12591, for example, a submucous myoma, 6 cm. in diameter, was removed through the vagina. Histologically (Path. No. 9349), the surface of the myoma was covered with squamous epithelium, and the muscular tissue had undergone marked hyaline degeneration and liquefaction. The remaining muscle-fibers were arranged in single, straight or curved, rows (Fig. 303) and at first sight strongly suggested carcinoma, but on careful study of the muscle nuclei they were found to be of a uniform size, and there was no doubt that the growth was benign.

SARCOMA OF THE UTERUS.

Sarcoma of the uterus, in our experience, has in the majority of cases developed in or been associated with uterine myomata. (See Chapter XIV, p. 169.) In such cases the only clinical clue to the malignant growth is the fact that the tumor has of late grown very rapidly.

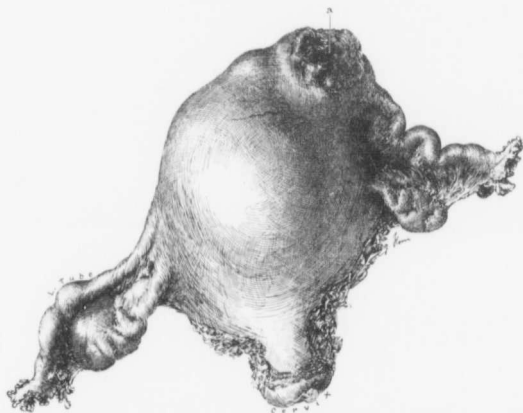


FIG. 304.—SARCOMA OF THE BODY OF THE UTERUS. ($\frac{1}{3}$ nat. size.)

Path. 10494. The body of the uterus is irregularly enlarged, and at a is the volcanic welling-out of a growth which occupies the interior of the organ. The cervix and appendages are normal. For the appearance of the growth on section see Fig. 305.

When the growth from the beginning is a sarcoma, it may implicate the uterus uniformly, or produce numerous nodular elevations. If the major portion of the tumor is subperitoneal, it may possibly be recognized by the soft feel; if submucous, portions can be curetted away and the diagnosis established.

In Fig. 304 we have an example of an enlarged uterus which, from its contour, suggested an irregular myomatous growth. Dr. James Bosley, under whose care the patient had come, had, however, recognized the malignant character of the growth from scrapings obtained a few weeks before. In Fig. 305 we see the appearance of the sarcoma on section. The cervix is normal, and would yield no clue on vaginal examination. The body of the uterus is occupied by a homogeneous growth which has extended to the peritoneal surface at several points. It shows considerable hemorrhage and degeneration in the area indicated by b.

The diagnosis between sarcoma and myoma is in some cases absolutely impossible prior to operation.

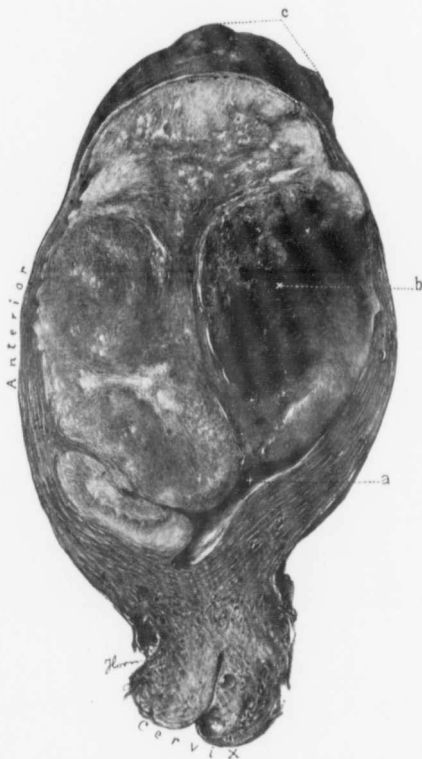

FIG. 305.—SARCOMA OF THE BODY OF THE UTERUS. (Nat. size.)

Path. No. 10194. For the general appearance of the uterus see Fig. 304. A few cervical glands are dilated, otherwise the cervix is normal. a is the distorted uterine cavity. Occupying the fundus is a homogeneous growth showing little structure. At b it is hemorrhagic and is disintegrating. At c the growth forms a nodular projection from the peritoneal surface. The postoperative history indicated wide-spread lymphatic involvement in a few months.

FIBROMA OF THE OVARY.

The diagnosis between fibroma of the ovary and myoma of the uterus may be fairly easy, provided it is possible to outline a perfectly normal uterus. If, on the other hand, the uterus contains myomata, the differentiation between the solid ovarian tumor and the myomata is well-nigh impossible. The following cases illustrate this difficulty:

Gyn. No. 9090. Path. No. 5247.

Fibroma of the ovary; small uterine myomata.

C. C., aged sixty-two, white. Admitted September 27; discharged October 20, 1901. Filling the lower abdomen, and extending almost to the umbilicus,

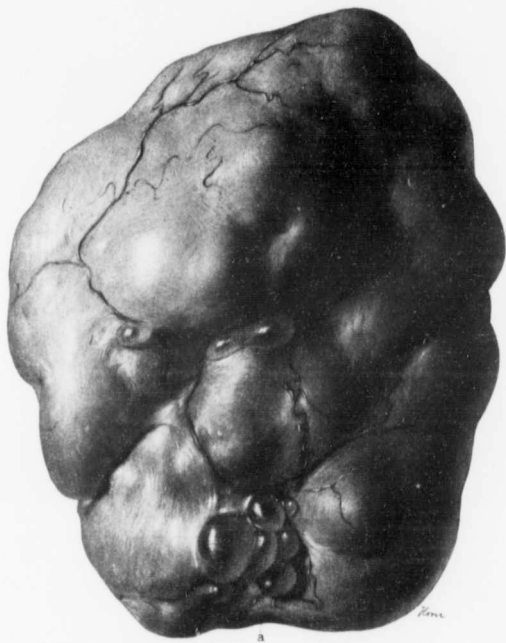


FIG. 306.—FIBROMA OF THE OVARY. (1 NAT. SIZE.)

Gyn. No. 9090. Path. No. 5247. The irregular globular mass measured 12 x 14 x 16 cm., and was whitish in appearance. Ramifying over its surface were numerous blood-vessels. At several points were small subperitoneal cysts. A colony of them is seen at a. When lying on the table, the tumor bore a striking resemblance to a subperitoneal myoma. The pedicle was 5 mm. broad and 1.5 cm. long.

was an irregular and freely movable nodular mass. The cervix was normal, but the body of the uterus could not be outlined.

On section of the abdomen a fibroma of the ovary, 12 x 14 x 16 cm., was found (Fig. 306). Three small subperitoneal myomata, not over 1 cm. in diameter, and another 2 cm. in diameter and pedunculated, were removed from the uterus and the patient made a good recovery.

A glance at Fig. 306 will show that the fibroma of the ovary bore a striking resemblance to a myoma, and the further fact that the uterus contained small myomata would influence the physician in making a diagnosis of uterine myomata instead of fibroma of the ovary. A subperitoneal myoma may be just as freely movable as was this ovarian tumor.

Gyn. No. 10491. Path. No. 6712.

Fibroma of the ovary; multiple uterine myomata.

R. B., aged twenty-nine, colored. Admitted May 14; discharged June 8, 1903. The cervix was high up, soft, and normal in size. Filling Douglas' pouch was a very hard mass. Occupying the lower abdomen, and extending as high as the umbilicus, was what appeared to be a myomatous uterus. When the abdomen was opened, the tumor filling the cul-de-sac proved to be a fibroma of the ovary. The myomatous uterus and the ovarian tumor were removed.

Path. No. 6712. The uterus contained submucous, interstitial, and subperitoneal myomata. It measured 10 x 17 x 20 cm., and was free from adhesions. The fibroma of the ovary measured 5 x 10 x 10 cm.

Uterine myomata are very common. Fibroma of the ovary is relatively rare.

Ascitic fluid is a common accompaniment of fibroma of the ovary, exceptional with myoma, although it may occur as noted on p. 30. Accordingly, if we have a solid pelvic tumor and also ascites, we may strongly suspect a fibroma of the ovary. This assumption becomes almost a certainty if the uterus is normal in size and free from myomata.

What has been said concerning ovarian fibromata applies equally well to the slow-growing sarcomata of the ovary.

OVARIAN CYSTS.

As a rule, the diagnosis between uterine myomata and ovarian cysts is easily established, but there are certain cases in which it is exceedingly difficult to decide whether the growth springs from the ovary or uterus. The following cases illustrate this point very well.

Myomata Resembling Ovarian Cysts.—In Case 10555 the abdominal walls were very lax. A smooth rounded mass, about 10 cm. in diameter, lay in the pelvis. It could be displaced to any part of the abdomen. The vaginal outlet was markedly relaxed; the fundus was in retroposition. It was impossible to determine whether or not the abdominal tumor had any connection with the uterus. On account of its excessive mobility, the tumor was thought to be an ovarian cyst. When the abdomen was opened, it proved to be a pedunculated subperitoneal myoma.

In Case 4699 the pelvis was filled with a rounded, slightly movable, and apparently fluctuant tumor. At operation the enlargement was found to be due to an interstitial myoma.

In Case 10204, in which the entire abdomen was greatly distended, the clinical signs, even under ether, strongly suggested an ovarian cyst, and yet the tumor proved to be a myomatous uterus.

In Case 7263 the soft and irregular boggy feel of the enlarged uterus strongly suggested a dermoid cyst glued to the surface of the uterus. At operation an interstitial myoma was found.

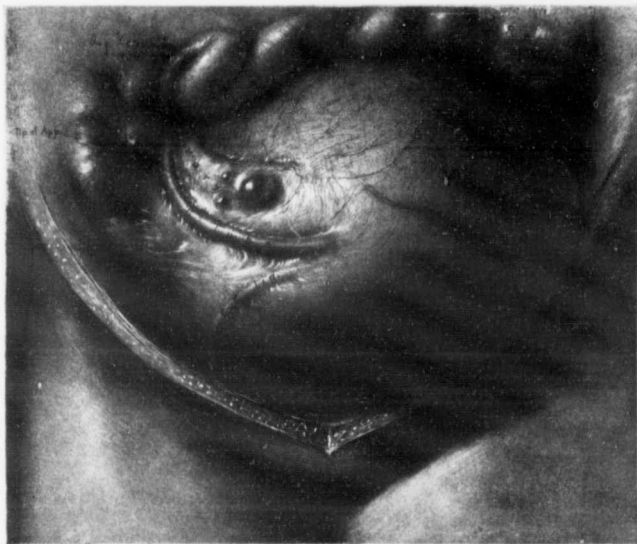

FIG. 307.—A MYOMATOUS UTERUS MISTAKEN FOR AN OVARIAN CYST.

Gyn. No. 9736. On section of the abdomen the tumor was found to have a double set of blood-vessels. An attempt was made to puncture it, on the supposition that it was an ovarian cyst. No fluid was obtained, and on enlarging the incision it was found that the tumor was a soft, boggy, myomatous uterus, with the ovaries plastered on its posterior surface.

The right round ligament is clearly seen in the drawing. The rectum was also firmly adherent to the tumor. Removal of the uterus was difficult on account of inflammatory tissue.

In Case 9736 (Fig. 307) the myomatous uterus simulated an ovarian cyst so closely that even after the abdomen was opened an attempt was made to evacuate it.

A cystic myoma may sometimes be felt on digital examination as a boggy mass. This was noted in Case 9030. Occasionally on abdominal palpation a doughy sensation was noted, as in Case 8251.

A Parasitic Myoma with Ascites.*—On p. 35 Case P. is reported in full. This patient had a tremendous abdominal enlargement and a drawn facial expression. Dulness in front, tympany in the flanks, and marked fluctuation were elicited. From the physical signs we were sure that the patient had a very large ovarian cyst. It was impossible to get the previous history from the patient, as she was weak mentally. Guided solely by our findings, we made a diagnosis of ovarian cyst, but in this the family physician, Dr. E. H. Hopkins, did not concur. He insisted that the patient had a myoma with ascites, because he was sure that the patient had had a solid uterine tumor for several years before the appearance of any fluid. On opening the abdomen we found a pedunculated myoma which received nearly all its nourishment from the omentum and bladder (Fig. 25, p. 36). In the abdomen were 51,000 c.c. of ascitic fluid. The tympany in the flanks was due to the fact that the intestines were held back by the tumor and the omental vessels, and even if they had been free, the abdominal distention was so great that the mesentery of the small bowel would not have allowed the intestines to reach the surface, and dulness would still have been present over the anterior abdominal wall.

Simple Ovarian Cysts Resembling Myomata.—Where the ovarian cyst is irregular in shape, fills the pelvis, and spreads out into the broad ligament, it may closely resemble a cystic myoma. We have such an example in Fig. 308. The tumor is very irregular in shape and lobulated; the uterus rests in a depression near the upper and anterior surface of the cyst. It

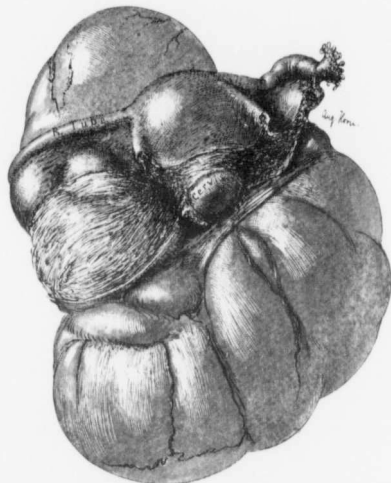


FIG. 308.—A MULTILOCULAR OVARIAN CYST IN FORM RESEMBLING A CYSTIC MYOMA. (1 nat. size.)

Gyn. No. 11133. Path. No. 7364. The multilocular ovarian cyst arising from the right ovary is markedly lobulated and irregular in form. It has evidently filled the pelvis completely, and been held firmly in place by the uterine attachments. In form and in its relation to the uterus it bears a close resemblance to the cystic myoma seen in Fig. 88, p. 111.

* Thomas S. Cullen, A Series of Mistaken Gynecologic Diagnoses, Jour. A. M. A., November 19, 1904.

is clearly evident that this tumor was firmly wedged in the pelvis. On referring to Fig. 88 (p. 111), where a very large cystic myoma was present, it will be seen that both tumors bear a striking resemblance to each other in form and also in the relation of the uterus to the tumor. Both of them naturally yielded a cystic feel on bimanual examination.

BILATERAL OVARIAN CYSTS WITH PAPILLARY MASSES ON THEIR SURFACES AND ALSO ON THE PERITONEUM OF THE UTERUS.

Occasionally the uterus may be wedged in between cystic tumors of both ovaries. If these are very tense and covered with papillary masses, myoma may be strongly suspected. In Fig. 309 we have an example of such a condition. Both ovaries have been converted into multilocular ovarian cysts, the left being



FIG. 309.—BILATERAL OVARIAN CYSTS WITH PAPILLARY MASSES ON THEIR SURFACES. (3 nat. size.)

GYN. No. 9608. Path. No. 5799. Both ovaries have been converted into multilocular cysts, and on their outer surfaces are papillary masses. The left lay deeper in the pelvis. Attached to the surface of the uterus are several small papillary masses, indicated by a *a*. From the general contour of the pelvic mass it might be mistaken for a uterus with multiple myomata.

the larger. Both are covered with shaggy papillomatous growths. The cyst on the left side has been firmly held in Douglas' sac by the uterus. In such a case the growths might readily be mistaken for soft myomata with secondary nodules on their surfaces. Where the cysts have very thin walls, however, little difficulty should be encountered.

OMENTAL METASTASES.

Where one or both ovaries are carcinomatous and portions of the growth are seen on the surface of the tumor, it is not unusual to find a secondary

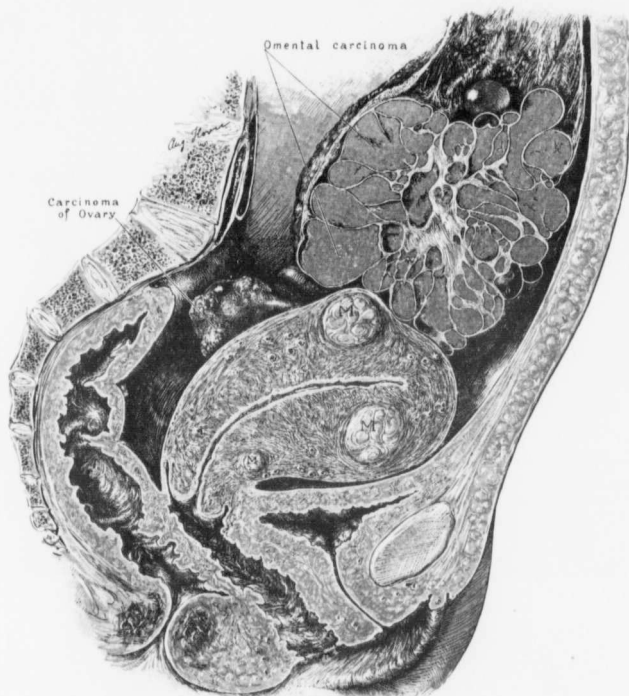


FIG. 310.—SMALL UTERINE MYOMATA; CARCINOMA OF THE OVARY WITH VERY LARGE OMENTAL METASTASES.

Path. No. 4878. The uterus contains two small interstitial and one subperitoneal myomata. The left ovary is small, but carcinomatous nodules project from its surface. The lower part of the omentum contains a large metastatic carcinomatous growth. This is lobulated, has a definite framework of connective tissue, and the intervening lobules consist of carcinomatous tissue of the same type as that of the primary growth in the ovary. Bimanual examination in such a case reveals a small myoma on the surface of the uterus, and the natural assumption would be that the omental growth was merely a subperitoneal nodule.

carcinomatous implication of the omentum. This may be limited to the lower end of the omentum, or occur as numerous foci. The nodules may be small or reach very large proportions. Where, on bimanual examination, the

uterus is found to be somewhat enlarged, and where one or more small myomata are detected on its surface, as in Fig. 310, the natural inference is that the abdominal growth is also myomatous. Some of the omental metastases, however, are not rounded, but have sharp, clean-cut edges, reminding one of the lower margin of the liver. In such cases no confusion should exist.

RUPTURED RECTAL DIVERTICULA.

The following case clearly illustrates the great difficulty sometimes encountered in making a positive diagnosis between uterine myomata and other pelvic lesions. Not until the abdomen was opened were we sure that the enlargement was not uterine in origin.

S., C. H. I. (February, 1904), Path. No. 7276.

Diagnosis: Pelvic abscess with retroverted myomatous uterus. **Actual condition:** Rectal diverticula with rupture into the surrounding fat, producing a definite tumor; small abscess between the tumor and the pelvic floor (Fig. 311).

This patient was sixty years of age. For some time she had experienced slight difficulty in defecation. The stools, however, were perfectly normal in caliber. For several days she had had a temperature of from 100° to 103° F.

On vaginal examination the uterus was somewhat enlarged. Posterior to it, and apparently continuous with it, was a globular mass. This was very hard, and resembled a myoma in contour. There was, however, a hard ridge over its lower portion, as is so often noted where a pelvic abscess exists.

A small incision was made in the vaginal vault, just posterior to the cervix, and after the mucosa had been peeled back, Douglas' pouch was entered with a pair of blunt artery forceps. A small amount of pus and a few flakes of fibrin escaped, but the mass was in no way diminished in size. Realizing the presence of an unusual condition, the opening in the vault was packed and the abdomen immediately entered from above. Filling Douglas' sac almost completely was a tumor mass, evidently springing from the sigmoid flexure. This mass had rotated through an angle of 90 degrees and had become firmly embedded in the pelvis. It closely resembled a rectal cancer. It was carefully brought out, and an end-to-end anastomosis done. A portion of the descending colon was brought up into a small incision in the left inguinal region and made fast. It was necessary to make an artificial opening at this point on the fourth day. The patient made a satisfactory recovery.

Path. No. 7276. On laying the tumor open we found two rectal diverticula passing out into the adipose tissue and communicating with the lumen of the gut by openings not more than 1 mm. in diameter (Fig. 311). The larger diverticula

*Thomas S. Cullen, A Series of Mistaken Gynecologic Diagnoses, Jour. A. M. A., November 19, 1904.

lum was 1 cm. in diameter and filled with a fecal mass. Its floor had given way, and the surrounding fat was everywhere infiltrated with inflammatory products. The excessive hardness of the tumor was due to replacement of the fat in many places by recent connective tissue. The small abscess between the tumor and the pelvic floor was due to the extension of the inflammatory process to the peritoneum of Douglas' pouch. The diverticula were lined with atrophic mucosa. A rectal examination in this case would have yielded little beyond some narrowing of the lumen of the bowel, which is often present in cases of pelvic abscess.

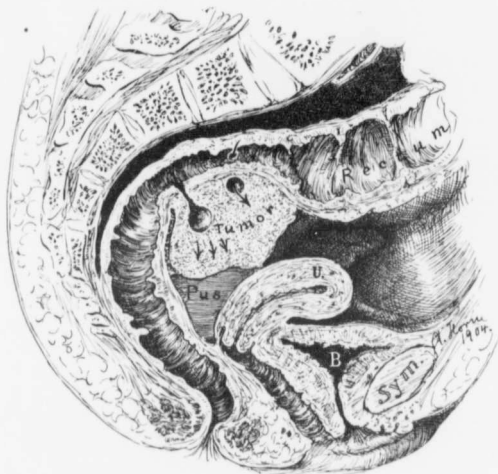

FIG. 311.—TUMOR OF THE SIGMOID FLEXURE DUE TO RUPTURE OF RECTAL DIVERTICULA INTO THE SURROUNDING ADIPOSE TISSUE; SMALL PELVIC ABSCESS.

Path. No. 7276. The lumen of the bowel below the promontory of the sacrum is considerably narrowed. At this point is a definite tumor made up of adipose tissue. Projecting into it are two diverticula, one seen in longitudinal, the other in cross-section. At the point indicated by the three arrows the diverticulum has given way, and its contents have percolated through the fat. This fat on histologic examination shows evidence of acute and chronic inflammation, which accounts for the denseness of the tumor. Between the tumor and the pelvic floor is a small abscess. The tumor was at first thought to be a myoma. (After Thomas S. Cullen.)

RETROPERITONEAL SARCOMA.

Retroperitoneal abdominal tumors are not common, but occasionally one is encountered which, in situation and form, simulates a myoma. In Fig. 312 is represented a large, lobulated growth, which occupied the lower abdomen, and which in general contour bore some resemblance to a myoma. The growth, however, was cystic, and the uterus was not enlarged. The patient understood English poorly, and consequently could not give a clear history of the development of the tumor.

Gyn. No. 9107. Path. No. 5265.

A. K., white. Admitted October 7; discharged November 9, 1901. The patient first noticed a tumor in the abdomen a few months ago. It has increased rapidly in size. For the past five weeks she has had severe pain in the left side of the abdomen. The patient is rather anemic and poorly nourished. The abdomen is greatly distended by a tumor, which is most prominent in the umbilical region and appears to be semieystic. It is irregularly nodular, and very

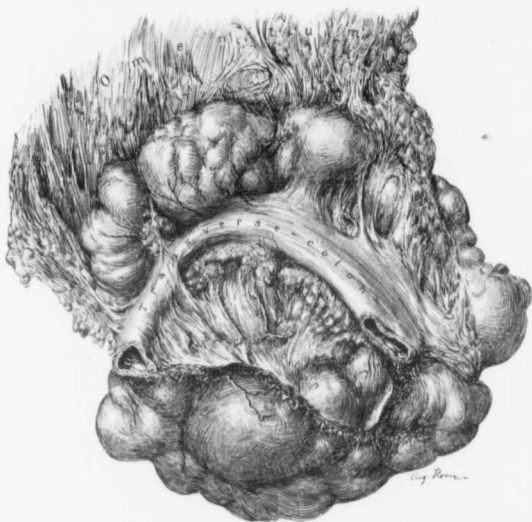


FIG. 312.—RETROPERITONEAL SARCOMA. (½ nat. size.)

Gyn. No. 9107. Path. No. 5265. The tumor was of rapid growth, and had developed behind the transverse colon, to which it was intimately adherent. It measured 15 x 23 x 25 cm. Above the transverse colon were large, sharply outlined, lobulated portions of the growth. The general contour of the tumor strongly suggested myoma, but its position and consistency excluded the possibility of a uterine origin.

freely movable. On vaginal examination no communication between the tumor and the uterus could be determined.

Operation (Dr. Hunner): The tumor proved to be a retroperitoneal sarcoma (Fig. 312) that lay beneath the transverse colon. It was necessary to resect a large portion of the colon with the tumor. The patient made a satisfactory recovery.

Path. No. 5265. The specimen consists of an oval-shaped tumor, 25 x 23 x 25 cm. To the lower border of the tumor is attached the omentum, and

across the surface of the tumor are 22 cm. of the transverse colon. On close inspection the tumor is seen to lie between two layers of the omentum, and is covered with peritoneum, except along the upper fifth, where it has been attached to the stomach. The tumor presents a dirty yellowish color, somewhat suggesting omental fat. Scattered throughout the omentum are numerous nodules. Some of these near the lower edge of the omentum are 1 cm. or more in diameter. On palpation the tumor is semifluctuant and appears partly cystic, but when cut into, the tissue seems for the most part to be homogeneous and resistant.

Histologically, the tumor consists of cells crowded together, with no definite arrangement. The shape and size of the nuclei vary considerably. Many giant-cells are present. Numerous thin-walled blood-vessels are scattered throughout the tissue. The tumor is a retroperitoneal sarcoma with omental metastases.

In the foregoing we have given merely a few examples of the difficulties occasionally encountered in making an accurate diagnosis. We have in one instance opened the abdomen on the supposition that the patient had a small and adherent myomatous uterus. A primary carcinoma of the right tube was found* with extension to contiguous parts. In another case a mass to the right of the uterus, and apparently continuous with it, seemed to be a myoma. At operation† it proved to be an inoperable carcinoma of the ovary which had spread out into the broad ligament and had apparently implicated the small bowel. On the other hand, we have on several occasions opened Douglas' pouch *per vaginam*, on the assumption that a pelvic abscess existed, only to find no abscess, but an adherent retroverted myomatous uterus.

The diagnosis of uterine myomata is, as a rule, easy; nevertheless, in a certain number of cases the real condition cannot be definitely established until the abdomen is opened.

* Thomas S. Cullen, Primary Carcinoma of the Right Fallopian Tube, Johns Hopkins Hosp. Bull., 1905, vol. xvi, p. 397.

† Thomas S. Cullen, A Series of Mistaken Gynecologic Diagnoses, Jour. A. M. A., November 19, 1904.

CHAPTER XXVIII.

THE EFFECT OF REMOVAL OF THE OVARIES ON UTERINE MYOMATA.

In the early days of the hospital hysterectomy was a more formidable operation than it now is, and when removal of the uterus was especially difficult, the ovaries were taken away in the hope that the tumor would gradually decrease in size, or at least remain dormant. In 25 cases only the tubes and ovaries were removed, and in 12 of these we have been successful in learning the subsequent history. From the accompanying table of the cases (page 505) we get some very interesting data.

In 4 of the cases no uterine bleeding was noted after operation. In Cases 1373 and 1405 it appeared once, and in Cases 182 and 516 three times. In Case 143 it was regular for a year, and in Case 213 bleeding occurred at irregular intervals for a year. In Case 1949 bleeding persisted at irregular intervals until the uterus was removed four years later. These figures tend to show that removal of the ovaries caused cessation of the bleeding, either at once or in the course of a year. It will be noted from the table, however, that in no case had the myomatous uterus reached large proportions.

In 10 of the cases the patients were completely relieved of their former pelvic symptoms. In Case 891 the patient's health five years later was "very bad." She had pain on defecation and micturition, and was exceedingly nervous. One patient (Case 1949) was readmitted to the hospital four years later, and the densely adherent myomatous uterus, which choked the pelvis, was removed.

We have from time to time heard of uterine myomata spontaneously disappearing or vanishing after removal of the ovaries, but have looked upon such reports with considerable incredulity. We have one case, however, where such a change evidently took place. On section of the abdomen in Case 143 the myomatous uterus completely filled the pelvis; both tubes and ovaries were removed. Two and a half years later the patient was examined. She had gained 40 pounds. The uterus was small, anteposed, and no trace of the myoma remained.

We now remove the myomatous uterus, wherever necessary, saving the ovaries if normal. The knowledge gained from these cases, however, certainly suggests the advisability of removing the ovaries, where feasible, in those cases in which hysterectomy is impossible.

EFFECTS OF REMOVAL OF THE OVARIES ON UTERINE MYOMATA.

GYN. NO.	AGE.	MENSTRUATION.	SIZE OF UTERUS AT OPERATION.	NUMBER OF YEARS SINCE OPERATION.	UTERINE BLEEDING SINCE OPERATION.	PRESENT SIZE OF UTERUS.	GENERAL HEALTH.
143	35	Almost constant bleeding for the past three months.	Pelvis completely filled.	2½	"Monthly sickness" about twelve times after operation; now no flow.	Uterus small, anteposed; no trace of myoma remains.	Good. Has gained 40 pounds; considers herself well.
182	37	Irregular.	Multinodular myomatous tumor.	2½	Slight bleeding at "period" for three months. (Examined by Dr. Kelly. Pelvic structures in excellent condition.)		Well.
213	39		Myoma on right side of uterus.	6	Irregular flow for one year.		Much benefited by operation; is still very nervous.
288	40	Normal.	Myoma, 10 cm. in diameter.	6	No flow since operation.		Health better than for nine years. Gained 50 pounds. Considers herself well.
516 } 615 }	35	Normal.	Pelvis choked with myomatous uterus.	5½	Three or four menstrual flows after operation.		General health perfect. Gained 25 pounds.
891	47	Flow gradually ceasing.	Uterus studded with small myomata.	5	No flow.		General health poor; pain on defecation and micturition; not benefited by operation.
939	35	Flow fairly free.	Uterus about 11 cm. in diam. (Size of fetal head.)	4½	No flow.		Gained 8 pounds. Has frequent micturition, but considers herself well.
1258	46	Flow gradually ceasing.	Uterus probably twice natural size.	4½	No flow.		Micturition still frequent, but patient was benefited by operation.
1373	38	Normal.	Myoma only a few cm. in diam.	4	One period after removal of ovaries.		Health good. Has gained 60 pounds. "Entirely cured."
1379	43	Profuse.	Myomata scattered over entire body of uterus.	4	None.		All old pains and discomforts have disappeared except those due to hemorrhoids.
1405	37	Profuse and offensive.	Two subperitoneal myomata, each about 5 cm. in diam.	4	One period after operation.		General health good. Has gained 15 pounds. Considers herself well.
1949	40	Profuse and painful.	Myoma about 11 cm. in diam. (Size of fetal head.)	4	Has had uterine hemorrhage at irregular periods.		Defecation painful, micturition frequent. Uterus removed (Gyn. No. 5317), densely adherent and choking pelvis (Path. No. 1774). Subperitoneal, interstitial, and submucous myomata.

CHAPTER XXIX.

ABDOMINAL MYOMECTOMY.

Any operation that has for its aim the conservation of the uterus instead of its removal must always be of particular interest to both surgeon and patient. We have carefully examined the cases admitted to the Johns Hopkins Hospital from the time it opened, in 1889, until July 1, 1906. In our consideration of the subject we have also included cases of patients operated upon at the Church Home and Infirmary, the Cambridge (Md.) Hospital, and the Frederick Emergency Hospital. In that period we have had 296 cases of uterine myomata in which the conservative method was adopted. In the following pages we shall give briefly the salient features, and then discuss fully the various complications accompanying or following immediately after operation. Those cases in which death occurred are reported in detail.

Letters have been sent to nearly all the patients, and it is interesting to learn the condition years after the myomectomy.

Myomectomy naturally falls into two main subdivisions:

1. Abdominal myomectomy.
2. Vaginal myomectomy.

Before proceeding to a detailed description of the operation and its various complications, we will partially outline the salient clinical features in cases requiring abdominal myomectomy.

Color.—Of the 296 patients, 250 were white and 46 were colored. Naturally, the whites outnumber the blacks, but the marked preponderance of white patients coming to abdominal myomectomy is due, in part at least, to the fact that in the colored the tubes are more frequently the seat of inflammatory trouble, which usually necessitates a hysterectomy instead of a myomectomy.

Age.—In all but 15 cases we have records of the age at the time of operation.

ABDOMINAL MYOMECTOMIES.

19 years of age	1 case
Between 20 and 30 years of age	43 cases
Between 30 and 40 years of age	137 "
Between 40 and 45 years of age	62 "
Between 45 and 50 years of age	19 "
Between 50 and 60 years of age	17 "
Between 60 and 70 years of age	2 "
Ages not recorded	15 "
Total	296 "

The youngest patient, who was nineteen years of age (Case 9637), had a small adenomyoma, 2.5 cm. in diameter, removed from the right uterine horn.

It will further be noted that at least 38 out of a total of 296 patients were over forty-five years of age, the oldest being sixty-six. This patient (Case 5279) had an intraligamentary myoma, 6 x 8 x 10 cm.

It is generally conceded that myomectomy is more dangerous than hysterectomy, and consequently, after the menopause, it is usually wiser to remove the uterus than to enucleate the myomata. There are, however, some exceptions. When there is only one myoma and this is attached to the uterus by a narrow pedicle, as in Case 9118, myomectomy is naturally the easier and safer operation. In looking back, it is always easy to see where one might have shown better judgment in the selection of the safer operation. For example, in Cases 1422, 5279, and 6047, myomata were enucleated from the broad ligament. In such cases we now know that it is very difficult to obliterate the resultant space, and hysterectomy is much safer. Again, in patients who have passed the climacteric no possibility of pregnancy or the preservation of the menstrual function exists to compensate for the increased risk.

Furthermore, we know that when many incisions are made into the uterus, the risk is materially increased, and yet in Case 5153 we removed 11 myomata through 7 incisions, and in Case 6395, 15 myomata were enucleated. Little is to be gained in saving such organs after the menopause.

In Case 5493 the nodule was a submucous myoma, and during its removal the uterine cavity was opened throughout its entire length. Here, likewise, the increased risk was in no way compensated for by the ultimate results.

Although myomectomy is always attended with an increased risk over hysterectomy, after the menopause the blood-supply of the uterus is much diminished, and the power of absorption from this organ lessened. This is shown by our results; every one of the 38 patients operated upon after the menopause recovered from the operation, and the greater number were perfectly well years after.

Single or Married.—Of the 296 patients that underwent abdominal myomectomy, 101 were single; 189 were married; in 6, data were lacking.

These figures are of only relative value, as the morals of some of the white as well as the colored patients were not above question.

The Relation of Uterine Myomata to Pregnancy.—In 90 of the myomectomy cases in married women during the child-bearing period we have definite data as to pregnancy. Of this number, 59 have had children. A few have been the mothers of large families, but in a large proportion only one or two children have been born. In 32 (35.4 per cent.) the patient had never been pregnant up to the time of entering the hospital. Our figures, therefore, favor the view that myomata may possibly cause sterility.

The Location of Myomata Removed by the Abdominal Route.—From a surgical standpoint, it seems advisable to divide the myomata into the following geographic groups:

1. Subperitoneal pedunculated myomata.
2. Interstitial (including those that are partly subperitoneal).
 3. Submucous (including those partly interstitial).
 4. Myomata of the broad ligament or intraligamentary myomata.
 5. Subvesical myomata.
 6. Cervical myomata.
 7. Adenomyomata.

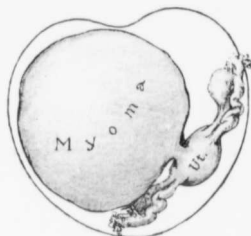


FIG. 313.—A PEDUNCULATED SUBPERITONEAL MYOMA.

GYN. No. 1950. The patient was forty years old. The uterus had been rotated to the left to accommodate the myoma, which was attached to the posterior surface of the uterus by a narrow pedicle. Abdominal myomectomy was performed. The patient made a good recovery. Fourteen years later she writes, "Health not good. Trouble not connected with operation," showing that no new myomata have developed. This is a case in which myomectomy is less dangerous than hysterectomy.

The myoma in Case 8310 was nearly as large as a uterus at full term. Its pedicle consisted of the fundus and cervix, and was 2 cm. in length. The cervix itself had been pulled high up toward the pelvic brim.

The myoma in Case 6781 was approximately 9 cm. in diameter, and almost completely enveloped in very vascular omental adhesions. The greater number of pedunculated myomata were freely movable.

In Fig. 313 we have an example of a large subperitoneal myoma that was easy of removal. The myoma represented in Fig. 314, on the other hand, was attached to the uterus over a broad area. It was difficult to decide whether the myoma alone should be removed, or whether a hysterectomy would be the safer procedure. Myomectomy was done, and the patient was in good condition sixteen years later.

Interstitial Myomata.—The majority of myomata are intersti-

In all but 25 of the 296 cases we have definite data as to the location of the myomata. In some instances subperitoneal pedunculated nodules, interstitial tumors, and submucous myomata were removed from the same organ.

Subperitoneal Pedunculated Myomata.—In 49 cases pedunculated myomata were removed, and in at least 8 of these cases interstitial myomata were also enucleated.

In Case 7220 the myoma measured 14 x 19 cm. It had rotated on its pedicle from right to left through an angle of 180 degrees, and was covered with dense vascular omental adhesions. (See Fig. 18, p. 22.)

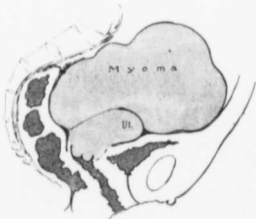

FIG. 314.—A LARGE SUBPERITONEAL MYOMA.

GYN. No. 1112. The myoma rises high out of the pelvis and is attached to the posterior surface of the uterus by a rather broad pedicle. Abdominal myomectomy was performed, and the patient reported that she was in very good health sixteen years later.

tial in their incipiency and gradually become subperitoneal or submucous. Consequently, we should expect the greater number operated upon to be of the interstitial variety, and such proved to be the case. All partially subperitoneal myomata are, to a great extent, interstitial, and as the operative procedure in both instances is the same, we find it wiser to include them in the same group. In 202 of the 296 cases, that is, in about 70 per cent., interstitial myomata were removed.

Submucous Myomata.—In 20 cases submucous myomata were removed. Sometimes it is possible to remove the myoma without opening the uterine cavity, but in others the myoma encroaches so upon the cavity that its removal is impossible without entering the cavity to some extent. The accompanying table gives the essential features in all the cases in which submucous myomata were found.

SUBMUCOUS MYOMATA REMOVED PER ABDOMEN.

TABLE SHOWING WHETHER UTERINE CAVITY WAS OPENED OR NOT DURING OPERATION.

NOT OPENED.	MODERATELY OPENED.	WIDELY OPENED.	HYSTEROTOMY.	BISECTION.
Case 5452: Seventeen myomata, some submucous. Cavity not opened.	Case 7025: Myoma, 9 cm. Uterine cavity opened; opening just large enough to admit uterine sound.	Case 4297: Myoma, 5 x 6 x 7.5 cm. Cavity widely opened.	Case 7029: Sessile submucous myoma, 2 x 2 cm.	Case 10351: Uterus bisected, 21 myomata removed. Uterus sewed up. Myoma, 1 to 1.5 cm. in diameter. Death.
Case 5614: Submucous myoma, 5.5 cm. Mucosa projected into wound, but uterine cavity not opened.	Case 9197: Interstitial nodule, small submucous, 2 x 1.5 x 1.5 cm. high in fundus, removed.	Case 4844: Myoma 3.5 cm.	Case 8726: Subperitoneal, interstitial myomata; 2 small submucous; removed by hysterotomy.	
Case 12852: Dermoid of ovary, 2 uterine myomata, small (1 partly submucous).	Case 10479: Submucous myoma, 1 cm.	Case 5447: Myoma, size of 4 months' pregnancy.		
	Case 65: Myoma filling pelvis. Uterine cavity opened; death.	Case 5493: Myoma, 6 cm. Entire length.	Case 8844: Interstitial, 4 cm. Hysterotomy to examine mucosa.	C. H. I., B.: Myoma, 7 cm. in diameter; lower third of uterus saved. C. H. I., B. 1019: Partly submucous myoma, 10 x 10 x 10 cm. Half of cavity saved.
		Case 7159: Uterus size three and one-half months' pregnancy. Myoma, one-half submucous. Case 10394: Submucous myoma, 7 cm., friable. C. H. I., S.; Path. No. 6771: Myoma, 10 cm. One-third covered with mucosa.		

In 3 cases it was possible to enucleate the partly submucous myomata without opening the uterine cavity. In 4 cases the uterine cavity was only slightly or moderately opened, and in 7 cases the cavity was explored for nearly its entire length. In 3 cases the uterus was deliberately split open to see if myomata were present, and in 2 out of the 3 myomata were detected.

Hysterotomy, or splitting of the uterus, has been frequently employed by our colleague, Dr. W. W. Russell, with excellent results. In Case 10351, however, a very large uterus was bisected, and 28 myomata were removed from various parts of the wall. The uterus was then sewn together again. The patient died. Complete details of her case are found in on page 537.

In C. H. I., B., one-third of the uterine cavity was saved, and the patient menstruates regularly. In C. H. I., 1019, in which a partially submucous myoma, 10 x 10 x 12 cm., was present, half of the uterine cavity was saved. The menses ceased about six months later, possibly partly as the result of a marked cardiac lesion.

Myomata of the Broad Ligament.—Seven out of 296 abdominal myomectomies were for myomata of the broad ligament, which sometimes occurred alone, and in other cases associated with interstitial or pedunculated nodules. The intraligamentary myoma is usually easily removed, but if there is much oozing, there is great danger of an accumulation of blood between the peritoneal folds, and this later may become infected, giving rise to a broad-ligament abscess, as happened in Case 5359 (p. 553).

Subvesical Myomata.—Subvesical myomata are not uncommon, but are usually associated with other myomata, and in such cases hysterectomy is the safer operation. Two of our abdominal myomectomies were done for the removal of subvesical nodules.

In Case 5332 a subvesical myoma, 8 cm. in diameter, was removed, and the patient was perfectly well ten years later.

In Case 6762 a subvesical nodule, 6 x 6 x 7.5 cm., was removed. Retention of urine required catheterization up to the twenty-third day. An annoying cystitis persisted for over two years, and now, eight years after operation, is much better, but apparently the patient has *tuberculous dorsalis*.

Cervical Myomata.—Cervical myomata that cannot be enucleated per vaginam are usually so hard to get at from above on account of their proximity to the uterine artery and ureter, and from the difficulty of obliterating the resultant space, that hysterectomy is generally the easier procedure. In two of our cases single cervical myomata have been removed per abdomen.

In Fig. 315 we have an example of a myoma that was attached to the uterus so low down in the cervical region that its removal occasioned much difficulty.

In Case 1033 a small cervical myoma, 1.5 x 2 cm., was removed from the posterior surface of the cervix. Nine years later (No. 8415) the uterus was removed on account of multiple myomata.

Case G., in which a large cervical myoma with part of the vaginal mucosa

was removed per abdomen without interrupting the four months' pregnancy, is reported in detail on p. 531.

In one of our early cases (No. 1329) a myoma, 5 cm. in diameter, was removed from the fundus, but instead of attempting to enucleate a cervical myoma, 8 cm. in diameter, we removed the ovaries. Of course, with our present knowledge we would do a hysterectomy and save the ovaries.

Adenomyomata.—In five cases diffuse or discrete adenomyomata were removed from the uterine wall. We have made a separate division of this variety, because in the majority of these cases the myoma is so intimately connected with the uterine wall that it cannot be peeled out and must be cut away. In Cases 3600, 4415, and 12036, it was necessary to cut out a wedge of the uterine wall to remove the growth. In cases 9024 and 12585 the myomata were more circumscribed and could be dissected out. All these cases are dealt with in detail in "Adenomyoma of the Uterus."

Size of the Myomata Removed.

—In the 296 cases we have included practically every case in which myomata were removed, no matter how small or how large. As seen from the records of the deaths, the removal of even small nodules may prove fatal.

Pedunculated Myomata.—In the following cases large pedunculated myomata were removed: in Case 9118 a subperitoneal nodule, 16 x 16 x 22 cm.; in Case 5826, a myoma 15 x 18 x 20 cm.; in Case 5086, a myoma 17 x 29 x 29 cm., and in Case 1672 a subperitoneal nodule, 30 x 34 cm. In all probability the largest subperitoneal nodule ever removed was from Case McA. (see Fig. 317, p. 514). The tumor weighed 89 pounds, and was attached to the uterus by a pedicle only a few centimeters in diameter.

Interstitial Myomata.—The interstitial tumors, of course, do not reach such large proportions. In Case 4055 an interstitial myoma, 10 x 10 x 21 cm., was removed; in Case 11256 one 15 cm. in diameter. In C. H. L. W., the tumor measured 16 cm., and in Case 4925, 12 x 21 x 27 cm. In the last case hysterectomy followed a few years later on account of the appearance of other myomata. (See Fig. 331, p. 562.)

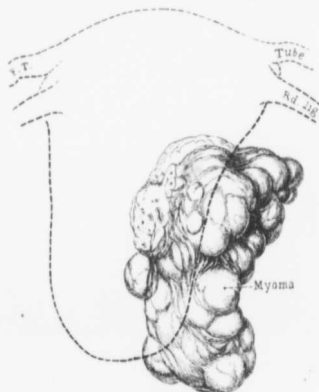


FIG. 315.—A DIFFICULT MYOMECTOMY.

Gyn. No. 8389. Path. No. 4576. At the junction of the cervix and fundus was a myoma about 7.5 cm. long. It was exposed with difficulty and removed. After operation the patient developed a severe cystitis. Six years later she was perfectly well.

Submucous Myomata.—Myomata of this variety are relatively small. In our group they varied from 1 to 10 cm. in diameter, the average being about 5 cm. In Case 5447 the myoma reached about 9 cm. in diameter and in C. H. L. S., 10 cm.

Successful Removal of a Pedunculated Eighty-nine Pound Cystic Myoma Intact.*

As will be noted from the following history, this patient was cognizant of the fact that the tumor had existed for over twenty years. At that time she was under the care of Dr. James Bosley. Further, it will be seen that this large growth did not prevent her from looking after her household duties until a short while before admission, and less than three months before the operation she had taken a 180-mile trip with no ill effects. This, so far as we can learn, is the largest myoma of the uterus that has been successfully removed. The patient is now, two and one-half years after the operation, in perfect health.

McA. Path. No. 10382.

Mrs. McA., aged fifty-eight, was seen by one of us (Cullen) in consultation with Dr. Marshall Smith, June 25, 1906.

History.—Twenty years ago she noticed a tumor in the lower abdomen, and later was seen in consultation with Dr. W. T. Howard, who at that time advised an operation. Some time after this she was delivered of a healthy child, now eighteen years of age. This patient, although suffering from a large abdominal tumor, was able to go around and to do her work until three weeks before I saw her. Her chief inconvenience had been her inability to lie on her back in bed. And sometimes when she would get "stalled," it was necessary for her husband to turn her over quickly, otherwise she would have suffocated. For two weeks before admission she had a temperature sometimes reaching as high as 103°. She was admitted to the Church Home and Infirmary July 27, 1906. There was considerable edema of the lower part of the abdomen and some edema of the legs. On admission to the hospital her temperature was 100° F.; pulse, 105. On the morning of operation the temperature was 100° F.; pulse, 100; respiration, normal.

Operation, July 30, 1906: Prior to receiving the anesthetic the patient was thoroughly washed and all preparations for operation were made, so that she might remain as short a time as possible under ether. It was impossible for her to lie down, consequently she was operated on in the sitting posture. An incision was made over the most prominent part of the tumor, and I attempted to puncture it; the growth, however, started to bleed, and no cyst fluid escaped. I continued the incision upward, for the reason that many large veins projected into the tumor from some structure above. The incision was gradually continued upward until the xiphoid process was reached (Fig. 316). We found that the large vessels going to the tumor were omental in origin, and were spread out over the entire upper surface. Some of them were fully 7 or 8 mm. in diam-

*Thomas S. Cullen, A Series of Interesting Gynecologic and Obstetric Cases, Jour. A. M. A., vol. xlviii, May 4, 1907.

eter. The tumor was densely adherent to the anterior and to the lateral abdominal walls. These adhesions were gradually shelled off with the hand, but I had to use the utmost care and do all liberating under sight, as the rupture of one large vein might have caused death before the hemorrhage could have been checked. Accessory vessels also passed from the stomach and the liver to the tumor. The pedicle of the tumor was not more than 1.5 cm. in diameter, and was situated directly beneath the ribs. On removal of the tumor I found that I had brought away a piece of liver tissue 3 cm. in diameter. We had no liver needles handy, so I used sharp Hagedorn needles, running the eye through instead of the sharp end. This device answered admirably, and the liver bleeding was

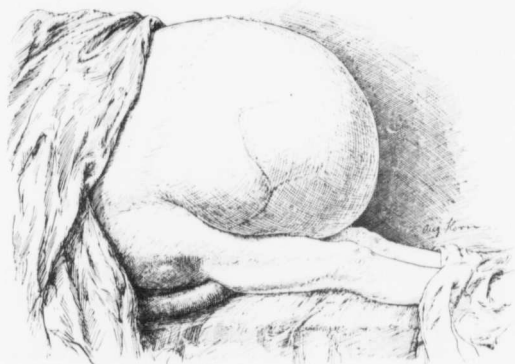

FIG. 316.—ABDOMINAL ENLARGEMENT DUE TO A CYSTIC MYOMA.

The abdomen is markedly and uniformly distended, and the growth extends down almost to the knees. It will be noted that there is no sagging in the flanks. Coursing over the surface were very large vessels. When it is realized that the abdominal incision extended from the xiphoid cartilage down over the entire length of the tumor, and then back to the symphysis, it is readily seen that the wound was nearly 4 feet in length. (After Thomas S. Cullen.)

easily checked with four catgut sutures. The uterus and the right tube and ovary lay under the surface of the liver. Anticipating the possibility of great difficulty in controlling the tumor, we had, prior to operation, sterilized a large foot-bath and covered it over with a sterile sheet. The foot-bath held about one-third of the tumor, and the person who took charge of it was able to guide the tumor in the desired direction without allowing it to slip from his grasp. The tumor was drawn downward and outward, and finally delivered from the abdomen. In the lower part it was extraperitoneal. I closed the abdomen, but left a small cigarette drain in the extraperitoneal pouch just over the symphysis.

Postoperative history: The patient stood the operation well, but was com-

mencing to collapse by the time we finished. She was under ether for one hour and twenty minutes; 200 grams were used. The operation, from the incision to complete closure, took fifty-five minutes; a much longer time would have been consumed had it not been for the combined assistance of both the Johns Hopkins and Church Home staffs. The patient's temperature rose to 102.2° F., within eight hours after operation, but had dropped to 100° F. by evening. The highest pulse-rate was 130. There was no postoperative vomiting. The legs were bandaged on account of the edema. The patient voided urine on the evening of the day of operation. She was catheterized only once. The usual after-treatment was employed. On the fourteenth day she had considerable discomfort from frequent stools. The diarrhea persisted off and on for a couple of weeks. At this time, however, the weather was excessively hot, and diarrhea was general throughout the hospital. It affected chiefly those patients who were somewhat weak. The patient, on admission to the hospital, weighed 174 pounds. Twenty-three days after operation she weighed 80½ pounds. The condition of the abdomen in this case was particularly interesting. I did not even resect a portion of the abdominal wall, because we had to save as much time as possible during operation. At the first dressing it was noted that the ribs extended out fully 6 inches from the abdomen, and that the recti muscles lay on the bed on either side, while there was a good deal of loose and wrinkled skin covering the abdomen. Another interesting point was that the gauze, which drained the extraperitoneal pocket just at the symphysis, now lay in the middle of the abdomen, as the tissues were gradually contracting. After the lapse of two weeks the recti muscles could be felt gradually contracting and coming in, and the costal arch was flattened down to some extent. When I examined her six weeks after operation the recti muscles were well up in the abdomen, being not over 10 cm. apart. The skin had contracted down wonderfully. The pendulous skin over the symphysis had retracted to a marked extent, and the ribs were almost in their normal position. At the time of operation there was a good deal of edema of the abdominal walls. There was also edema of the legs and of the buttocks. Although the utmost care was used, a bedsore developed several days after the operation, there being a black slough 6 cm. in diameter over the sacrum, and surrounded by a faint red halo. It had resulted from pressure on the table. The patient had had marked edema of the back, but was forced to sit up during almost the entire operation. After she went home she rapidly regained her strength. The bedsore gradually diminished, and in time entirely healed. It is astonishing that she had so little inconvenience after the operation.

FIG. 317.—CROSS-SECTION OF A CYSTIC MYOMA WEIGHING 89 POUNDS. (½ nat. size.)

The pedicle is clearly seen, and in the fresh specimen was not over 1.5 cm. in diameter. Attached to the top over the pedicle are the tube and ovary, and near the tube is a piece of liver substance. The tumor has been converted into one large cavity, the walls of which consist of muscle. In the walls are numerous cystic spaces, particularly well shown at the points indicated by a. There are several large cystic dilatations in the wall. The largest is indicated by b. The myomatous walls vary from 5 cm. to 1 or 2 mm. in thickness. At the point c, where the tumor lay over the vertebral column, the wall is exceedingly thin. The entire inner surface is lined with partly organized blood-clots, which give the growth a very shaggy appearance. The entire tumor was filled with blood. The outer surface is in many places covered with adhesions containing large vessels.

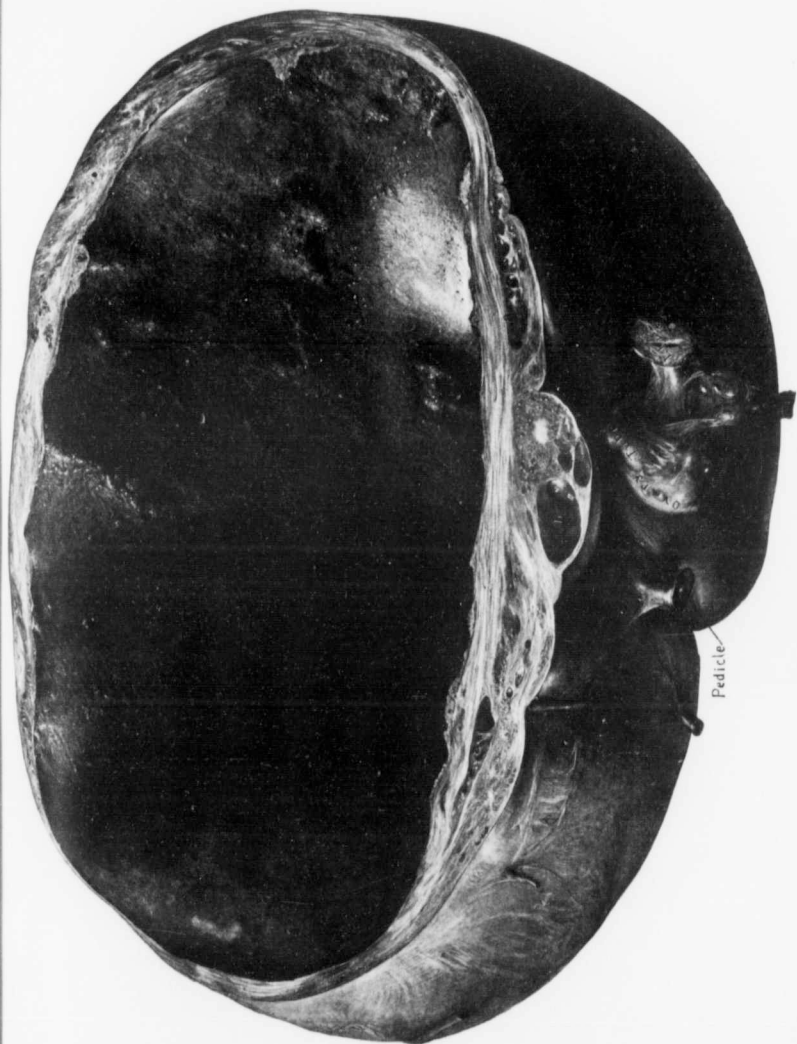


FIG. 317.

Description of Tumor.—Path. No. 10382. Miss N. Ellicott, superintendent of nurses, weighed the tumor immediately after its removal; the net weight, after deducting that of the vessel in which it lay, was exactly 89 pounds. The thin part lay posteriorly, otherwise we might have evacuated the tumor. Had we done so, however, it would have been much more difficult to have gotten at the large vessels, which we encountered at almost every point. Had this condition persisted much longer, the posterior wall of the tumor would certainly have

given way, and then operation would have been almost out of the question. As it was, the hardened specimen collapsed of itself when placed on the table.

Macroscopic Examination.—The hardened specimen is about 50 cm. in length, 45 cm. in breadth, and approximately 25 cm. in thickness. Over the entire anterior surface and laterally are numerous adhesions. Attached to the upper border is an area of omentum 20 cm. in breadth, and the hardened vessels range from 5 to 6 mm. in diameter. The pedicle of the tumor is 1.5 cm. in breadth, 1 cm. in thickness, and the portion removed is 1.5 cm. in length. Situated just beneath the pedicle, and attached to the surface of the ovary, is a piece of

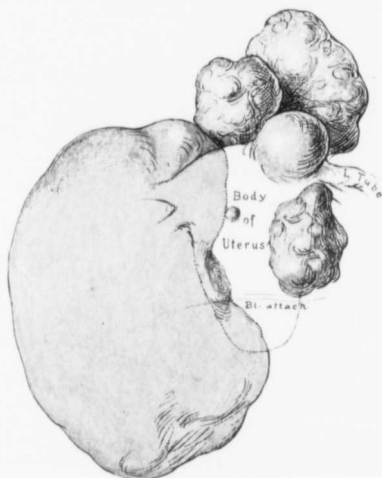

FIG. 318.—MULTIPLE MYOMECTOMY.

GYN. No. 8462. From this uterus 13 myomata were enucleated. The large kidney-shaped tumor on the right measured 7 x 7 x 14 cm. Practically all the myomata seen were removed, with little injury to the uterus. Six years later the patient reported that her general health could not have been better. Prior to the operation she had frequent micturition and a troublesome pruritus ani, which had persisted over two years, but was completely relieved by operation.

liver substance 3 by 2 cm. (Fig. 317). On pressure the tumor in part seems to be solid, in part cystic. At operation, when I attempted to puncture the tumor, nothing but blood was encountered. The growth is, however, evidently made up of one large cystic space and numerous smaller ones, together with the semisolid area. Over the part that is cystic the muscle-fibers have been greatly stretched and thinned out, and there are little hernial projections, the picture being analogous to that found in a slightly sacculated urinary bladder. On section the greater part of the tumor is found to consist of one cavity, which

is approximately 42 by 35 cm. The walls vary from 2 mm. to 5 cm. in thickness. Only at one point is the wall very thin, namely, on the under surface, where it lay over the vertebral column. The greater part of the wall consists of simple myomatous tissue, but at numerous points small cystic areas are visible, and the tissue has undergone the characteristic hyaline transformation. One of the cysts measures 2 by 3 cm. The inner surface is covered with blood, and the greater part of the tumor is filled with blood which has undergone coagulation during the hardening.

Microscopic Examination.—On histologic examination the growth is seen to be made up of typical myomatous tissue. In many areas hyaline transformation has taken place and at some points there is typical liquefaction. The inner surface of the cyst has no epithelial lining; it is covered with blood which is faintly organized.

Number of Myomata Removed by Abdominal Myomectomy.—In the greater number of the cases the uterus contained only one myoma, and that was interstitial. In several instances, however, several tumors were enucleated. For example, in U. P. L. S., and C. H. L. H., 9 myomata were removed. In Case 4365, 10 myomata; in Cases 5153 and 10300, 11 myomata, and in Cases 8773, 6395, and 5452, 13, 15, and 17 myomata, respectively, were shelled out. In Case 8462 (Fig. 318) 13 myomata were removed. The patient six years later was well. The greatest number removed in any one of our cases was furnished by Case 10351. The uterus was split, and 28 myomata, varying from 1 to 1.5 cm., were removed. The patient developed marked abdominal distention, and on exploration free blood and clots were found in the abdomen. Death occurred on the fifth day. The case is reported fully on p. 537.

After adding up all the myomata removed and then striking an average, we find that if they had been evenly distributed, each uterus would have contained a fraction over two myomata.

CONTRAINDICATIONS TO MYOMECTOMY.

Low Hemoglobin.—In three of our cases in which abdominal myomectomy was performed the hemoglobin was very low, and it is interesting to follow the progress of the individual cases.

In Case 9629 the patient was twenty-seven years old and had a hemoglobin of 23 per cent. A large interstitial myoma necessitated an incision into the uterus 13 cm. long. The patient made a slow convalescence, owing to her anemia, but there were no complications.

In Case 10573 the patient, aged twenty-seven, had a rough apical systolic murmur transmitted faintly to the axilla. There was also a marked systolic murmur over the pulmonic area; hemoglobin, 38 per cent. A myoma, 10 cm. in diameter, and several smaller ones, were enucleated. The patient developed phlebitis of the left saphenous vein on the seventeenth day. It did not retard

her progress materially, however, as she was discharged on the twenty-fourth day.

In Case 10257 the patient was twenty-three years old, and the hemoglobin 47 per cent. Prior to suspension of the uterus an interstitial myoma, 1 cm. in diameter, and another smaller one, were removed. Convalescence was normal, and since then the patient has had two normal labors.

Syphilis.—When syphilis exists, the question naturally asked is, Will the wound heal if an abdominal operation is performed? In Case 11169 a colored woman, aged forty-six, had marked relaxation of the outlet, prolapsus of the uterus and a myoma, and also a syphilitic ulcer of the leg. The cervix was amputated, the perineum repaired, a myoma 4 cm. in diameter shelled out of the fundus, and the uterus suspended. The patient made a perfect recovery, and was transferred to the surgical department, where the ulcer was skin-grafted. She left the hospital on the forty-seventh day. The syphilitic taint in this case certainly in no way retarded convalescence.

ABDOMINAL MYOMECTOMY.

General Considerations.—Before undertaking an abdominal operation for uterine myomata several points should be thoroughly weighed. In the first place, it is generally agreed that, as a rule, hysterectomy is safer than myomectomy. On the other hand, it is the surgeon's duty to save the pelvic organs whenever feasible.

Age.—If the patient is under forty-five years of age, the possibility of a subsequent pregnancy should always be borne in mind.

Condition of the Patient.—When the patient is very anemic and otherwise frail, as a rule, a myomectomy is hazardous, and the possible gain by saving the uterus would be more than balanced by the liability to a fatal outcome. In every case the advantages and disadvantages of each operation should be thoroughly discussed, and explained to the patient or some responsible relative.

Under no circumstances should the surgeon undertake the operation unless the patient freely consents that the operator shall do exactly what he deems wise when the abdomen is opened, as it is usually impossible to tell with absolute certainty just what should be done until the uterus is exposed. One patient coming for operation was so strenuous in her opposition to hysterectomy that she exacted a promise from one of us (Cullen) that nothing more than a myomectomy should be done. On opening the abdomen we saw clearly that hysterectomy would be the safer operation, but our hands were tied by the promise, and many myomata were enucleated. This patient (Case 10588), within twenty-four hours, developed fever and died at the end of forty-eight hours. There was no hemorrhage into the abdominal cavity, and the cultures were negative. Since then we have absolutely refused to operate unless the matter is left to the best judgment of the operator.

Points to be Considered after the Abdomen has been Opened.—As soon as the uterus is exposed, the appendages should be carefully examined. Should pus-tubes be present, it will be necessary to remove them at once, and if this can be accomplished without the escape of any pus, myomectomy may be considered. Should pus escape, however, there is always a risk of infecting the cavities made in the uterus if myomectomy be done.

Next, the location and number of the myomata are of importance. Sub-peritoneal and pedunculated nodules are easy of removal. Interstitial myomata, if of small size and few in number, are also enucleated without much difficulty.

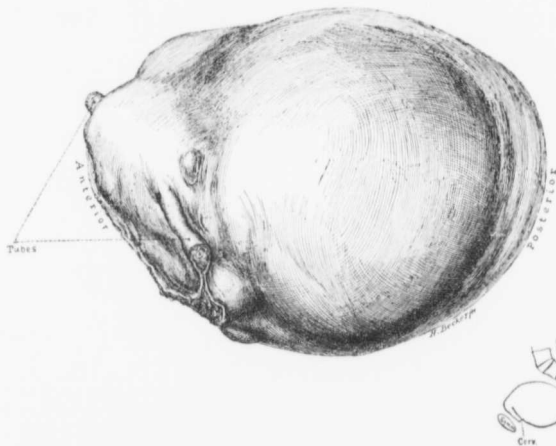

FIG. 319.—MYOMECTOMY OR HYSTERECTOMY.

In such a case it may be possible to shell out the large myoma occupying the posterior wall and the several smaller ones, saving the uterus. The myoma has, however, extended so far downward toward the cervix that it would have been very difficult to accurately close the myomectomy wound. Unless the patient were very young and the necessity for children of the utmost importance, hysterectomy would be the wiser operative procedure, as it offers the patient much greater chances of recovery.

It has been our experience that the more the uterus is mutilated, the greater the danger to the patient. Where many interstitial myomata are removed, the uterus is lacerated in all directions, and it is not only difficult to completely check oozing, but the area for infection is very great.

The same applies when a very large interstitial myoma is enucleated. For example, in Case 4925 an interstitial myoma, 12 x 21 x 27 cm., was removed, and 50 catgut sutures were required to obliterate the cavity and approximate the uterine surfaces. Notwithstanding the fact that our patient made a good recovery, in future we would hardly advise such an operation unless the pos-

sibility of issue was of the greatest importance. We have removed myomata when as many as 70 sutures were required to obliterate the cavity.

If the clinical signs strongly point to submucous myomata, the operator should be exceedingly cautious in recommending abdominal myomectomy. Opening up occasions no trouble, as noted in

Cases 5447 and 5493, in which

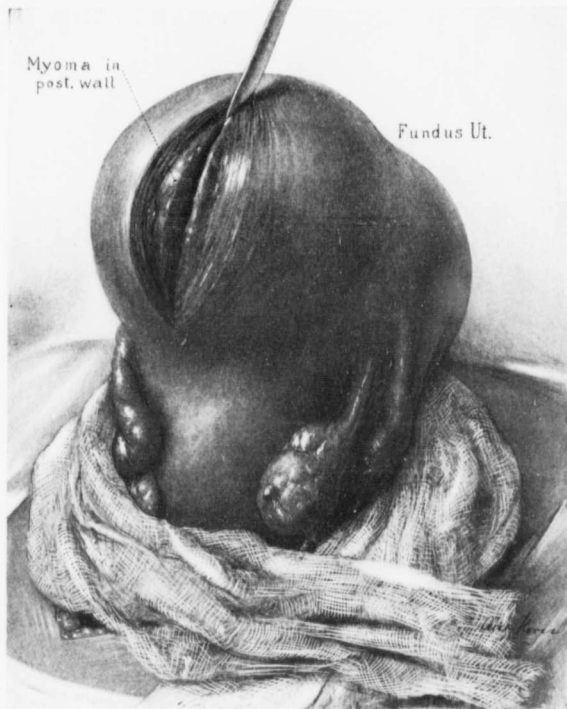


FIG. 320.—THE FIRST STEPS IN ABDOMINAL MYOMECTOMY.

The uterus has been lifted out of the abdomen and is surrounded with gauze. The tubes and ovaries are normal. The myoma in the posterior wall has been exposed and incised for a short distance.

the cavity was opened up for its entire length. It is sometimes almost impossible for the operator, however, to tell with certainty whether the endome-

trium is normal or infected, and if infected, there is a great danger that the infection may spread to the wound in the uterine wall.

When large interstitial myomata are present or when many small nodules are found, the uterus itself, after the myomectomy, is occasionally fully two or three times its natural size; consequently the tendency to absorption is markedly increased.

In Fig. 319 we have an example of a border-line case—a case where it is difficult to determine whether a myomectomy or a hysterectomy should be performed. The uterus contains but one large myoma, and this does not apparently encroach upon the uterine cavity. On the other hand, it extends far down into Douglas' pouch, and after myomectomy it would be difficult to effectually obliterate the resultant space. In this case, while myomectomy was feasible, hysterectomy as carried out was undoubtedly the safer procedure.

Removal of Pedunculated Myomata.—If the pedicle is very small, it is only necessary to cut it in such a way that in the uterus a wedge-shaped cavity is left. If there are any large blood-vessels, they can be picked up free hand and tied with catgut and the shallow cavity obliterated with catgut.

Subperitoneal, pedunculated myomata are occasionally enveloped in omentum. If the omental adhesions are limited to the anterior surface of the myoma, the omentum should be tied and cut. Care should be exercised because such omental vessels are often very large and friable, and if torn, bleed tremendously. When the nodule is enveloped in adhesions, it is often wiser to cut the pedicle and attack the adhesions from the under surface.

When the myoma is densely adherent to the sigmoid, as in Case 7978, it is wise to sacrifice the outer layers of the tumor, leaving them attached to the bowel. In the case in question a thin layer of tumor, 10 cm. in length, was left on the bowel. After removal of the tumor this raw area was turned in on itself and sutured, a smooth surface resulting.

Removal of Interstitial Myomata.—The removal of small interstitial myomata is easy. An incision is made over them (Fig. 320), they are grasped with the mesoforceps, and peeled out with a knife-handle or some other blunt instrument (Fig. 321). Should two or three be near one another, they can often be brought out through the same incision, thus minimizing the possibility of subsequent adhesions.

When a large interstitial myoma is present, an oval or elliptic incision is usually made over the tumor. It is always better to be on the safe side and not remove too large an area of the uterine wall with the myoma, as after removal



FIG. 321.—KELLY-CULLEN MYOMA ENUCLEATOR.

of the myoma the uterine muscle frequently retracts to such an extent that it is




FIG. 322.—SHELLING THE TUMOR OUT OF THE UTERINE WALL.

The myoma is firmly grasped with the mesoforceps and strong traction made. The tumor is being shelled out by means of the myoma enucleator.

difficult to bring the tissues together and obliterate the dead space. On the other hand, it is easy to cut away the excess from redundant uterine flaps.

The myoma is grasped with a strong mesoforceps and gradually shelled out with a myoma enucleator (Fig. 322), a pair of curved artery forceps, a knife-handle, or a blunt periosteal elevator. Care should be taken to avoid getting

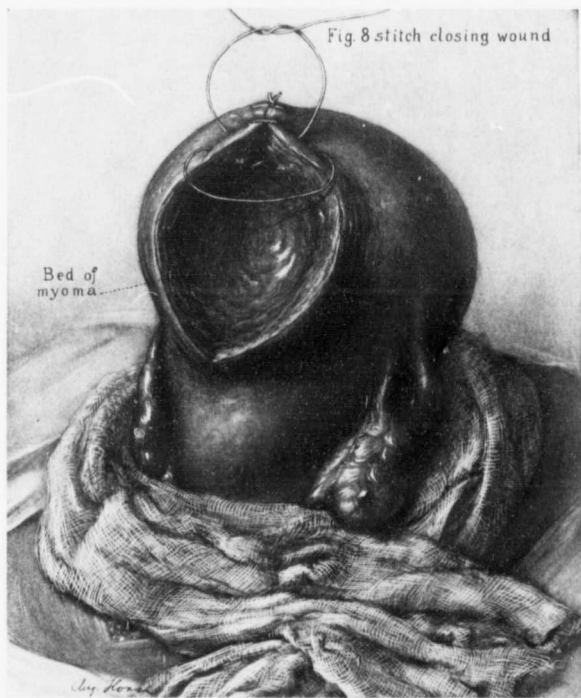


FIG. 323.—OBLITERATION OF THE SPACE IN THE UTERINE WALL AFTER REMOVAL OF THE MYOMA.

One figure-of-8 catgut suture has been introduced and tied. The second has just been inserted. It is important to accurately coapt the surfaces, leaving no dead spaces. When the cavity is large, two or three tiers of sutures may be necessary in addition to tying any large vessels.

into the uterine cavity, if possible; but, where necessary, it may be fully opened up.

Submucous Myomata.—Many large interstitial myomata are partly submucous, and then it may be necessary to bring away a large area of the mucosa covering the myoma. This should be cut away boldly but carefully with the knife.

Sometimes where there is marked uterine hemorrhage but a small uterus, hysterotomy is done, the first incision going directly into the uterine cavity. This is then explored for small myomatous nodules, which often give rise to alarming hemorrhage.

If the uterine cavity is opened, after the removal of large nodules it is usually wise to dilate the cervix from above to allow for free drainage for several days

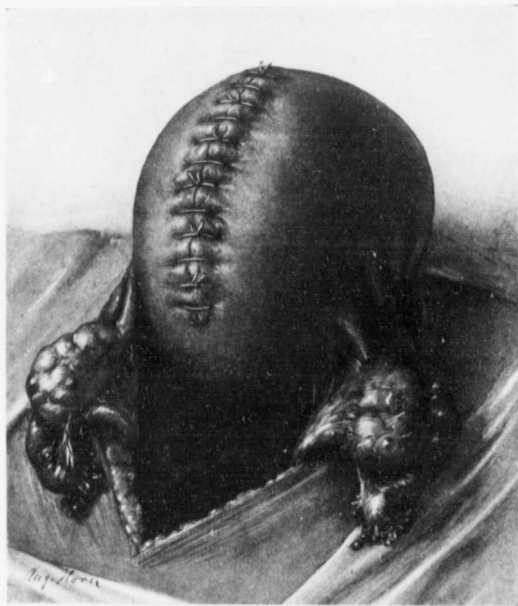

FIG. 321.—APPEARANCE OF THE UTERUS AFTER ABDOMINAL MYOMECTOMY.

The uterus is still considerably enlarged. Accurate approximation has been accomplished. By employing a figure-of-8 suture, only half as many knots are necessary, and thus there is a diminished liability to adhesion.

at least. Whether a small gauze drain should be left in the uterus with its low end projecting from the cervix is still a mooted question. We have employed it in several cases.

The sutures are now introduced into the depth of the wound. They extend to, but do not pierce, the mucosa. When these are tied the uterine cavity is closed.

In the early days we employed silk, but now catgut is used in all myomec-
tomies. The cavity in the uterine wall is gradually obliterated with tier after tier
of figure-of-eight catgut sutures (Fig. 323) introduced with a curved needle with
rounded edges, and finally the surfaces of the uterus are approximated as ac-
curately as possible, and yet with just sufficient pressure to check bleeding (Fig.
324). Ochsner lays special stress on not tying the sutures too tight, as the
tissues may be so blanched that they become incapable of resisting the slightest
infection. One must, however, completely obliterate the spaces formerly occu-
pied by the myomata.

Tearing of the Uterine Artery during Abdominal Myomectomy.—In Case 6773 both ovaries were released from light ad-
hesions, and two interstitial myomata, each about 4 cm. in diameter, removed.
One of the tumors lay very close to the uterine artery. This vessel was torn
during the enucleation and ligated near the cervix. The uterus was then sus-
pended.

Suspension of the Uterus after Myomectomy.—One of the greatest drawbacks
to a myomectomy is the fact that one or several lines of sutures are bristling
from the surface of the uterus and, so to speak, are inviting the omentum or
intestine to become adherent. If the suture line be in the anterior wall of the
fundus, it can be effectually hidden by attaching the uterus to the anterior
abdominal wall. If fastened to the anterior wall, firmer union is liable to take
place than if no myomectomy had been performed, and a subsequent pregnancy
may lead to serious trouble, as in Case 4856 (p. 567). If the uterus is suspended
with catgut instead of silk, the union, as a rule, is not so firm. In any event we
would infinitely rather take the chances of dystocia than of intestinal obstruction
from adhesions, especially when, at any time during the course of a subsequent
pregnancy, by a very simple exploratory laparotomy, the adherent uterus
may be readily freed, as has recently been pointed out by Dr. Elizabeth Hurdon*
and others.

Covering over the Incision in the Uterus with the Broad Ligament.—When the tissues are lax, it may be possible, as was
done in Case 12852, to draw portions of the broad ligament over the fundus,
thus completely hiding the suture line.

Preservation of a Portion of the Fundus.—When the myoma occupies nearly
the entire fundus, rendering an enucleation difficult, it may still be possible, by
amputation, to save a portion of the mucosa. This plan was adopted in cases
C. H. I. 930 and in C. H. I. 1019.

In Case C. H. I. 1019 the patient was thirty-nine years old. The menses
continued for six months and then ceased. Since then the patient has been
in bed nearly all the time, suffering from marked cardiac dilatation.

In Case C. H. I. 930 the results have been much more satisfactory. The upper
part of the fundus was amputated on account of a submucous myoma, 7 cm.

* American Jour. of Obstetrics, July, 1907.

in diameter. The patient, fifteen months later, was in good health and menstruating regularly.

This method of attempting to save as much of the mucosa of the body as feasible has received a great deal of attention from Spinelli, of Naples, and others, and deserves the most careful consideration.

OTHER OPERATIONS PERFORMED IN CONJUNCTION WITH AN ABDOMINAL MYOMECTOMY.

When the patient is under the anesthetic, other pathologic pelvic conditions requiring attention are often detected. The accompanying data will give a fair idea of the various other operations that were performed in the 296 abdominal myomectomy cases:

Removal of both tubes and ovaries.....	13 cases	
Removal of right tube and ovary.....	11 "	
Removal of left tube and ovary.....	12 "	
Removal of one or both tubes.....	18 "	
Plastic operations on the tube.....	3 "	(Nos. 4016 4471 12165).
Release of pelvic adhesions.....	17 "	
Removal of ovarian cysts.....	20 "	
Graafian follicle cysts: Cases 4765, 8698, C. H. I. Peth., 5493 and 12848, Corpus luteum cysts: Cases 5588, C. H. I. Cath., C. H. I. 930, San. 1628. Papilocystoma of ovary: Cases 1455, 12034 (double). Dermoid cyst: Case 12852 (left twisted pedicle), San. 2142.		
Resection of corpus fibrosum.....	1 case	
Repair of perineum.....	37 cases	
Repair of complete perineal tear.....	2 "	
Anterior colporrhaphy.....	5 "	
Removal of vaginal cysts.....	2 "	(Nos. 5846 8844).
Dilatation and curetting.....	28 "	
Amputation of cervix.....	10 "	
Suspension of uterus.....	71 "	
Shortening of the round ligaments.....	6 "	
Appendectomy.....	15 "	
Cure of left inguinal hernia.....	1 case	
Cure of ventral hernia.....	1 "	
Cholecystotomy (for gall-stones).....	2 cases	(Nos. 6854 8310).
Fixation of kidney.....	2 "	
Opening of ischio-rectal abscess.....	1 case	
Removal of hemorrhoids.....	3 cases	
Removal of clitoris.....	1 case	(No. 9304).
Omphalopexy.....	1 "	(San. 1545).

Tubes and Ovaries.—The removal of the tubes and ovaries was indicated in most instances by dense adhesions, hydrosalpinx, hematosalpinx, or pus tubes.

In Case 9243 the right tube was the seat of a tubal pregnancy, and in Case 10587 the mucosa of both tubes was tuberculous.

Plastic operations were done on the left tube in Case 4471, and on the right tube in Case 4016, artificial fimbriated ends being made.

In Case 12165 a myoma occupied the cornu, and after removal of the tumor the tube was anastomosed into the uterine wall with success.

Ovarian Cysts.—Where feasible, small ovarian cysts were merely punctured or resected, as much of the ovary as possible being saved.

It will be noted that in two instances (Cases 1455 and 12034) secondary papillary masses were scattered throughout the abdomen.

Gyn. No. 1455.

Abdominal Myomectomy and Removal of Papilocystoma of the Ovary.

B. J., married, aged fifty-seven, white. Admitted June 27; discharged August 8, 1892. Operation: When the abdomen was opened, a large cyst was tapped. It had developed from the right ovary, and contained, besides 2000 c.c. of chocolate-colored fluid, many dense papillary masses. The peritoneum was also studded with papillary masses. A pedunculated myoma attached to the left uterine cornu was enucleated. The patient made a satisfactory recovery. On June 10, 1907, we received a communication from the patient's husband saying that she had died on September 11, 1903; in other words, she had lived eleven years, notwithstanding the fact that papillary masses were present at the time of operation.

Gyn. No. 12034.

Bilateral Papilocystomata of the Ovary with Multiple Metastases in the Peritoneum and Bowel. Abdominal Myomectomy.

This patient was admitted April 8, and discharged May 5, 1905. At operation about 2000 c.c. of ascitic fluid were evacuated, and both ovaries were found to be the seat of papillary cysts. The one on the left side was approximately 13 cm. in diameter; the one on the right, somewhat smaller. Projecting from the surface were delicate, tree-like outgrowths. These covered over half the surface area of the cyst. The cysts and a myoma, 2.5 cm. in diameter, were removed. The patient's health a year and a half later was "fairly good."

In both of these cases, after removal of the ovarian tumors a myomectomy was done. Under ordinary circumstances one would prefer hysterectomy, but in both of these cases, as indicated by the history, myomectomy under existing circumstances was a simpler operation. It is remarkable that in Case 1455 the patient lived over ten years after the operation, notwithstanding the wide distribution of the papillary growth.

Repair of the Perineum.—The large number of perineal operations was indicated mainly by the numerous cases of prolapsus associated with myomata.

Suspension of the Uterus.—It will be seen from the table that in 71, or nearly 25 per cent. of the cases, the uterus was suspended. This was done partly for the correction of a retrodisplacement, but more often on account of the necessity of bringing the myomectomy suture line in contact with the anterior abdominal wall, thus minimizing the possibility of the omentum or intestines becoming adherent to the catgut sutures projecting from the surface of the uterus.

ABDOMINAL MYOMECTOMY DURING PREGNANCY.

When a myoma complicates pregnancy, no operation is performed until after delivery, provided the myoma in no way obstructs the pelvis, so as to prevent delivery by the vagina. In six of our cases, for various reasons, it was deemed necessary to do a single or multiple enucleation during the puerperium. In Case 4990 the patient had had four miscarriages, but no children at term, during her seven years of married life. On her admission she was three and one half months pregnant. An interstitial and partly submucous myoma, 7 x 7 x 10 cm., was removed (Fig. 325), but one in the cervical region could not be dislodged without much handling and the certainty that a miscarriage would be caused. Notwithstanding the extreme care the fetus came away on the tenth day. About seven weeks after the first operation the cervical nodule, which measured 10 cm. in diameter, was shelled out.

Case 5081 affords another example of a miscarriage following myomectomy. The patient was three months pregnant (Fig. 326). An interstitial myoma, 8 x 9.5 x 12 cm., was removed. Within twenty hours the patient complained of sudden uterine pain, and the fetal head was found projecting from the vulva.

The results in the three succeeding cases were much more satisfactory, the pregnancy in each of these cases going on to term. In Case 1249 the patient was three months pregnant. A sessile subperitoneal myoma, about 6 x 7 x 8 cm., was removed from the posterior surface of the uterus (Fig. 327) and recovery was uninterrupted.

The patient in Case 8897 had been pregnant over three months. A pedunculated myoma, 8 x 8 x 12 cm., was removed from the left side of the uterus, and two interstitial nodules, each 2 cm. in diameter, were shelled out. The pregnancy went to term.

Mrs. G. (Path. No. 7895) was brought to the Emergency Hospital, Frederick, complaining of uterine hemorrhages. A cystic mass could be felt rising out of the pelvis. Pregnancy was suspected, but the operator was assured that none existed. As will be noted from Fig. 328, a myomatous tumor occupied the anterior lip of the cervix and encroached markedly on the anterior vaginal wall. On opening the abdomen a four months' pregnancy was found. The myoma was shelled out from above, and an area of vaginal mucosa, 6 x 5 cm., removed with it, as the myoma was very adherent to the vagina. The patient promptly recovered.

and was delivered at term of a ten-pound child. In this case the myoma so obstructed the pelvis that a normal labor would hardly have been possible.

We had one (Case 11110) death following myomectomy during pregnancy. This patient had been married eleven years and had never been pregnant. When the abdomen was opened a large, soft, four months' pregnancy was found. Scattered over the surface were many small myomatous nodules. The largest, 7 cm. in diameter, was removed. Considerable difficulty was experienced in controlling the hemorrhage. After the operation the bowels would not move. On the fifth day the fetus was expelled, and the placenta had to be removed with the curet. On account of an intestinal obstruction enterostomy was performed, on the sixth day. There was much bloody fluid in the abdomen, but the intestines, apart from the distention, looked normal. The patient died on the following day. This case is reported in full on p. 539, under "Deaths following abdominal myomectomy."

In Case 6508 abdominal myomectomy was attempted during pregnancy, but on account of the excessive hemorrhage, an immediate Porro operation seemed imperative.

DETAILED REPORT OF CASES IN WHICH ABDOMINAL MYOMECTOMY WAS PERFORMED DURING PREGNANCY.

Gyn. No. 4990. Path. Nos. 1521 and 1628.

Uterine Myomata Complicating a three and a half months' pregnancy (Fig. 325).

M. S., married, aged thirty-five, white. Admitted February 3; discharged April 24, 1897. The patient has been married seven years, has had no children, but four miscarriages, the last two years ago. In December, 1896, she discovered a small hard lump in the right side of the abdomen, low down.

Operation, myomectomy. To the right of the three and one half months' pregnant uterus was a dense, hard myoma, which was firmly attached to the uterus (Fig. 325). There was also a large myoma, situated low down in the broad ligament, to the left of the cervix. The one on the right side was removed, but it was impossible to remove the one in the broad ligament without interfering with the pregnancy. Ten days later the patient miscarried, and it was necessary to remove the remains of the placenta with the curet.

March 15, 1897: An attempt was made to partially obliterate the blood-supply of the uterus by clamping the left uterine vessels; but this had little effect.

March 27, 1897: Myomectomy per abdomen. The large myoma situated to the left of the cervix was removed. The patient made an uninterrupted recovery. It is interesting to note that the site of the first myomectomy was almost unrecognizable at the second operation, there being practically no scar.

Path. No. 1521. The myoma situated near the right tube measured 7 x 7 x 10 cm.

Path. No. 1628. The myoma situated to the left of the cervix was 10 cm. in diameter.

January 1, 1907. The patient's general health at present, nearly ten years after operation, is good. She has no hemorrhages. Menstruation is normal. There has been no pregnancy since the operation.

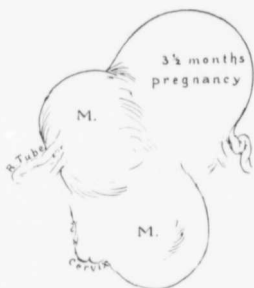

FIG. 325.—UTERINE MYOMATA COMPLICATED BY A THREE AND ONE-HALF MONTHS' PREGNANCY.

GYN. No. 1990. The interstitial myoma near the right tube was enucleated. A miscarriage followed on the tenth day. The large nodule to the left of the cervix was removed several weeks later.

removed. The subsequent history was uneventful.

A letter from the patient, dated January 1, 1907, nine and one-half years after operation, states that she has been under a physician's care for uterine trouble for four years. She has no hemorrhages. There is no vaginal discharge, but there is some bladder irritation. Her menses are normal.

Gyn. No. 1249.

Myomectomy Without Interference with the Pregnancy (Fig. 327).

M. S., married, aged twenty-five. Admitted March 7; discharged April 6, 1892. The patient has been married one year, and has had no children and no miscarriages. Operation, myomectomy. An incision, 8 cm. in length, was made into the uterus, and the subperitoneal nodule projecting from

Gyn. No. 5081.

Uterine Myomata Complicating Pregnancy (Fig. 326).

R. H., married seven months, aged twenty-five, white. Admitted March 9; discharged May 25, 1897. Operation. An interstitial myoma, 8 x 9.5 x 12 cm., was removed (Fig. 326). The incision into the uterus was 14.5 cm. long, and the hemorrhage was excessive. Two other small myomata were also removed. The patient was kept under morphin after operation, but within twenty hours complained of sudden pain, and the fetal head was found projecting from the vulva. She was anesthetized and a three months' fetus and placenta were

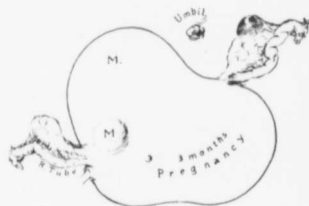


FIG. 326.—MULTIPLE MYOMECTOMY ON A WOMAN THREE MONTHS PREGNANT.

GYN. No. 5081. The large interstitial myoma projected from the posterior surface of the uterus. It was enucleated, and several smaller nodules were also removed. A miscarriage followed within twenty-four hours.

An incision, 8 cm. in length, was made into the uterus, and the subperitoneal nodule projecting from

the posterior surface removed (Fig. 327). This myoma was approximately 7 x 6 x 8 cm. The temperature never rose above 99.5° F. The patient made a perfect recovery, and the pregnancy went on to term.

January 1, 1907, about fourteen and one-half years after operation: A letter from Dr. Edwin H. Miller, of Philadelphia, states that the patient's general health is not good. She has no hemorrhages; there is no discharge; no bladder disturbance, and her menstruation is normal.

Gyn. No. 8897.

Uterine Myoma Complicating Pregnancy.

K. S., aged twenty-nine, white, married. Admitted July 3; discharged July 30, 1901. The patient has been married six months. On bimanual examination definite myomatous nodules can be made out. Operation, multiple myomectomy. A median incision exposed one large myoma springing from the wall of the fundus anteriorly, a smaller one beside this on the anterior wall, and a third on the left posterior wall. The pedicle of the large myoma was cut across, and the resultant raw surface obliterated with catgut sutures. The other two myomata were shelled out. The uterus itself was about the size of a four months' pregnancy. The patient recovered rapidly, the pregnancy being in no way interfered with. The large myoma measured 8 x 8 x 12 cm.; the two smaller ones, each 2 cm. in diameter.

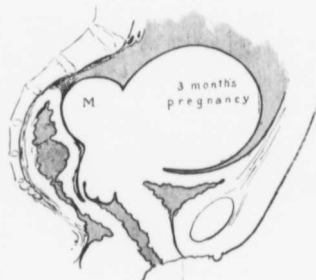

FIG. 327.—A SUBPERITONEAL MYOMA COMPLICATING PREGNANCY.

GYN. NO. 1249. The subperitoneal nodule (m) was enucleated and the patient went on to term.

Case G., Path. No. 7895.

Removal of a Large Cervical Myoma per Abdomen from a Patient Four Months Pregnant (Fig. 328).

This patient was thirty-four years of age. One of us (C.) saw her in consultation with Dr. Lamar, of Middletown, on May 17, 1904. She was operated upon in the Frederick Emergency Hospital. She had been bleeding profusely for several weeks. When I saw her, the pulse was 130. The entire anterior lip of the cervix was greatly thickened (Fig. 328); the posterior was normal. The thickening in the anterior cervical lip was caused by a hard nodule, approximately 9 cm. in diameter. Above this was what appeared to be a cystic tumor. Despite careful inquiries there was nothing in the history in any way suggesting pregnancy. On opening the abdomen we found a four months' pregnancy and the myoma of

the anterior lip. This almost completely filled the pelvis. Not having permission to do a hysterectomy, we determined to shell out the myoma, but this was so intimately blended with the vagina that a portion of the vagina, about 6 x 5 cm., had to be removed with the tumor. The opening into the vagina was closed, but there was much oozing, and in places the bleeding was checked with the greatest difficulty. The patient made a good recovery, went on to term, and after a normal labor was delivered of a ten-pound child.

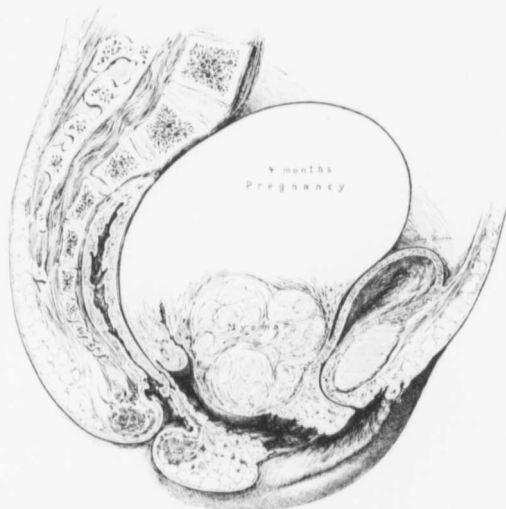

FIG. 328.—MYOMA OF THE CERVIX OBSTRUCTING THE VAGINA AND COMPLICATING A FOUR MONTHS' PREGNANCY.

G. Frederick Emergency Hospital, Path. No. 7805. The myoma had developed in the outer portion of the anterior lip of the cervix. It had not only grown upward, but also had encroached markedly on the vagina. It was so intimately blended with the vaginal mucosa that over a wide area it was necessary to remove the mucosa with the myoma. The pregnancy proceeded to term.

On May 29, 1907, three years after the operation, I received a letter from the patient in which she stated she was absolutely well.

IMMEDIATE DEATH FOLLOWING ABDOMINAL MYOMECTOMY.

In our 296 abdominal myomectomies 280 patients recovered and 16 died—a mortality of 5.4 per cent. From the clinical course of the fatal cases and from the autopsy findings in some of them we can, with a fair degree of accuracy, divide the probable causes of death into the following groups:

Intestinal obstruction, peritonitis, or both	8 cases
(Cases 57, 65, 482, 1862, 5638, 7560, 10351, 8; Toronto case.)	
Possible cerebral embolus with hyperpyrexia	1 case
Myomectomy during pregnancy	1 "
Probable infection from an unsuspected carcinoma of the body (Case 1173)	1 "
Probable death from faulty catgut (Case 1752)	1 "
Probable infection from Fallopian tube (Cases 5124 and 11296)	2 cases
Almost moribund condition of patient before operation, death on table (Case 1672)	1 case
Possible myocarditis (C. H. L., W.)	1 "
	<hr/>
	16 cases

INTESTINAL OBSTRUCTION, PERITONITIS, OR BOTH.

In the majority of our fatal cases death was due either to intestinal obstruction or peritonitis or to obstruction followed by peritonitis. In some instances the cause of death is perfectly clear, as in Case 7560, in which the patient undoubtedly died of a streptococcus peritonitis. In other cases, however, the patients had first shown signs of intestinal obstruction, and later mild manifestations of peritonitis. It is well known that obstruction may, in a few days, lead to peritonitis, and, further, that where peritonitis is the primary factor, intestinal paralysis with signs of obstruction is among the earliest manifestations of peritonitis. We are inclined to think that in our cases intestinal obstruction was the dominant factor in most instances, and that the peritonitis was secondary.

As we all learn more by our failures than by our successes, we have concluded to report each of the fatal cases in some detail, so that the reader may draw his own conclusions as to the cause of death.

Gyn. No. 57.

Abdominal Myomectomy; Obstruction; Death.

S. R., married, aged thirty-three, colored. Admitted November 25; died December 6, 1889. Operation, myomectomy; double salpingo-oöphorectomy. A myoma, 3.5 cm. in diameter, was removed from the fundus. Both tubes and ovaries were excised on account of adhesions. After operation the abdomen was not distended or tympanitic. Vomiting commenced on the third day. There was inability to evacuate the bowels after the sixth day. The patient died on the eleventh day. Her pulse at that time reached 168; her temperature was not over 100.5° F. Just prior to death there was some delirium.

Aut. No. 48. The peritoneum is red and injected. The intestines are adherent, and bound down in the pelvis. The heart and lungs are normal. Cultures from the peritoneal cavity, kidneys, and spleen give negative results.

Gyn. No. 65.

Intestinal Obstruction Following Abdominal Myomectomy. Death.

E. K. B., married, aged thirty-three, white. Admitted December 10, 1889; died January 2, 1890. Operation, December 30th. The pelvis was filled with the tumor mass, which was intimately adherent. After liberation of adhesions, which was accompanied by considerable hemorrhage, a myoma was enucleated, the uterine cavity being opened.

Subsequent History.—The pulse became more rapid. The abdomen was opened on the third day. There was no evidence of inflammation. The pulse soon rose to 152, and the temperature was 101.6° F. on the following day, when she died.

Aut. No. 52. The intestines are distended, and there is some bloody fluid in the abdomen. Anatomic diagnosis: peritonitis, general anemia, fatty degeneration of the heart and kidneys. Cultures from the abdominal wound, from the pelvis, and from the bloody fluid in the abdominal cavity gave a growth of *Staphylococcus pyogenes aureus*.

It will be noted that when the abdomen was opened on the third day there was no evidence of inflammation. When the drain is placed in the abdomen, cultures later on usually yield one of the pus-organisms. In this case it looks as if death was due to obstruction rather than to peritonitis.

S. (Toronto), June, 1903.

Probable General Peritonitis. Death.

Mrs. S. was seen in consultation in Toronto June 8, 1903. She gave a history of bleeding for a short time. On examination the uterus was found to be the size of that of a four and one-half months' pregnancy, but freely movable. On section of the abdomen the growth was found situated in the anterior wall. On cutting through a thin layer of muscle we encountered a partially degenerated myoma, fully 12 cm. in diameter. This was readily shelled out. The cavity was obliterated with catgut, and a few silk sutures were used as the catgut gave out. The patient stood the operation well, but died three days later. The pulse from the time of operation was never lower than 135, and shortly before her death reached 165. The temperature varied from 101° to 104° F. She had no vomiting or distention, and the bowels moved freely. It is impossible to state the exact cause of death, as no autopsy was allowed. The diagnosis lay between peritonitis or the unaccountable absorption that takes place even when no infection occurs.

Gyn. No. 482.

Abdominal Myomectomy. Death from Suppurative Peritonitis.

A. W., single, aged twenty-three, colored. Admitted December 20, 1890; died January 7, 1891. Operation, December 22d. The ovaries on both sides contained Graafian-follicle cysts. The tubes and ovaries were released from adhesions and removed. A small myoma in the posterior wall of the fundus was transfixed beneath its base and removed.

Subsequent History.—On the fifth day the temperature rose to 101.8° F., and examination revealed a tender, semifluctuant spot in the left broad ligament. On the sixth day the temperature reached 103.2° F., the pulse 160, and the patient had an attack of vomiting. The abdomen was not especially sensitive and not distended. The incision was thoroughly cleansed with bichloride, and the lower portion opened. On the introduction of the index-finger a small amount of blood escaped. The omentum and intestines were adherent to the myomectomy wound in the uterus, and also at the points from which the tubes and ovaries had been removed. These adhesions were separated, and about 30 c.c. of blood escaped. A drainage-tube was inserted behind the uterus.

The patient seemed to improve slightly at first, but later became gradually weaker. The abdomen became more tympanitic and the pulse became more rapid and poor in volume. She complained of severe thirst, had several involuntary stools, and died in a semiconscious state on the twelfth day. The temperature ranged between 99° and 102° F. The pulse just prior to death was 156.

Cultures after the second operation showed *Staphylococcus aureus*. In this case the trouble was undoubtedly primarily an obstruction due to adhesions, and following the second operation peritonitis developed.

Gyn. 1862.

Abdominal Myomectomy; Intestinal Obstruction Followed by Peritonitis. Death.

L. J., single, aged thirty-eight, colored. Admitted March 15; died April 10, 1893. Operation, March 22d. A sessile tumor, 10 x 12 cm., was enucleated from the anterior surface of the fundus, and a smaller myoma, 2 x 3 cm., from the posterior surface.

The patient subsequently developed some tenderness and swelling, with marked constipation. She was anesthetized, and a hand, introduced into the rectum, broke up adhesions by which some of the loops of the small intestine had become adherent to the pelvis. Later the patient vomited some fecal matter, and a second operation was performed. The abdomen, which was distinctly distended, was opened, and the intestines were found greatly inflamed and somewhat adherent. In releasing the intestines the peritoneal coat was torn in several places—in one place so badly as to necessitate a resection of the bowel. Some fecal matter escaped. A drain was introduced into the pelvis and to the point of the intestinal resection.

The temperature after the first operation was below 100° F., and did not go much higher until the fifteenth day, the day after the second operation. It then rose to 102.2° F., and the pulse to 150. The patient died of peritonitis on the twentieth day.

With our present knowledge of intestinal obstruction we would not think of loosening up adhesions through the rectum without knowing the exact condition in the pelvis. Adhesions are now never liberated except under sight. The

primary cause of death in this case was undoubtedly the adhesions, which produced intestinal obstruction. Such a case would now call for an enterostomy.

Gyn. No. 5638.

Intestinal Obstruction Following Abdominal Myomectomy. Death.

M. K., single, aged thirty-seven, white. Admitted October 26; died November 4, 1897. Operation, myomectomy and suspension. A large myoma was enucleated from the posterior wall of the uterus, and five smaller nodules from the anterior surface.

After operation all attempts to move the bowels were fruitless. The patient vomited continually, the vomitus later having a fecal odor. The temperature varied between 98.4° and 100° F. The pulse became gradually more rapid and weaker, reaching 132 on November 3d.

Second operation: release of adhesions; release of suspended uterus. The intestines were distended with gas. Adhesions of omentum and small intestines to the uterus obstructed a loop of small bowel. A gauze drain was introduced.

The temperature rose to 103°F., the pulse reached 144, and was very thready in character. There was much nausea and vomiting, and the patient died about twenty-four hours after the second operation.

Gyn. No. 7560.

Abdominal Myomectomy, Streptococcus Peritonitis. Death.

J. B. C., aged forty-four, white. Admitted February 7; died February 15, 1900. Operation, February 12th, abdominal myomectomy; suspension of the uterus. A myoma, about 4.5 cm. in diameter, was removed from beneath the left round ligament. The tubes and ovaries were normal. At the time it was noted that the colon was much distended with gas.

In the peritoneum over the bladder there appeared a slightly elevated area, 1 x 2 cm. This seemed to be a thickening of the bladder-wall, which did not, however, appear inflamed. After the operation the patient suffered from nausea and vomiting. The vomitus was dark brown in color, and suggested an admixture of clotted blood. Her first night was fairly comfortable. She voided a small quantity of urine. The pulse ranged between 80 and 104, the temperature between 98° and 100.5° F. The nausea grew worse. At the end of twenty-four hours the tongue was very dry and the abdomen was distended, but at first there was no tenderness. The bowels did not move until several enemata had been given. On the third day the temperature reached 104.8° F. A diagnosis of general peritonitis was made.

Operation, February 14th. At the upper angle of the wound some creamy white pus was noted along the sutures. The incision was opened, the peritoneal sutures were cut, and a seropurulent fluid, slightly blood-tinged, welled up.

Cover-slips from this showed streptococci. The intestines were injected and covered with a fibrinous deposit. The omentum was injected. There were no adhesions. The abdominal cavity was flushed out. The patient died the following day.

Gyn. No. 10351.

Abdominal Myomectomy Followed by Intestinal Obstruction. Death.

L. B. D., aged thirty-five, colored, married. Admitted March 24; died March 29, 1903. At operation a multinodular myomatous uterus was found filling the pelvis, and extending to within 5 cm. of the umbilicus. The uterine vessels were controlled by a rubber tube drawn around the cervix. The uterus was then bisected, and 28 myomata of various sizes were shelled out. The cervix was dilated, an iodoform pack put in the uterine canal, and the uterus sewn up with two layers of catgut sutures. The bleeding was apparently successfully controlled. There was, however, slight oozing, and several strips of iodoform gauze were left in the lower end of the abdominal incision. The patient left the table in excellent condition.

Four hours after operation the temperature reached 101° F., the pulse was 100. Twenty-four hours later the pulse was 130. The temperature never was higher than 101° F. Her pulse became gradually higher until the fifth day at 9 A. M., when she died. Eight hours after the operation the binder was stained through with blood. Her bowels refused to move and she had quite marked abdominal distention, which began twenty-four hours after the operation. The restlessness increased shortly after the operation.

On the fourth day she was removed to the operating room, and under gas an enterostomy was done. When the abdominal cavity was opened, a large amount of tarry blood escaped, together with some clots. The intestines were moderately distended. A loop of small intestine was brought out and opened. There was an escape of gas, but no fecal matter. After this second operation there was no improvement, and the patient gradually grew weaker and died. She had what appeared to be fecal vomiting before death.

The myomata varied from 1 to 1.5 cm. in diameter.

In this case it would have been much wiser to have done a hysterectomy instead of a myomectomy, especially when so many myomata were present. After splitting almost entirely through the uterus it is exceedingly difficult to approximate the two halves, and at the same time absolutely to check bleeding.

POSSIBLE CEREBRAL EMBOLUS WITH HYPERPYREXIA.

In Case 10588, in which a multiple myomectomy was done, the pulse soon rose to 140, and gradually became poorer in quality. The abdomen showed slight distention, and the patient became drowsy. Her temperature suddenly rose to 107° F. shortly before her death on the third day. The abdominal inci-

sion was opened after death. Not over an ounce of blood-stained fluid was found. There were no evidences of peritonitis, and cultures were negative. In this case the symptoms suggested a cerebral embolus.

Gyn. No. 10588.

Multiple Abdominal Myomectomy. Death with Indefinite Signs.

L. H., single, aged forty, white. Admitted July 5; died July 8, 1903. The patient was well nourished and had a good color. The heart and lungs were apparently normal. The uterus contained several myomata, varying from 0.5 to 5 cm. in diameter.

The operation was perfectly simple, and the patient was returned to the ward in good condition. Soon after her pulse rose to 140, but remained of good volume for twenty-four hours. The second night she was quite uncomfortable. She was given calomel on the second day, followed by Epsom salts and enemata, which were not effectual. On the third day her pulse was 120; her temperature, 100° F. She was comfortable, and slept well during the night. About 11 A. M. there was a sudden collapse. In the afternoon her temperature rose to 107° F. There was no pallor and no symptoms except the temperature were present to indicate peritonitis. Everything pointed strongly to an embolus involving a thermic center. She gradually grew weaker, and died at 7 P. M. We had permission to open the abdominal incision and found the intestines perfectly smooth. There was not an ounce of blood in the abdomen. The stitches had held everywhere in the uterine wall, and on opening the uterus we found that none had entered the uterine cavity. Furthermore, there were no dead spaces containing blood.

This is one of those cases in which the patient dies and yet no definite assignable cause can be detected without the most thorough autopsy. The probability, however, is that she had an embolus. Cultures from the peritoneal cavity were negative.

A few years later we learned that this patient shortly before entering the hospital had told several friends that she was sure she was going to die. In all cases in which the patient has a persistent premonition of death, operation, if not immediately imperative, should be deferred until the chances of success have been so thoroughly impressed upon the patient that her mental attitude is changed and she promises to do all she can toward getting well.

In this case, as is said elsewhere, we wished to do a hysterectomy, but were hampered by our promise to the patient to save the uterus.

FATAL MYOMECTOMY DURING PREGNANCY.

The patient had been married eleven years and had never been pregnant before. At operation a four months' pregnancy was detected. Numerous

nodules studded the uterus. A myoma 7 cm. in diameter was removed and some difficulty was experienced in controlling the bleeding.

Intestinal atony developed, undoubtedly favored by the pregnancy. Miscarriage followed, and the patient soon died. Infection certainly played a very minor rôle in this case.

For the successful abdominal myomectomies during pregnancy see p. 528.

With our present knowledge we would not think of doing a myomectomy in such a case. The abdomen would be closed at once, the pregnancy being allowed to go on to term, after which, if necessary, hysterectomy or myomectomy would be performed.

Gyn. 11110.

Abdominal Myomectomy During Pregnancy. Death.

C. S., aged thirty-three, colored. Admitted March 9; died March 20, 1904. This patient had been married eleven years and had never been pregnant. Operation, March 14, 1904. When the abdominal cavity was opened, a large, soft, pregnant uterus was found. The pregnancy had probably run about four months. Many small nodules were scattered over the surface of the uterus, and one of the larger tumors, about 7 cm. in diameter, was removed. There was some difficulty in controlling the bleeding.

Postoperative History.—After the operation morphin was given rather freely during the first forty-eight hours, to prevent, if possible, miscarriage. On the evening of the second day the temperature was 101.6° F., and at noon of the next day it was again normal. Cathartics were given on the second day, but neither these nor enemata had any effect, and the intestinal distention increased rapidly. On the night of the third day she was quite ill; her pulse was 118, and the abdomen considerably distended. Leukocytes, 36,000. The distention became somewhat less, and her leukocytes dropped to 11,000. The bowels did not move, however. There were no signs of bleeding from the vagina until the night of the fifth day, when she suddenly passed a small fetus. The placenta had to be removed manually.

The distention was becoming greater, the pulse had become more rapid, and on the sixth day an enterostomy was done under cocain. Her pulse at this time was 130 and weak. The incision was made through the outer border of the right rectus muscle and the peritoneal cavity opened. There was much free blood; the intestinal coils were much distended, but otherwise normal. A loop of large bowel was brought into the wound and sutured with catgut.

Cultures taken from the bloody fluid at the time of the second operation yielded *Staphylococcus albus*. The temperature steadily rose to 103.5° F., and she died on the following afternoon.

PROBABLE INFECTION OF THE UTERUS FROM AN UNDETECTED CARCINOMA OF THE BODY OF THE UTERUS.

In looking over the history of Case 1173 it will be noted that the patient had a slimy, watery, vaginal discharge. This is very significant in connection with the subsequent history, but at the time was overlooked. In this case the uterus was bound down by adhesions and contained two myomata. One of these, about 7 cm. in diameter, was enucleated. The other could not be shelled out on account of adhesions. The patient died on the sixth day of acute purulent peritonitis.

This operation was performed in 1892, when the technic of myomectomy had not been fully developed. Now we would not think of trying to save the uterus in such a case, but would perform hysteromyomectomy. The finding of a carcinoma of the body of the uterus at autopsy gives us a very valuable surgical hint. In all cases in which we advise abdominal myomectomy, as far as possible we exclude the presence of a carcinoma of the body. In the chapter on Carcinoma of the Body and Myoma, it was clearly demonstrated that in numerous cases carcinoma was not suspected until the uterus was opened up after its removal.

Myomectomy in the presence of an adenocarcinoma of the body is naturally almost certain to give rise to infection.

Gyn. No. 1173. Aut. 277.

Abdominal Myomectomy Complicated by an Undiscovered Adenocarcinoma of the Body of the Uterus.

A. B., single, aged forty-three, colored. Admitted January 26; died February 18, 1892. In November, 1891, two small myomata were removed per vaginam in New York. Three and a half months ago the patient noticed a lump in the left iliac region. She has a slimy, watery, vaginal discharge, with occasional clots, is very anemic, and has a double apical heart murmur.

Operation, February 13, 1892. The uterus was distended by two myomatous masses; the anterior, about 7 cm. in diameter, was removed. The posterior, which was slightly larger, was bound down by adhesions, which precluded its enucleation.

The patient vomited many times after operation. The abdomen became distended, the pulse rapid, and the temperature rose to 103° F. on the fifth day, dropping to 101.5° F. on the sixth day, the day of her death. That day the patient was covered with a cold, clammy sweat and voided urine involuntarily.

Aut. No. 277. Anatomic diagnosis: Acute purulent peritonitis. Myoma and carcinoma of the uterus; general arteriosclerosis; cardiac hypertrophy; chronic diffuse nephritis; bronchopneumonia (right lung). The peritoneal cavity showed pure *Staphylococcus pyogenes aureus*.

A DEATH PROBABLY FROM FAULTY CATGUT.

Between January 18 and 25, 1893, five laparotomies were performed in the Gynecological Department of the Johns Hopkins Hospital, and four of these patients died.* In all the fatal cases the operation was a simple one, and the abdomen at the time of operation was apparently perfectly clean. In the fifth case—one of pyosalpinx—the patient recovered.

In all the cases *Staphylococcus aureus* was found. The source of infection appeared to be some old catgut, but it was impossible to determine with certainty, as all the catgut had been used, none remaining for bacteriologic examination.

This case was one of the four fatal cases.

Gyn. No. 1752.

Abdominal Myomectomy; General Peritonitis Apparently Due to Faulty Catgut. Death.

E. H., aged thirty-four, white. Admitted January 12; died January 26, 1893. Operation, January 23, 1893. Two symmetric myomata were discovered, one in the anterior wall, 8.5 cm., and one in the posterior wall, 8 cm. in diameter. Both of these were enucleated, as were also four other smaller ones.

On the night of the second day the patient complained of severe stabbing pain over the area of the lower lobe of the left lung. The pain was increased on deep inspiration. The tongue was moist and slightly coated; the abdomen was not distended. On the following day the pulse was 120. Her expression was bad. She had been nauseated at intervals during the entire day. The abdomen was prominent, distended, tympanitic, and sensitive. On opening the lower angle of the wound the operator was unable to find any evidence of pus. The temperature was 104.4° F. On January 26th it rose to 107.8° F., and death quickly followed. The patient was conscious to the last.

Autopsy. Anatomic diagnosis: Purulent hemorrhagic peritonitis following abdominal myomectomy; stitch-hole abscesses; acute splenic tumor; embolic lung abscess; congestion of the lungs; infection with *Streptococcus pyogenes* and *Staphylococcus pyogenes aureus*. (The autopsy findings are given in full in the Johns Hopkins Hospital Reports, 1895, vol. iv, p. 412.)

PROBABLE INFECTION FROM FLUID LIBERATED FROM THE FALLOPIAN TUBES.

In Case 5124 the uterus not only contained numerous myomata, but was also densely adherent. When the abdomen was opened, the right tube and a myoma, 4 cm. in diameter, were removed, and an artificial fimbriated end was made for the left tube. After many ups and downs this patient died about six weeks after operation.

* Thomas S. Cullen, Postoperative Septic Peritonitis, The Johns Hopkins Hosp. Reports, vol. iv, 1895, p. 411.

In Case 11296 a myoma, 6 cm. in diameter, was shelled out of the posterior wall, and both tubes, which were filled with clear fluid, were punctured, the fluid escaping into the abdominal cavity.

The surgical treatment in both of these cases is open to criticism.

In Case 5124 we (Cullen) would have shown much better judgment had we done a hysterectomy. In Case 11296 both tubes should have been removed and no fluid allowed to escape into the abdominal cavity. The occlusion of the tube was primarily due to an infection, and we can never tell when all the organisms are dead.

Gyn. No. 5124.

Abdominal Myomectomy; Release of Adhesions; the Making of an Artificial Fimbriated Extremity for One Tube. Death.

A. M. B., aged forty, married, colored. Admitted March 23; died May 5, 1897. Operation, March 26th, vaginal section with release of adhesions. Second operation, April 19th. Pelvic adhesions were liberated from above, the right tube was removed, a myoma 4 cm. in diameter enucleated from the uterine wall, and an artificial opening made in the left tube. Other myomata were seen, but were not disturbed.

The abdominal incision broke down for its entire length, necessitating drainage. Subsequently on two occasions pelvic drainage was reestablished from below. The patient, however, gradually grew weaker, the pulse more rapid, and she died on May 5, 1897.

In this case the fact that the abdominal incision broke down notwithstanding the careful technic, indicates a very low vitality. At the time of operation it would have been much wiser to remove the uterus with the appendages, instead of trying to do a conservative operation.

Path. No. 1665. The right tube is 8 cm. in length, firmly covered by dense adhesions. It contains a yellowish, cheesy-like material.

Histologic examination shows the tube to be the seat of a chronic salpingitis.

Gyn. No. 11296.

Abdominal Myomectomy, Evacuation of Serous Fluid from Both Fallopian Tubes. Death.

V. S., aged thirty-four, white, married. Admitted May 19th; died May 28, 1904. The patient was intensely neurotic and rather anemic. She was fairly well nourished and well built. Operation, May 21, 1904. A myoma, 6 cm. in diameter, was enucleated from the posterior wall. Both tubes were the seat of a hydrosalpinx. They were punctured, fluid escaping into the abdominal cavity.

Postoperative History.—For four days she did fairly well. Her temperature was 101.2° F. on the second day; the third day it reached 100° F.; the fourth day it was down to 99° F., but she began to vomit. Enemata had no effect. On the fifth day she was nauseated nearly all day, took but little nourishment, but had no abdominal pain. There were six small offensive fluid stools. Her temperature on the fifth day varied from 99° to 102° F. Her pulse, however, at one time reached 130, and her general condition was not satisfactory. The nausea continued. The wound was inspected and found to be clean. Lavage relieved her gastric symptoms a good deal.

On the seventh day she began to have diarrhea, and the same afternoon her condition suddenly became worse; she grew very weak, restless, and slightly irrational; her pulse reached 140, and she died on the eighth day. Just before her death the cheeks were flushed, the eyes were bright, and the intellect was active; there was no pain or rigidity. She was intensely restless. No autopsy was allowed, but we diagnosed a general peritonitis. Shortly before death the temperature was 106.5° F.

THE PATIENT IN AN ALMOST MORIBUND CONDITION BEFORE OPERATION.

Many an apparently forlorn hope yields a brilliant surgical triumph, and as long as there is a possibility of saving the patient, it is the surgeon's duty to take that chance. In the following case the patient was in a desperate condition and succumbed on the table. The death, of course, cannot be in any way attributed to the abdominal myomectomy, but it is, nevertheless, included among our fatal cases.

Gyn. No. 1672.

Removal of a Large Cystic Myoma from a Patient in an Almost Moribund Condition. Death on the Table.

B., single, white. Admitted November 12; died November 13, 1892. The patient, on admission, was suffering with extreme dyspnea and was unable to lie down. The abdomen was much distended, fluctuant, and dull on percussion everywhere, except at the center of the upper abdominal zone. The circumference at the umbilicus was 52 inches. The urine contained a moderate amount of albumin, but no casts.

Operation November 13th. The anesthetic was administered with the patient in the sitting posture, on account of the extreme dyspnea.

A small incision was made near the dependent portion of the abdomen, a trocar was inserted, and from four to six pints of fluid deeply stained with blood came away. The almost moribund patient was then placed on the operating table. The incision was increased in length, and a large quantity of blood-stained fluid flowed out. The large fibrocystic tumor was shelled out of its adhesions, which were fibrous and omental in character. The pulse and respiration stopped. The patient was inverted, and artificial respiration resorted to, but to

no purpose. The pulse before operation was 160. The tumor was a cystic myoma, 30 x 34 cm., the inner portion being composed of one large cyst filled with chocolate-colored contents. The base of the tumor measured 14 x 16 cm. and was composed of typical myomatous tissue.

MYOCARDITIS AS A POSSIBLE CAUSE OF DEATH FOLLOWING ABDOMINAL MYOMECTOMY.

In C. H. I. case W., the patient gave a history of cardiac weakness, and at the end of twenty-four hours after operation became weak and had fainting spells. None of her symptoms except vomiting in any way suggested peritonitis. Unfortunately, no autopsy could be obtained. Her postoperative condition strongly suggested a myocardial lesion.

C. H. I., W.

W., white, aged thirty-eight years, was admitted to the Church Home and Infirmary October 10th, and died October 12, 1899. She had noticed an abdominal enlargement about a year before. The tumor had grown considerably since she was examined, six months before. A myoma, 16 cm. in diameter, was removed from the posterior wall, and several small ones from both the anterior and posterior walls. The patient was weak, but did fairly well for twenty-four hours. She had fainting spells on the afternoon of October 12th, vomited a good deal, and died suddenly the same evening. There was no abdominal distention, no hemorrhage. Her temperature had been normal throughout. No autopsy was obtainable.

Dr. W. F. Hines, of Chestertown, Md., her family physician, informed me that on several occasions she had suddenly collapsed, and that he thought she had a myocardial infection. We are unable to say with absolute certainty whether or not such was the condition.

IMMEDIATE POSTOPERATIVE COMPLICATIONS IN NON-FATAL CASES OF ABDOMINAL MYOMECTOMY.

By immediate we mean those occurring during the patient's sojourn in the hospital. Of the 280 patients, quite a number had mild or serious complications. These are of sufficient practical importance to warrant a thorough consideration.

The postoperative complications encountered were:

High temperature.

Rapid pulse.

Hysterical manifestations.

Excessive nausea and vomiting.

Postoperative hemorrhage.

Great abdominal pain.

Cystitis.

Nephritis.

Escape of pus from the urethra.

A foul uterine discharge.

Sloughing of the anterior uterine wall.

Pelvic peritonitis.

Intestinal obstruction.

A high leukocytosis.

Abscess in the broad ligament, with spontaneous evacuation into the bladder.

Tonsillitis.

Bronchitis.

Pleurisy.

Bronchopneumonia.

Lobar pneumonia.

Phlebitis.

Bedsore.

Temperature and Pulse after Abdominal Myomectomy.—Elevation of temperature with an acceleration of the pulse is a common occurrence after an abdominal myomectomy, and causes the surgeon much anxiety. As a rule, both temperature and pulse drop gradually, reaching normal several days after operation. Of the cause of the increased temperature we know little or nothing. On reopening the abdomen in some of the severer cases we have found no hemorrhage nor infection. It is quite possible that in many cases, notwithstanding the surgeon's care, there exist small accumulations of blood in spaces that have not been totally obliterated, and that the disintegration and absorption of this blood may in some way be responsible for the increased temperature. No other class of abdominal operations has given us as much anxiety during the first week following operative interference.

In 242 of the cases we have complete data as to the postoperative temperature and pulse.

That the findings may be presented as concisely as possible, tables have been prepared. In these are included the postoperative temperature and pulse-rate during the first week, as abnormalities after this period, with a few exceptions, were associated with postoperative complications and are considered in the discussion of that subject. Only the highest temperature and pulse-rate are considered, and the grouping of the cases is arranged accordingly, as seen in Tables I and III. In Table II are included cases showing a temperature above 102° F., the striking feature being the absence of any clear cause for such rise. Similarly, in Table IV cases showing a high pulse-rate are considered, and here too, in the majority, no satisfactory cause can be assigned. In 11 cases the pulse-rate remained high during the greater part of convalescence.

Temperature.—From a consideration of Table I it will be seen that in 78 per cent. of the cases the maximum postoperative temperature during the first week was over 100° F.

TABLE I.

MAXIMUM POSTOPERATIVE TEMPERATURE DURING FIRST WEEK.		
98.8°,	1 case	(0.4 per cent.)
99°-100°,	53 cases	(21.7 per cent.)
100°-101°,	127 cases	(52.9 per cent.)
101°-102°,	43 "	(17.9 per cent.)
102°-103°,	10 "	(4.2 per cent.)
103°-104.5°	8 "	(2.9 per cent.)
Total,	242 cases	

In 17 cases the temperature was above 102° F. These cases are shown in Table II. In only 4 out of the 17 cases could any definite cause be assigned for this elevation.

TABLE II.

CASES SHOWING A MAXIMAL POSTOPERATIVE TEMPERATURE OF OVER 102° F. IN THE FIRST WEEK.

GYN. NO.	TEMPERATURE.	DAY AFTER OPERATION.	APPARENT CAUSE.
121	102.2°	Seventh.	Not clear.
362	103.4°	Seventh.	Lung involvement (no definite consolidation).
6724	102.4°	Second.	Lung involvement.
9304	102.4°	Fourth.	" "
1489	102.5°	Third.	" "
8844	102.6°	Sixth.	Tenderness and muscle spasm in right iliac fossa following appendectomy and myomectomy.
7230	102.8°	Sixth.	Not clear.
8176	102.8°	Second.	" "
4055	103.0°	Sixth.	" "
10659	103.0°	Second.	" "
10394	103.0°	Third.	" "
5452	103.2°	Fifth.	" "
4929	103.4°	Sixth.	" "
858	103.8°	Fifth.	" "
2039	104.2°	Fourth.	" "
3359	104.5°	Fourth.	Too early discontinuance of vaginal drainage.
11052	104.5°	Second.	Bronchopneumonia.

Pulse.—That the pulse-rate is materially increased after abdominal myomectomy is evidenced by the fact that in about 67 per cent. of 241 cases the maximum during the first week was over 100, as is shown in Table III.

TABLE III.

MAXIMAL POSTOPERATIVE PULSE-RATE DURING THE FIRST WEEK.		
70 - 80	1 case	(0.4 per cent.)
80 - 90	12 cases	(5.0 per cent.)
90 - 100	66 "	(27.5 per cent.)
100 - 110	69 "	(28.3 per cent.)
110 - 120	54 "	(22.5 per cent.)
120 - 130	23 "	(9.75 per cent.)
130 - 140	11 "	(4.57 per cent.)
Above 140	5 "	(2.08 per cent.)
Total,	241 cases	

In 16 cases the maximum pulse-rate during the first week was over 130. In only 3 of these could a satisfactory cause be assigned.

TABLE IV.

CASES SHOWING A MAXIMAL POSTOPERATIVE PULSE-RATE OF ABOVE 130 DURING FIRST WEEK.

GYN. NO.	PULSE-RATE.	DAY.	APPARENT CAUSE.
5588	132	Second.	Not clear.
10059	132	Sixth.	" "
10587	132	Second.	" "
10394	132	Third.	" "
11052	132	Second.	Bronchopneumonia.
2500	136	Third.	Not clear.
8476	136	Second.	" "
9221	136	Third.	" "
858	140	Fifth.	" "
6724	140	Second.	" "
8089	140	Fifth.	" "
12583	144	Third.	Intestinal obstruction; beginning post-operative peritonitis.
1212	148	Third.	Not clear.
10983	160	Second.	Pulse before operation 160; almost imperceptible after operation. Rapid and irregular during convalescence.
2772	152	Third.	Not clear.
10300	170	First.	Not clear.

In 11 cases the pulse-rate remained high during convalescence, and in only 2 of these (Gyn. No. 10983 and 12583) could a satisfactory cause be assigned.

In Gyn. No. 3980, 5588, 6585 and 7073 the pulse-rate was above 100 for several days.

In Gyn. No. 2598 and 7816 the pulse was irregularly rapid, reaching 110 on several occasions.

In Gyn. No. 11111 convalescence was slow, and the pulse during the last nineteen days ranged between 112 and 84.

In Gyn. No. 6760 the pulse rose to 130 on the second day, and during convalescence ranged between 110 and 90.

In Gyn. No. 10300 the pulse immediately before operation was 90. The evening following operation it rose to 162. During the next nine days it gradually dropped to 100, and from this time until the date of discharge ranged between 100 and 90.

The two cases in which a definite cause for the acceleration could be assigned were Gyn. No. 10983 and 12583. In the former the pulse immediately following operation rose to 160. It continued high and irregular, ranging between 116 and 104 from the sixth to the thirty-second day. In this case there was a rather severe postoperative hemorrhage, the details of which are considered on p. 549.

In Gyn. No. 12583 the continued rapid pulse was undoubtedly due to the intestinal obstruction and commencing postoperative peritonitis.

Hysterical Manifestations.—In Case 2710 a myoma, 5 x 5 cm., and the left tube and ovary were removed. On her admission to the hospital it was noted that the patient, who was forty years old, was very nervous and hysterical. During her convalescence she had several hysterical attacks, but these in no way retarded her recovery.

The patient in Case 7886 was also forty years old. On admission she complained of general nervousness. Several myomata were removed. Her convalescence was complicated by nervousness of an extreme type.

In Case 8259 the patient was forty-two years old and complained of marked nervousness. A myoma, about 7 cm. in diameter, was removed. Her nervous condition is now (six years after operation) even worse, and her own life and that of her family are rendered miserable by her morbid imaginations.

It will be noted that in each of these three cases the nervous phenomena antedated operation, and that the extra strain of operative interference merely served to accentuate them.

Excessive Nausea and Vomiting.—In Case 2039 there was much nausea, but no vomiting. In Case 10300, 11 myomata were removed; the same night the pulse reached 170, and nausea persisted until the seventh day.

The nausea in Case 10497 persisted for four days, although only two small myomata had been enucleated.

In Case 4873 two large interstitial myomata were removed, and a dermoid cyst was resected from the right ovary. Nausea and vomiting were present for five days.

In Case 5801 several myomata were enucleated. During convalescence there were two attacks of nausea and vomiting. The patient vomited a blood-stained fluid each time.

In Case O., operated upon at the Hebrew Hospital, continuous vomiting persisted for several days, the vomitus sometimes being of a dark chocolate color. Such vomiting is usually followed by death. As seen on p. 551, this patient had acute nephritis and extensive sloughing of the anterior uterine wall. She recovered and now, five years later, is perfectly well.

Stereoraceous vomiting is usually indicative of obstruction, and is always a grave symptom. In Case 2598 a myoma of the right cornu, together with the corresponding tube and ovary, was removed. The patient had persistent vomiting for six days. At this time the stomach was washed out and a large quantity of stereoraceous matter came away. The patient recovered.

A reference to p. 533 will give a description of the excessive vomiting noted in fatal cases.

Postoperative Hemorrhage.—We include here only those cases in which, notwithstanding the hemorrhage, the patient recovered. In two cases (Nos. 62 and 10983) secondary hemorrhage occurred. In the first case the bleeding was slight in amount; in the second, very extensive.

Gyn. No. 62.

Hemorrhage Following Abdominal Myomectomy.

M. S. L., single, white, aged thirty-three. Admitted November 28, 1889; discharged February 1, 1890. Operation. A myoma, approximately 7 cm.

in diameter, was removed, as well as the right tube and ovary. On the second day there was slight oozing, necessitating another ligature about the deep sutures in the uterus. The patient then made an uneventful recovery.

Gyn. No. 10983. Path. 7192.

Hemorrhage Following Removal of a Myoma.

C. B., colored, aged thirty-two. Admitted January 9; discharged February 11, 1904. Operation, removal of an intraligamentary myoma, about 12 cm. in diameter, and enucleation of several nodules from the posterior wall. After the patient reached the ward it was noticed that the abdominal dressings were markedly stained. Her pulse rose from 116 to 130. An hour later it was 140, and the dressings were soaked with bright-red blood. On removal of one stitch a quantity of blood filled the incision. As rapidly as possible it was sponged out. She was at once taken to the operating room, and the incision was opened. The abdominal cavity was filled with blood. As no bleeding point calling for control could be found in the uterus, gauze packs were placed in the cul-de-sac about the uterus. These apparently checked the oozing. She did well for twelve hours, but then her pulse again rose to 140, and the oozing was very free. The abdominal incision was again opened, two sutures were taken in the top of the uterus, whence the myoma had been removed, and ten minims of adrenalin 1:1000 were administered hypodermically. The bleeding was entirely checked, and from this time on she made a normal convalescence. Her highest postoperative temperature was 100.8° F.; the highest pulse was 160, on the second day. She was discharged on the thirty-first day.

Intense Abdominal Pain Following Abdominal Myomectomy.—Abdominal pain is a natural accompaniment of abdominal operations, but unless intestinal obstruction is present or peritonitis is developing, the pain is usually readily amenable to treatment. In only one of our cases was it excessive. In Case 11256, the patient, forty-two years of age, had a myomatous uterus extending almost to the umbilicus, and also complained of nervousness. An interstitial myoma, 15 cm. in diameter, was removed at the patient's request. Her highest postoperative temperature was 100° F., and from a physical standpoint she rallied readily, but for nearly a week she complained of the most intense agony. The pain was relieved by various simple remedies. It was with the greatest difficulty that she could be persuaded to leave her bed. She finally left the hospital on the thirty-seventh day. Three years later she was still excessively nervous, and said that her health was not good.

Such a case might very readily mislead the operator into reopening the abdomen, on the supposition that obstruction existed or that peritonitis was commencing.

Postoperative Cystitis.—This not infrequent complication following an abdominal operation is sometimes undoubtedly due to carelessness, but in other instances occurs without any appreciable cause.

In Case 8389 an interstitial myoma, about 6 cm. in diameter, was found at the junction of the cervix and corpus on the left. The nodule was removed. The patient developed a severe cystitis, although she was never catheterized in the ward. It had not entirely subsided when she left the hospital, and although her health was good six years later, she still suffered from "bearing-down pains" in the vesical region.

In Case 8462 many myomata, the largest $7 \times 7 \times 14$ cm., were removed. Convalescence was complicated by a cystitis. The patient was well six years later.

In Case 6762 a myoma, $6 \times 6 \times 7.5$ cm., lay between the vesical reflection and the uterus. Catheterization was necessary up to the twenty-third day on account of retention. A cystitis developed and lasted for two years. At present, eight years later, there is no bladder disturbance, but the patient has *tabes dorsalis*.

In this case the persistent retention was an undoubted factor in the causation of the cystitis, and in the removal of the myoma from beneath the bladder the vesical blood-supply may possibly have been injured.

Nephritis Aggravated by Abdominal Myomectomy.—In Case 7753 a myoma, 3 cm. in diameter, was shelled out, a hysterotomy done for a polypoid condition of the endometrium, and the perineum repaired. Later the patient was transferred to the medical side for treatment for a chronic nephritis. The nephritis had been present before the operation, and it is interesting to see how much a patient can sometimes stand even when the kidney function is impaired.

The acute nephritis in Case O, operated upon at the Hebrew Hospital, was evidently due in part to the acute infection following the sloughing of the anterior uterine wall. With removal of the necrotic tissue the renal symptoms subsided, and the patient is well five years later.

Free Escape of Pus from the Urethra.—In Case 6474, in which the uterus extended for two-thirds the distance from the pubes to the umbilicus, a large interstitial myoma was removed per abdomen. The temperature reached 103.2° F. on the eighteenth day, and a persistent phlebitis developed in the left leg. Sixty cubic centimeters of pus escaped from the urethra. Its source could not be definitely ascertained, but possibly it came from a small pelvic abscess that may have opened into the bladder. Such an evacuation of an abscess is well instanced in Case 5359, described on page 553.

A Foul Uterine Discharge Following Abdominal Myomectomy.—In Case 10394 the patient, thirty-four years old, had a submucous myoma, $2.5 \times 5 \times 9$ cm. A drain was carried down through the uterus to the vagina, and a small drain left in the lower end of the abdominal incision. On the third day the temperature reached 103° F., and on the removal of the uterine drain a foul discharge came away. On the nineteenth day the patient had a chill, and the temperature was 104° F.

The tumor, on removal, was found to be lobulated, dirty gray in color, and

had a foul smell. Histologic examination showed an acute inflammation. There was much degeneration of the tissue, and infiltration with polymorphonuclear leukocytes. The infection from the degenerated submucous myoma readily accounts for the offensive discharge. The patient was well three and one-half years later.

In Case C. H. I. S., admitted June 9, 1903, a soft, cystic, submucous myoma, 10 cm. in diameter, was removed. On the sixth day the temperature reached 103.6° F., but then dropped to normal. There was a most offensive uterine discharge. The patient's health was fair four years later.

In Case O., operated upon in the Hebrew Hospital, nearly all the anterior uterine wall came away, and there was naturally a most offensive and abundant uterine discharge.

In each of these cases the uterine cavity was opened up at operation, and in the first and third cases the cause of the offensive discharge was readily explained.

Sloughing of the Anterior Uterine Wall After Removal of a Large Interstitial Myoma.—In this case, although the patient's urine contained much albumin, we were forced to operate on account of the pressure symptoms. The globular uterus extended almost to the umbilicus. During removal of the tumor the uterine cavity was slightly opened. Persistent nausea and vomiting followed the operation, the vomited material at times being of a chocolate color. The urine contained much more albumin and many casts after operation. A vaginal discharge having appeared, the cervix was split and quantities of the necrotic anterior uterine wall were removed. Had it not been for this evacuation of the uterine contents, the patient would undoubtedly have died of infection.

Why the anterior wall sloughed it is, of course, impossible to determine with certainty. Opening into the uterine cavity during operation naturally provides an avenue of infection if the uterine cavity contains pus-organisms. In this case also the nephritis naturally reduced the patient's resistance.

Had it not been for the fact that the suture line in the uterus was brought into intimate contact with the anterior abdominal wall as the result of the fixation (the patient being near the menopause and single), the thin and rotten shell of the anterior uterine wall would certainly have perforated and the patient died of peritonitis.

O., Hebrew Hospital.

Sloughing of the Anterior Uterine Wall Following Abdominal Myomectomy.

O., admitted to the Hebrew Hospital July 14, 1902. The patient had been suffering for several years with a myomatous uterus, and for the last four or five days her legs had been markedly swollen and she had been forced to remain in bed. The urine contained much albumin and many casts. Operation, however, could not be avoided, as there were distinct pressure symptoms. When the abdomen was opened, a myoma was found extending almost to the umbilicus, and

situated in the anterior wall. It was peeled out without difficulty. It was fully 11 cm. in diameter, and there was a good deal of bleeding. At two points the uterine cavity was opened. The cavity was closed with catgut sutures, and the uterus firmly fastened to the anterior abdominal wall. The appendages were normal.

July 17th: Ever since operation the patient has been vomiting. The vomitus has a chocolate color. The stomach has been washed out, and since then the nausea has been much less marked. To-day the pulse is better, and the patient shows some improvement. The urine still contains many casts.

July 20th: The urine contains quantities of albumin and casts. She has improved very little and for the last few days has been delirious. There has been a most offensive uterine discharge for several days. On examination under anesthesia we found fetid pus escaping from the cervix. On stretching the cervix and curetting, only a slight amount of tissue came away, but on careful examination of the anterior uterine wall where the myoma was situated, and on making a little traction, masses of necrotic uterine tissue were brought away. We removed in all fully a large handful of the necrotic uterine wall, without, however, causing any hemorrhage. To insure free drainage we split the cervix posteriorly back as far as the internal os, and controlled all bleeding points with catgut. The uterine cavity was then irrigated thoroughly and packed with iodoform gauze. The patient made a gradual recovery.

July 1, 1907: The patient is in excellent health five years after operation.

Pelvic Peritonitis Following Abdominal Myomectomy.—Where there have been pelvic adhesions associated with a myomatous uterus there is liable to be slight pelvic peritonitis following operation if all oozing is not checked and no vaginal drainage is provided for.

In Gyn. No. 5826 two large myomata were removed from the uterus. One of these was partially covered with omental adhesions. After the operation the patient had a slight bronchitis, and her temperature reached 101° F. At the time of her discharge there was some slight induration and tenderness in the posterior vaginal fornix. The patient was well nine years after operation. Such thickenings often disappear spontaneously in a short time.

In Case 4537 a colored woman, forty-two years of age, had an interstitial myoma, 5 x 6 cm., and a tubo-ovarian cyst, which was densely adherent to the posterior surface of the uterus. Both were removed. A month later the pelvis was opened through the vagina and about 300 c.c. of encysted sero-hemorrhagic fluid came away. On account of prolapsus the cervix was removed and the perineum repaired. The patient was in fair health nine and one-half years later.

Intestinal Obstruction Following Abdominal Myomectomy.—In only one of our 280 abdominal myomectomies in which recovery took place did we have intestinal obstruction. In Case 12583 the patient was thirty-seven years old. At operation the left appendages were liberated from adhesions, and the right appendages removed on account of a corpus-luteum cyst; two interstitial myo-

mata, the larger 2.5 cm. in diameter, and the appendix, which was slightly constricted near its base, were also removed. On the third day signs of intestinal obstruction developed. When the abdomen was opened, no evidence of general peritonitis could be found, but a loop of gut had become adherent to the posterior surface of the uterus. The intestine at this point was thickly coated with fibrin. Recovery after the second operation was uneventful. The patient is well eighteen months later.

Where obstruction can be definitely diagnosed there should not be any delay in opening the abdomen.

For the fatal cases of obstruction see p. 533.

Leukocytosis Following Abdominal Myomectomy.—When a purulent accumulation is present, one naturally expects to find an increase in the number of leukocytes. We have had one case in our series, however, in which the leukocytosis developed and subsided without our being able at any time to detect the purulent focus. In Case 8773 the patient was thirty-eight years old and single. Many myomata were present, thirteen separate incisions being made through which to remove them. The patient, who was extremely nervous and had had fits of depression prior to operation, did well for a few days after operation, but from the eleventh to the twenty-first she ran a temperature, reaching 102.8° F. on the fifteenth. On the nineteenth day the leukocytosis reached 18,000. She rapidly improved, and left the hospital on the twenty-fifth day in excellent condition, and with the nervous depression seemingly relieved.

Abscess in the Broad Ligament Developing After Removal of a Myoma. Spontaneous Evacuation into the Bladder.—In the following case a large intraligamentary myoma lay partly in front of the uterus, but chiefly to the left, between the peritoneal folds. Enucleation was easy, but closure of the resultant space difficult. Several days after operation an abscess developed in the space formerly occupied by the myoma, and soon opened into the bladder.

In this case it would have been wiser at the time of operation to have carried a small retroperitoneal drain from a point just above Poupart's ligament down to the point at which the myoma had been removed.

Vaginal drainage was not attempted earlier on account of the danger of injuring the left ureter or the uterine artery. The patient was well ten years later.

Gyn. Nos. 5359 and 5560.

Abscess of the broad ligament developing after removal of a myoma (Fig. 329).

L. W., single, aged thirty-five. Admitted June 27, 1897; discharged September 6, 1897. Operation, June 28, 1897, myomectomy and suspension of the uterus. A myoma, 7 x 9 x 12 cm., was shelled out of the left broad ligament (Fig. 329). The temperature rose steadily after operation, reaching 104.6° F. on the fourth day. It then fell slowly, reaching 100° F. on the sixteenth, and becoming normal on the forty-eighth day. Several days after operation there

was a sudden escape of pus from the bladder, with an improvement in the condition. The urine contained quantities of pus for a considerable time. Shortly afterward the pelvis was drained through the vagina, and on November 22, 1897, it again became necessary to open the pelvis through the vagina, about 60 c.c. of thin grayish pus escaping. On January 14, 1898, the vaginal opening was again dilated, but no pus came away. In November, 1900, all vestige of the former trouble had disappeared, and the pelvis was absolutely free from any thickening. The patient was perfectly well ten years after operation.

Tonsillitis.—This complication is a by no means rare one, particularly in old institutions, and the sudden rise of temperature, especially after an abdominal myomectomy, may alarm the surgeon until the cause of the fever is ascertained.

In only one case (5873) did tonsillitis develop. In this case five small myomata and the appendix had been removed, and a radical cure for left inguinal hernia had been done a month later. Recovery was satisfactory.

Bronchitis.—The anesthetic employed in the early years of the department was chloroform, but since 1894 ether alone or preceded by nitrous oxid or ethyl chlorid has been the anesthetic in common use.

In two out of the 280 successful cases a bronchitis developed. In Case 8389 an interstitial myoma, about 6 cm. in diameter, was removed. The patient developed a severe cystitis and a slight bronchitis, neither of which was absolutely cured when she left the hospital.

In Case 5826 two fairly large myomata were removed. The patient developed a marked bronchitis that lasted several days.

Pleurisy.—In 3 of our 280 successful cases pleurisy occurred during convalescence.

In Case 4415 a wedge of adenomyomatous tissue, 2 x 5 cm., was excised from the posterior uterine wall. During convalescence the patient had phlebitis and pleurisy with effusion. With the development of the pleurisy the temperature rose to 102° F. The patient remained well for two years, after which the uterine hemorrhages recurred.

In Case 8764 four myomata were removed. On the twelfth day the patient complained of a sharp pain at the lower angle of the right scapula. At this point there were impaired resonance and a slight friction rub. The pulmonary dullness disappeared completely in five days.

In Case 1576 seven myomata were removed. Convalescence was interrupted by a definite attack of pleurisy, with effusion in the right chest, accompanied by

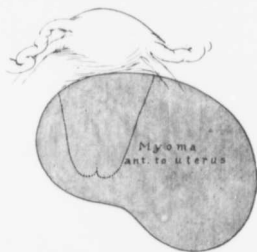


FIG. 329.—A MYOMA OF THE BROAD LIGAMENT.

Gyn. No. 3159. The myoma lay partly between the bladder and uterus, but chiefly in the left broad ligament. After removal of the myoma peritonitis and abscess developed in the left broad ligament and opened into the bladder.

a cough, fullness of that side of the chest, and a temperature of 102.2° F. Eleven years later the patient "died very suddenly from hemorrhages—she vomited blood." The letter strongly suggested death from pulmonary tuberculosis.

Bronchopneumonia.—In Case 11052 the patient was twenty-seven years old. A myoma, 3 cm. in diameter, was removed from the fundus. She developed bronchopneumonia; the temperature rose to 104.5° F. on the second day, and slowly dropped, reaching normal on the eleventh day. The subsequent course was uneventful.

Lobar Pneumonia.—In Case 660 a large pedunculated myoma and the left tube and ovary were removed from a woman thirty-six years old. The myoma was enveloped in many omental adhesions. The temperature on the second day was 101.4° F., but below 101° until the fourteenth day, when she had a chill, a cough, and a temperature of 105.2° F. A few days later a consolidation in the right lower lobe was made out. Finally she made a perfect recovery.

In Case 8764 several myomata were removed and the uterus was suspended. The patient, a white woman, aged thirty, on the thirteenth day complained of sharp pains at the lower angle of the right scapula. Resonance was impaired, the respiratory sounds were harsh, a slight friction-rub was detected, and later a distinct area of consolidation. This entirely cleared up before she left the hospital.

Phlebitis Following Successful Abdominal Myomectomy.—From the accompanying table it will be seen that in six out of 280 cases a phlebitis developed. In five of these the thrombosis was situated in the left leg. In Case 4415 the history note does not mention which leg was involved.

PHLEBITIS FOLLOWING SUCCESSFUL ABDOMINAL MYOMECTOMIES.

CASES.	SIZE OF MYOMATA.	ONSET.	LOCATION.
12504	Four myomata, largest 4 cm. in diameter.	Seventeenth day.	L. saphenous vein.
12028	Several small myomata.	L. femoral vein.
10573	Multiple myomata, largest about 7 cm. in diameter. (Hemoglobin, 38 per cent.)	Seventeenth day.	L. saphenous vein.
9329	Myoma, 3 cm. in diameter. Repair of complete perineal tear.	Slight phlebitis in left leg.
6474	Myoma, 10 cm.	Phlebitis in left leg obstinate.
4415	Adenomyoma; removal of wedge 2 x 5 cm.	Phlebitis (side not noted). Pleurisy.

Besore Following Abdominal Myomectomy.—In Case MeA. (p. 512), in which an 89-pound myoma was removed, the patient had edema of the buttocks and legs. On account of marked dyspnea the operation was performed with the patient in the sitting posture. Notwithstanding the greatest care a besore developed a few days after operation. It retarded her recovery only very slightly.

ABDOMINAL OPERATIONS NECESSARY SUBSEQUENT TO ABDOMINAL MYOMECTOMY.

As a result of the many letters sent out we have information concerning the greater number of the 280 myomectomy patients, with the following results:

CASE.		
12504.	Release of vesical, intestinal, and ovarian adhesions.....	1
7566.	Relief of intestinal obstruction.....	1
2709½ + 5635.	Repeated myomectomy.....	1
4517 + 7073.	Removal of ovaries.....	2
5359 + 5560.	Evacuation of pelvic abscess.....	1
706,4329,4925,	5076, 5846, 6760, 7779, 7886, 8230, 8936, U. P. I. + C. H. I., Ser. No.	1
1582,	Hysterectomy.....	12
	Total.....	18

Release of Vesical, Intestinal, and Ovarian Adhesions.—In Case 12504 a myoma, 4 x 4 x 3 cm., was removed from the right uterine cornu, and several other very small nodules were shelled out. The appendages were normal. Sixteen months later the abdomen was opened on account of pelvic pain. Fig. 330 shows the findings. The bladder was adherent to the anterior surface of the uterus. A loop of small bowel was partially kinked and firmly fixed to the posterior surface of the uterus on the right side, and also firmly glued down to the inner edge of the right ovary.

This case demonstrates clearly the danger of postoperative adhesions. It is impossible to prevent the intestines from adhering to the suture line in the uterus if the myoma is situated in the posterior wall of the uterus. When located in the anterior wall, suspension of the uterus will often cover in the raw area completely.

Gyn. No. 12504.

Abdominal myomectomy. Subsequent operation for release of vesical, intestinal, and ovarian adhesions (Fig. 330).

A. S., single, aged thirty-eight, white. Admitted November 10, 1905; discharged thirty-two days later. A myoma, 4 cm. in diameter, was removed from the vicinity of the right uterine horn, and the opening closed with through-and-through sutures of plain catgut; other small myomata were also enucleated. On the seventeenth day the patient complained of pain in the left leg, with some swelling. On November 16, 1907, the abdomen was again opened. We removed the appendix, which was enlarged and injected. There were numerous adhesions to the ascending colon. The bladder was drawn up over the anterior surface of the uterus (Fig. 330). These adhesions were easily liberated. A loop of small bowel was adherent to the posterior surface of the uterus by numerous exceedingly vascular adhesions, which were also easily separated, and the same loop was adherent to the right ovary over an area 1.5 cm. in diameter. The relation between the ovary and the bowel was an exceedingly intimate one. After

loosening up adhesions we found that the outer coat of the bowel had been sacrificed to a slight extent. The raw surfaces were approximated with Pagenstecher sutures.

This complication is of great interest. At the previous operation the uterus was free from adhesions and the appendages were normal. The intestine had undoubtedly become adherent to the uterus over the area of the myomectomy, probably as the result of the irritation produced by the ends of the catgut sutures. Why the intestine became adherent to the ovary it is impossible to say.

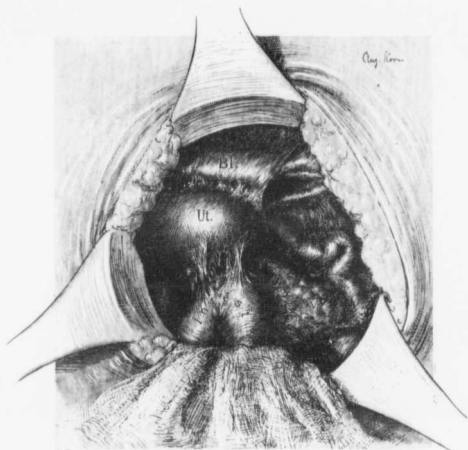


FIG. 330.—PELVIC ADHESIONS FOLLOWING ABDOMINAL MYOMECTOMY.

GYN. No. 12504. This was the condition found sixteen months after a myoma, 4 cm. in diameter, had been removed from the vicinity of the right uterine cornu. Several other small nodules were also enucleated. The bladder is adherent to the anterior surface of the uterus. A loop of small bowel was firmly fixed to the posterior surface of the uterus, and also to the right ovary.

Intestinal Obstruction Following Years After Abdominal Myomectomy.—We have had one case of this character. In 1886 a conservative pelvic operation, of the nature of which we know nothing, was performed. Fourteen years later the patient entered the Johns Hopkins Hospital and a myoma, three times the size of the uterus, was removed. Intestinal adhesions were released, and the uterus was suspended. The following year another surgeon removed the appendix, and subsequently had to open the abdomen for obstruction, releasing many adhesions, and resecting a portion of the small bowel. A few months ago the patient had typhoid fever. In January, 1907, she reported that her health was not good.

In this case the myomectomy was in no way responsible for the adhesions, as these were present before the operation.

Gyn. No. 7566.

Abdominal myomectomy with subsequent removal of the appendix; later dense adhesions producing intestinal obstruction and requiring resection of the bowel. Recovery.

M. E., white, single, aged forty. Admitted February 10; discharged March 10, 1900. She said that a conservative abdominal operation had been done fourteen years before, the nature of which we do not know. At operation various intestinal adhesions were released, a myoma was removed from the uterus, and the uterus suspended. The uterine tumor was about the size of a two months pregnant organ. The tubes and ovaries were not diseased. In a letter received from her seven years later she states that in the following year her appendix was removed, and that later on, on account of dense adhesions and intestinal obstruction, it was necessary to open the abdomen again and remove a portion of the small intestine. In 1906 she had typhoid fever.

Repeated Myomectomy.—In one case in which a myoma was situated in the left cornu, the cornu and the left appendages were removed after liberation of many adhesions. Three and a half years later, after release of adhesions, two small myomata were removed from the anterior wall of the uterus.

Gyn. Nos. 2709½ and 5635.

C. B., aged fifty-six, white, widow. Admitted April 9; discharged May 5, 1894. A myoma, 5 x 6 x 7.5 cm., was removed from the left cornu. Pelvic adhesions were liberated, and the left tube and ovary were removed.

The patient returned to the hospital (No. 5635) on October 27, 1897, and was discharged November 24th of the same year. The operation this time consisted of a myomectomy with removal of the right tube and ovary. Adhesions were present between the uterus and omentum, small intestine, and bladder. Two small myomata were removed from the anterior wall of the uterus near the cervix. The patient made a good recovery.

Removal of Ovaries Subsequent to Myomectomy.—In Case 4517 four small myomata were removed and the uterus was suspended. The appendages were normal. About ten years later she had another abdominal operation, of the character of which she knows nothing. A few months later she had her ovaries removed, for what reason we do not know.

In Case 7073, after release of the adherent appendages, an interstitial myoma, 7 cm. in diameter, was removed. A few months later she came under the care of another physician, and her ovaries were removed, with temporary benefit.

Gyn. No. 4517.

Removal of ovaries after myomectomy.

E. T., single, aged thirty-nine. Admitted July 17; discharged August 16, 1896. Operation, July 18th. Myomectomy and suspension of the uterus. Four small myomata were enucleated. The appendages were normal. On June 10, 1907, we received a communication from the patient saying: "The operation did but little good. It only patched me up for about a year. From then on I have been a great sufferer." Last year she had an operation performed at another hospital, and in April of this year had her ovaries removed. Their condition we do not know. Of course, in this case it is quite possible that the adhesions of the ovary were in no way the result of the previous operation, especially as the patient remained well for the first year.

Gyn. No. 7073.

Myomectomy with subsequent removal of the ovaries.

M. S. H., aged thirty-six, white, married. Admitted July 13; discharged August 22, 1899. Operation, myomectomy with release of adherent tubes and ovaries; suspension of the uterus. The myoma was subvesical. After its removal a good many sutures were necessary on account of the bleeding from the stitch holes.

April 29, 1907: A letter from Dr. A. F. Brant, of Heathsville, Va., says that the patient experienced little relief from the operation. She returned to another hospital within a few months and had both ovaries removed.

Of course, in this case the adhesions in the pelvis already existed. An attempt was made to rectify matters without sacrificing the organs.

Evacuation of a Pelvic Abscess Months After a Myomectomy.—In Case 5359, in which a broad ligament myoma was removed, an abscess developed. This opened into the bladder. Before the patient left the hospital it was necessary to drain the pelvis through the vagina, and on several occasions after she left the hospital it was found expedient to reestablish the pelvic drainage. This case is reported in full on p. 553.

HYSTERECTOMY SUBSEQUENT TO ABDOMINAL MYOMECTOMY.

In the following pages several cases are described in which removal of the uterus became necessary later. These cases naturally fall into two definite groups:

1. Hysterectomy on account of pelvic adhesions.
2. Hysterectomy on account of the development of other myomata.

Hysterectomy on Account of Postoperative Adhesions.—Cases 5076, 5846, and

San. 1582 belong to this group.* In Case 5076 an interstitial myoma, 6 x 7.5 x 9 cm., was removed, and portions of both ovaries were resected on account of an ovarian cyst. Two years later Dr. George Ben Johnston, of Richmond, found it necessary to remove the uterus and appendix.

In Case 5846 a reference to the history shows that a myoma, 2 cm. in diameter, was removed, and pelvic adhesions were released. Five years later hysterectomy was done for pelvic adhesions.

The uterus in San. 1582 contained a myoma, 4 cm. in diameter; this and the appendix were removed. Later a hysterectomy was required on account of dense pelvic adhesions, probably gonorrhoeal in origin.

Adhesions may be due to so many different causes and are so frequently associated with myomata before operation that it is difficult to attribute pelvic adhesions to the myomectomy unless the adhesions are chiefly around the uterine incisions from which the tumors have been enucleated, and even then, where adhesions have once existed, there seems to be a marked tendency for them to reform.

Gyn. No. 5076.

Abdominal myomectomy with subsequent hysterectomy on account of pelvic adhesions.

M. C., white, married, aged forty-five. Admitted March 7; discharged April 26, 1897. Operation, March 8th, myomectomy; cystectomy. An elliptic incision, 6 cm. long, was made in the anterior wall of the uterus, and an interstitial myoma, 6 x 7.5 x 9 cm., enucleated. A Graafian-follicle cyst of the right ovary was dissected out. On February 21, 1907, we received the following letter from the patient: "My health was not improved by my stay in the Johns Hopkins Hospital. Two years later I went to Dr. Ben Johnston, of Richmond, who removed the uterus and appendix."

Gyn. Nos. 5846 and 10183.

Abdominal myomectomy with subsequent hysterectomy on account of adhesions.

E. L. A., white, aged thirty-three, married. Admitted February 4; discharged March 4, 1898. Operation, February 5, 1898. Two small vaginal cysts were removed, a subperitoneal myoma 2 cm. in diameter was enucleated, pelvic adhesions were freed, and the uterus was suspended.

Gyn. No. 10183. For two years after leaving the hospital the patient was in very good health, but during the last three years there has been a gradual increase in the menstrual discharge. Now the patient is in bed most of the time. She has a great deal of pain, especially in the left side.

* In Gyn. No. 8220, after liberation of the adhesions, two small myomata were removed from the uterus. Examination of the scrapings (Path. No. 4403) showed tuberculosis. Four months later the uterus was removed on account of the tuberculosis. The hysterectomy was in no way rendered necessary by the myomata.

January 14, 1903: Abdominal hysterectomy on account of somewhat dense adhesions.

Hysterectomy on Account of the Development of Other Myomata.—The following cases are of some interest, inasmuch as they not only show the number of myomata that may develop after a myomectomy, but also enable us to determine with relative accuracy the rate of growth of some of the myomata.

Often during a myomectomy minute white specks are seen either on the surface or in the musculature of the uterus. These are usually myomata, not over 0.5 or 1 mm. in diameter, and may be readily overlooked.

Fortunately, relatively few of our patients have required a secondary hysterectomy.

In Case 706 (also 1033 and 8415) a small subperitoneal myoma situated near the cervix was removed in 1891. Ten years later the uterus was everywhere studded with small myomata and filled the pelvis. Hysterectomy was performed.

In Case 4925 (also 9439) an interstitial nodule, 12 x 21 x 27 cm., was removed. Fifty catgut sutures were necessary to close the resultant space. Five years later the uterus seen in Fig. 331 (p. 562) was removed.

Case 7779 (also 12689) affords a very interesting example of the subsequent development of large myomata. A subperitoneal myoma, 9 x 10 x 12 cm., and several smaller ones, were removed in 1900 (Fig. 332). A little less than six years later the uterus was again enlarged, measured 12 x 13 x 16 cm., and contained numerous myomata. These were subperitoneal, interstitial, and submucous, the last of large size (Fig. 333 p. 564). Hysterectomy was performed.

In Case 7886 a pedunculated myoma, about 7 cm. in diameter, and several small interstitial nodules were removed in 1900. About six years later hysterectomy was performed, chiefly on account of dense adhesions between the uterus and surrounding structures. The uterus contained three small myomata, the largest 1 cm. in diameter. There was also some diffuse thickening of the inner muscular layers of the uterus, with early adenomyoma.

The left ovary and a myoma were removed in Case 8936 in 1896. Five years later hysterectomy was performed on account of dense pelvic lesions and interstitial and submucous myomata.

In U. P. I. Case G., five interstitial myomata, the largest 5 cm. in diameter, were removed. Seven and a half years later (C. H. I. Case G.) the uterus was densely adherent and contained several myomata. Hysterectomy was performed.

Judging from these cases only, one would doubt the wisdom of doing a myomectomy, but the cases requiring a second operation form a small percentage of the total number.

Case 706 (1033 and 8415).

Abdominal myomectomy with subsequent hysteromyomectomy.

This patient entered the hospital on April 28, 1891, when a dilatation and curettage was done. She returned to the hospital (1033) on October 28th of the same year, when a cervical myoma, 2 x 1.5 cm., was removed from the uterus through an abdominal incision.

Gyn. No. 8415. Again admitted December 29, 1900. On vaginal examination the cervix was found to be normal in size and in good position. Numerous nodules filled the pelvis. The uterus bulged forward, pushing outward the anterior vaginal wall. A hysterectomy was done. The patient made a perfectly satisfactory recovery.

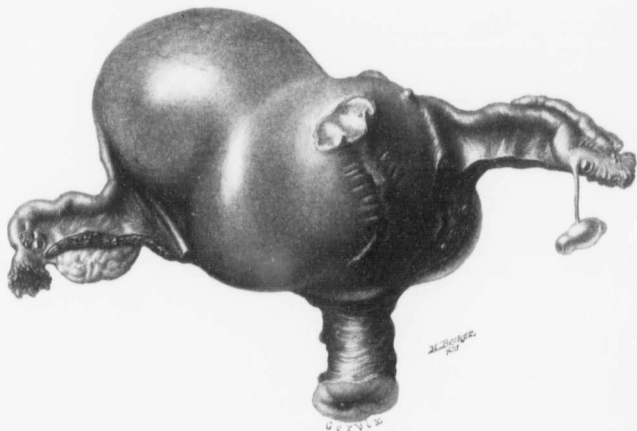

FIG. 331.—APPEARANCE OF A UTERUS FIVE YEARS AFTER REMOVAL OF A LARGE INTERSTITIAL MYOMA. ($\frac{1}{2}$ nat. size.)

Gyn. No. 9439. Path. No. 5640. Five years ago an interstitial myoma, 12 x 21 x 27 cm., was removed. The appendages and the cervix are normal. The scar on the anterior surface of the uterus shows clearly some of the transverse suture lines, and at the upper end of the scar is an oval area showing where the uterus was attached to the anterior abdominal wall. The enlargement in the fundus is caused by several myomata, and projecting from the fundus, near the right tube, is a large myomatous nodule. See Fig. 60, p. 77, for the appearance of the uterus at the first operation.

Path. No. 4595. The specimen consists of the uterus, which is approximately 13 x 10 x 11 cm. Surrounding it on all sides are myomata, sessile and pedunculated. It also contains interstitial and submucous nodules.

Gyn. Nos. 4925 and 9439.

Myomectomy with hysteromyomectomy five years later (Fig. 331).

S. J. L., white, single, aged forty-three. Admitted January 6; discharged

January 28, 1897. Operation, January 9, 1897, myomectomy. The uterus was twisted to an angle of 90 degrees (Fig. 60, p. 77). It contained one myoma 12 x 21 x 27 cm., in the anterior wall. The resultant space was closed with 50 catgut sutures.

Gyn. No. 9439. The patient was readmitted March 3, 1902, and operated upon on March 5th, a complete hysterectomy and appendectomy being performed. As soon as the abdomen was opened the scar of the old myomectomy was seen on the left anterior surface of the fundus (Fig. 331). The fundus itself was greatly enlarged, especially to the right, and there was a rounded tumor in the right cornu. The first glance at the specimen suggested a uniformly enlarged bicornate uterus. The patient made a perfectly satisfactory recovery.

Path. No. 5640. The specimen consists of the entire uterus with the appendages. Its general form is seen in Fig. 331.

Gyn. Nos. 7779 and 12689.

Abdominal myomectomy with hysteromyomectomy nearly six years later (Figs. 332 and 333).

R. W., aged thirty-one, white, single. Admitted April 30; discharged May 26, 1900. Operation, May 3, 1900, myomectomy. The largest tumor was situated in the posterior wall of the uterus, and was very offensive, apparently undergoing degeneration. Several other smaller myomata were removed from various portions of the uterus (Fig. 332). The patient made an uninterrupted recovery.

Path. No. 4038. The large myoma measures 9 x 10 x 12 cm. Its surface is rough and shaggy, and on section presents an area of degeneration consisting of a soft disintegrating mass.

Gyn. No. 12689. Readmitted February 10, 1906. The patient had some discomfort for a year following the previous operation, but remained perfectly well for four years. A few months ago she began to have pain in the iliac fossa and in the hip, aching in character. One month ago the menstruation lasted nearly thirty days.

Operation, panhysterectomy. The peritoneal surface of the uterus was everywhere smooth. There was one small band of adhesions from the pelvic wall to the region of the left ovary. On superficial examination there were no signs whatever of the previous operation. The patient made a perfect recovery.

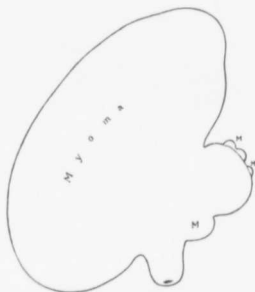


FIG. 332.—MYOMATA REMOVED BY ABDOMINAL MYOMECTOMY.

Gyn. No. 7779. Path. No. 4038. The large subperitoneal nodule projecting from the posterior surface of the uterus measured 9 x 10 x 12 cm. Projecting from the fundus, and also from the anterior surface, are other small nodules. For the appearance of the uterus about six years later see Fig. 333.

Path. No. 9558. The uterus is 15 cm. in length, 13 cm. in breadth, and 12 cm. in its anteroposterior diameter (Fig. 333). Attached to one point is a small tag of omentum. Projecting from the posterior surface is a pedunculated myoma, 2.5 x 1.5 cm. The enlargement in the uterus is due chiefly to one large and several smaller submucous myomata. The large myoma is 9 cm. across.

This case is particularly interesting, as it shows the possible developments in the course of six years.

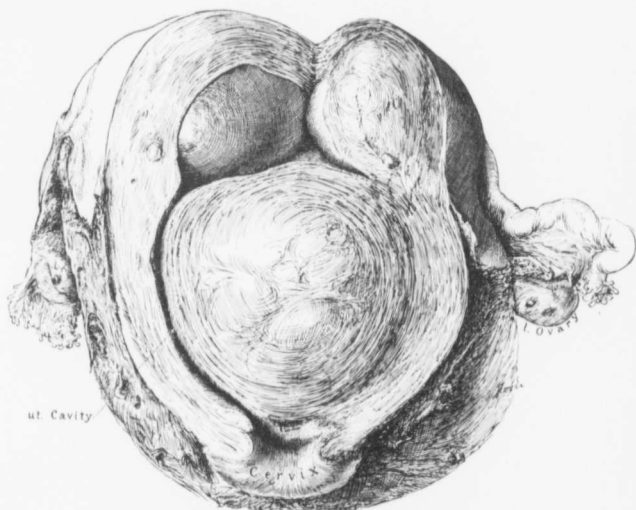


FIG. 333.—A UTERUS ABOUT SIX YEARS AFTER ABDOMINAL REMOVAL OF ALL MYOMATA THAT COULD BE DETECTED. (2 nat. size.)

Gyn. No. 12689. Path. No. 9558. The uterus measures 15 x 13 x 12 cm. The chief increase in size is caused by submucous myomata. The appendages are normal. For the appearance of the uterus when myomectomy was performed nearly six years before see Fig. 332.

Gyn. No. 7886. San. No. 2178.

Abdominal myomectomy followed six years later by hysteromyomectomy.

C. S., aged forty, white, married. Admitted June 9; discharged July 7, 1900. Operation, multiple myomectomy. A myoma 7 cm. in diameter was removed from the posterior surface of the uterus, and several smaller scattered ones were also enucleated. Convalescence was complicated by nervousness of an extreme type.

San. No. 2178. The patient was readmitted on May 2, 1906. In addition

to the myomatous uterus, there were marked adhesions around the left tube and ovary and to the surrounding structures. The rectum and intestines were slightly adherent on the right side.

Path. No. 9803. The uterus, both anteriorly and posteriorly, is enveloped in adhesions. It is very little increased in size, and contains three myomata, the largest 1 cm. in diameter. The right tube is bound down to the uterus. Its fimbriated end, however, is free. The ovary is little altered. The left tube and ovary show few adhesions, but the fimbriated end of the tube is normal. Microscopic examination in this case shows commencing adenomyomatous formation in the body of the uterus.

Gyn. Nos. 8936 and 9203.

Myomectomy followed by abdominal hysterectomy.

S. B., aged thirty-six, white. Admitted July 22, 1901. Five years before the patient had been operated on for sterility, and at that time a myoma was removed from the body of the uterus, and the left ovary also extirpated. The patient on admission was extremely pale; the hemoglobin was 15 per cent. She remained in the hospital for some time, and was sent home to recuperate.

She was readmitted on November 9, 1901, and discharged on December 7, 1901. Her hemoglobin had risen to 46 per cent. In the lower part of the abdomen, on the left side, was a hard mass made up of two distinct nodules that reached half-way to the umbilicus. This was very movable and tender. Operation, November 11, 1901, hysteromyomectomy; removal of the right tube and ovary; cure of ventral hernia. The sigmoid was densely adherent to the posterior wall of the fundus. This was cut free by leaving the outer sheath of the myoma and round ligament against the intestines. On the right side the pus-tube and cystic ovary were gradually pulled out of their bed of adhesions. The patient, on her discharge, had a hemoglobin of 75 per cent.

U. P. I., G., also C. H. I., G.

Myomectomy with subsequent development of other myomata.

This patient was seen in consultation with Dr. Thomas Linthicum, Savage, Md., on February 19, 1898. She was forty years old, and complained of profuse and frequent menstruation. On February 23d a myomectomy was done. The uterus was the size of that of a three and one-half months' pregnancy, nodular, and contained five interstitial myomata, which were removed through three incisions. The largest myoma was 5 cm. in diameter. On March 23, 1899, the uterus was only slightly enlarged and freely movable.

On December 11, 1902, the patient was admitted to the Church Home and

Infirmary. On examination we found a nodule, fully 10 cm. in diameter, on the left side. The adhesions were broken up and the uterus was removed. The patient's health five years after the second operation was "tolerably good."

IMMEDIATE RETURN TO THE HOSPITAL ON ACCOUNT OF ADHESIONS.

In Case 6760 a partially submucous myoma, 15 cm. in diameter, was removed *per abdomen*. The patient made a fair recovery, but two days after her discharge returned to the hospital. The abdomen was reopened and dense adhesions were found between the ileum and fundus along the myomectomy line. During their liberation the ileum was torn. Hysterectomy was performed, but the patient never reacted satisfactorily and soon died. Examination of the mucosa showed a marked endometritis, and it is quite probable that the pelvic infection was due to the wide opening up of the uterine cavity to permit the enucleation of the myoma.

Gyn. Nos. 6760 and 7036. Path. Nos. 3052 and 3315.

Intestinal obstruction following shortly after abdominal myomectomy.

Mrs. L., admitted March 13, 1899. At this time abdominal myomectomy was performed and an interstitial myoma, encroaching upon the uterine cavity and measuring about 15 cm. in diameter, removed. The patient improved fairly rapidly, and was discharged April 23d. Two days after leaving the hospital she had a return of the uterine hemorrhage. There was constant oozing, and the uterus was increased in size. At the second operation it was found that the fundus was twice the normal size. The appendages were bound down and the ileum was adherent to the fundus along the line of the former incision. During the separation of these adhesions the ileum was ruptured. The sigmoid and rectum were also densely adherent to the floor of the pelvis and the posterior surface of the fundus. Complete hysterectomy was done, and the rent in the bowel sutured. The patient died on July 6, 1899.

Path. No. 3315. Histologic examination of the mucosa shows a marked endometritis.

PREGNANCY FOLLOWING MYOMECTOMY.

Letters were sent to all patients upon whom an abdominal myomectomy had been performed, in order to learn not only about their subsequent health, but also whether they had borne children after the operation. A large number of answers were received.

After ruling out those that died immediately after operation, unmarried patients, widows, women over forty-five, and those patients upon whom a sub-

sequent hysterectomy was performed, we still have 94 patients in whom pregnancy was possible.

As we all know, the menopause occurs early in some and late in others, consequently we took a middle ground in assuming forty-five as the arbitrary age at which the menses should cease; otherwise it would have been impossible to obtain an even approximate basis for our calculation. The accompanying table shows that 13 of the 94 patients have been pregnant—12 proceeding to term, and one miscarrying. In 8 of the cases there has been only one pregnancy, but in Case 10257 two children, and in Case 7159 three children, were born. In Case 2042 the patient, who was single at the time of operation, is now the mother of four. The patient in Case 4856 was single when operated upon. Over three years later she became pregnant; the labor was long and tedious, and finally Cesarean section was performed, with delivery of twins. The patient died apparently of shock. It will be noted that in this case suspension of the uterus had been performed.

When a long suture-line is left in the uterus after removal of a myoma, the chance of omental, intestinal, and other adhesions is great; on the other hand, if a suspension is done, the union with the anterior abdominal wall is liable to be very firm. In either case there is considerable danger. After carefully weighing the advantages and the disadvantages, we have decided that in those cases where it has been impossible to draw the round or broad ligaments up over the suture-line it is, as a rule, wiser to suspend the uterus after the myomectomy, provided the suture-line is in the upper part of the fundus or situated anteriorly. If far down posteriorly, the uterus is dropped back. True, there are numerous disadvantages associated with the suspension, but when we remember that in the majority of cases the patients do well, and further that, if malposition of the pregnant uterus should by chance exist, we can readily and promptly release it with little danger, we shall not hesitate to choose the lesser of the two dangers, and suspend the uterus in suitable cases.

In the accompanying table the size and situation of the myomata are given. Some of them were small and removed when the abdomen had been opened for other causes. The majority of the tumors were interstitial. It is particularly interesting to note that in Case 7159, in which a submucous myoma about 8 cm. in diameter was present and the uterine cavity was widely opened, the patient subsequently had three children. Of the 13 women that became pregnant subsequent to operation, 7 had previously been pregnant, 3 sterile, and 3 were single at the time of operation.

CASES OF PREGNANCY AFTER MYOMECTIONY.

No.	NAME.	AGE.	DATE OF OPERATION.	NUMBER OF PREGNANCIES BEFORE OPERATION.	SIZE OF MYOMATA.	NUMBER OF CHILDREN SINCE OPERATION.
1260	H.	30	March, 1892.	One.	One myoma, 2 cm. in diam. (suspension of uterus).	One.
1489	W.	35	July, 1892.	None.	One interstitial, about 6 cm.	One.
2042	R.	22	June, 1893.	Single, since married.	Subperitoneal pedunculated myoma, 16 cm. in diameter.	Four.
4856	H. P.	28	December, 1896.	Single, since married.	Myoma, 4 x 8 cm. (uterus suspended).	Died about four years later in twin labor. Cesarean section performed in a distant city after "a prolonged and exhausting labor."
5303	H.	40	May, 1897.	Two.	Subperitoneal myoma, 3 x 5 cm. (suspension of uterus, repair of perineum).	One miscarriage, nine years later.
5826	F.	34	January, 1898.	One mis. (?)	Two nodules, subperitoneal and pedunculated, 15 x 18 x 20 cm.; interstitial, 2.5 x 3.5 x 5 cm.	One.
7159	S.	31	September, 1899.	Three.	Partly submucous, about 8 cm. Cavity widely opened.	Three.
9243	N.	28	November, 1901.	None.	Two small interstitial myomata (release of adhesions, removal of right tube and ovary).	One.
9329	F.	38	January, 1902.	Three.	Myoma, 4 cm., in right cornu (repair of complete perineal tear; suspension of uterus).	One
10257	B.	23	February, 1903.	Single; since married.	Several small interstitial myomata.	Two
10479	W.	33	May, 1903.	Two.	(a) Submucous myoma, 2 cm.; (b) interstitial, 1 cm.	One.
11000	S.	36	January, 1904.	None.	Three myomata: (a) 2 cm., (b) 3 cm., (c) 4 cm. Removal of left hydrosalpinx.	One.
San. 1545	H.	32	March, 1903.	One.	Interstitial, 5 x 6 x 7 cm.	One.

PRESENT CONDITION OF PATIENTS AFTER AN ABDOMINAL MYOMECTIONY.

Letters were sent out to all patients, and from many replies were received. Where no response was forthcoming the family physician often kindly furnished the necessary data. Finally, in a good many cases the patients were visited in their homes and their present condition was ascertained.

Out of the 280 successful cases, we have accurate data of the subsequent history in 216.

137 patients are well at periods varying from a few months to sixteen years.

48 are in only fair condition. Some are suffering from pelvic trouble, but the large majority from lesions remote from the pelvis.

13 required subsequent operation for various troubles.

18 died chiefly from intercurrent affections.

216

Patients Remaining Well Years After an Abdominal Myomectomy.—We have endeavored to be as unbiased as possible in the grouping of these cases. In a few of the cases in the following table the patients were not absolutely well, but said that they were greatly benefited, and that their general health had been much better since operation, or that the operation had been the means of saving their lives.

Patients well	16 years after operation.	3 cases
" "	15 " " "	2 "
" "	14 " " "	1 case
" "	13 " " "	2 cases
" "	12 " " "	2 "
" "	11 " " "	3 "
" "	10 " " "	16 "
" "	9 " " "	9 "
" "	8 " " "	11 "
" "	7 " " "	7 "
" "	6 " " "	19 "
" "	5 " " "	10 "
" "	4 " " "	13 "
" "	3 " " "	18 "
" "	2 " " "	6 "
" "	1 year " "	14 "
" "	less than a year after operation.	1 case

137 cases

The reason that there are so few between the tenth and the sixteenth year is because at that time hysterectomy was performed much more frequently than myomectomy.

Patients in Fair Condition After an Abdominal Myomectomy.—In this group we have included those patients that are at present not well.

In Cases 9024 and 9329 there is a persistent cystitis; in Cases 5965, 9470, 11111, excessive menstrual bleeding, and in Cases 6773, 12028, and C. H. I., Peth., from the data received, we would not be surprised if the uterus contained more myomata. Thus in only 8 of 48 cases in which the patient is not well is the trouble definitely attributable to the pelvic organs. Of the remaining 40 patients, in Case 6070

there were symptoms of some spinal lesion, and in Case 6950 of asthma and emphysema. In Case 7218 there was a renal lesion, and in Case 7872 a gastric ulcer. The rest of the patients were either below par or complained of indefinite symptoms.

CAUSES OF DEATH IN PATIENTS SUCCUMBING AFTER LEAVING THE HOSPITAL.

Eighteen of the 216 patients concerning whom we have late records are dead.

No assigned cause (Cases 515, 1455,* and 7721).....	3 cases
Typhoid fever, three years later (Case 9215).....	1 case
Spinal meningitis, five months after operation (Case 4055).....	1 "
Liver abscess, several years later (Case 4160).....	1 "
Pneumonia. Ovaries removed in another hospital several months later. Died next year of pneumonia (Case 7073).....	1 "
Pulmonary tuberculosis, four years later suddenly (Case 1576).....	} 6 cases
eleven years later (Case 1821).....	
several years later (Case 1916).....	
five years later (Case 2189).....	
ten years later (Case 2500).....	
two years later (Case 6145).....	
Operation for release of adhesions (dense intestinal adhesions following shortly after patient left hospital; ileum torn during operation (Case 6700).....	1 case
Intussusception. Well after operation, sudden intussusception three years later (Case 8698).....	1 "
Cesarean section for twins several years after abdominal myomectomy (Case 4856).....	1 "
Obscure uterine lesions. "Died from uterine trouble" seven years later (Case 1685).....	} 2 cases
Died apparently from some pelvic lesion six years later (Case 4814).....	
	18 cases

* Died suddenly eleven years after operation, aged sixty-four.

CHAPTER XXX.

VAGINAL MYOMECTOMY.

In 84 of our cases vaginal myomectomy was performed. In several other cases a submucous myoma was enucleated preparatory to an abdominal hysterectomy. The latter cases are described elsewhere.

Age.—Submucous myomata, in our experience, are most common during the child-bearing period, as is indicated by the accompanying table, dealing with the age in 80 of the cases:

Between 20 and 30 years of age	8 cases
“ 30 and 40 “ “ “	29 “
“ 40 and 50 “ “ “	32 “
“ 50 and 55 “ “ “	11 “
	80 cases

The youngest patient (Case 4382) was twenty years of age. Three years previously she had borne a child. On admission, the uterus was found to be soft and thin. Projecting from the cervical canal, and filling the upper part of the vagina, was a sloughing mass, approximately 6 cm. in diameter. The patient made a good recovery.

Our oldest patient (Case 8159) was fifty-four years of age. A submucous myoma, 6 cm. in diameter, was twisted off, and the patient was well six years later.

Color.—In 83 cases we have data as to the color of the patient. Of this number, 64 were white and 19 colored.

Symptoms of Submucous Uterine Myomata.—The chief symptoms are hemorrhages and its sequences, and those due to pressure.

Vaginal Discharge.—If we bear in mind the various forms of submucous myomata, the various positions of submucous nodules, and the gradual disintegration of the myomata, the character of the uterine discharge will be readily understood.

Profuse menstruation is, as a rule, the first sign of a submucous nodule; the periods are also prolonged. Menorrhagia, as a rule, develops gradually, but, as in Case 7050, may be copious from the first. In some cases the hemorrhage may assume alarming proportions, as in Case 12591, in which the patient estimated a loss of from three to four pints. The flow may be bright red in color, dark, or even brownish; when excessive, it may be clotted, the patient passing pieces of tissue resembling liver.

In the majority of the cases bleeding is the most prominent symptom;

nevertheless, in a few, this phenomenon is entirely wanting. In Cases 10872 and 11010 no excessive flow was noted, and in Case 12257 the last period had occurred forty-six days before the patient's admission. In Case 1489 the flow was scant.

Leukorrhœa.—In several Cases (2291, 5687, 9875, and 11243) the discharge was leukorrhœal in character, in some of the cases being very offensive.

Profuse Yellowish Discharge.—In quite a number of cases the flow was yellowish in color, thick or thin, and most offensive.

Watery Discharge.—In Cases 7383 and 10872 the discharge was watery in character, and in Case 1150 it was watery and blood-tinged.

The hemorrhage usually indicates that a large area of uterine mucosa has been put on tension by the submucous myoma which acts as a foreign body. The offensive yellowish or watery discharge means that the tumor is undergoing necrosis and disintegration. The odor in some of these cases is so offensive that it takes hours to remove it from the hands.

With the loss of blood, secondary manifestations are noted. In Case 10376 the patient, on account of excessive hemorrhages, was compelled to remain in bed all the time. Her hemoglobin was only 30 per cent.

In Case 9638 the loss of blood was so great that the patient's vision was blurred and she was dizzy. Her hemoglobin was reduced to 21 per cent.

In Case 11889 the bleeding was severe, many clots being passed. Functional heart murmurs were heard, and the hemoglobin had fallen to 14 per cent.

Loss of Weight.—When the patient has had a constant loss of blood for years, there is likely to be a marked loss in weight, but when the symptoms, although severe, are of short duration, the patient may still be stout, although suffering from anemia.

Fever and Chills.—When a sloughing submucous myoma is present, it is but natural that absorption should occasionally follow, with a subsequent rise of temperature and acceleration of the pulse. We have seen the temperature reach 106° F.

Pressure Symptoms.—Submucous myomata must of necessity be or become much smaller than the pelvic cavity, in order that expulsion may take place through the vagina. Occasionally they reach the size of a "child's head," as in Case 1317. In Case 4663 the myoma was 18 cm. long, but much smaller in its other dimensions. When pressure symptoms are present, they are due either to large interstitial or subperitoneal nodules, or to a large tumor mass caused by a multiplicity of smaller nodules. Pressure symptoms are fully described on p. 448.

VAGINAL MYOMECTOMY.

It is only necessary for us to remember that we are usually dealing with a tumor partially or completely filling the vagina, and attached somewhere in the

uterine cavity by a pedicle varying from 1 to 3 cm. in diameter, to at once think of the appropriate surgical procedure. The cases naturally fall into two main groups.

1. Non-infected submucous myomata.
2. Infected and disintegrating submucous myomata.

Non-infected Submucous Myomata.—If the vagina is large and the myoma of moderate size, it is often possible to place a curved clamp on the pedicle, and at once cut the myoma off. The pedicle is then whipped over with two or more

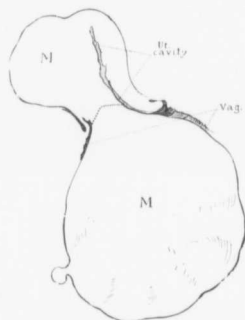


FIG. 334.—A LARGE SUBMUCOUS MYOMA.

Gyn. No. 2873. The patient had lost a great deal of blood, and for one week before admission a submucous myoma had protruded from the vulva. It measured 11 x 15 cm. The patient was very pale, cachectic, had a rapid and extremely weak pulse, and accelerated respiration, but an operation afforded the only hope. Vaginal myomectomy was done, the pedicle being severed at the point indicated by the dotted lines. The pulse soon rose to 172, and the temperature to 102.9° F. She died within twelve hours after the operation, apparently from shock.

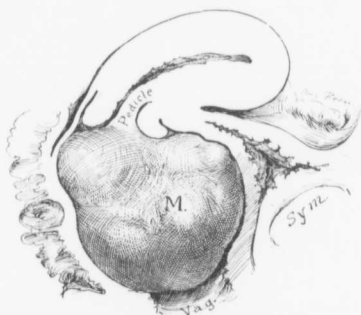


FIG. 335.—A SUBMUCOUS MYOMA GREATLY DISTENDING THE VAGINA.

Gyn. No. 2393. The uterus contained a single myoma. This had become submucous, and finally pedunculated. It had been forced out of the uterus, and markedly distended the vagina. The only way to remove such a tumor satisfactorily is to grasp it firmly with mesoforceps and remove successive wedges until the mass is so diminished in size that it can be delivered. The pedicle then can be easily clamped, and the tumor removed. The pedicle is then controlled with catgut sutures.

catgut sutures. When the myoma is still larger, it may be grasped with mesoforceps and delivered, a finger in the rectum materially assisting in its expulsion, or it may be possible to deliver the tumor with obstetric forceps as in Case 3066. In Case 2873 (Fig. 334) the large myoma already protruded from the vagina.

When the tumor is too large (Fig. 335) and the vagina relatively small, the tumor may be seized with two mesoforceps and bisected to the pedicle (Fig. 336). If half of the tumor is now cut off, the other half will still serve to steady the ped-

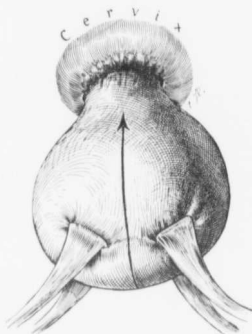


FIG. 336.—VAGINAL BISECTION OF A SUBMUCOUS MYOMA.

The myoma is firmly grasped with meso-forceps on either side, and cut in two, as indicated by the arrow. Half is then removed, and the corresponding half of the pedicle controlled with catgut. The other half is then removed, and its vessels are controlled, the sutures already introduced meanwhile serving as a tractor.

down to the rectum and the tumor delivered with obstetric forceps.

When the myoma has not been completely expelled into the vagina or lies partly in the cervical canal, it may be necessary to split the cervical lips both anteriorly and posteriorly or laterally until the pedicle is reached. The remainder of the operation is then relatively easy. This method was employed in Cases 5242 and 5296.

Sometimes, notwithstanding the care used, the pedicle is so friable that the stitches will not hold or it may slip through the artery forceps. It immediately retracts, and its subsequent control is impossible. In such cases, as a rule, it suffices to pack the uterine cavity tightly with iodoform gauze, which is removed after twenty-four or forty-eight hours.

Occasionally the pedicle of the myoma is attached to the cervical lips instead of projecting through the cervical canal. In such a case a wedge-shaped incision is made in the cervix, the myoma withdrawn and the resultant space closed as indicated in Figs. 339 and 340.

icle and prevent it from slipping. After half the pedicle has been sutured, the other half of the tumor is removed and the rest of the pedicle sutured.

When bisection is not feasible, a wedge of the myoma may be removed (Fig. 337). If the tumor is still not sufficiently reduced in size, successive wedges are taken out (Fig. 338) until it can be delivered and the pedicle controlled with catgut.

In a virgin the vagina is often so small that removal of the myoma by any of the methods suggested is not feasible. In such cases the perineum may be incised, as was done in Cases 1610 and 1716. After the necessary room has been obtained, the myoma is removed in the usual way.

In Case 3066 the patient was a widow, aged thirty-five and had never been pregnant. The vagina was filled with a submucous myoma, 6 x 11 x 11 cm. The perineum on the right side was incised

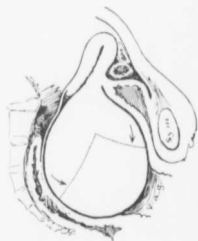


FIG. 337.—METHOD OF REMOVING A VERY LARGE SUBMUCOUS MYOMA

When the submucous myoma greatly distends the vagina, as in this case, a wedge may be removed, as indicated by the dotted lines. If the remaining portion is still too large, successive segments are cut away, as indicated in Fig. 338.

Years ago it was the custom to remove submucous myomata by means of an écraseur, and then it was very important for the operator to determine with absolute certainty whether partial inversion of the uterus was present. Several years ago I saw a surgeon remove a submucous myoma with the wire. To his great astonishment, after removal of the tumor, he found, where the pedicle should have been, a hole fully 2.5 cm. in diameter, communicating directly with the abdominal cavity. The weight of the submucous nodule, together with the usual expulsive movement, had occasioned partial inversion of the uterus. He had removed fully half of the fundus. Fortunately, no intestines had dropped into the cup-like depression, otherwise these also would have been severed by the écraseur.

With the abandonment of the wire and the employment of the simple method of operating under sight, such a complication could hardly be encountered.

In four of our cases (1610, 1716, 2873, and 7133) slight inversion of the uterus was noted at operation.

In some instances, as in Case 4967, in which a submucous myoma projected from a large multinodular uterus, it may be possible to do a vaginal myomectomy and then immediate removal of the uterus from above.

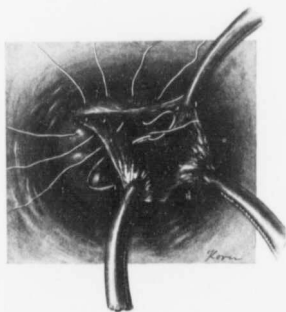

FIG. 339.—SUTURE OF THE CERVIX AFTER REMOVAL OF A SUBMUCOUS MYOMA.

The pedicle of a submucous myoma is usually attached high up in the cervical canal or in the uterine cavity, but occasionally springs from the cervix. In such cases it is removed as a wedge from the cervix, and the resultant space closed with formalin and plain catgut. If the incision has extended high up laterally, care must be exercised not to pierce the uterine artery with the needle.

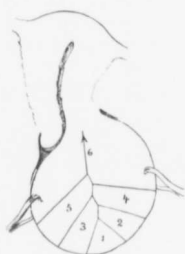

FIG. 338.—METHOD OF DELIVERING A VERY LARGE SUBMUCOUS MYOMA.

The tumor is altogether too large to be removed intact from the vagina. It is grasped with forceps, and successive wedges are removed in the order indicated. In this way the pedicle is finally clearly exposed and controlled with catgut.

Removal of Infected and Disintegrating Submucous Myomata.—A reference to p. 572 will show how foul a condition of the vagina may be caused by infected and disintegrating myomata, and it will be readily seen that no amount of preparatory cleansing will give the operator a clean field for operation. He must accordingly operate in such a way that the vagina or cervix is in no way injured, otherwise a serious general infection may result. When the myoma is firm, it may be bisected and removed, or its size may be materially reduced by first taking away one or more wedges of tissue. Under no circumstances, however, should the perineum be incised or the cervix split.

In many cases a degenerated myoma resembles a tough piece of beef that has lain in water for a long time. Such tissue is very soft and boggy. It cannot, however, be easily torn, but can be readily cut away with the scissors. When the tissue is very friable, it can be brought away piecemeal with placental forceps. Sometimes it is possible to control the stump with catgut, but when this will not hold and when bleeding occurs, the thermocautery may be employed. After removal of these myomata it is well to give a vaginal douche of bichlorid solution and to pack lightly with iodoform gauze.

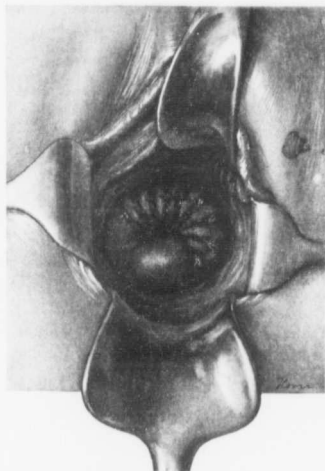


FIG. 340.—APPEARANCE OF THE CERVIX AFTER REMOVAL OF A SUBMUCOUS MYOMA THAT HAD BEEN ATTACHED TO THE VAGINAL PORTION OF THE CERVIX.

COMPLICATIONS OCCURRING DURING VAGINAL MYOMECTOMY.

1. Uncontrollable bleeding from the pedicle.
2. Rupture of the uterus.

Hemorrhage.—In Case 6604 the patient was thirty-four years of age and single. A wedge was removed from the submucous myoma which filled the vagina. Suddenly, the tumor tore away from its pedicle and was delivered. The pedicle was far up in the cervical canal. As there was steady bleeding from the uterus and as it was impossible to draw the cervix down so that the bleeding area could be exposed, the uterine cavity was tightly packed with gauze, but the bleeding still

continued. The abdomen was then opened, and both of the uterine arteries were tied. On the right side this procedure was difficult on account of dense adhesions, which bound the tube and ovary and the uterus to the pelvic floor. The patient eight years later wrote that she was in good health.

This case is another striking example of the necessity of always being prepared to do an abdominal operation whenever any important vaginal work is undertaken. We always make it a point to have the abdomen cleaned in such cases so that no delay will be necessary if its exploration should suddenly be found imperative.

Rupture of the Uterus.—In Case 9137 the woman was forty-eight years of age. The outlet was small, and a hard oval mass, 6 x 10 cm., filled the vagina. The cervical canal was fully 1 cm. in diameter, and the pedicle could be felt

extending up into the uterine cavity. The tumor was partially bisected and twisted off. A sound passed up into the cavity at the point of the pedicle went directly into the abdominal cavity. A small gauze drain was carried into the uterus, but nothing further was done. The patient, in writing five years later, stated that she was well.

In such a case it would, of course, be much wiser to clamp and cut the pedicle instead of twisting it off.

In this connection it may be interesting to mention Case 12323. The patient was thirty-two years of age and complained of amenorrhea. Although the utmost care was used in curettage, the instrument suddenly passed into the abdominal cavity. Anterior vaginal section was done, and a small perforation found just on the edge of the subperitoneal myoma, not over 3 mm. in diameter. The minute nodule was removed, and the rupture closed. The patient suffered no ill effects from the mishap.

Vaginal Myomectomy on a Patient Almost Moribund. Recovery.—The following case demonstrates that even when the patient has profound toxemia as a result of a sloughing gangrenous myoma, she may rally if the tumor is removed. Dr. Gerry R. Holden, of Jacksonville, Fla., who was resident gynecologist at the time, felt almost certain that the patient would succumb, but took the only chance. The speedy recovery was little short of marvelous, and the patient wrote, two years later, that her health was better than ever.

Gyn. No. 11889. Path. No. 8297.

L. V. G., colored, aged thirty-two, admitted February 13, 1905. She had had one child, and no miscarriages. During the last year she had experienced a great deal of pelvic pain at the menstrual period, and had had to remain in bed frequently during the flow, which had been excessive. For the last three weeks she had been in bed. Ten days before her physician packed the uterus with iodoform gauze, and gave ergot to control the hemorrhage. The patient became very weak and anemic from the repeated hemorrhages, and had a high fever and one severe chill.

On admission she seemed to be in an almost moribund condition. She was markedly delirious, suffered great pain, and had a rectal temperature of 104.2° F. The pulse was weak, irregular, 140 to the minute, and could not be felt in the right wrist. The respirations were 40, and a loud systolic murmur could be heard at the apex and was transmitted to the midaxillary line. Her hemoglobin was 14 per cent. She was stimulated at night, and in the morning the temperature was somewhat lower and the pulse better. On abdominal examination it was found that a rounded tumor filled the pelvis and extended as far as the umbilicus. The abdomen was very sensitive. On vaginal examination the cervix was found to be dilated, the external os being 4 cm. in diameter. Projecting from the cervix was a nasty, grayish-white, necrotic, submucous myoma. The

hand introduced within the cervix palpated a myoma which reached high into the abdomen.

Operation under nitrous oxid anesthesia. The cervix was well exposed. The tumor was seized with a heavy mesoforeeps and an effort made to take it out piecemeal. Over one-quarter of the tumor was gotten away in this manner. The tissue was foul-smelling and necrotic. An iodoform gauze pack was introduced into the uterus. The prognosis was exceedingly grave. Recovery was slow, owing to thrombosis of the right femoral vein and also to nephritis. On her discharge, one month and twenty-five days after operation, her hemoglobin was 60 per cent., her general condition good. She refused further operation.

Path. No. 8297. The largest piece of tissue was 2 x 6 x 9 cm. Even after the specimen had been in alcohol for a year and a half the odor was most disgusting, and sections showed that the tissue was necrotic. The surface was covered with polymorphonuclear leukocytes, and in the blood-vessels were what appeared to be myriads of micro-organisms.

January 9, 1907: We are just in receipt of a letter from the patient in which she says: "My health is better than ever. I am healthier than ever and stouter." Of course, in this case a large portion of the submucous myoma is still in the uterus.

Other Operations.—In the majority of our cases the vaginal myomectomy was the only operation performed. In Case 6855, however, after removal of a submucous myoma, 3.5 x 4 x 8 cm., a vaginal cyst, 2 x 3 cm., was excised from the left side and a tubo-ovarian abscess containing about 80 c.c. of non-fetid pus evacuated. The pus from the pelvic abscess might very readily have infected the wound from which the vaginal cyst had been removed.

In Case 10314 a submucous adenomyoma, approximately 7 x 7 x 11 cm., was removed from a patient having a double vagina and a double cervix. The vaginal septum was removed. This case is reported at length in "Adenomyoma of the Uterus," p. 161.

COMPLICATIONS FOLLOWING VAGINAL OPERATIONS FOR UTERINE MYOMATA.

1. Elevation of temperature and pulse.
2. Phlebitis.
3. Erysipelas.
4. Delirium.

Elevation of Temperature and Pulse.—In 57 of our successful vaginal myomectomies we have accurate data as to the postoperative temperature. From the accompanying table it will be seen that 21 of the patients had a temperature of 101° F. or over, after the operation. It will be further noted that in nearly all these cases the myoma removed was disintegrating and naturally, therefore, was infected.

The highest temperature (105.5°) was noted in Case 4382. The patient had suffered from fever and chills before the operation.

The maximum temperature was usually present on the second or third day. With the rise in temperature there was naturally a coincident rise in the pulse-rate.

CASES OF VAGINAL MYOMECTOMY WITH A POSTOPERATIVE TEMPERATURE OF OVER 101° F.

CASE NO.	HIGHEST TEMPERATURE.	DAY AFTER OPERATION.	CHARACTER OF MYOMA.
301	101.6°	Third.	Blackish red.
1317	104°	Third.	Strangulated.
1489	102.25°	Third.	
1551	102.25°	Third.	Sloughing.
	(Restless, delirious.)		
1610	102.6°	Second.	Smooth.
1716	102°	Second.	
4382	105.5°	First.	Sloughing.
	Chills and fever before operation; Temp. reached normal 29th day.		
4794	101.9°	First.	Sloughing.
5296	102.6°	First.	Sloughing.
5496	103.6°	Third.	Sloughing.
5622	101.4°	Sixteenth.	Smooth.
58714	105°	Fifth.	Smooth.
6441	101.2°	Second.	Nerotic.
6604	101.2°	Second.	
6833	102°	Fifth.	Sloughing.
7030	102°	First.	Sloughing.
10376	101.8°	Second.	Sloughing.
10618	105°	Second.	Sloughing.
10635	102°	Second.	Smooth.
12257	102.2°	Third.	Sloughing.
13014	101.4°	First.	Sloughing.

Phlebitis.—In Case 10314, after removal of a submucous adenomyoma, the patient developed a phlebitis in the left leg on the twenty-first day. Her highest temperature was 100° F. It is interesting to note that in none of the 21 cases in which the postoperative temperature exceeded 101° F., did phlebitis develop.

In Case 11889 the patient entered the hospital with a large sloughing submucous myoma. Her hemoglobin was only 14 per cent. Despite the fact that she was almost moribund, vaginal myomectomy was undertaken and she made a good recovery. The case is reported in detail on p. 577. During convalescence she had thrombosis of the right femoral vein, and also of the superficial veins of the neck.

Erysipelas.—In Case 12079 the patient, forty-six years of age, had a sloughing submucous myoma. Vaginal myomectomy was performed, and the uterus was dilated and everted. On the eighth day following the second anesthesia there was a sudden rise of temperature, and erysipelas developed at the point at which a subcutaneous infusion had been given.

The pathologic report (8655) showed that the surface of the myoma was composed of typical granulation tissue, and that many of the blood-vessels were

filled with organisms. It is possible that the infection came from the uterine tumor. The patient, however, had had an attack of erysipelas four years before her operation, at a time when no uterine tumor had been detected.

Delirium.—In Case 1551 the patient, aged forty-seven, white, gave a history of a vaginal myomectomy four years before admission. On examination a myomatous uterus was found filling the pelvis and extending almost to the umbilicus. A very offensive gangrenous mass filled the vagina. The patient was noisy, restless, and had a rapid pulse on admission. As much as possible of the sloughing myoma was removed, and an iodoform pack introduced. After operation the patient was still restless, delirious, and noisy at times. The maximum temperature was 102.2° F., on the third day. Twelve days later more of the submucous myoma had been forced into the vagina, and this was twisted off. With the removal of the submucous nodule the patient speedily recovered, although the uterus contained other myomata. The restlessness, delirium, and temperature were undoubtedly due to septic absorption from the sloughing submucous myoma.

IMMEDIATE DEATH FOLLOWING VAGINAL MYOMECTOMY.

In 84 cases submucous myomata were removed through the vagina; 79 patients recovered and 5 died.

On referring to the history of Case 1441 it will be seen that the operation was a simple one, and that, under ordinary circumstances, we should have expected recovery. The woman died in a state of profound asthenia on the thirteenth day. We are not clear as to the cause of death, but infection may possibly have been spread from a primary focus in the myoma.

In Case 2873 the woman was in a desperate condition on admission, not only on account of the great loss of blood, but also from septic absorption. Operative interference offered the only possible chance of relief. Although the operation itself was a simple one, she died in profound shock twelve hours later.

In Case 3426 the condition was a most complicated one. Not only was there infection in the vagina, but an ovarian abscess was also present. It is little wonder that the patient died of general peritonitis. With our present knowledge of these cases we never do an exploratory abdominal operation when a sloughing submucous myoma is present. The necrotic submucous growth is removed through the vagina. After several weeks, when the vaginal discharge has ceased and when the dangers of infection are greatly reduced, an abdominal hysterectomy is done if necessary. In the case under discussion any operative measure would have been accompanied by the greatest danger.

In Case 3508 death occurred six weeks after operation. The patient, on admission, was much run down, and recently had been vomiting. The operation was not responsible for her death, but failed to tide her over, her vitality having become too low.

The history of Case 6185 reveals the desperate condition of the patient on admission. She had a moderate fever, a rapid pulse, and a foul, sloughing, brownish-green, myomatous mass projecting down beneath the thighs. There is little wonder that she succumbed on the fourth day.

In this case it might have been wiser to leave the clamps attached to the pedicle instead of attempting to suture the stump.

Gyn. No. 1441.

Vaginal myomectomy. Death.

S. L., white, married thirty-two years. Admitted June 20; died July 3, 1892. Operation, June 21, 1892; removal of a submucous myoma by morcellation. The uterus was packed with gauze to control hemorrhage. After the operation the patient had a considerable quantity of seropurulent discharge, interspersed with a few hemorrhages of small amount. Toward the end there were vomiting and periods of extreme restlessness, usually followed by unconsciousness and feebleness of the pulse and respiration. The patient died in a state of profound asthenia on the thirteenth day. Her temperature reached 102.8° F. on the third day, but was below 99.5° F. after the ninth day.

Gyn. No. 2873.

Vaginal myomectomy. Death.

C. D., aged forty-nine, white, married. Admitted June 23; died June 23, 1894. The patient, on admission, gave a history of having had a submucous myoma removed a week before admission. She had lost a great deal of blood recently, and was very cachectic and weak. On admission she was found to be poorly nourished and very pale; she had a rapid and extremely weak pulse and a rapid respiration. A large myomatous tumor, 11 x 15 cm., projected from the vulva. It was attached by a pedicle 4 x 5 cm., and the uterus was partly inverted. Vaginal myomectomy was done, and a second nodule, 2 x 3 cm., was removed from within the cervix. Thirty catgut ligatures were required to control the oozing. The cavity of the uterus was packed with gauze. The patient's pulse rapidly rose to 172, her temperature to 102.9° F., and she died within twelve hours after operation in a condition of marked shock.

Gyn. No. 3426.

Vaginal myomectomy for a sloughing submucous myoma. Death from general peritonitis.

A. S., single, aged forty-five, colored. Admitted April 7; died April 17, 1895. For the past year the menses have been less regular and scant. Her last period commenced four weeks ago, and the flow since then has been continuous. Twelve years ago the patient noticed a small lump in the right side. This has grown gradually larger. Four weeks ago she began to have severe pain accompanying the copious discharge.

Operation, April 11, 1895, exploratory celiotomy; myomectomy through the vagina. When the abdomen was opened, a large myomatous uterus was found densely adherent to the pelvic floor. The abdomen was at once closed. The cervix was distended by a sloughing submucous myoma, which had been partly expelled through the vagina and was removed as far as possible with the écaraseur and curet; the uterus was then packed.

The patient developed signs of general peritonitis—constant abdominal pain, nausea, and vomiting. The temperature gradually rose to 103.7° F. on the sixth day, falling suddenly to normal just before her death on the seventh day.

Aut. No. 653. Anatomic diagnosis: Sloughing uterine myoma, infection of the vagina, cavity of the uterus and Fallopian tubes. The right ovary was the seat of an ovarian abscess, and there was wide-spread fibrinopurulent peritonitis. Both ureters were dilated. At autopsy cultures yielded *Streptococcus* from the peritoneal cavity and also from the vagina.

Gyn. No. 3508.

Vaginal myomectomy for a sloughing submucous myoma. Death six weeks later.

L. M., aged thirty-five, colored, married. Admitted May 13; died July 30, 1895. For three weeks prior to admission the patient has had an offensive bloody discharge containing shreds of broken-down tissue. Eighteen months ago she first noticed an abdominal tumor. It has been gradually getting larger, and for the two months there has been some abdominal pain. Recently the patient has been vomiting considerably.

Operation, May 15, 1895. A sloughing submucous myoma was removed, and the uterus dilated, curetted, and washed out. The patient's highest temperature was 103.2° F., on the third day. She gradually grew weaker and died six weeks after operation.

Gyn. No. 6185. Path. No. 2441.

Removal of a Gangrenous Submucous Myoma (Fig. 341). Death.

A. W., aged fifty-four, colored, married. Admitted June 21; died June 25, 1898. The patient was admitted as an emergency case. Between the thighs was a large ovoid tumor, dark brownish-green in color. This was covered with a bloody, foul-smelling discharge, and measured 8 x 15 cm. It projected from the cervix, the pedicle being 2.5 cm. in diameter.

Operation, June 22, 1898. It was impossible to clean the vagina thoroughly. The pedicle of the tumor was clamped, and the sloughing growth removed. Several sutures were passed through the cervix to stop the oozing, as it was impossible to satisfactorily control the pedicle. A smaller myoma was also grasped with mesoforeeps and twisted off. The uterine cavity was then tightly packed with iodoform gauze. The uterus itself after removal of the tumor

was about 11 cm. in diameter. The patient did not do well after operation. Her temperature on admission was 99° F.; after the operation it rose to 101.8° F.; on the second day it dropped to 99.5° F.; on the third day it rose to 103° F., and on the fourth day it reached 106.2° F. shortly before death. The pulse on her admission was 115; shortly before death it rose to 158.

Path. No. 2441. The specimen consists of a pear-shaped submucous nodule, approximately 7 x 12 cm. Its surface is slightly roughened, and on section it presents the typical myomatous appearance. Sections from the surface of the tumor show no trace of mucosa. The surface is covered with myriads of polymorphonuclear leukocytes and necrotic tissue. Beneath this is a very vascular zone, composed of large and small blood-vessels (Fig. 341). So abundant are the vessels that in places they occupy half the field. Some of these vessels contain organizing thrombi. The surrounding stroma shows a considerable amount of hemorrhage, or is infiltrated with many polymorphonuclear leukocytes. The tumor consists of non-striated muscle-fibers cut in various directions, and presenting the characteristic myomatous appearance. In some places there is hyaline degeneration, with a gradual melting away of the myoma, nothing but a delicate reticulum being left. We are dealing

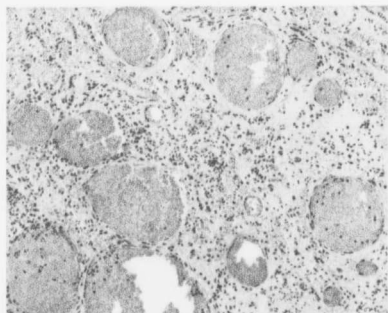


FIG. 341.—A VERY VASCULAR SLOUGHING SUBMUCOUS MYOMA. ($\times 100$ diam.)

Gyn. No. 6185. Path. No. 2441. The surface of the myoma consisted of necrotic tissue covered and infiltrated with polymorphonuclear leukocytes. Beneath this was an exceedingly vascular zone. As seen from the picture, nearly half the field is made up of large and small markedly dilated veins. The muscular elements have to a great extent disappeared, and the tissue is infiltrated with small round cells and fragmented nuclei. There has also been much hemorrhage into the tissue.

with an ordinary submucous myoma, the surface of which has become necrotic and disintegrated. It is exceptional to find so many blood-vessels in a myoma. They readily account for the free hemorrhage noted.

Aut. No. 1112. Anatomic diagnosis. Gangrenous submucous myoma; acute vegetative aortic and mitral endocarditis; septic infarction of the left lung; acute localized pleurisy; old pleuritic adhesions; chronic interstitial splenitis; subacute glomerular nephritis; miliary abscess in the left kidney. Chronic adhesive pelvic peritonitis.

In this case the weakened condition of the patient was certainly caused by

the profuse hemorrhages; the acute endocarditis and the miliary abscesses can likewise easily be accounted for by infection from the foul sloughing and infected myoma. The death can certainly be attributed to the submucous myoma in this case.

A FATAL CASE IN WHICH VAGINAL MYOMECTOMY WAS IMPOSSIBLE.

Gyn. No. 8804.

From the following history it is seen that the patient was suffering from a most profound anemia and from absorption from a large sloughing myoma. Vaginal myomectomy was impossible, and only a palliative operation was ventured upon.

M. P., aged forty-five, white. Operation, June 1, 1901; death on the same day. This patient had had frequent hemorrhages for three and one-half years before her admission. On May 8, 1901, her last period began, and continued until her admission to the hospital. She had grown very weak, and had been losing ground. For the previous two weeks she had had symptoms of fever. She was a very large, fleshy woman. Her lips and mucous membranes were markedly blanched; the respirations were shallow, and she looked very ill. There was a blowing systolic murmur at the apex. The hemoglobin was 20 per cent. On palpation a rounded tumor was found filling the entire abdomen. The circumference of the abdomen measured 115 cm. On vaginal examination the outlet was found greatly relaxed. There was a free bloody discharge. The cervix was in the normal position. The external os was greatly dilated. Palpation through the external os revealed a necrotic mass near the anterior surface. Under light anesthesia thorough curettage was done, and fully a liter of foul blood-clots removed from the uterine cavity. The cavity was then irrigated with salt solution and lightly packed. The patient was returned to the ward in fairly good condition. Toward evening the pulse became irregular, the respirations shallow, and she soon died.

FINAL RESULTS AFTER VAGINAL MYOMECTOMY.

Letters were sent out to all patients that recovered from the original operation, and in 48 of the 79 cases we have data as to the subsequent history:

Subsequent hysterectomy necessary.....	2 cases
Subsequent operation, nature not known.....	1 case
Development of carcinoma of the body five years later.....	1 "
Recurrent fibroids.....	1 "
Death from intercurrent affection fourteen and fifteen years later.....	2 cases
Patients not well.....	8 "
Patients well at periods varying from a few months to fifteen years.....	33 "
	<hr/>
	48 cases
Subsequent pregnancy.....	2 cases

Hysterectomy Subsequent to Vaginal Myomectomy.—In Case 1317 the patient was thirty-three years of age. On April 11, 1892, a blackish-red, strangulated myoma, about 11 cm. in diameter, was found filling the vagina. This mass was so friable that the greater portion was easily broken down with the finger. On the third day the temperature reached 104° F., but she left the hospital after a month, feeling well.

When the patient reentered the hospital eighteen months later (Gyn. No. 2183) the vagina was filled with a large, sloughing, offensive mass, which protruded from the cervix. This was removed, and twenty days later the large myomatous uterus, which extended as high as the umbilicus, was taken away through an abdominal incision. The patient left the hospital very much improved.

Fifteen years after the first operation she wrote: "My health is very bad." She was very weak and nervous, and often had attacks in which she fell. The nervous phenomena, however, had been prominent before her first admission to the hospital.

In Case 9196 the patient was forty-seven years of age and entered the hospital on November 5, 1900. Projecting from the cervical canal was a pedunculated, smooth, submucous myoma. This was readily removed, and with the curet a large amount of mucosa was brought away. Recovery was without incident. Several months later the patient entered a hospital in Staunton, Va., and was curetted on account of uterine hemorrhage. This gave relief for a few weeks. She then returned to Baltimore and had her uterus removed.

Path. No. 6319 demonstrates clearly the cause of the persistent bleeding. The uterus was the seat of a typical diffuse adenomyoma. The complete details of the gross and histologic examination of the uterus are found in "Adenomyoma of the Uterus," p. 99.

Other Operations Subsequent to Vaginal Myomectomy.—In Case 5133 the patient was forty-eight years of age. She entered the hospital on March 26, 1897. Projecting from the cervical canal, and attached by a pedicle 1 cm. in diameter, was a submucous myoma 3 x 5 cm. This was readily removed, and the patient made a good recovery. In a letter from her ten years later she said that she had since had two other operations, but further inquiry failed to elicit their nature. Her general health was fair.

Vaginal Myomectomy; Hysterectomy Five Years Later on Account of Adenocarcinoma of the Body of the Uterus.—Gyn. No. 3295. Aged forty-five. Entered the hospital on January 24, 1895. The vagina was filled with a smooth, hard conical mass. This was readily removed and the patient discharged on February 23d.

Gyn. No. 7699. On April 4, 1900, a complete abdominal hysterectomy was done for adenocarcinoma of the body, which apparently had originated just above the internal os. Situated near the right cornu was an interstitial myoma,

3 cm. in diameter. This case is reported in detail in the chapter on Adenocarcinoma of the Body of the Uterus, p. 280.

"Recurrent Fibroids." On p. 585 we mentioned Case 1317, in which, after the removal of a large submucous myoma, the patient reentered the hospital eighteen months later and had a second submucous myoma excised. A few weeks later hysterectomy was performed.

In Case 5496 the patient, aged forty, first entered the hospital on September 3, 1897. Filling the vagina was a large, cauliflower-shaped, sloughing and friable submucous myoma. The removal of this was complicated by excessive hemorrhage. The patient rapidly gained strength and left the hospital on September 30, 1897. On several subsequent occasions other submucous myomata were removed. The case is described in detail in the chapter on Sarcoma (p. 252).

The patient wrote on January 9, 1907, more than nine years later, that her general health was good, but that she had a constant uterine discharge.

Late Deaths Following Vaginal Myomectomy.—Two of the 48 patients concerning whom the subsequent history has been learned are dead. One (Case 909) died fifteen years after operation, of some unknown cause. The other (Case 1551) died fourteen years after operation, of cerebral hemorrhage. Neither of these deaths can be in any way attributed to the operation.

Patients Alive, but not well After Vaginal Myomectomy.—From the accompanying table it will be seen that 8 of the patients are not well, but in only 2 of these (No. 12079 and San. No. 1593) is there evidence of pelvic disease. In San. No. 1593 it looks very much as if the uterus contained other myomata.

No.	YEARS SINCE OPERATION.	PELVIC DISEASE.	CAUSE OF ILLNESS.
4663	Ten.	No.
5242	Ten.	No.	Pain in chest and knees.
8410	Six.	No.
10376	Four.	No.
10872	Three.	No.	Nervousness.
12079	One.	Yes.	Pain in left side of pelvis.
12591	One.	No.
San. 1593	Three.	Yes.	Still menstruating at fifty-four; is weak and dizzy.

Patients Remaining Well After Vaginal Myomectomy.—Of the 48 patients about whom we have been able to obtain the necessary data, 33 are well at periods varying from six months to fifteen years. This demonstrates conclusively that in many cases the uterus contains only one myoma, and that after its removal the patient may have no further uterine trouble.

TABLE OF VAGINAL MYOMECTOMIES—PATIENTS REMAINING WELL.

CASE No.	YEARS AFTER OPERATION.	CASE No.	YEARS AFTER OPERATION.
1150	Fifteen.	8600	Six.
1489	Fifteen.	8831 (Now a myoma 1 cm. at junction of cervix and body.)	Six.
1610	Fourteen.		
1716 (Weight at operation 70 pounds, now 160.)	Fourteen.	9137	Five.
2182	Thirteen.	9875	Three.
2593	Thirteen.	10618	Four.
2666	Thirteen.	Sad. 1497	Three.
4165	Eleven.	10635	Four.
5296	Ten.	11243	Three.
5687	Nine.	C.H.L.J.	Three.
6002	Nine.	C.H.I. 409	Two.
6143	Nine.	11889 (Almost moribund.)	Two.
6441	Eight.	12237	One.
6604	Eight.	13014	One-half.
6833	Eight.	C.H.I. 1201	One-half.
6855	Eight.		
7010	Seven.		
8159	Six.		
8517	Six.		

Pregnancy Following Removal of a Submucous Myoma.—In two of our 48 patients pregnancy has occurred. One (Case 1489), aged thirty-five, was admitted on July 23, 1892. Her menses had been irregular, occurring at intervals of from four to nine weeks. Six weeks previous to her admission she noticed a tumor in the left ovarian region. This was not tender, but apparently increased rapidly in size. On vaginal examination a small submucous myoma was found. The uterus was the seat of an early pregnancy. The myoma was readily removed. On the third day the temperature reached 102.2° F., but dropped to normal by the tenth day. The pregnancy was in no way interfered with.

The patient, writing fifteen years later, stated that her health was good, and that she had been delivered of the one child. The conception in this case, or course, antedated the operation.

In Gyn. No. 6002 the patient was thirty-four years of age. She entered the hospital on April 5, 1898, complaining of a more or less continuous bloody vaginal discharge, which she had had for three years. The vagina was filled with a large, hard, firm, rounded mass, about 11 cm. in diameter. The uterus, which was small, was perched on the top of the mass. The tumor was removed chiefly by morcellation and the pedicle controlled with catgut. Recovery was prompt, although the patient was anemic.

Nine years later the patient wrote that she had had perfect health ever since. She also said that since the operation she had had one child, and that the birth was an easy one.

CHAPTER XXXI.

ABDOMINAL HYSTEROMYOMECTOMY.

Local Applications as a Means of Checking Hemorrhage.—A few years ago it was customary to apply astringents to the uterine mucosa, with the idea of checking the bleeding. When the uterine cavity was small and readily accessible, this doubtless had some temporary value, but in the majority of the cases it is impossible to reach all portions of the uterine cavity with any instrument, and then there is always the danger of losing the cotton pledget of the applicator, as in Fig. 342, or of setting up a pelvic inflammation. With the splendid technic as now perfected, operation certainly gives the patient a much better prospect of recovery than does any method of local treatment. When the uterus is freely movable, the operative mortality is very low. Where pus-tubes are associated with myomata, local applications are contraindicated.

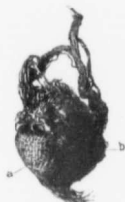

FIG. 342.—A GAUZE SWAB FOUND IN THE CAVITY OF A MYOMATOUS UTERUS. (Nat. size.)

S., C. H. I. December 15, 1906. At operation we found a foul, offensive uterine discharge and an irregular, greenish mass, about 1.5 cm. in diameter, lying free in the uterine cavity. The artist in sketching the hardened specimen chipped off the outer layer and detected the gauze network as seen at a. At b the coagulated blood is still present.

The consultant who had attempted to check the uterine hemorrhage had applied chromic acid to the uterine mucosa, and the pledget had evidently dropped off the probe. The foul discharge greatly increased the dangers of the operation.

Electrical Treatment for Myoma Cases.—Our experience in this field has been practically nil. It is supposed that electric applications check hemorrhage and in some instances diminish the size of the tumor. A glance at the various figures showing the sizes and shapes of the uterus and the distorted uterine canals that are thus so frequently found in myoma cases will convince the reader that, even if electricity has a beneficial effect, in many cases it would be impossible for the physician to reach any appreciable portion of the uterine cavity with his instrument.

The following case that was under Apostoli's care for a considerable period is of interest. Electricity certainly had a temporary effect, but it will be noted that after cessation of the treatment the bleeding recurred and he finally advised hysterectomy.

Our examination of this uterus after removal showed little or no alteration in the myomata, and the mucosa was practically normal.

J. Path. No. 3674

J. J., seen December 9, 1899. In 1885 the patient suffered from a severe degree of prostration and had fever for sixty days. She had constant

abdominal pain and profuse menstruation. The bleeding shortly after this became excessive, and she had almost total loss of memory. Dr. Apostoli gave her electric treatment, and she returned much improved. In 1887 she went back to Paris for more electric treatment, and again experienced relief, but later, at Carlsbad, she had profuse menstruation. This was again checked by electric treatment.

In 1891 Dr. Apostoli found her very ill, and did not expect her to recover. In 1897 electric treatment was again started and the bleeding ceased during the treatment, but recommenced and continued when the electricity was stopped. Apostoli advised operation, but the patient refused. When she came under our care the patient had constant headache and profuse hemorrhages, and had been in bed one week of each month. The uterus was removed by one of us (Kelly) December 9, 1899, and the patient recovered.

Path. No. 3674. The specimen consists of a myomatous uterus, slightly irregular in shape, measuring 10 x 10 x 13 cm. (Fig. 343). The outer surface is smooth and glistening, and somewhat roughened. Scattered throughout the uterine wall are numerous myomata, the largest 7 cm. in diameter.

The uterine cavity is approximately 10 cm. in length, and in places, especially in the neighborhood of the cervix, is almost obliterated, as well as much distorted by the submucous nodules. To introduce a stiff catheter or an instrument far up into such a uterine cavity would be almost an impossibility. The uterine mucosa is smooth. Over the submucous nodules it is as thin as parchment, but where not subjected to pressure, reaches 2 or 3 mm. in thickness. None of the myomata gives any macroscopic evidence of disintegration.

Histologic Examination.—The uterine mucosa presents a wavy and undulating appearance, and has an intact surface epithelium. Over the prominent portion of the submucous myomata the mucosa is thinned out and consists merely of a narrow layer of stroma covered with epithelium, but devoid of glands. In the protected areas between nodules the mucosa is slightly thickened; the glands

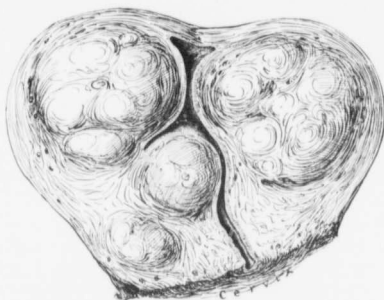


FIG. 343.—A MYOMATOUS UTERUS AFTER YEARS OF ELECTRIC TREATMENT.

Path. No. 3674. This patient was given intra-uterine electric treatment by Apostoli in 1885 with relief, and again in 1887, 1891, and 1897 respectively. Hysterectomy was performed (by Kelly) in 1899.

As seen from the history, the electric treatment temporarily checked the bleedings, but they recurred. The uterus, on removal, was 10 x 10 x 13 cm. From the contour of the uterine cavity it is evident that no local applications could possibly have reached all portions of the interior of the uterus. It must be admitted that the growth was a slow one, as it had been under observation for fourteen years.

are numerous, convoluted, and in places moderately increased in caliber. The gland epithelium is intact, slightly swollen, but somewhat flattened. These enlarged glands have little tufts of stroma projecting into their cavities, and these tufts are also covered with epithelium. The picture is one of gland hypertrophy. The stroma of the mucosa is sparsely sprinkled with small round cells, and in the superficial portions there is some hemorrhage. The mucosa, taken as a whole, is normal. The myomata show a few areas of hyaline degeneration, but are otherwise unaltered.

It will be seen from the foregoing that the electric treatment had caused no permanent alteration in either the mucosa or the myomata. Gland hypertrophy is a common accompaniment of uterine myomata, and hyaline degeneration of the tumor is invariably found.

Indications for Operative Interference.—Long experience has taught that myomata, if let alone, may reach large proportions and give rise to pressure symptoms, and that if they become submucous, alarming and occasionally fatal hemorrhage may ensue. In some of our cases the subperitoneal or intraligamentary myomata had suppurated and opened into the intestines or caused a peritonitis. Submucous tumors occasionally undergo disintegration that in some instances leads to a fatal issue; hyaline and cystic changes have been frequently noted. In over 1 per cent. of the cases sarcoma had either developed in or been associated with the myomatous growth, and in nearly 2 per cent. of our cases, carcinoma of the body of the uterus in addition to the myomata was found.

Judging from these findings, the surgeon would naturally infer that all myomata should be removed. It must be remembered, however, that many patients have small myomata that occasion no discomfort whatsoever, and are detected only during the routine examination made when the woman is being treated for some intercurrent affection.

If a patient has a small myomatous uterus that is apparently quiescent and occasioning no discomfort, it is wise to let well enough alone; but should the periods be increasing in duration and be very free, submucous myomata are probably present, and the advisability of a myomectomy or hysterectomy should be carefully considered while the patient is still in good condition. Again, whenever the tumor appears to be growing rapidly, it should be removed. The presence of a myomatous uterus two or three times its natural size, when unaccompanied by any discomfort, is no indication for operation. The patient should, however, be kept under observation, reporting to the physician at least four times a year.

The Anesthetic.—In nearly all our cases at the present time ether, preceded by gas or ethyl chloride, is the anesthetic used, the ether being administered by the drop method. Since doing away with the cone we have been surprised at the marked diminution in the amount of postoperative vomiting.

Occasionally when the patient has bronchitis or an old pleurisy chloroform is used.

In Case 11944 the abdomen was opened with the patient under the influence of Schleich's solution, the incision extending from the ensiform to the pubes.

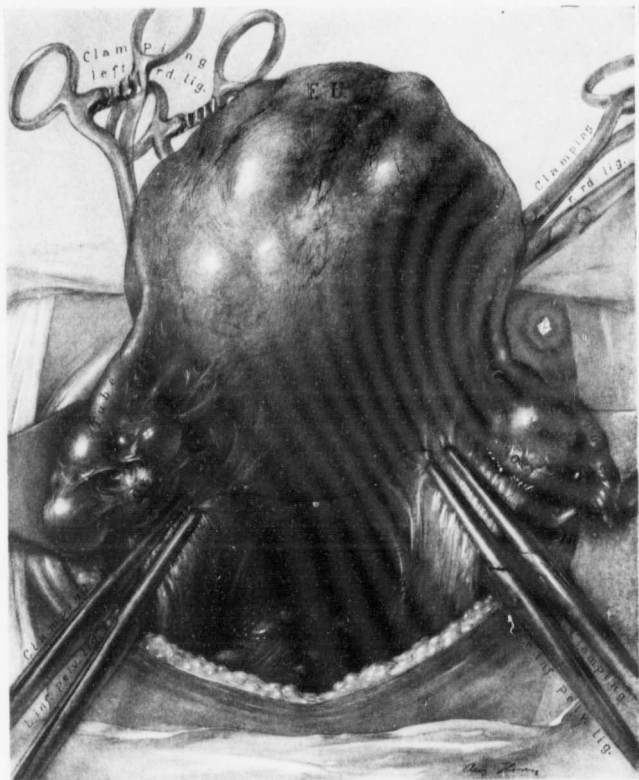

FIG. 344.—THE MYOMATOUS UTERUS PRIOR TO REMOVAL.

A liberal incision gives good exposure, facilitates the operation, and prevents the bruising of tissues that may occur where very strong traction is necessary. Where it is advisable to remove the appendages with the tumor, the round ligaments are first clamped and cut, and then the ovarian vessels are doubly clamped, as indicated, and cut between the clamps. The uterus can then be lifted farther upward, and the uterine vessels located after the bladder has been pushed down.

After the tumor was delivered, the patient complained bitterly of an indescribable feeling of unrest and annoyance, although there was no pain. The operation was completed under general anesthesia.

In San. No. 2142 the patient had a mitral insufficiency. The entire operation,

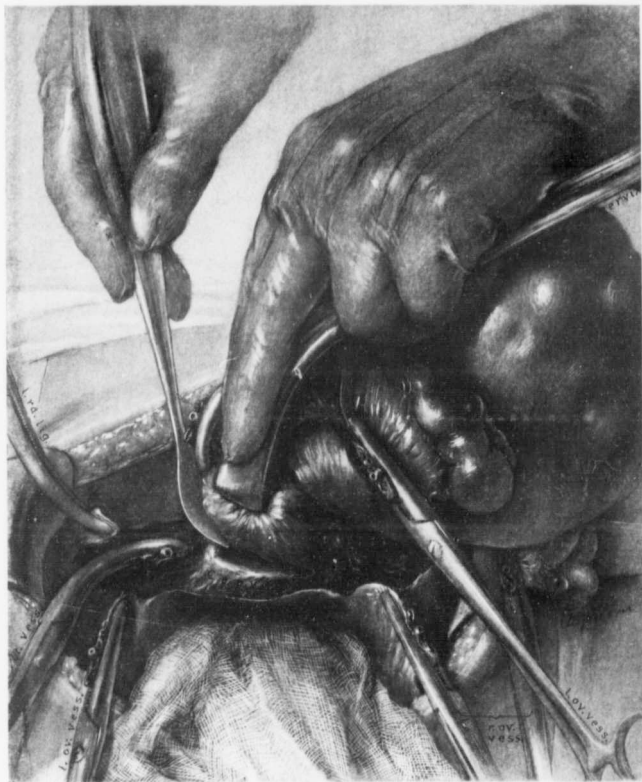


FIG. 345.—AMPUTATION THROUGH THE CERVIX.

The left round ligament, the left ovarian vessels, and the left uterine vessels have been cut between clamps. The right round ligament and the ovarian vessels have likewise been controlled. The cervix is being drawn strongly upward and to the right with mesoforceps, and is being severed. When the amputation is completed, it will only be necessary to clamp the right uterine vessels and the tumor can be removed.

which lasted an hour, was performed with nitrous oxide gas as the anesthetic, with thorough satisfaction.

Taking all in all, we have found ether the safest and most satisfactory anesthetic.

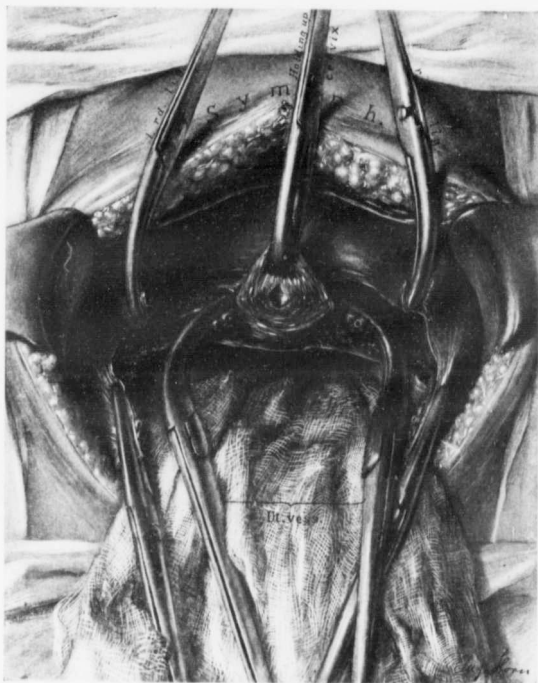


FIG. 346.—THE APPEARANCE OF THE PELVIS WHEN ALL THE CARDINAL VESSELS HAVE BEEN CLAMPED AND THE TUMOR REMOVED.

The anterior lip of the cervix is grasped with Jacob's forceps, and the uterine vessels with Wertheim's clamps, the ovarian vessels with Kocher-Ochsner clamps, and the round ligaments with curved artery forceps. For the appearance of the tumor with its attached clamps see Fig. 347.

Supravaginal Hysterectomy and Panhysterectomy in Myoma Cases.—Considerable difference of opinion exists as to whether supravaginal hysterectomy or total removal of the uterus should be carried out when myomata exist. After

carefully weighing the advantages and the disadvantages of each operation, we have adopted supravaginal hysterectomy as the usual procedure.

Supravaginal amputation is the easier operation, especially in difficult cases, where it is almost impossible to expose the cervix and the uterine vessels. In this operation there is much less danger of injuring the ureters, and less tendency to the production of cystitis. When a portion of the cervix is saved, the ends of the round ligaments may be inserted into it, and a good buttress for the pelvic contents is thus formed, which diminishes the tendency to prolapse of the pelvic contents. Panhysterectomy is much safer whenever sarcomatous degeneration of the uterus is suspected (p. 195) or when carcinoma of the body of the uterus complicates uterine myomata (p. 276).*

When, as in Case 8114, the cervix is so small that no stump can be left, complete hysterectomy is not only a wise procedure, but the only possible one. In other cases the cervix may be unfolded by a large submucous cervical myoma, as in Case 9798 (Fig. 40, p. 57). Here it was necessary to completely remove the uterus.

In some cases large submucous myomata filling the vagina distend it and lift the uterus up. In such cases the vagina is easily opened up, and it is manifestly simpler to do a complete hysterectomy. Cases 10995 and C. H. I., R. are good examples of such a condition.

Taking all in all, and making due allowance for the possibility of occasionally encountering sarcoma or carcinoma, we feel that supravaginal hysterectomy is the better operation to adopt in the majority of the cases.†

SIMPLE ABDOMINAL HYSTEROMYOMECTOMY WITH PRESERVATION OF THE TUBES AND OVARIES.

Where abdominal hysterectomy is deemed advisable in patients before the menopause, and where the appendages are normal, it is our duty to save the ovaries on both sides if possible. If the uterus is relatively movable, it may be removed in one of two ways:

1. By first tying the cardinal vessels as they are encountered and then removing the uterus.

* *Inspection of the Uterine Cavity for Carcinoma and the Myomata for Sarcoma before Suture of the Cervix.*—We have elsewhere strongly emphasized the necessity for opening up the uterine cavity just as soon as the tumor is removed, to exclude the presence of carcinoma of the body, as it has been associated with myomata in 25 of our cases (see p. 277).

On p. 190 is described in detail a case in which we had amputated through the cervix and a typical sarcoma was present in the myoma. Section of this myoma would have instantly demonstrated the malignant growth. It was overlooked, and the patient, two years later, had an inoperable growth in the cervix. Whenever a malignant growth is found, the cervix should be excised at once.

† *Group Operations.*—On p. 526 we have considered the various other operations that were performed in addition to a myomectomy. In quite a number of our hysterectomy cases other disorders required surgical interference. The necessary procedures were undertaken at the same time, or, when the patient was too weak, after an interval of several weeks.

2. By clamping the cardinal vessels as they are encountered, removing the uterus, and then applying the ligatures.



FIG. 347.—THE UTERUS AS IT APPEARS ON REMOVAL WHEN ALL THE VESSELS HAVE BEEN CONTROLLED WITH CLAMPS AND CUT.

The cervix is grasped with mesofoceps, the uterine vessels with Wertheim clamps, the round ligaments with curved artery forceps, and the ovarian vessels with Kocher-Ochsner forceps.

Tying the Cardinal Vessels as They are Encountered and Then Removing the Uterus.—The usual steps are:

1. Tying the left round ligament on the distal and clamping on the proximal side and severing.

2. Ligating the left ovarian and tubal vessels on the pelvic side near the uterus, clamping on the uterine side, and cutting between the clamps.
3. Separating the vesical peritoneal fold from the anterior surface of the uterus, from the round ligament on the left to the round ligament on the right.
4. Separating the folds of the left broad ligament until the left uterine vessels are seen or felt. Ligating the uterine vessels on the pelvic side, clamping on the uterine side. Severing the uterine vessels between the clamps and ligating.
5. Ligating and suturing the right round ligament.
6. Ligating the right ovarian and tubal vessels near the uterine horn and cutting the tube and ovary from the uterine cornu.

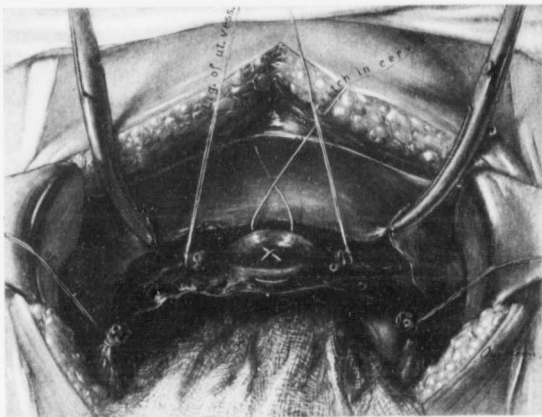


FIG. 348.—APPEARANCE OF THE PELVIS AFTER ALL THE CARDINAL VESSELS HAVE BEEN CONTROLLED.

The ovarian and uterine vessels on both sides have been tied, and the anterior and posterior lips of the cervix are being approximated by a figure-8 suture of catgut, which has not yet been tied. The round ligaments are temporarily clamped prior to their insertion into the cervical stump.

7. Separating the right broad ligament and exposing the uterine vessels, ligating and then cutting these vessels.
8. Amputating through the cervix.
9. Closing the cervical flaps.*
10. The final toilet of the pelvis includes bringing the ends of the round ligaments to the cervical stump and covering in the cervical stump with the redundant vesical peritoneum, thus leaving a perfectly smooth pelvic cavity.

* The cervical flaps are nearly always brought together with catgut. In a few of the early cases silver wire or silk was used. As a rule, the cervical stump is not over 3 or 4 cm. in diameter, but in a small number of cases the raw area to be approximated may be very large.

By tying and severing the left round ligament the broad ligament is at once opened up, and the uterus can be lifted still further out of the abdomen. The "clear space" beneath the tubal vessels is well exposed, and a ligature is at once carried through it, the ovarian and tubal vessels being controlled a short distance from the uterine horn. In this ligature are included the inner end of the tube and the utero-ovarian ligament, in addition to the vessels. The combined mass is, however, relatively small. Some employ only catgut for this ligature, but it is safer to use, for all cardinal vessels, a fine Pagenstecher reinforced by a second consisting of catgut. Clamps are now applied to the uterine horn, and the tube and ovary severed from their uterine attachment. It is necessary to have forceps that, when once applied, will remain *in situ* and not spring off or

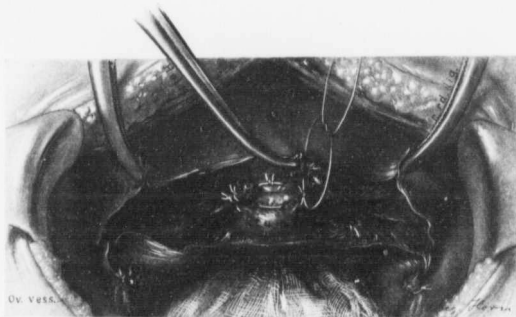


FIG. 349.—DRAWING THE UTERINE VESSELS INTO THE CERVICAL STUMP.

The uterine and ovarian vessels on both sides have been ligated, and the round ligaments are controlled with forceps. The left uterine vessels have been drawn over and included in the last cervical ligature on that side. The right uterine vessels are being drawn over preparatory to including them in the last suture on the right side. This method is frequently adopted, and offers additional security against hemorrhage from the uterine vessels.

slip. Ochsner's modification of Kocher's forceps answers this requirement perfectly.

In opening up the left broad ligament only a scant amount of connective tissue is encountered. This is rapidly snipped with the scissors, or can be readily dissipated by gently separating with the two index-fingers drawn away from each other. If the posterior peritoneal layer of the broad ligament is cut downward toward the cervix for about half an inch, the uterus can be brought still further upward, and the uterine vessels are better exposed. During this dissection it is advantageous that a light be placed on the opposite side of the broad ligament, so that, if any important structures are in danger, they can be seen by the transmitted light. When cutting the posterior peritoneal flap, it is well to keep

close to the uterus and not to cut too far down, as the ureter might be severed. The left uterine artery with its accompanying veins is now exposed and can be readily tied. A round curved needle is used. It is inserted close to the cervix, so that the vessels are not punctured; in fact, it may pass through the outer margin of the cervix. After both ligatures have been tied, a clamp is applied about an inch above, and the vessels severed between the clamp and the ligatures.

The steps on the opposite side are similar to these already described.

Prior to cutting across the cervix, the abdominal incision and the surrounding pelvic contents are carefully walled off with gauze. The operator makes strong traction on the uterus and cuts across the cervix with a knife, or preferably with a Kelly spud (Fig. 345). As he does this, he cups out the cervix slightly or leaves

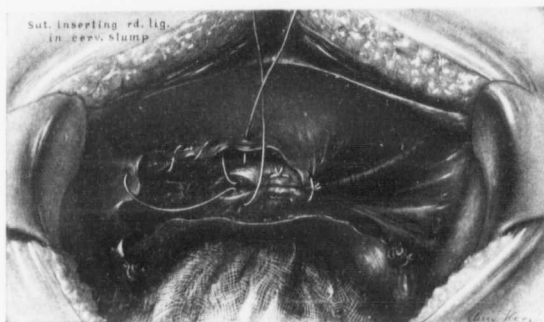


FIG. 350.—INSERTION OF THE END OF THE ROUND LIGAMENT INTO THE CERVICAL STUMP.

The central part of the cervical stump has been approximated. On the right the round ligament has been brought into the angle of the cervix. On the left, the suture which accomplishes this has been introduced, but not drawn taut and tied. The remaining raw areas are then approximated, as shown in Fig. 352. The stumps of the ovarian vessels are seen.

a concave surface, so that it really forms the anterior and posterior flaps, which can be approximated. There should be very little bleeding, as all the main vessels have already been controlled. The cervical stump is grasped with a Jacob's forceps and drawn upward. If the remaining cervical mucosa shows any signs of inflammation, it is advisable to dilate the cervical canal well, so that there may be good drainage, or, still better, remove most of the cervical mucosa with the uterus, as advocated by one of us (Kelly), and as shown in Figs. 353, 354.

The anterior and posterior surfaces of the cervical stump are now approximated with catgut. The last suture on the right and that on the left includes

the stump of the corresponding uterine artery (Fig. 349), thus doubly minimizing the chance of secondary hemorrhage from these vessels.

The round ligaments are now, if of sufficient length, brought down and fastened to each other and to the cervical stump (Figs. 350, 351, 352). The stumps comprising the inner ends of the tubes and the utero-ovarian ligaments with the vessels are covered over with broad ligament peritoneum, and the cervix is

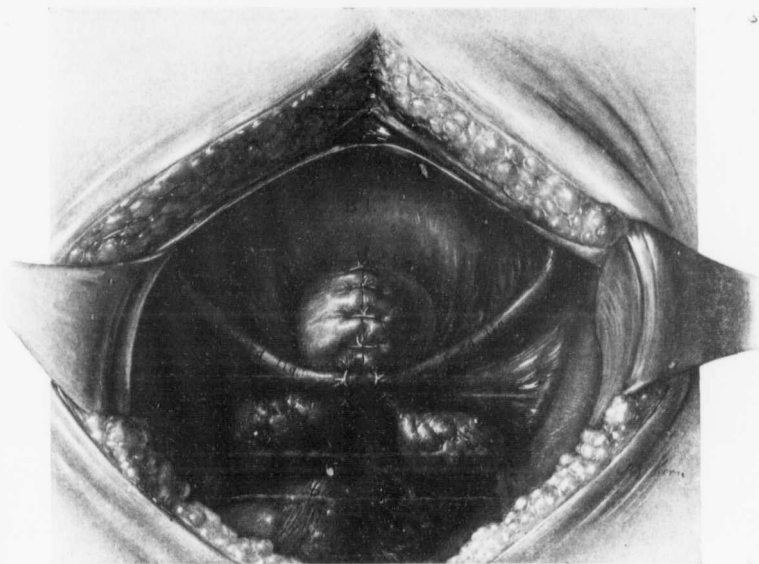


FIG. 351.—APPEARANCE OF THE PELVIS AFTER SUPRAVAGINAL HYSTERECTOMY.

The cervical suture line is usually from left to right, but here it has been in the anteroposterior direction. The ends of the round ligaments are brought together behind the cervix, to minimize the danger of prolapsus, and the inner ends of the ovaries have been approximated. All raw areas have been controlled, so that there is little danger of postoperative intestinal adhesions. (For the usual method of closure see Fig. 352.)

covered over with vesical peritoneum. In this final covering over of the areas with peritoneum fine needles and fine catgut are necessary, on account of the delicate character of the peritoneum, and care must be exercised not to pierce any artery with the needle-point or to prick the ureter or include it in one of the peritoneal flaps.

Prior to closing the cervix, the operator has, of course, requested an assistant to open the uterine cavity to exclude the possibility of cancer of the body. The

uterine myomata have also been examined to see if, perchance, a sarcomatous degeneration can be found. If either early process should happen to be present, the cervix should be removed at once. For a full discussion of this point see p. 179.

The appendix is now examined and the abdomen closed.

Clamping of the Cardinal Vessels, Removal of the Uterus, and the Application of the Ligatures.—If the surgeon has had little experience in abdominal hysterectomies, it is advisable to tie the vessels as he encounters them, but one who is

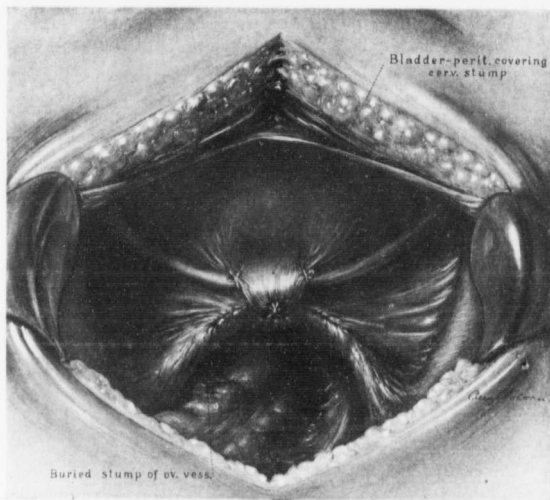


FIG. 352.—APPEARANCE OF THE PELVIS AFTER INSERTION OF THE ROUND LIGAMENT INTO THE CERVICAL STUMP.

The round ligaments have been brought into the angles of the cervix, as indicated in Fig. 350. The bladder peritoneum is then drawn over the cervix and snugly sutured to its posterior surface. The stump of the ovarian vessels and the remaining raw areas are covered in with peritoneum by means of continuous sutures.

doing hysterectomies frequently can save much time by temporarily clamping the vessels and tying them after the uterus has been removed.

Where clamps alone are used, it is absolutely necessary to employ those that will not slip, otherwise alarming hemorrhage may result. Figs. 344, 345, 346 show the most satisfactory kinds of artery forceps. The various steps in the operation are:

1. Clamping the left round ligament on the outer side and clamping on the inner side, severing the round ligament and then opening up the left broad ligament.

2. Clamping the left ovarian and tubal vessels near the uterus, separating the tube and ovary from the uterus.
3. Opening up the left broad ligament and freeing the bladder from the uterus.
4. Doubly clamping and cutting the left uterine vessels.
5. Clamping and severing the right round ligament.



FIG. 353.—EXTENSIVE REMOVAL OF THE CERVICAL MUCOSA WHERE SUPRAVAGINAL HYSTERECTOMY IS PERFORMED.

When the clinical findings strongly suggest an infection of the cervical mucosa, it is advisable to remove as much of this as is feasible. The uterus is freed on all sides, and the cervix severed circularly almost to the mucosa. The dissection is continued downward until most of the mucosa lining the canal has been freed, as indicated. Two provisional sutures held in the directions of the arrows prevent retraction of the cervix. A clamp across the cervix prevents any escape of the uterine contents. The uterus, which is held merely by the cervical mucosa, is liberated by means of the thermocautery. The operation is finished in the usual manner. One of us (Kelly) has been using this method with much satisfaction for several years.

6. Clamping and severing the right tube and ovary from the uterus at the cornu.
7. Spreading the right broad ligament and clamping the uterine vessels.
8. Amputating the uterus at the cervix.
9. Ligating the left ovarian, left uterine, right uterine, and right ovarian vessels in the order mentioned.
10. Closing the cervical stump, bringing the ends of the round ligament into the suture line if possible.

11. Covering over all raw areas with peritoneum.

It is always well to clamp and cut the round ligaments at once, as cutting them permits the operator to lift the uterus still further out of the abdomen and, furthermore, the clear space in the broad ligament is at once seen. One blade of the artery forceps may be at once pushed through this, and the ovarian and tubal vessels controlled. A clamp is now applied to the uterine cornu, and the uterus is severed from its tubal and ovarian attachments. The bladder reflection is now picked up and easily separated by slipping the scissor blade beneath the bladder peritoneum, and severing it from left to right or the reverse. The peri-

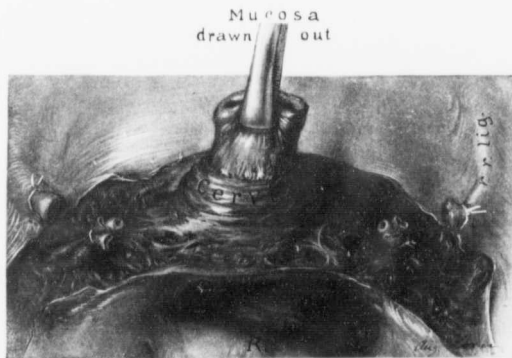


FIG. 354.—EXTENSIVE REMOVAL OF CERVICAL MUCOSA.

Where there seems to be danger of infection from the cervical mucosa, the mucous membrane is sometimes dissected out, in the manner indicated, and removed prior to closure of the cervical lips.

toneum is very thin and translucent, and if it carries blood-vessels of any appreciable size, these are seen at once.

The left broad ligament is now widely opened, and the uterine vessels, after a little blunt dissection, are readily seen or felt. They are now doubly clamped with Wertheim parametrial forceps, and the vessels cut between the clamps (Fig. 345). The structures on the right side are handled in the same order, and the cervix can then be cut across with little or no hemorrhage.

The clamps controlling the vessels are now replaced by ligatures. For each group of vessels we usually employ one Pagenstecher reinforced by one catgut ligature.

Wherever there is the slightest danger of infection from the cervical canal, the abdominal incision and the pelvic contents should be most carefully walled off before the cervix is severed. The cervical flaps are now brought together, and, where possible, the ends of the round ligaments sutured into the cervical

stump. All raw areas are now covered over with peritoneum, and after careful sponging of the pelvis the abdomen is closed.

The Employment of the Round Ligaments in the Suspension of the Cervical Stump.—In those cases in which the cervix tended to sag down into the vagina, after bringing the cervical flaps together we have drawn the ends of the round ligaments down to the cervix and sutured them there, as indicated in Figs. 350, 351, 352. The peritoneum has then been sutured over the cervix. By this means the cervix has been held well up in the vaginal vault. This method is similar to that advocated by other surgeons.

The Preservation of One or Both Ovaries in Cases of Hysteromyectomy.—In at least 125 of our cases one or both ovaries were saved. That we might ascertain the effect of such preservation upon the general health, letters were sent out to these patients. Fifty-six (37 white and 19 colored) replied, giving fairly complete answers. The chief object was to ascertain in what percentage of the cases an artificial menopause had been avoided, special attention being paid to the presence or absence of hot flashes. In order to absolutely exclude any abnormally early appearance of the menopause we have included only those cases in which the patients were not over forty-one years of age. A study of the accompanying table will show the essential data obtained.

CASE NO.	AGE AT OPERATION.	PRESENT AGE.	HOT FLASHES.			PRESENT HEALTH.
			Present or Absent.	Earliest Appearance After Operation.	Duration.	
3340	36	48	Present.	Fourteen months.	Four years.	Good.
4635	37	48	"	Not mentioned.	Still persist.	Very good.
4832	28	39	"	Several years.	Still persist (every two weeks).	Variable.
5239	39	49	"	A few months.	Still occasionally present.	Excellent.
5277	31	41	"	"	"	Good.
5325	35	45	"	Several months.	Several months.	Poor.
6372	40	49	"	Eight years.	Occasionally present.	Good.
6972	38	46	"	Five years.	One year.	Poor.
7096	30	37	Absent.	"	"	Very good.
7703	29	36	Present.	Two years.	Still occasionally present.	Very good.
8306	36	42	Absent.	"	"	Fair.
8705	39	45	"	"	"	Very good.
9029	38	41	Present.	Soon after.	Still persist.	Good.
9078	36	42	Absent.	"	"	Good except for ovarian pain at period.
9286	37	43	"	"	"	Perfect.
9527	36	41	"	"	"	Fairly good.
9788	32	37	Present.	Immediately after operation.	Six months.	Poor.
9818	40	45	Absent.	"	"	Good.
9843	29	34	"	"	"	Good.
9928	40	45	Present.	Six months.	Three to four days.	Good.

CASE NO.	AGE AT OPERATION.	PRESENT AGE.	HOT FLUSHES.			PRESENT HEALTH.
			Present or Absent.	Earliest Appearance After Operation.	Duration.	
10357	38	42	Present.	Four years.	Still persist.	Good.
10453	36	40	Absent.			Good.
10558	38	42	Present.	A few weeks.	Still persist.	Fair.
10580	27	31	Absent.			Good.
10667	38	42	"			Poor.
11216	27	30	Present.	Two months.	Still persist.	Poor.
11217	41	44	Absent.			Very good.
11392	34	37	Present.	Three weeks.	Still persist.	Poor.
11472	38	41	"	One year.	Still occasionally present.	Good.
11681	33	36	Absent.			Fairly good.
11688	39	42	Present.	Two months.	Still occasionally present.	Good.
11722	33	36	Absent.			Fairly good.
11984	41	43	"			Very good.
12086	37	38	"			Good.
12185	38	40	"			Good.
12401	24	26	Present.	Not mentioned.	Not mentioned.	Fair.
12569	27	29	Absent.			Good.
12488	41	43	Present.	One month.	Four months.	Perfect.
12522	34	36	"	Sixteen months.	Still occasionally present.	Fair.
12525	28	30	"	One month.	Still persist.	Good.
12696	28	30	Absent.			Good.
12764	24	25	"			Good.
12967	41	42	"			Good.
12944	43	44	Present.	A few weeks.	Still persist.	Good.
13039	27	28	"	Six months.	Still persist.	Fair.
C. H. L., 382	37	40	"	Three months.	Four months.	Good.
C. H. L., 392	32	35	Absent.			Good.
C. H. L., 620	35	37	"			Perfect.
C. H. L., 673	36	38	Present.	One month.	Still persist.	Fair.
C. H. L., 949	39	41	Absent.			Fair.
C. H. L., 1095	29	30	Present.	One month.	Still persist.	Good.
San., 1691	40	43	Absent.			Good.
San., 1702	40	43	"			Good.
San., 1773	37	40	Present.	After operation.	Six months.	Very good.
San., 2144	39	40	"	Several months.	Still persist.	Good.
San., 2164	38	39	Absent.			Fair.

HOT FLUSHES.—Twenty-nine, or 51.8 per cent., of the patients suffered from hot flushes of varying severity and duration. These in most instances appeared at the time the menstrual flow would normally have been present. In 4 of the 29 cases (4832, 6372, 6972, and 10357) the hot flushes did not appear for several years after operation. Of these patients, 2 were forty-nine and forty-seven years old respectively when the hot flushes occurred. This was undoubtedly the period when, under normal conditions, their menopause would

have been reached. In Cases 6972 and 10357 the women were forty-three and forty-two years old respectively when the hot flushes appeared, and although they were still under forty-five years of age, the phenomena strongly suggested the onset of the normal menopause. By excluding these 4 cases from our tabulation we find that in only 25, or 44.6 per cent., of the 56 were hot flushes or indications of the menopause present.

In Case 9928 the patient was forty years old. Hot flushes appeared six months after operation and lasted only a few days. She is now forty-five years old, and has had no reappearance of symptoms suggestive of the menopause.

In 3 cases hot flushes appeared only occasionally. In 6 cases hot flushes occurred after operation, but continued only for a few months.

In several cases, however, the hot flushes occurred more frequently and were of much longer duration. In Case 3340 the woman was thirty-six years old. Hot flushes appeared fourteen months after operation, and were present each month for four years. In Cases 9029 and 10558 hot flushes appeared soon after operation and still persisted six and four years later respectively. In 12 cases hot flushes appeared during periods of from one to three years after operation, and still persisted. Thus in only 15 of the 56 cases were there hot flushes of moderate severity which persisted for a long period.

Even if we exclude the 4 cases in which no hot flushes were present for several years and were not noted before what appeared to be the normal menopause, we still have 27 cases, or 48.1 per cent., in which no hot flushes have ever been noted. This, to our mind, demonstrates conclusively that the surgeon should, wherever possible, save every normal ovary. In some instances, of course, when the ovaries are lying high in the abdomen, although it might be surgically feasible to spare them, their retention might materially increase the risk.

Vicarious Menstruation.—Efforts were also made to ascertain if in any way the menstrual function was retained. In 2 cases (8705 and 9527) bleeding from the nose was noted at the time menstruation would normally have been present. Both of these patients prior to operation had not been subject to bleeding from the nose. In one of these cases (8705) bleeding occurred at the second month after operation, but never reappeared. In Case 9527 bleeding from the nose appeared each month for several months. In neither of these cases, however, is mention made of the duration or the amount of bleeding.

In 4 cases vaginal bleeding was present. Undoubtedly in these cases there had been a high amputation of the uterus, a small portion of the uterine mucosa remaining, which at the menstrual period continued to perform its normal function. In 3 of these cases the vaginal bleeding was irregular and lasted but a short time. The fourth case (9286) is most interesting. Three years after operation menstruation reappeared, and has continued each month for the past two years. The quantity of flow is slight.

Present Health of Patients.—In 36 of the cases the health

is "good"; in 13, "fair"; and in 7, "poor." In only 4 cases were the symptoms directly referable to the pelvis

Simple Left to Right Abdominal Hysterectomy with Removal of the Appendages.—When it is deemed advisable to remove the tubes and ovaries with the uterus, the technic carried out may be similar to that described on p. 600, the only difference being that the ligatures or clamps applied to the ovarian and tubal vessels control these vessels to the outer or pelvic side of the ovary, instead of near the uterine horn.

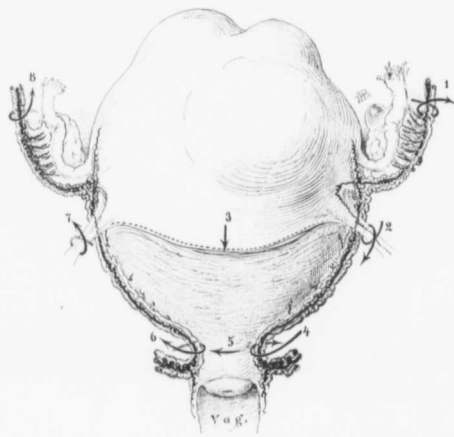


FIG. 355.—A DIAGRAMMATIC REPRESENTATION OF THE LEFT TO RIGHT OPERATION.

This represents a hysterectomy after the menopause, otherwise the ovaries would not have been removed. First the left ovarian vessels are controlled and cut, then the left round ligament. The bladder is now freed, and the left uterine vessels are controlled. The cervix is cut across, the right uterine vessels are clamped and severed, and the uterus is rolled out. The right round ligament is clamped and cut. The right ovarian vessels are controlled, and the uterus is removed.

The numbers and arrows indicate clearly the line of procedure. (After Howard A. Kelly.)

Several years ago one of us (Kelly*) described a method which materially simplifies hysteromyomectomy. It is usually spoken of as the "left to right," or "right to left," operation (Fig. 355).

The usual steps in the operation are the following:

1. Suturing and severing the left round ligament.
2. Doubly clamping and cutting the left ovarian vessels (Fig. 344).
3. Freeing the bladder from the uterus.
4. Blunt dissection of the left broad ligament and double clamping of the left uterine vessels.

* H. A. Kelly, Johns Hopkins Hosp. Bull., February, 1896.

5. Amputation of the uterus through the cervix (Fig. 345).
6. Clamping the right uterine vessels and severing these vessels.
7. Clamping the right round ligament and right ovarian vessels, severing them, and removing the uterus.
8. Tying all cardinal vessels (Fig. 348).
9. Closure of the cervix, with insertion of the round ligaments into the cervical stump (Fig. 350).
10. Covering over all raw areas with peritoneum (Figs. 351 and 352).

In this operation the aim is literally to roll the tumor out of the abdomen. When the left round ligament is severed and the left ovarian vessels are ligated and cut, the bladder is freed from the uterus; the uterus is then drawn strongly to the right, and with gentle dissection the left uterine vessels are seen or felt, and must be controlled by the most trustworthy clamps—preferably Wertheim's. When the cervix is cut across, the uterus can be drawn still further outward. The lower part of the cervix is meanwhile firmly grasped with mesoforceps by an assistant to prevent it from receding. As the knife severs the final cervical fibers on the right, great traction is exerted and a certain amount of stretching of the tissues enables the operator to grasp the uterine vessels at a higher level. These once severed, the uterus can be rolled out, and after the round ligament and the ovarian vessels have been clamped, the uterus is free. All cardinal vessels are now controlled, the cervix is closed, and all raw areas are covered over with peritoneum.

In each case some minor modifications may be necessary. For instance, in some cases when there is not room to apply two forceps to the left ovarian vessels, it may be necessary to ligate the vessels and then cut, the vessels on the uterine side being grasped as they are cut. Again, when the operation is likely to be a long one or when it may be necessary for the operator to withdraw without doing a complete operation, it is often wise to tie all vessels as they are encountered. Where it is very difficult to get a point of cleavage on the left side, the removal may be started on the right and carried to the left. In this operation the more difficult side is always left until the last, and in the end it really becomes the easier side, as after severance of the cervix the uterus can be rolled out without difficulty.

HYSTEROMYOMECTOMY FOLLOWED BY IMMEDIATE REMOVAL OF THE APPENDAGES.

In certain cases the appendages are so glued down to the surrounding structures that their removal is not only fraught with much danger, but it is almost impossible to get a point of cleavage. Where such a condition exists, the uterus, as a rule, is not very large. This is readily understood, because if the uterus had reached large proportions, the appendages would have been lifted high into the abdomen, and then control would have been easier.

In such cases two methods of treatment are available:

1. Hysterectomy with immediate removal of the appendages.
2. Bisection of the uterus.

Wherever possible, hysterectomy is preferable, bisection being reserved for those cases in which hysterectomy is otherwise impossible.

Hysterectomy with Immediate Removal of the Appendages.—The uterus is firmly grasped with strong mesoforceps, and any vantage once gained by the traction is never yielded. The following steps are then taken:

1. Clamping and cutting of the left appendages at the uterine horn.
2. Tying and severing the left round ligament.
3. Separating the bladder reflection.
4. Exposing, clamping, and severing the left uterine vessels.
5. Cutting across the cervix.
6. Clamping and severing the right uterine vessels.
7. Clamping and severing the right round ligament, the right appendages at the uterine horn and removing the uterus.
8. Liberating the left appendages from below upward, clamping the ovarian vessels, and removing.
9. Liberation of the right appendages. Clamping of the ovarian vessels; removal.
10. Tying all the cardinal vessels.
11. Closure of the cervix, with insertion of the round ligaments into the stump if feasible.
12. Closure of all raw areas.
13. Drainage through the vagina if raw areas cannot be covered, or if there is much danger of infection.

By removing the uterus first, the adherent appendages can be gotten at from the under side and dissection carried on under sight. Before this procedure was adopted the rectum was much more frequently injured. Naturally, clamping the vessels instead of tying them during removal of the uterus is preferable, as in the later steps of the operation the tying of the vessels further out would make the first ligatures superfluous.

Recently one of us (Kelly) has cupped out the cervix to a marked degree in those cases in which inflammation of the cervical mucosa is suspected. From Figs. 353 and 354 it will be noted that the cervical mucosa is dissected free almost to the external os. It is then clamped, so that none of the cervical contents can escape to contaminate the cervical stump, and then cut across below the clamp.

BISECTION OF THE UTERUS.

In a certain number of cases the operator, on opening the abdomen, feels completely baffled to find the uterus sitting on the top of a myoma, which fills the pelvis (Fig. 356), or that the uterine tumor fits the pelvis so accurately and is so fixed by adhesions that the usual operative pro-

eslures are futile. Or, as in Case 9678, a large pelvic abscess may add to the difficulty.

In such cases bisection, as described by one of us (Kelly),* in 1900, enables the operator in a few minutes to overcome the chief obstacles, and enucleation can then be effected.

As seen on p. 683, the mortality in this operation is high. In myoma cases it is never to be resorted to when the uterus can be removed intact, and is to be studiously avoided whenever the chance of sarcomatous degeneration of a myoma exists, or when there is a possibility of carcinoma of the body being present.

It is but natural that the mortality should be high, as it is only in desperate and otherwise inoperable cases that the operation is to be performed. The steps of the operation are as follows:

1. Grasp each side of the fundus with strong mesoforceps and make firm traction upward (Fig. 357).

2. Cut directly through the center of the tumor until the vesical reflection is reached.

3. Dissect down the vesical reflection, the assistant meanwhile keeping up the strong traction.

4. Continue the bisection until the cervix is reached (Fig. 358).

5. Cut to the left until the uterine vessels are nearly exposed, meantime making very strong traction on the left half of the uterus (Fig. 359). Doubly clamp the left uterine vessels and cut between forceps.

6. Roll out the left half, clamping in succession the left round ligaments and the left ovarian vessels (Fig. 360).

7. Cut across the right of the cervix until the tumor is nearly free. Clamp the right uterine vessels and cut.

8. Clamp the right round ligament and the right ovarian vessels in succession and deliver the right half of the uterus.

9. Ligate the cardinal vessels.

10. Close the cervical flaps.

11. Cover all raw areas with peritoneum, and drain through the vagina if it be deemed necessary.

It is a well-known fact that strong traction greatly diminishes hemorrhage.

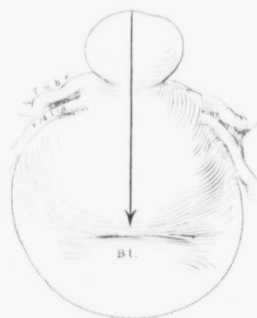


FIG. 356.—BISECTION OF THE UTERUS.
The arrow indicates the line of bisection.

*Howard A. Kelly, A Preliminary Report on the Surgical Treatment of Complicated Fibroid Tumors of the Womb, with a Description of Two Methods of Operating, Johns Hopkins Hosp. Bull., 1900, vol. xi, p. 56.

so there should be no let up on the mesofoereps from the time bisection is commenced until the two halves of the uterus have been delivered.

Sometimes it is only necessary to continue the incision until a large myoma has been bisected and shelled out (Fig. 361). In such cases the uterus may then collapse, and the operation is converted into a simple one (Fig. 362), the uterus being easily removed in the usual way from left to right.

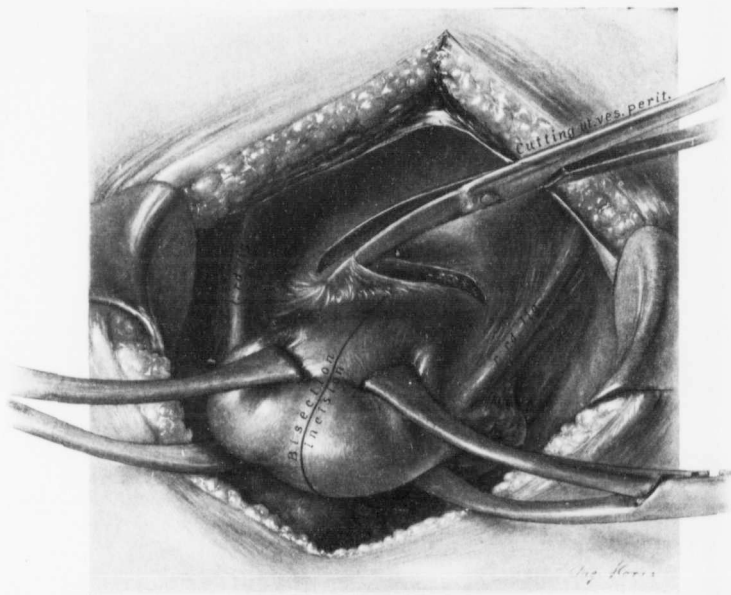


FIG. 357.—FIRST STEPS IN BISECTION OF THE UTERUS

The fundus has been firmly grasped on the right and left with mesofoereps. The bladder is being dissected free and pushed down preparatory to bisection of the organ. The myomatous uterus has purposely been drawn small, so that the various steps can be more readily followed.

In other cases, even after bisection and shelling out of the uterus, dense adhesions are found fixing it to the pelvic floor. These adhesions are now carefully dissected free from below upward under sight.

As a rule, the operation is not accompanied by much hemorrhage, but if in the bisection the knife cuts too far to one side, large venous sinuses or big branches of one or other uterine artery may be cut, and alarming hemorrhage follow.

We cannot be too emphatic in saying that this operation should be employed only where no other method is feasible.

On the other hand, bisection is of the greatest assistance to the surgeon in

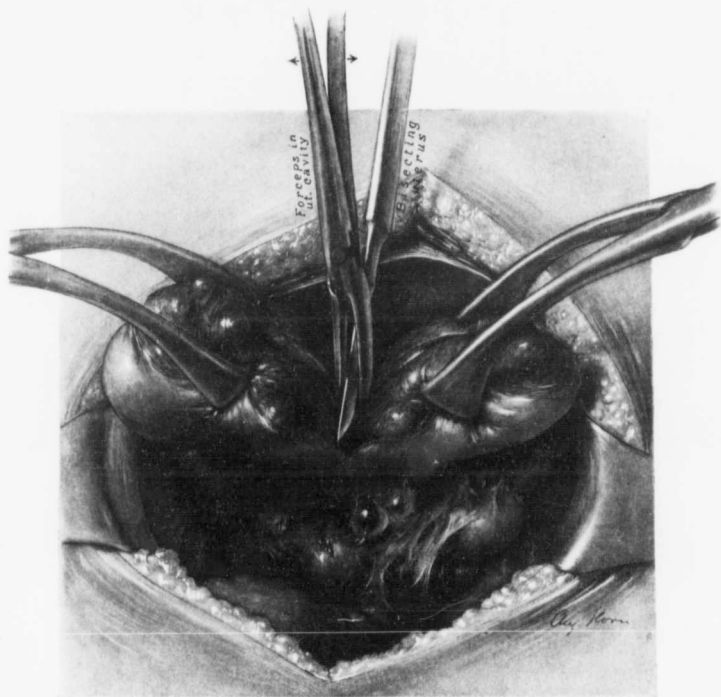


FIG. 358.—BISECTION OF THE UTERUS.

The uterus has been bisected almost to the cervix. The mesoforceps now grasps each half of the uterus about its middle. A pair of artery forceps in the uterine cavity insures cutting in the midline, thus avoiding either uterine artery. The appendages are embedded in adhesions.

cases in which hysterectomy is necessary, on account of densely adherent pus-tules. In such cases there is, as a rule, little danger from splitting the uterus. The adhesions are then attacked from their under side, and a very difficult or impossible removal of the uterus is rendered comparatively easy. For such

cases bisection is undoubtedly the easiest operation, and yields the lowest mortality.

Abdominal Hysteromyomectomy from Below Upward, Transverse Section of the Cervix being the First Step.—One of us (Kelly*) when operating upon a very complicated myomatous uterus, found it so firmly fixed that its removal by

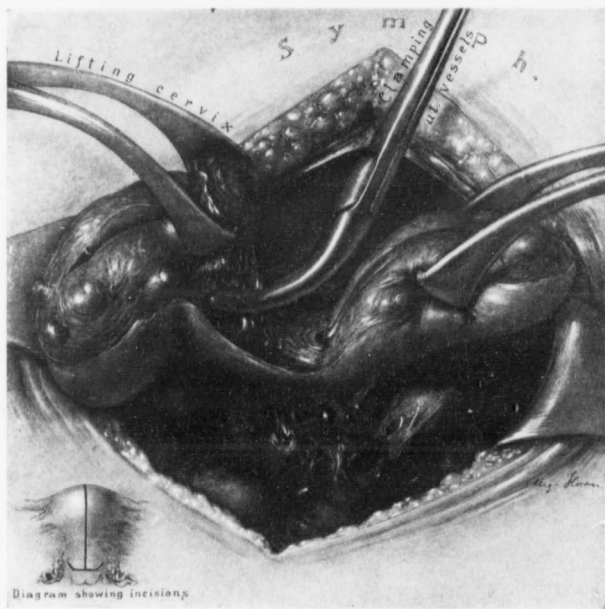


FIG. 359.—BISECTION OF THE UTERUS.

The left half of the uterus has been amputated through the cervix. This portion of the cervix is drawn strongly upward with meso-forceps, and the left uterine vessels are clamped. The left half of the uterus is now rolled completely out, clamped at the uterine horn, and removed.

any of the usual methods, or even by bisection, was out of the question. A novel plan was then adopted. Fortunately, the cervix was fairly accessible. The bladder reflection was at once separated, and the cervix firmly grasped with meso-forceps (Fig. 363). It was then severed transversely, and the uterine

* Howard A. Kelly, A Preliminary Report on the Surgical Treatment of Complicated Fibroid Tumors of the Womb, with a Description of Two Methods of Operating. Johns Hopkins Hosp. Bull., 1900, vol. xi, p. 56.

vessels were grasped on either side (Fig. 364). The cervix having been cut through and the broad ligaments opened, the round ligaments were next cut, the ovarian vessels clamped and cut and the densely adherent tumor was then freed from its pelvic attachments. The abdominal complications were then readily dealt with, first because they could be studied both from in front and also from behind, and—equally important—because there was now little bleeding, the cardinal vessels of the tumor having been tied.

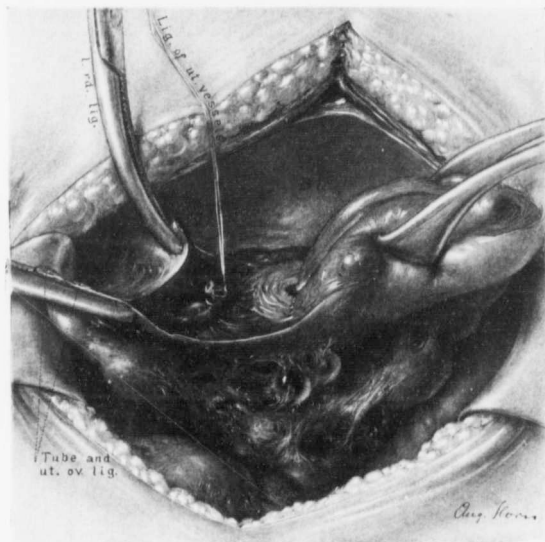


FIG. 360.—BISECTION OF THE UTERUS.

The left half of the uterus has been removed. The left uterine vessels have been tied. The left round ligament and the left tubal and ovarian vessels are controlled with forceps. The right half of the uterus is removed in the same manner. The adherent appendages are now carefully dissected free under sight, and removed if necessary.

We cannot better show the value of this operation than by giving in detail the first case that led to its employment.

In Case 7549 the patient, when placed on the table, had a small, rapid pulse which soon reached 140. After the release of some omental adhesions a large myomatous tumor was found glued down by extensive adhesions. The transverse colon was so intimately attached to it (Fig. 109, p. 143) that it soon became evident that continued dissection would finally necessitate an extensive resection

of the bowel. An attempt was then made to leave a thin layer of the tumor attached to the bowel, as had been successfully carried out in the previous case.* The bleeding became so profuse that this plan of procedure had to be abandoned. The operator then turned to the lower pelvic pole of the tumor. The cervix was grasped with strong mesoforceps and pulled up within reach. The vesical reflection was dissected back, and the cervix grasped low down with a second pair of mesoforceps. The cervix was now cut transversely from before backward, con-

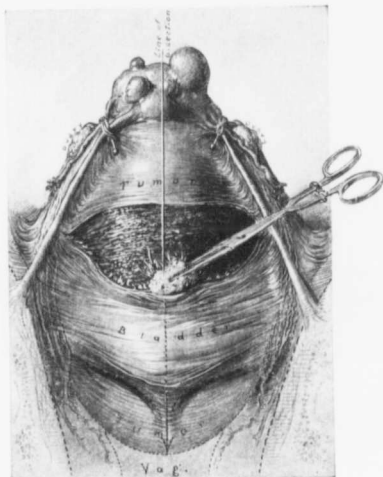


FIG. 361.—BISECTION WHERE THE UTERUS COMPLETELY FILLS THE PELVIS.

The myomatous uterus filled the pelvis so accurately that it would have been absolutely impossible to get at the uterine vessels. The vessels at the uterine horns have been controlled temporarily to partially check the blood-supply to the tumor. The bladder peritoneum is being pushed down prior to bisection of the body of the uterus, in the line indicated by the arrow. The bisection with removal of the large myoma is shown in Fig. 362. (After Howard A. Kelly.)

tinued traction being made on both portions. The cellular tissue to the left of the cervix was then exposed, and the uterine vessels, although not yet seen, were doubly clamped and severed. The uterine vessels on the right side were next controlled in the same way.

When these important vascular trunks had thus been secured, the larger forceps were used to forcibly drag up the tumor and the uterine body, rotating them on a transverse axis, exposing first the round ligament, then the ovarian vessels on the left, and then those on the right side. These structures were

*Howard A. Kelly, Johns Hopkins Hosp. Bull., 1891, vol. ii, p. 46.

clamped, and the whole mass was disconnected from its pelvic attachment. The tumor now remained fixed only by dense adhesions at its upper pole.

The next occurrence was the rupture of a large abscess lying behind and extending from the center of the tumor into a sac, bordered posteriorly by the lumbar vertebrae, and above by the mesocolon, and discharging through a large opening into the transverse colon.

The specimen examined showed that the abscess was in reality a suppurating

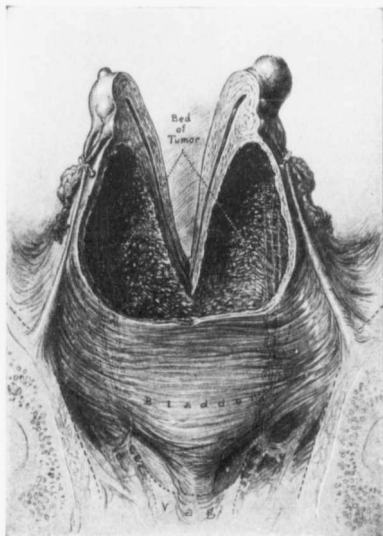


FIG. 362.—THE VALUE OF BISECTION OF THE UTERUS.

Fig. 361 shows the appearance of the uterus before the bisection. We now see the uterus split in two. The large myoma which occupied the anterior wall and blocked the pelvis has been shelled out, leaving plenty of room. The cardinal vessels can now be controlled with ease, and the hysterectomy completed in the usual manner. (After Howard A. Kelly.)

myoma, which had become adherent and had discharged into the large bowel. The tumor was now shelled out and enucleated from behind upward without any injury to the bowel. The contaminated abdominal cavity and the abscess cavity, which contained at least a liter of thick yellow pus, were closed. The opening in the bowel was sutured. An abdominal drain of iodoform gauze was carried down to the point of this sac and the abdomen closed. The patient made an excellent recovery, and only a small, rapidly closing fistulous tract remained.

Had the operator not hit upon this method of first amputating through the cervix and then working from below upward, any radical procedure would have been out of the question, and the patient's death would at have been a matter of only a short time.

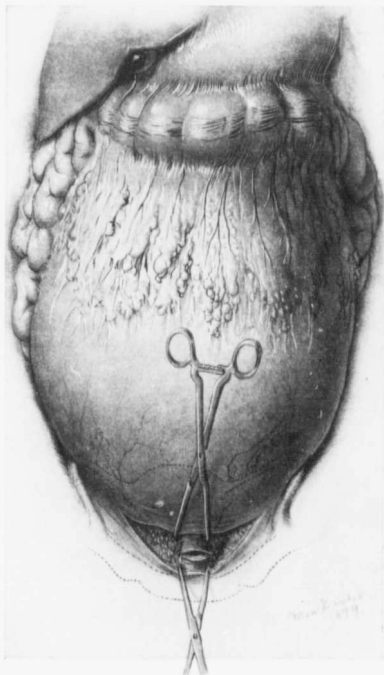


FIG. 363.—TRANSVERSE SECTION OF THE CERVIX AS THE FIRST STEP IN HYSTEROMYOMECTOMY.

It was impossible to separate the myomatous uterus from the omentum and transverse colon without great danger of losing the patient on the table. Fortunately, the cervix was accessible. The overlying bladder peritoneum was severed, the cervix grasped with two pairs of mesofoceps, and severed transversely. The complete separation of the cervix is seen in Fig. 364. (After Howard A. Kelly.)

PANHYSTERECTOMY.

When complete removal of the uterus is decided upon, we have found it wiser to control all vessels as they are encountered. We will describe the method

of hysterectomy where it has been found advisable to remove both ovaries with the uterus.

1. The left round ligament is tied with catgut and cut.

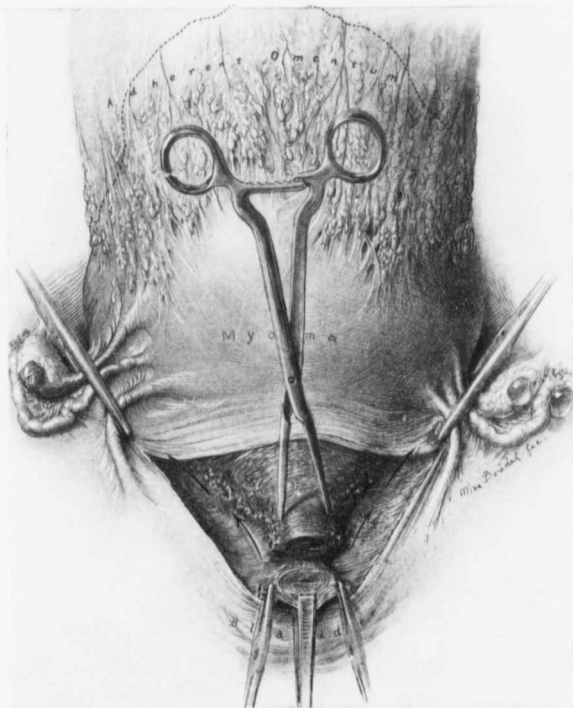


FIG. 364.—ABDOMINAL HYSTEROMYECTOMY "FROM BELOW UPWARD."

The cervix was separated transversely. The uterine vessels were clamped and cut and the ovarian vessels clamped. The uterus was then liberated from its pelvic attachment in the manner indicated by the arrows. It was then rolled out, walled off from the abdominal contents with gauze, and the adhesions to the transverse colon were attacked from their posterior and ensler side. Had the abscess opening into the bowel (Fig. 109, p. 143) ruptured before the uterus had been freed from the pelvis, the dangers of a fatal termination would have been infinitely greater. (After Howard A. Kelly.)

2. If the left ovarian vessels are accessible, they are tied with Pagenstecher thread, reinforced with catgut and cut.
3. The right round ligament is tied and cut.

4. The right ovarian vessels are tied and cut.
5. The bladder reflection is dissected free and pushed down.
6. The left uterine vessels are tied and cut.
7. The right uterine vessels are tied and cut.

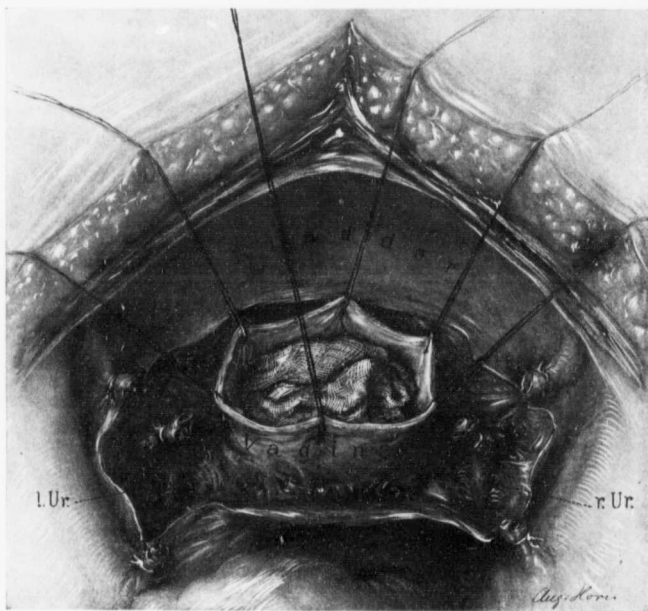


FIG. 365.—APPEARANCE OF THE PELVIS AFTER COMPLETE HYSTERECTOMY.

The vagina is walled off with a piece of gauze; the vaginal walls are held taut by provisional sutures (or artery forceps) to prevent infection from the vagina. The ligated stumps of the ovarian and uterine vessels and the round ligaments are seen. In some cases, as indicated in the drawing, the ureters are also clearly visible. The vaginal walls are whipped over to check bleeding, and the vagina is either drained or closed. The raw areas are then covered over.

8. The cervix is gradually dissected free until the vaginal wall is seen on all sides.
9. The cervix is freed from the vagina on all sides and the uterus removed (Fig. 365).
10. The vaginal margins are whipped over with fine catgut to control all bleeding, and if it is deemed safe to close the vagina, the anterior and posterior raw vaginal surfaces are approximated.

11. The raw areas in the pelvis are covered over with peritoneum.

The plan of operation differs little from that employed in the supravaginal hysterectomy, until the cervix is reached. The uterine vessels are ligated by passing a needle threaded with Pagenstecher thread close to the cervix, so as to avoid piercing the vessels. A second suture of catgut is then introduced in the same way.

After the uterine vessels have been cut, the dissection is carefully carried downward until the vagina is encountered. Here one frequently finds vaginal veins which may cause troublesome bleeding. In catching these vessels great care must be taken to avoid the ureters.

After the right uterine vessels have been controlled and the dissection has been carried down to the vagina, little difficulty is usually encountered in severing the cervix from the vagina, but, should there be any, a pair of artery forceps pushed up into the vagina from below may be cut down upon and the vagina thus easily opened (Fig. 369).

It is wise to drain the pelvis in all cases where there is likelihood that the uterine cavity has been infected.

Raw Areas.—The surgeon aims to produce as few raw areas as possible, and when finishing the operation, if feasible, leaves everything covered with peritoneum (Fig. 352). This minimizes the possibility of intestinal loops becoming adherent, kinking, and causing intestinal obstruction.

Raw areas after an abdominal hysteromyomectomy are usually due to an accompanying pelvic infection. Thus, in Case 6198 the uterus was firmly fixed to the rectum. After operation it was found impossible to cover the cervical stump, and it was left bare. In Cases 8690 and 12139 the raw areas were so extensive that it was impossible to cover them.

Sometimes the capillary oozing from the roughened peritoneum, whence an adherent tube or ovary has been liberated, is persistent. This oozing may be controlled with hot gauze left on for a few minutes while the operator is engaged in liberating or tying other structures. If the bleeding is not checked, a suture which puckers up the peritoneum may control it perfectly, as in Case 7739.

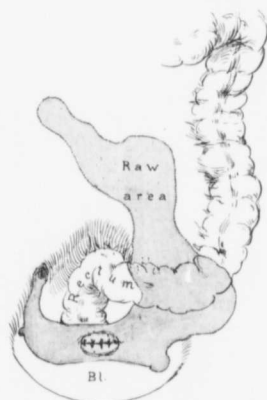


FIG. 366.—A LARGE RAW AREA LEFT AFTER REMOVAL OF A CYSTIC MYOMA.

GYN. No. 4828. The abdomen was filled with a cystic myoma which had carried the sigmoid flexure above the umbilicus. The sigmoid, as now seen, has dropped back into the pelvis.

In closing such a raw area the large vessels or the left ureter might be very easily pricked with the needle.

When the bleeding area is small and the needle prick causes much oozing, the point may be lifted up and tied, as indicated in Fig. 367.

A large raw area in Case 7064 was completely covered in by drawing the broad ligament over it. The bladder may also be pressed into a similar service, especially where, as a result of an extensive myomectomy, the surface of the uterus is much roughened. In some of these cases we have drawn the bladder over such an area and sutured it, thus completely hiding the suture line. Occasionally we have drawn the bladder peritoneum back, and attached it to the peritoneum of the rectum.

In suturing the peritoneum (Fig. 366) delicate needles and fine catgut should be employed, and great care exercised to avoid piercing blood-vessels or one or other ureter.

Where thickened and indurated areas are felt, as after the evacuation of a pelvic abscess, it is not only impossible, but unwise, to attempt to cover them over with peritoneum. In such cases a gauze drain laid in the pelvis and brought out through the vagina will yield the best results.




FIG. 367.—METHOD OF CONTROLLING A BLEEDING AREA WHERE A NEEDLE CANNOT BE SAFELY EMPLOYED.

Sometimes a bleeding point lies directly over a ureter or a large vessel, and any attempt to suture the area might entail injury to the vessel from the point of the needle. By lifting up such an area with a pair of curved forceps the operator can effectually control the bleeding without using the needle.

Irrigation of the Abdominal Cavity.—In many of the myoma cases operated upon in the early days of the hospital the abdomen was irrigated with salt solution just prior to closure. Sometimes this was done to wash out any blood that might have escaped into the abdominal cavity; in other cases to cleanse the intestines when pus had escaped during the hysterectomy.

With our more careful technic in walling off the tumor from the general cavity with gauze, the abdominal contents are rarely soiled, and if contaminated, they are carefully wiped off with gauze slightly moistened with salt solution. When it is impossible to cleanse the pelvis, the infected area is lightly packed with gauze, the lower end of which is brought down into the vagina. The patient is then put to bed, and is kept in Fowler's position for several days.

She is permitted to drink all the water she desires from the moment she recovers from the anesthetic.

We have entirely given up abdominal irrigations after hysterectomies for myomata.

Hemorrhage During Abdominal Hysteromyomectomy.—When the uterus is small and uniform, the ovarian and uterine vessels are easily gotten at and controlled; but when the tumor has reached large proportions, not only are the vessels displaced, but of necessity they are also much larger. Sometimes the uterine artery on one side may be carried up into the abdomen, while on the opposite side it is deep in the pelvis. The vessels may reach tremendous pro-

portions. In Case 7474, for example, the uterine arteries were fully as large as the femorals. A corresponding augmentation in the diameters of the veins has also been noted.

The great increase in the size of the ovarian vessels is described on p. 352.

Hemorrhage from the Pedicle of a Subperitoneal Myoma.—During a hysterectomy much traction is naturally employed, and sometimes subperitoneal, pedunculated nodules are partially or completely pulled away from the uterus (Fig. 368). In such cases free hemorrhage follows unless the pedicle is quickly clamped. This condition was present in Case H., admitted to the Church Home and Infirmary, March 16, 1903.

Hemorrhage Due to General Oozing.—When the myomatous uterus is adherent to the surrounding structures, free hemorrhage often accompanies the liberation of the tumor. This is due chiefly to capillary oozing, and not to bleeding from vessels of any appreciable size. The more recent the adhesions, the more marked is the tendency to bleed.

Tearing of the Ovarian Vessels.—In Case 7276, during the release of adhesions, one of the ovarian vessels was torn. Free hemorrhage followed, but was quickly controlled with forceps.

In Case 7064 the hysterectomy was a most difficult one, owing to dense vascular adhesions,

and because the tumor so accurately filled the pelvis. The vessels were clamped as encountered and tied later. The right ovarian vessels were tied and the clamps removed. The ligature was not tight enough, the artery retracted, and the free bleeding immediately produced a wide-spread hematoma, obscuring the situation of the artery. It was necessary to tie the vessel high above the brim of the pelvis, at the point at which it crossed the ureter. The hematoma was then shelled out, and the peritoneal surfaces were approximated.

Hemorrhage from the ovarian vessels is usually a minor complication, as these vessels are easily accessible.

Hemorrhage from the Uterine Vessels.—In Case 6722, after the left uterine vessels had been tied and severed, the cervix was cut across. Suddenly the right uterine artery was torn, and there was excessive and almost uncontrollable bleeding for half a minute, after which the artery was successfully clamped.

The myomatous uterus in Case 7266 was densely adherent and wedged in the pelvis. During the operation the left uterine artery was torn, and free hemorrhage followed before it could be controlled.

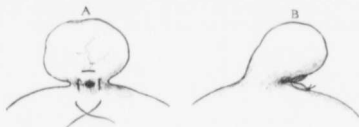

FIG. 368.—TEMPORARY CONTROL OF BLEEDING FROM A SUBPERITONEAL PEDUNCULATED MYOMA.

During an abdominal hysteromyomectomy a subperitoneal myoma may be partially torn away from the uterus, and troublesome oozing follow. If the operation is a long one, a mattress suture will effectually check the bleeding. *B* is a side view showing the suture securely tied.

After tying off the omental adhesions in Case 6206 the operator delivered the myomatous uterus and then began enucleation on the left side. The left ovarian vessels and the left round ligament were controlled and severed, and the bladder, which was high up on the surface of the tumor, was freed. As the tumor was being pulled up to get at the left uterine artery, this vessel, together with several large veins, was suddenly torn, and there was a tremendous gush of blood. The bleeding was, however, quickly checked.

During removal of the densely adherent myomatous uterus in Case 11634 the left uterine artery ruptured at a point just external to the ureter. In this case, on account of the oozing, it was necessary to drain through the vagina.

During removal of a small densely adherent myomatous uterus in Case 7120 the uterine artery was torn while the bladder was being liberated. The tear was in such close proximity to the ureter that it was necessary to carefully dissect out the ureter to avoid injury to it. The artery was then ligated near the pelvic floor.

Alarming Hemorrhage from Vessels on the Pelvic Floor.—In Case 6792 the uterus was found perched on the top of a large myoma. The normal appendages on each side and both round ligaments were tied and severed. The bladder was then freed and pushed down, and the uterine arteries on both sides were controlled. The uterus with the appendages was then removed. The tumor was then shelled out of the loose cellular pelvic tissue. It came out easily, but with tremendous hemorrhage, the blood almost filling the pelvis. After much difficulty it was found that the hemorrhage came from a large vessel on the pelvic floor. This was ligated, but the general oozing was still so profuse that the anterior branch of the internal iliac artery was tied. The raw area was now covered in, care being taken not to injure the ureter, which was placed toward the median line.

After all bleeding had been checked, several gall-stones were removed. The patient left the hospital well.

The myomatous uterus in Case 6915 was as large as that of an eight months' pregnancy, and the abdominal walls were very thick. The bladder reached almost to the umbilicus.

Enucleation was begun from right to left, and large masses of ovarian vessels were raised with difficulty and tied off, in a narrow space between the tumor and the pelvic brim. After section of the round ligament the bladder was dissected free on the right side and a large mass of knotted veins passing from the uterus to the bladder was revealed. These were ligated and cut. The right uterine vessels were exposed and tied without difficulty; the cervix was cut across, and the left uterine vessels controlled. As the uterus was being carefully drawn up there was a sudden uncontrollable hemorrhage. The bleeding point could not be gotten at, and nothing remained but to remove the uterus with the utmost speed, notwithstanding the bleeding. The tumor, which still held by its ovarian attachment, was rolled out of the abdomen, the blood rapidly

laddled out of the pelvis, and a large spurting vessel caught on the pelvic floor. During the necessarily speedy removal of the uterus the bladder was torn from the trigonum to the symphysis. The rent was closed, and the operation completed in the usual way. The patient was discharged well on the thirty-third day.

Hemorrhage Due to Slipping of a Ligature.—In Case 6178 the ligature around the left uterine artery slipped and free hemorrhage followed for several minutes. The vessel was caught and retied.

Just as the abdomen was being closed in Case 5734 free blood was noted in the pelvis; the ligature controlling the left uterine artery had slipped. The vessel was retied.

Hematoma in the Broad Ligament.—In Case 5193, at the close of the operation a hematoma, 4 x 5 cm., was noted in the left broad ligament. The clot was turned out and the bleeding vessels were controlled.

Hematoma Under the Sigmoid Flexure.—After removal of a large myomatous uterus in Case 7583 a hematoma, 3 x 5 cm., was detected under the sigmoid flexure. It was opened and the bleeding vessels were controlled.

Almost Fatal Bleeding from an Accessory Branch of the Uterine Artery.—The myomatous uterus in Case 4731 filled the entire lower abdomen. The cervix was represented as a mere button. Abdominal hysterectomy was performed without difficulty, notwithstanding intestinal adhesions and the marked vascularity of the tissues. Just as the patient was ready to leave the table she became pulseless and markedly blanched; a large clot was found filling the vagina.

On account of the collapse, internal hemorrhage was suspected, and the abdomen was at once explored. No blood being found, the cervical stump was reopened, and an accessory branch of the uterine artery found spurting. The blood from this found its way into the vagina through the cervical canal. Although the patient was pulseless at the wrist, she soon rallied and left the hospital well at the end of five weeks.

The above cases yield some very important practical suggestions:

1. In cases in which much difficulty is expected, tie vessels and cut as you go. When the emergency arises, the field will not be entirely obstructed by artery forceps.
2. Doubly ligate all the cardinal vessels.
3. If a hematoma forms, shell it out and catch the vessels.
4. Inspect all stumps carefully to see if bleeding has been effectually checked.
5. Whenever there is danger of including the ureter in a ligature, dissect it out to be sure that it is intact.
6. In whipping over the pelvic peritoneum be careful not to puncture a vessel, as a hematoma will result.

Vaginal Drainage.—Where, on account of raw areas in the pelvis that cannot be satisfactorily covered, or where, as a result of pelvic infection, it is deemed

advisable to drain the pelvis, vaginal is naturally preferable to abdominal drainage.

The easiest way to accomplish this is to have an assistant carry a pair of artery forceps high up into the vagina. The operator then cuts down upon the




FIG. 369.—METHOD OF ESTABLISHING VAGINAL DRAINAGE.

When, on account of raw areas or continued oozing, it is deemed advisable to drain the pelvis through the vagina, the latter is carefully wiped out and any secretions that may have escaped from the uterus during operation are in this way removed. A long curved artery forceps is then introduced into the vagina under sight, and pushed up directly behind the cervix, as indicated by *a*. At this point the forceps is cut down upon and then pushed up into Douglas' pouch. The opening is then enlarged by separating the forceps blades or with a dilator from above. The ends of the necessary drain or drains are now caught with the forceps and drawn down into the vagina, care being exercised not to include the rectum or any ligatures in the forceps. The upper end of the drain is held taut until the pelvis has again been wiped dry, and is then snugly applied to the pelvis. The rectum and bladder usually drop down and completely cover over the gauze, effectually preventing any loops of small bowel from adhering to it.

foreeps from above (Fig. 369). The opening thus made is stretched with the forceps, the pelvis is quickly wiped out, and one or more long pieces of iodoform gauze are introduced. The ends of the gauze are grasped with the forceps and drawn down until they are seen at the vaginal outlet. The pelvic portion of the drain is snugly applied to the raw area, and the rectum allowed to drop down over it, so that no small bowel can become adherent to the gauze. A piece of rubber tissue around the drains, at their exit from the pelvis, will facilitate their removal later.

In introducing the forceps the assistant must push them up directly behind the cervix. If introduced to one or other side, the vessels of the broad ligament may be cut or the ureter injured. Sometimes the rectum is adherent to the posterior surface of the cervix. In such a case, if it is not previously liberated, when the forceps are cut down upon, the incision will first open up a fold of the bowel, and then the vagina.

The artery forceps should be introduced into the vagina under sight. In one case (C. H. I., 949), in which a small uterus was studded with myomata, a pelvic inflammation was also present. On account of the pelvic inflammation it was decided to drain through the vagina, but not remove the uterus. The assistant experienced much difficulty in pushing the artery forceps up into the vagina directly behind the cervix. Finally, however, the maneuver was accomplished, and the operator cut down upon the forceps from above. He remarked that the vagina had not been carefully wiped out, as a small amount of clear fluid escaped. After two pieces of 3-inch iodoform gauze had been laid in the pelvis and their lower ends brought out below, the abdomen was closed. To our astonishment the end of the gauze was found emerging from the urethra, and not

from the vagina. Naturally, the assistant had had much difficulty in bringing the tip of the forceps up behind the cervix, but finally had done so by greatly stretching and distorting the bladder. The abdomen was at once opened, the gauze was drawn out from below, and a complete hysterectomy performed, the ureters being at the same time carefully dissected out, as it was impossible to tell whether they had also been injured. They were found intact; the hole in the base of the bladder was closed, and the patient made a perfect recovery.

A similar example is furnished by Case C. H. I., 1552, December 31, 1906. In this case, after removal of a densely adherent ovarian cyst, an artery forceps was introduced from below and cut down upon from above. Next morning the ends of the two pelvic drains were found emerging from the rectum instead of from the vagina. The abdomen was at once opened, and the drains withdrawn from the rectum. Only with great difficulty was the opening in the bowel closed, as the hole in the rectal mucosa was at a point 4 cm. below that in the outer or peritoneal coat. Finally, we reproduced the conditions present when the bowel was injured, by carrying the index-finger of the left hand up in the rectum to the hole, and then pushing it up until it was opposite the hole in the peritoneum. The opening was thus closed from above, and a drain introduced. The patient made an uninterrupted recovery.

Successful Hysterectomy in a Constitutional Bleeder.—In Case 11919 the patient was forty-seven years old. She gave a history of nephritis, was weak and anemic, and had a hemoglobin of 40 per cent. Ever since a child she had bled profusely from the slightest scratch or cut. Her sisters also had a marked predisposition to hemorrhage. She entered the hospital on account of a myomatous uterus, which reached to the umbilicus. There was severe uterine bleeding. After her hemoglobin had risen to 60 per cent. hysterectomy was performed, and the patient made a good recovery. The tendency to bleeding in no way retarded her convalescence.

Abdominal Hysterectomy in a Syphilitic Patient.—In Case 6791 a woman, aged forty, was the mother of two children. She had had syphilis for several years. On admission she was very weak, and had a soft systolic murmur at the apex.

The myomatous uterus was removed through the abdomen. The removal was rendered difficult on account of chronically inflamed and adherent adnexa and dense vesical, intestinal, and appendicular adhesions. Notwithstanding these complications, the hectic taint did not apparently retard the patient's progress and she made a good recovery.

Hysteromyomectomy in Patients with Renal Lesions.—We shall here discuss only those cases in which the patients recovered. The others are dealt with *in extenso* in their appropriate chapters.

In Cases 1069, 1383½, and 1672, albumin without casts was noted before operation. After removal of the uterus the albumin disappeared.

In Case 1946 albumin was noted before operation. Immediately after removal

of the uterus it increased in amount and then disappeared. In these cases we cannot say definitely that the kidneys were diseased, but the albumin certainly indicated an abnormal condition.

When a hysterectomy is contemplated and the urine found to contain albumin and casts, we have to consider whether the patient can successfully withstand the operation. It is a well-known fact that any patient having nephritis has a lowered resistance, and that the dangers accompanying any operation are much increased. On the other hand, the local pelvic condition in some cases is becoming so serious that the patient will in all likelihood succumb if operative relief is not given.

The following cases show what may be accomplished: In Case 5103, a white woman, aged fifty-four, had for four years been losing a good deal of blood. The last hemorrhage, she claimed, amounted to two or three quarts. The lower abdomen was filled with a globular uterus. The urine contained albumin and casts. After an abdominal hysterectomy the urine diminished in amount, while the albumin increased and hyaline and granular casts were very abundant. Convalescence was otherwise uneventful. The bleeding was due to a submucous myoma 6 cm. in diameter.

In Case 6272, a colored woman, aged thirty-six, entered Dr. Osler's service suffering from nephritis and mitral insufficiency. Later she was transferred to the gynecological department on account of a myomatous uterus. When the abdomen was opened, a considerable amount of ascitic fluid was found. The multinodular uterus filled the lower abdomen and was firmly fixed in the pelvis. After removal of the uterus the appendix was amputated. The patient recovered perfectly from the operation, and was returned to the medical side for further treatment.

These two cases demonstrate clearly that much may be accomplished even in most unfavorable subjects.

GENERAL HINTS IN OPERATIONS FOR THE REMOVAL OF UTERINE MYOMATA.

The following procedures we have found of especial value, before, during, and after hysteromyomectomy.

Before Operation.—When the patient is very anemic we build her up with rest, good food, iron, strychnin and plenty of fresh air, and operate before the next period, if this is likely to be profuse.

Inoperable cases may later become operable.

Remember that almost moribund patients may recover if operated upon.

Never operate without full permission to do all that is necessary, and then be as conservative as possible.

Never tell the patient that there is no danger in the operation.

Have the bowels well emptied before operation.

D u r i n g O p e r a t i o n .—Always determine the upper limit of the bladder with the catheter before opening the abdomen.

When a pelvic abscess exists, drain through the vagina and do a hysterectomy, if necessary, two or three months later.

A good long abdominal incision saves time in the end. Cut down almost to the symphysis.

Employ the operation offering the quickest and easiest removal of the uterus, and involving the least danger of loss of blood and of infection.

A tumor wedged in the pelvis can sometimes be pushed up by the hand in the vagina.

Rotate or "lateralize" a tumor to facilitate its delivery from the abdomen. A corkscrew introduced into the tumor answers as a good tractor in some cases, but should not be used where malignancy is suspected.

Get at dense adhesions from the under surface if possible.

Where dense intestinal adhesions are present, sacrifice the outer coats of the tumor (Fig. 377, p. 635). Do not injure the bowel.

When large omental vessels enter a myoma, ligate and tie distally and proximally. These vessels are very friable, and may tear if clamped.

The ovarian and uterine vessels in difficult cases may be more easily exposed by rotating the uterus.

Treat the cervical canal as if it were an infected area.

When the tumor involves the cervix, do a complete hysterectomy.

Cover in all raw areas when feasible.

If a large raw area involves several inches of small bowel, short circuit by means of a lateral anastomosis, and then roll in the raw area (Fig. 378, p. 635).

A f t e r - t r e a t m e n t .—Give enough morphin to relieve pain during the first twenty-four hours.

Let the patient drink all the water she desires from the time of operation, provided there are no especial contraindications. If she vomits, the stomach will be thoroughly washed out. If she retains the water, the excess of mucus will be carried into the bowel.

Get the patient on the back-rest in two or three days after operation, if feasible.

Use little catharsis—rely chiefly on enemata.

If there is the slightest sign of intestinal obstruction, give no cathartic by mouth, as it may increase the kink. Coax the intestinal contents down with enemata.

A low enema of two ounces each of glycerin and water will almost invariably relieve abdominal distention if not due to obstruction.

Open the abdomen at once if there are definite signs of peritonitis or obstruction.

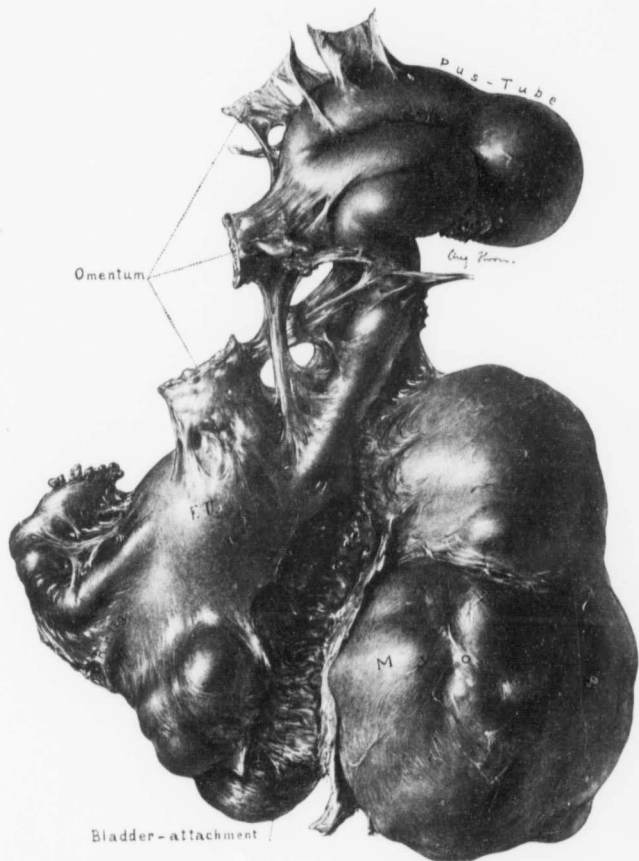


FIG. 370.—AN INDICATION FOR ABDOMINAL INSTEAD OF VAGINAL HYSTEROMYOMECTOMY. ($\frac{1}{2}$ nat. size.)

Path. No. 1990. Some surgeons advocate vaginal removal of the myomatous uterus as a routine procedure, but in our experience the enlarged uterus is often adherent to the omentum or to the bowel, and removal from below would prove a hazardous procedure. In this case we have a large left pus-tube which did not lie in the pelvis, but high in the abdomen. Its removal from below, even in the absence of the large myoma in the left broad ligament, would have been fraught with grave danger. As we are never absolutely sure what we will find on exploring the abdomen in these cases, it certainly seems that abdominal hysteromyomectomy is, as a rule, the more surgical procedure.

VAGINAL HYSTEROMYOMECTOMY.

Vaginal removal of the uterus is easily carried out provided the myomata are few in number and of small size, and provided there is a certain amount of prolapsus.

In about one-half of the cases the appendages were adherent (see p. 337), the adhesions adding materially to the difficulty of removal through the vagina.

The uterus may be removed intact by the usual method; but, if too large, may be drawn down, bisected, and removed, as has been so brilliantly done by Döderlein, Segond, Krönig, Wertheim, and others.

Our findings at operation have only served to strengthen our opinion that when the uterine myomata are of sufficient size to cause trouble, it is wiser to remove the uterus from above, especially as in some instances there are other and unsuspected pathologic conditions in the abdomen requiring treatment (Fig. 370), lesions that might be totally overlooked unless the abdomen were opened.

We must admit that the recovery after vaginal hysterectomy is a more speedy one, and that the immediate discomforts are infinitely less, but in the end we feel that the patient's condition is much better after the abdominal operation.

Out of the total of 993 hysteromyomectomies only 24 were by the vaginal route.

CHAPTER XXXII.

DIFFICULT ABDOMINAL HYSTERECTOMIES.

Thick Abdominal Walls.—The thickness of the abdominal wall plays an important rôle in all difficult abdominal operations for myomata. If the walls are thin and lax, exposure of the abdominal contents is easy, but, when much adipose tissue is present, removal of the uterus is often fraught with the greatest difficulty. The thickened abdominal walls naturally increase the distance to the pelvis, and in these cases there is liable to be much subperitoneal pelvic fat, and also much fat in the omentum. Moreover, these patients usually breathe badly.

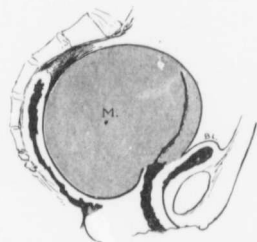


FIG. 371.—A MYOMATOUS UTERUS ACCURATELY FILLING THE PELVIS.

Gyn. No. 3338. The enlargement was due to a myoma in the posterior wall. If the myoma is soft, as in this case, the cardinal vessels are easily controlled, but when the tumor is very dense, it may be impossible to reach the ovarian or uterine arteries. In the latter case myomectomy, with subsequent hysterectomy or bisection, would have to be resorted to. This uterus could not be dislodged from the pelvis prior to operation.

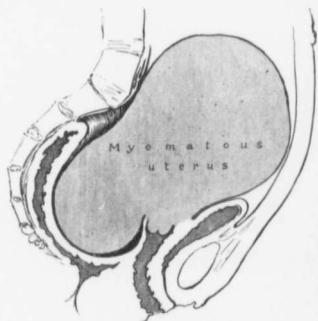


FIG. 372.—AN INCARCERATED MYOMATOUS UTERUS.

Gyn. No. 3119. The pressure symptoms were so severe just prior to operation that the patient, aged thirty-four, could not work. In order to get at the cardinal vessels and to deliver the tumor it was necessary to have an assistant press up from below. Even then delivery of the uterus would have been exceedingly difficult had not one of the myomata been soft as the result of degeneration.

The amount of adipose tissue may be marked. Thus in Case 2713 the abdominal walls were 6 cm. in thickness.

Uterine Myomata Adherent to the Abdominal Wall.—When the myomata are undergoing suppuration, they naturally become adherent to the surrounding structures, and, if near the abdominal wall, the nodule may become densely adherent to the peritoneum of the lateral or anterior wall, as was pointed

out in Chapter IX. Pelvic adhesions are very frequent. If the inflammatory reaction has been marked, adhesions between the abdominal wall and the myoma will be found in a few cases. In the following cases, in which the myoma had not undergone suppuration, adhesions to the abdominal wall were noted—Gyn. Nos. 2691, 3440, 4870, 7237, 7739, and San. No. 1049.

Raw areas on the abdominal peritoneum naturally cause the surgeon much concern. His aim is to draw over the peritoneum and completely cover them, but if the process has been a recent one, there is liable to be considerable induration, and the peritoneum is brittle instead of elastic and pliable. In such a case it is almost impossible satisfactorily to eliminate the formation of intestinal adhesions at these points.

Myomata Snugly Filling the Pelvis.—

Fig. 371 represents the type of a myoma that is often difficult to remove. It fills the pelvis snugly and cannot be dislodged upward into the abdominal cavity. Control of one or other uterine vessel is difficult, but when one side has been tied and cut, the cervix can be cut across and the tumor rolled out. If this plan is not feasible, it may become necessary to shell out the large tumor and do a hysterectomy, or bisection may be resorted to.

In Fig. 372 we have a very large unwieldy tumor, which not only completely fills the lower abdomen, but also the pelvis. In such a case shelling out of the myoma or bisection is out of the question. The only chance of removing the uterus lies in so rotating the tumor that the uterine vessels on one side can be controlled. The cervix is then cut across and the uterus removed.

Fig. 373 shows a rather unusual condition. The chief myomatous development having taken place between the folds of the broad ligament, it has become necessary to split the broad ligament on each side and carefully strip it off. Moreover, when the myomata develop in such a manner, the ureters may be displaced forward, outward, or downward, and their location must be ascertained most carefully. In this case the tumor was loosely adherent to the bladder and rectum.

Fig. 374 represents one of the most difficult cases the surgeon can encounter. The operation was begun from "right to left." Large masses of ovarian veins having been with difficulty tied and cut, and the bladder freed by dissection,

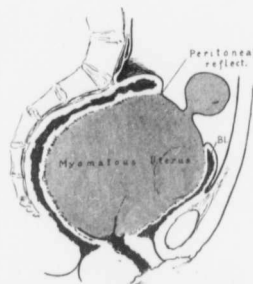


FIG. 373.—RETROPERITONEAL DEVELOPMENT OF MYOMATA.

Gyn. No. 4097. The myomatous uterus reached above the brim. The greater part of the myomatous development had been retroperitoneal. The rectal peritoneal reflection passed over to the myoma at the pelvic brim. Over the anterior surface the bladder reflection passed to the surface of the tumor, far above the level of the symphysis. Both the bladder and the rectum were displaced high into the abdomen, and during the liberation of the rectum a tear, 2 cm. broad and 12 cm. long, was made in its outer coats.

In such a case there is great danger of injuring the ureters, which, as might be supposed, are displaced by the tumor.

a large mass of knotted veins was revealed passing from the bladder to the uterus. All these were tied, and the right uterine vessels were then exposed and ligated with much difficulty. The cervix was cut across. The uterus was drawn up carefully, but a sudden and uncontrollable hemorrhage immediately followed.

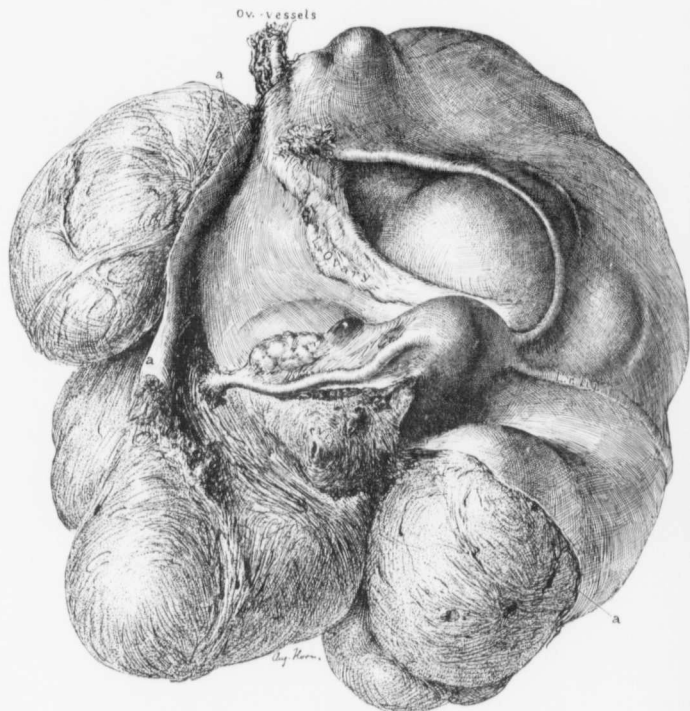


FIG. 374.—A VERY DIFFICULT HYSTEROMYECTOMY. ($\frac{1}{3}$ nat. size.)

Gyn. No. 6915. Path. No. 3170. The body of the uterus reached the level of the umbilicus and lay surrounded by myomatous nodules. The bladder had been drawn upward almost to the umbilicus. The letters *a* indicate the limits of the peritoneal covering of the tumor.

It now became necessary to enucleate with the utmost speed. The tumor was liberated on the left side and shelled out. Blood was literally ladled out of the pelvis, and all spurting vessels were caught. The tumor was cut away entirely and removed. The bladder was torn from the trigonum to the symphysis and drawn out in a long thin flap. It was sutured, and the raw pelvic areas

were covered over. Apart from a mild phlebitis in the left leg on the twenty-third day, the patient made a perfect recovery. If the uterus had not been removed with the utmost speed, the patient in a few minutes would have bled to death on the table.

In Fig. 375 the myomatous uterus accurately fills the pelvis and, viewed from the abdominal cavity, would seem difficult of removal. A previous careful bimanual examination, however, would have demonstrated that the uterus



FIG. 375.—A MYOMATOUS UTERUS BLOCKING THE PELVIS.

Autopsy specimen, January 15, 1897. The uterus fills the pelvis snugly and has crowded the greater part of the bladder above the symphysis. Viewed from the abdominal cavity, it seems almost impossible to lift the uterus out of the pelvis, but from Fig. 376 we see that it could be readily dislodged either by upward pressure from below or by means of a corkscrew from above. (After Howard A. Kelly.)

could be readily dislodged into the abdomen (Fig. 376), and myomectomy or hysterectomy, according to the age of the patient, rapidly carried out.

Intestinal Adhesions.—When we consider in how many cases the appendages are adherent (see p. 337) and, referring to the chapters dealing with parasitic myoma and suppurating myomata, follow the details of those cases in which the myomata were densely adherent to the rectum, or where hysterectomy was rendered exceedingly difficult on account of the uterus being bound down, we can readily understand why intestinal adhesions are commonly found.*

* Pronounced intestinal adhesions were noted in the following cases: Gyn. No. 515, 1151, 2108, 2691, 3394, 3842, 3921, 4370, 4731, 4732, 4870, 4917, 5123, 5260, 5392, 6133, 6324, 6432, 6521, 6791, 7064, 7181, 7226, 7549, 8008, 9027, 9078, 9342, 9678, 9736, 10651, 11472, 12209, 12488.

The bowel may become adherent to the myomatous uterus, to one or both appendages, or to the abdominal wall; or, as a result of a general peritoneal infection, the intestinal loops may become adherent to one another.

If the peritonitis has been of recent date, the involved intestinal loops are much injected, frequently edematous, and are easily parted, but their separation is followed by very profuse bleeding from capillary oozing.

Where the intestines have been long adherent, if loosely attached by fan-like adhesions, these can be readily cut without any hemorrhage. In some instances,

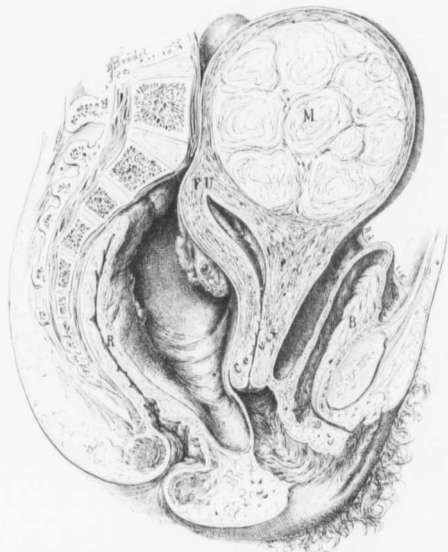


FIG. 376.—A MYOMATOUS UTERUS THAT TENDED TO SAG DOWN AND COMPLETELY FILL THE PELVIS. Autopsy, January 15, 1897. For the uterus before being dislodged from the pelvis see Fig. 375. (After Howard A. Kelly.)

however, the intestine is so glued to the tumor that it is necessary literally to cut it away. In such a case the wiser procedure is carefully to dissect through the outer layers of the tumor, leaving them attached to the intact bowel (Fig. 377).

When a large raw area is left on the intestine, it is usually advisable to short-circuit the gut just beyond and turn the raw areas in upon themselves, as indicated in Fig. 378. The treatment necessary when suppurating myomata open into the bowel is described on p. 612.

Myomatous Uteri Associated with Pelvic Abscess.—In some of the cases the operator can definitely outline the myomatous uterus from above, while on vaginal examination induration of the vault can be detected. This board-like thickening can usually be readily distinguished from the globular bulging of a myoma in Douglas' sac. When such an induration is present, hysterectomy is for the time being contraindicated. An incision should be made behind the cervix, and Douglas' pouch drained. Usually the patient will improve rapidly, and the vaginal tissue soften materially. She may be sent home for a few months, and then return for the hysterectomy. It is astonishing to note how much the nodular uterus loosens up as a result of the drainage, and what would have been a formidable and dangerous operation now becomes relatively easy. The following case illustrates such a plan of treatment.

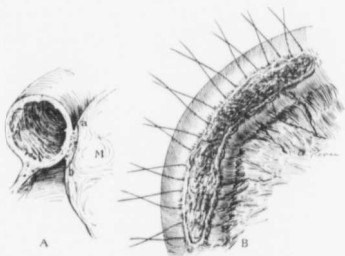


FIG. 377.—LEAVING THE OUTER LAYERS OF THE MYOMA ATTACHED TO THE BOWEL.

In some cases when the bowel is densely adherent to the myoma, as at A, the outer layers of the tumor can be left attached to the intestine, as indicated by the dotted line a-b. The freed bowel then presents the picture B. The bowel-wall is thus preserved intact, and the lumen is encroached upon only slightly.

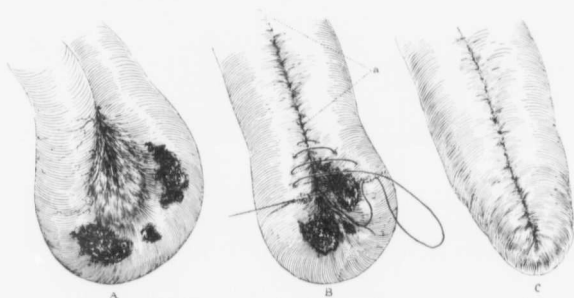


FIG. 378.—METHOD OF DEALING WITH EXTENSIVE INTESTINAL ADHESIONS.

A indicates three raw areas—points at which the bowel has been adherent to the myoma. To cover them in successfully necessitates much narrowing of the lumen of the bowel, with the danger of postoperative obstruction. One of us (Cullen) in such cases does a lateral anastomosis as a routine procedure. In Fig. B, at a, the line of the anastomosis is indicated. The raw areas of the bowel are then turned in upon themselves, leaving a perfectly smooth, tongue-shaped projection, C. The results have been most satisfactory.

Preliminary evacuation of a pelvic abscess; subsequent hysteromyomectomy.

Mrs. H., thirty-eight years of age, was admitted to the Church Home and Infirmary on March 31, 1904. She had for a long time complained of a pain in the lower abdomen. Occupying the entire lower abdomen was a hard mass which reached almost to the umbilicus. Through the rectum a distinct bulging, irregular in character, could be detected.

On opening Douglas's sac through the vagina we encountered a smooth pocket, 9 cm. in diameter. On the left side was a pus-cavity containing 500 c.c. of grayish-yellow, non-odorous pus. Both cavities were drained. The patient left the hospital with instructions to return later for hysterectomy.

July 26, 1904: She had improved greatly in health, but the pain in the left side had been persistent. On opening the abdomen we found many adhesions, and a myoma 6 cm. in diameter. The right tube and ovary were much enlarged and densely adherent. The left tube and ovary formed a mass 8 cm. in diameter. We amputated from right to left with much difficulty, but were able to control the vessels perfectly. Vaginal drainage was employed, and the patient made a good recovery.

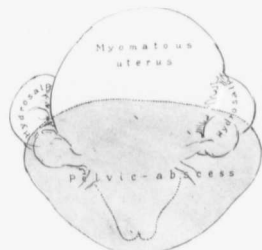


FIG. 379.—A LARGE ABSCESS LYING ANTERIOR TO A MYOMATOUS UTERUS.

Gyn. No. 8008. The patient was forty-one years of age and colored. Three weeks before admission, while washing clothes, she had severe pain in the lower abdomen, and on the following day noted some abdominal swelling. She was in bed for two weeks before admission.

At operation the bladder was found extending half-way to the umbilicus, and the intestines were everywhere adherent. Anterior to the globular myomatous uterus lay the large abscess indicated by the shaded area. Both tubes were filled with clear fluid. Hysterectomy was performed, and the abscess drained through the vagina. Recovery.

when the abdominal organs are so loaded with fat that exposure of the field of operation is almost impossible. In a few instances the pelvis has been so deep that great difficulties were experienced in removing the uterus.

We are here chiefly interested in those cases in which, on account of dense adhesions or the coexistence of a purulent collection in the pelvis, hysterectomy is almost impossible.

Case 7181 is an example of that class of cases in which the operator, on opening the abdomen, feels almost hopeless. Everything is so glued down and covered with adhesions that few, if any, of the familiar landmarks are visible. Finally, he finds one point of vantage, and after loosening up this area, another is exposed, until in the end the uterus can be removed.

While it is, as a rule, advisable to drain an abscess and do a hysterectomy later, there are certain cases in which this is not feasible. In Fig. 379, for instance, the pelvic abscess lay anterior to the uterus, and without an abdominal operation could not have been intelligently handled. In this case it was wiser to do a hysterectomy at the same time.

The Treatment of Apparently Inoperable Uterine Myomata.—Great difficulties are occasionally encountered when the intestines have been imperfectly emptied, or

when the abdominal organs are so loaded with fat that exposure of the field of operation is almost impossible. In a few instances the pelvis has been so deep that great difficulties were experienced in removing the uterus.

We are here chiefly interested in those cases in which, on account of dense adhesions or the coexistence of a purulent collection in the pelvis, hysterectomy is almost impossible.

Case 7181 is an example of that class of cases in which the operator, on opening the abdomen, feels almost hopeless. Everything is so glued down and covered with adhesions that few, if any, of the familiar landmarks are visible. Finally, he finds one point of vantage, and after loosening up this area, another is exposed, until in the end the uterus can be removed.

Gyn. No. 7181.

A densely adherent myomatous uterus.

A. R. L., married, white, aged forty-two. Admitted September 4; discharged October 1, 1899. On section of the abdomen the omentum was found drawn out into a cord-like mass, 9 cm. broad. This was spread out over the surface of the tumor and had become adherent to the bladder. The tumor was wedged in the pelvis and immobile; a nodule, about 11 cm. in diameter, extended upward and lay against the right costal margin. A hand was passed under the mass, and by rotation the nodule was brought out of the abdomen. The main tumor mass was then partially raised out of the pelvis. The uterus was everywhere surrounded by adhesions, and posteriorly no opening could be found on the left side. The left tube and ovary were densely adherent and were plastered on the side of the tumor; the left broad ligament lay spread out over the surface. Posteriorly, the small intestines were everywhere densely adherent to the tumor, and it was impossible to pass a hand beneath the tumor on account of adhesions to the large bowel.

On the right side everything was glued down. The ileum and appendix were adherent to the infundibulopelvic ligament. The right broad ligament was very much thickened, and was drawn up over the mass; beneath it, in the angle between the pelvic wall and the fundus, was a small cystic tumor. The bladder was drawn high up over the tumor and covered a myomatous nodule.

Operation. The omentum was ligated and released, the small gut freed along the posterior border. The left tube and ovary were dissected free with scissors. It was still impossible to budge the tumor. Finally, an opening was made and the ovarian vessels were caught about 3 cm. above and under the sigmoid, which also had to be dissected back. The right round ligament was next caught and severed, and now, for the first time, the tumor commenced to yield. The bladder was most carefully outlined and pushed down with a sponge. The engorged left uterine artery was exposed, caught, and ligated with heavy silk. Even then the tumor was so immobile and so densely adherent posteriorly that it was deemed best to control the vessels on the right side. This was accomplished with the greatest difficulty. The right ovarian vessels were controlled after the most careful dissection. An attempt was made to control the right uterine vessels, but they could not be exposed. The subvesical vessels were large and bled actively. The cervix was amputated; free hemorrhage followed, but the right uterine vessels were then caught with clamps and the right broad ligament was clamped and cut. After removal of the uterus the right tube and ovary were gradually dissected loose. The remainder of the operation was carried out in the usual manner. The patient made a very satisfactory recovery.

C. H. I., Case K. March 14, 1903.

Uterine myomata associated with an ovarian abscess, an abscess in the omentum (Fig. 380), partial

obstruction, relief by exploratory operation. Hysterectomy two weeks later.

Case K., seen in consultation with Dr. A. Barr Snively, of Waynesboro, Pa., on March 14, 1903, is an excellent example of what may be accomplished by completing the operation in two stages. When the patient was first seen, there were symptoms of obstruction. These were relieved, and the abdomen was

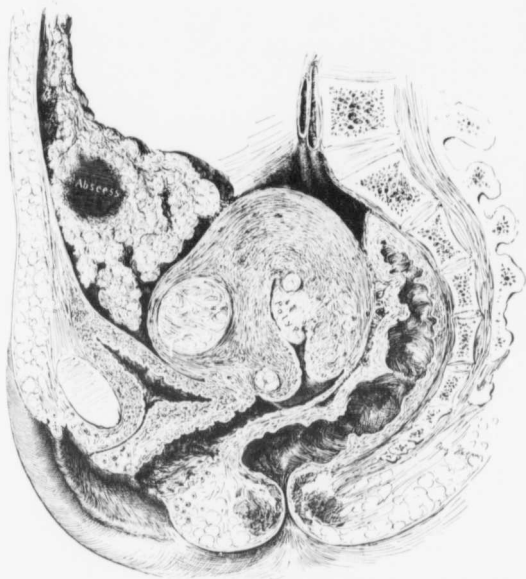

FIG. 380.—CIRCUMSCRIBED ABSCESS IN THE OMENTUM ASSOCIATED WITH A DENSELY ADHERENT MYOMATOUS UTERUS AND AN OVARIAN ABSCESS.

C. H. I., K., March 26, 1903. The uterus reached to the pelvic brim. In the longitudinal section of the uterus three myomata are seen. It also contained others. Projecting into the uterine cavity is a polyp. The posterior surface of the uterus is densely adherent to the rectum. One ovary had been converted into an abscess sac. This is not, however, visible at this level. The omentum is markedly thickened and contains an abscess.

drained. After a delay of nearly two weeks it was possible to do a complete hysterectomy. Had we attempted a radical operation when the patient was first seen, she would have undoubtedly died on the table.

This patient had been ill for about a year, and several months before had had an attack of pelvic pain, very severe in character. For the previous two days the temperature had been from 100° to 101° F., and the pulse had been

rapid. On the night before I saw her she collapsed, and her pulse was almost imperceptible. She was too weak to be removed to the hospital, and operation was imperative. A median incision was made, and the uterus found extending slightly above the pelvic brim. It was everywhere wedged in the pelvis and covered with dense adhesions. Over the surface of the tumor the omentum and several loops of small bowel had grown fast. To relieve the pain, we loosened up the intestinal loops and then closed the abdomen.

March 26, 1903: The uterus contained several myomata; both tubes were filled with pus and glued to the pelvic floor. On the left side was an ovarian abscess containing a considerable quantity of very fetid pus. Enucleation was commenced from the left side, and was found to be impracticable. The right side was gradually liberated, the uterus cut from right to left, and also pulled away. The walls of the abscess still remained, and there was considerable bleeding from the pelvic floor. A pelvic drain was carried down through the vagina.

Preparatory to closing the abdomen we carefully examined the omentum and found that it contained a mass about 10 cm. in diameter. The omentum was very hard, and the condition suggested a foreign body. In order that there might be as little escape of pus as possible we incised the left rectus, continuing the incision five inches to the left. The omentum was tied off and removed. The thickening was found to be due to an isolated omental abscess (Fig. 380). At one point the abscess reached the peritoneum, and here, over an area 1 x 2.5 cm., the surface had become necrotic. The patient made a very satisfactory recovery.

There are other cases in which the operator, once he has commenced the operation, from the character of the condition, is forced to complete it, not being able to abandon it at any stage. One patient came with a large umbilical hernia, densely adherent omentum, and a large myomatous uterus filling the greater part of the abdomen, and associated with a large ovarian abscess communicating with the bowel. This is a typical example of such a group of cases. This patient was, fortunately, in good condition, and made an excellent recovery. In many of these cases, however, the surgeon is in a quandary as to what should be done, realizing, on the one hand, that the patient is continually losing ground, and, on the other, that operation is fraught with great danger. As a rule, the operation offers the only possibility of relief.

Gyn. No. 5123.*

Umbilical hernia; multinodular myomatous uterus; large ovarian abscess communicating with the small bowel; hysterectomy; recovery. (Fig. 381.)

R. L., colored, aged forty. Admitted March 23, 1897. The patient had first noticed a tumor ten years before. At times she had had a great deal of abdominal pain, and on one occasion had been confined to bed for three months.

* Thomas S. Cullen, Johns Hopkins Hosp. Bull., 8, 1897, vol. viii, p. 217.

On account of the irregular hernial protrusion the abdominal incision was commenced at a point midway between the xiphoid and the umbilicus, and continued downward to within a short distance of the pubes, the hernial sac being encircled and removed. At the umbilicus the omentum was firmly adherent. Presenting at the incision were several subperitoneal myomata. To these the omentum was also firmly adherent. After these adhesions had been loosened up the nodular myomatous uterus, 21 x 28 cm., was delivered (Fig. 381).

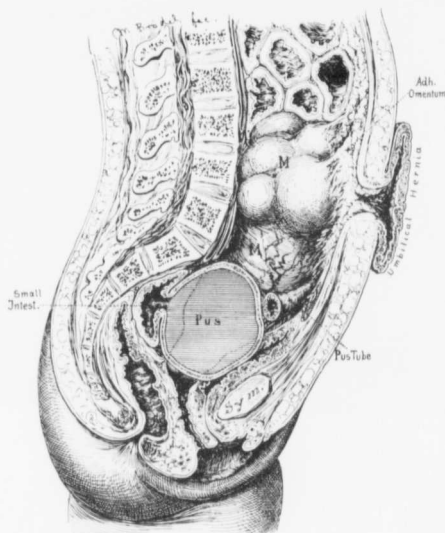


FIG. 381.—A LONGITUDINAL SECTION OF THE ABDOMEN SHOWING AN UMBILICAL HERNIA, A LARGE, DENSELY ADHERENT MYOMATOUS UTERUS, AND AN OVARIAN ABSCESS.

Gyb. No. 5123. The section shows, from above downward, an umbilical hernia, a large multinodular myomatous uterus, on the upper and anterior surface of which the omentum is adherent, a pus-tube, and an unusually large ovarian abscess, which communicated with a loop of small intestine. The abscess was more on the right side of the body, but has been drawn on the same level to bring it out more clearly. (After Thomas S. Cullen.)

Occupying the posterior part of the pelvic cavity was an elastic tumor, 17 cm. in diameter. This looked like an ovarian cyst, and was intimately adherent to two loops of the small intestine. During an attempt to shell off the outer layers of the cyst, leaving them attached to the intestine, the cyst ruptured and was found to contain about 900 c.c. of grayish, fetid pus. After removal of the uterus the ovarian abscess was freed; it was necessary, however, to leave a small part of the sac attached to the intestine, and on careful examination an opening,

1 cm. in diameter, was found between the intestine and the abscess sac. The margins of the intestinal opening were almost as dense as cartilage, but very friable. After a good deal of dissection it was possible to turn in the edges, and the opening was closed with fine silk sutures. These were now supported with a second and a third row. The abdomen was closed without drainage, and the patient made a good recovery.

The Gradual Absorption of Adhesions after Abdominal Sections.—The mere opening of the abdomen is in some cases followed by partial absorption of dense adhesions. Case W. affords a striking example of such an amelioration of the condition. On opening the abdomen we found dense adhesions everywhere, and the operation had to be abandoned at once on account of the patient's precarious state. She gradually improved, and on several occasions, in the course of the next few months, she was brought to the operating-room, but each time to no avail. Finally we were able to open the abdomen, and were greatly surprised to note how the tumor had loosened up. Hysterectomy was performed, and the patient was well several years after. In this case she would certainly have succumbed on the table had we attempted a radical operation when the abdomen was first opened.

A. W. Path. No. 8932.

Successful hysterectomy after several unsuccessful attempts.

A. W., aged forty-five, colored, seen in consultation with Dr. Brice Goldsborough, at the Cambridge, Md., Hospital, May 24, 1905. For four years her physician had been endeavoring to have her submit to an operation for a large myoma, but she had persistently refused. When I saw her there was a great deal of abdominal distention; her pulse was weak and rapid. The history was strongly indicative of an accompanying peritonitis.

On opening the abdomen we found what appeared to be a lobulated myoma, everywhere adherent to the abdominal wall and also in the pelvis. The tumor bled on the slightest touch. As her condition was desperate, we thought it wiser to close the abdomen, hoping that at a later day we might remove the uterus.

On several subsequent occasions she was brought to the operating-room, but as soon as the anesthetic was started her pulse would run up to between 120 and 150, and become very weak. Finally, on August 17, 1905, she was again brought to the operating-room. Since the previous operation she had improved markedly, and the tumor showed much mobility. On opening the abdomen we found we were dealing with a multinodular myomatous uterus; one large nodule, fully 14 cm. in diameter, presented at the incision, and was adherent to the abdominal wall. It was shelled out, clamped, and removed. A second nodule appeared on the left side. It was treated in a similar manner, and a third was removed from the pelvis. During liberation of the first large tumor we encountered

an abscess which lay along the edge of and in a cleft of the tumor. The left tube contained a quantity of milky pus. We amputated through the cervix, removing the entire growth. The pelvis was drained, and the patient made a slow but uninterrupted recovery, and in the course of a few months was able to resume her work.

The histologic examination showed that the abscess cavity noted in the cleft of the large myoma was lined with typical granulation tissue.

February 20, 1907. The patient's condition is excellent.

CHAPTER XXXIII.

‘ PREGNANCY AND UTERINE MYOMATA.

In the chapter on abdominal myomectomy we have considered those cases in which a myomectomy was performed during the course of pregnancy, and on p. 528 we have given data relative to the number of pregnancies or miscarriages the patients had had before being operated upon.

In five other cases we encountered myomata and pregnancy at operation. In Case C. H. I., 620, the woman was thirty-five years old, and during fifteen

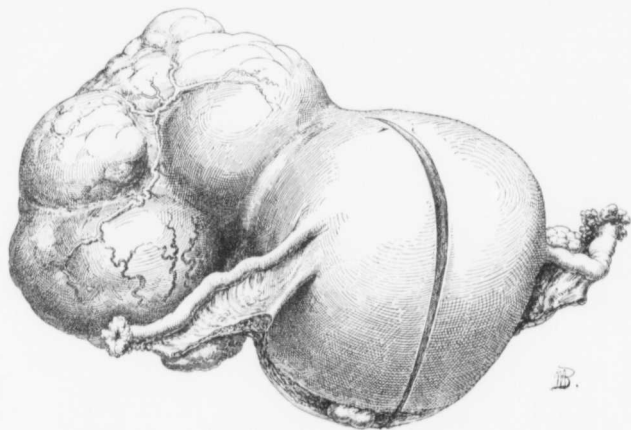


FIG. 382.—A LARGE PEDUNCULATED SUBPERITONEAL MYOMA COMPLICATING PREGNANCY. (4 nat. size.)

Path. No. 740. (Specimen sent by the late Dr. Stansbury Sutton, of Pittsburg.) The uterus measures 9.5 x 11 x 12 cm., the increase in size being due to the pregnancy. The tubes and ovaries are normal. Attached to the posterior surface of the uterus by a very broad base is a markedly nodular myomatous mass, which measures 9 x 11 x 12 cm. For the interior of the uterus see Fig. 383.

years of married life had never been pregnant, but had missed her last two periods. For months she had been aware of a nodular growth in the lower abdomen. When the abdomen was opened, a large subperitoneal nodule was noted. The uterus was slightly enlarged and rather soft, so that a pregnancy was suspected. As the cervix, however, was very hard, and as the patient had remained sterile throughout fifteen years of her married life, we excluded

a pregnancy and performed a hysterectomy. As will be seen from the accompanying history, the uterus contained a small fetus.

In Case 6508 the pregnancy was recognized clinically, and an attempt was made to remove the large myomata without disturbing gestation. The bleeding was so alarming, however, that complete removal of the uterus was deemed necessary in order to save the patient's life.

In Case 12902 a widow, forty-four years of age, gave a history of having missed her period five months before admission and of some distention of the abdomen. A large multinodular uterus was detected, and the breasts were full of colostrum. After carefully weighing the condition, the operator decided to remove the uterus,



FIG. 383.—A NORMAL PREGNANCY ASSOCIATED WITH A LARGE SUPERFICIAL MYOMA. ($\frac{1}{2}$ NAT. SIZE.)

Path. No. 740. (Specimen sent by the late Dr. R. Stansbury Sutton.) The picture represents the uterus in Fig. 382 after being opened. The uterine walls appear normal. The placental attachment presents the usual appearance, and the fetus, which measures 6.5 cm. in length in its doubled-up position, is perfectly normal.

The myoma did not appear in any way to be impeding the growth of the fetus. The only suspicion of a myoma was furnished by a small subperitoneal nodule on the left.

feeling that, from the position of the tumors, delivery of a normal child would be impossible.

The pathologic report shows that the largest myoma was 12 cm. in diameter, and that there were also several submucous nodules.

Fig. 386 shows the enlarged uterus in Case 12587. The patient had missed two periods, but on admission the breasts contained no colostrum, and there was a brownish vaginal discharge. The cervix was larger than normal, but firm. Hysterectomy was performed, but when the uterus was opened a small fetus was found. In this case a continuation of the pregnancy would hardly have been possible.

In Case 2434 the patient was over seven months pregnant. In the fundus were several myomata, and blocking the pelvis was a cervical myoma, 10 cm. in diameter. The patient complained of constant pain in the lower abdomen. Normal labor was out of the question. The pregnancy was allowed to advance as far as possible, and Cesarean section, followed by supravaginal hysterectomy,

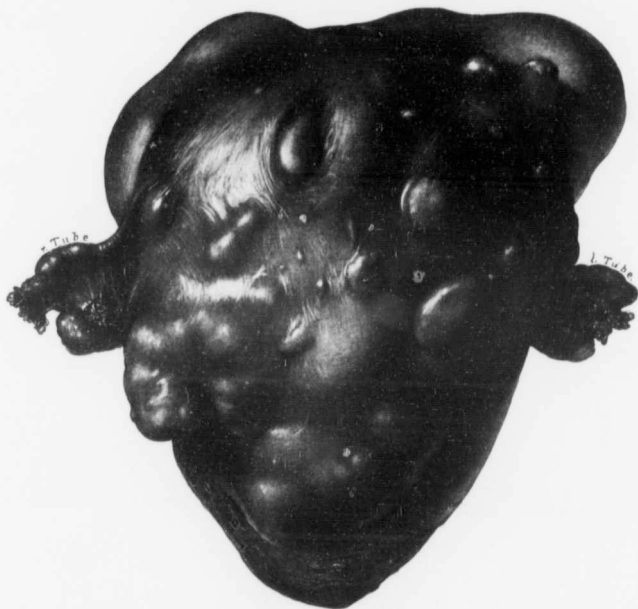


FIG. 384.—A PREGNANT MULTINODULAR MYOMATOUS UTERUS. ($\frac{1}{2}$ nat. size.)

Path. No. 8325. (Specimen sent by Dr. George Ben Johnston, of Richmond, Va.) This pear-shaped uterus measured 16 x 16 x 25 cm. Scattered over its entire surface are large and small subperitoneal myomata. The appendages on both sides are normal, but the left tube is inserted on a higher level than is that on the right. For the appearance of the interior of the uterus see Fig. 385.

was performed. The mother made a good recovery, but the child died suddenly without apparent cause twenty hours after operation.

The specimen shown in Figs. 382 and 383 was sent to us by the late Dr. R. Stansbury Sutton, of Pittsburg, Pa.; and that in Figs. 384 and 385 by Dr. George Ben Johnston, of Richmond, Va.

Changes in the Myomatous Uterus Due to Pregnancy.—GROSS CHANGES.

—The cervix is usually much softer, but in some of our cases it was very hard.

On opening the abdomen one is instantly impressed by the marked increase in vascularity, as noted in Case 6508, in which, on account of the alarming bleeding, myomectomy had to be abandoned and hysterectomy performed. The tremendously increased blood-supply may give the uterus a dark, purplish-red color, as was seen in Case 12587.

Whether the pregnancy is in any way mechanically interfered with will depend, of course, on the position of the tumors. In Fig. 382 we see an enlarged pregnant uterus, with a broad-based, lobulated, subperitoneal myoma attached to its posterior surface. From Fig. 383 we see, however, that the tumor in no way had encroached upon the uterine cavity, and the development of the child was proceeding normally.

Fig. 384 shows a uterus fairly riddled with myomata, small and large nodules projecting forward from the surface. The interior of this uterus, as seen in Fig. 385, shows that there were also interstitial and submucous myomata, and that, where the myomata were submucous, the placenta was atrophic or missing. Nevertheless, pregnancy was proceeding in an orderly fashion.

Fig. 386, from Case 12587, shows a dense, multinodular uterus, with one small submucous myoma and an early pregnancy. A full-term pregnancy was almost out of the question in this case, and the premonitory signs of miscarriage were already present. If the child had become viable, the cervical myoma (a) would have prevented delivery by the normal channel.

Nature has, however, the happy faculty of sometimes accomplishing what seems most improbable. Case 7549 affords a brilliant example. Seven weeks after a normal labor a large, densely adherent myomatous uterus was removed. Filling up the entire uterine cavity was a sloughing submucous myoma, 9 x 15 cm. This case is illustrated on p. 65.

Histologic Changes.—The individual muscle-fibers are considerably swollen, and the nuclei are usually more vesicular. They may, however, stain more deeply and be irregular in outline, as was noted in Case 12587.

In addition to the changes in the muscle-fibers, there is usually swelling of the stroma cells between the muscle-bundles.

Hyaline areas in the myomata seem to show an increased tendency to melt away when associated with pregnancy. This is strikingly seen in Fig. 84 (p. 106).

Disappearance of Myomata after Pregnancy.—It is claimed that in a few instances myomata that were clearly palpable before and during pregnancy disappeared shortly after labor. We have never seen any evidence supporting this view, but our experience with pregnancy associated with myomata has been too limited to enable us to speak with any degree of certainty on this point.

FIG. 385.—PREGNANCY IN A MULTINODULAR MYOMATOUS UTERUS.

Path. No. 8325. (Specimen sent by Dr. George Ben Johnston, of Richmond, Va.) For the appearance of the intact uterus see Fig. 384. Scattered throughout the walls are interstitial and submucous myomata. The fetus looks normal, and from the head to the buttocks measures 16 cm. in length. Where the myomata project into the uterine cavity the placenta is very thin or entirely wanting. This is particularly well seen at a and a'.

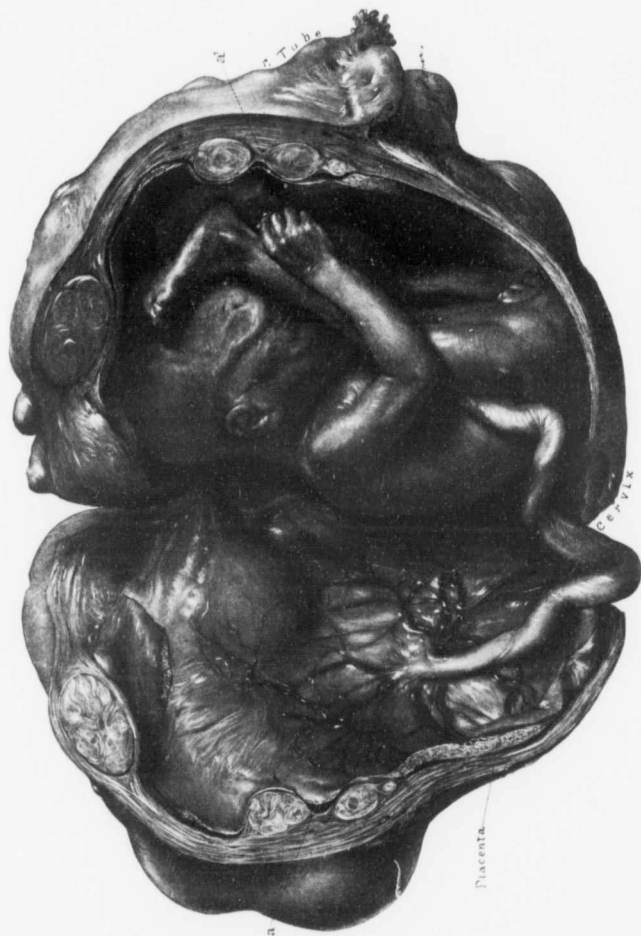

FIG. 385.

MYOMATA ASSOCIATED WITH PREGNANCY.

Gyn. No. 6508.

Early Pregnancy in a Myomatous Uterus: Myomectomy was attempted, but Hysterectomy had to be performed on account of the alarming hemorrhage.

A. C., married, aged thirty-four, white. Admitted November 14; discharged December 20, 1898. There has been no flow for the last six weeks. The entire right side of the abdomen is on a higher level than the left.

Examination under Ether.—An irregular tumor, approximately 11 x 12 cm., is felt low down on the right side of the abdomen. The mass is very hard, and appears to be made up of a number of superficial bosses with shallow sulci between them. The tumor is freely movable, and can easily be pushed over to the left side. On vaginal examination the outlet is found to be slightly relaxed. The cervix is well back, is soft and flabby, and instantly suggests pregnancy. In the anterior fornix is a small, hard nodule. The uterus itself apparently contains a three or four months' pregnancy. Operation, hysteromyomectomy.

On section of the abdomen, the fundus is found to be dark purple in color, much enlarged, and traversed by greatly distended vessels. Springing from the upper anterior surface of the fundus is a pedunculated myoma, about 12 cm. in diameter. Projecting from the anterior surface of the uterus is a smaller myoma, about 8 cm. in diameter. Myomectomy was decided upon, and the small myoma was removed through a circular incision. Removal was instantly followed by a profuse hemorrhage, which was at once controlled by grasping the incision with the fingers. Attempts were made to control the bleeding with sutures; but there was much oozing from the needle punctures. Bleeding points were grasped with artery forceps, but a broad, deep sinus was opened, and a terrific hemorrhage followed. The uterine muscle tore wherever the forceps were applied. It was found that the only hope of saving the patient was to remove the uterus. An assistant grasped the cervix tightly with his hand, and thus controlled the bleeding. The uterus was removed in the usual manner. The patient made a satisfactory recovery.

Gyn. No. 12587. Path. No. 9348.

Hysteromyomectomy. The Uterus Contained a Two Months' Fetus (Fig. 386). Death on the Fifth Day, from Bronchopneumonia.

S. J., married, aged thirty-nine. Admitted December 30, 1905; died January 7, 1906.

For the last year and a half the periods have been increasing in length, sometimes lasting thirteen days. Seven months ago a tumor was noticed in the lower abdomen. Her last period was two months before admission, but two

weeks ago there was a bloody discharge for two or three days. For the last two weeks she has been losing her appetite, and has had some nausea and vomiting. She has been forced to remain in bed for the last ten days. The breasts contain no colostrum. The lower part of the abdomen, as far as the umbilicus, is filled with a firm, nodular mass. A brownish, mucous discharge escapes from the vagina. The cervix is larger than normal and is firm. The history is suggestive of pregnancy with myoma, but the examination is not conclusive.

Operation.—On section of the abdomen a dark, purplish-red, myomatous uterus was encountered. The uterus was boggy and suggested pregnancy. The vessels of the ovarian ligaments were greatly distended.

Hysterectomy was carried out in the usual manner, the uterus being amputated through the cervix.

The operation was a very difficult one. The patient left the table in a poor condition. On the following day her leukocytes were 30,600; the temperature was 102.6° F. She developed a pneumonia and died on the fifth day.

The autopsy showed, however, that a general peritonitis was the immediate cause of death. There was an acute fibrinous pelvic peritonitis; thrombosis of the uterine and vesical veins, thromboses in the pulmonary arteries, pulmonary abscesses, bronchopneumonia, acute bronchiectasis and bronchitis, acute fibrinous pleuritis, acute diphtheric colitis, cloudy swelling of the viscera.

Path. No. 9348. The uterus (Fig. 386) measures 16 x 13 x 14 cm., and is markedly nodular. Covering the posterior surface are many adhesions, and springing from the fundus is a sessile, mulberry-shaped nodule, 4 x 5 cm. There are also numerous other nodules springing from the anterior and posterior walls. Scattered throughout the uterus are nodules of various sizes. The uterine cavity contains a small fetus, which lies just beneath the small submucous myoma (*d*). The myoma projects a short distance into the sac.

Histologically, the uterine mucosa presents the typical picture of pregnancy. Over the submucous nodule, which projected into the uterine cavity, there is considerable decidual formation, but no glands. It is interesting to see the swelling of the muscle-fibers and the stroma cells between the muscle-bundles.

In this case signs of miscarriage had already appeared, and had the child come to term, the myoma (*a*), as seen in Fig. 386, would have prevented delivery through the natural passages.

Gyn. No. 12902. Path. No. 9840.

A Multinodular Myomatous Uterus Containing a Pregnancy Between Two and Three Months.

I. L. P., white, widow, aged forty-four. Admitted May 5; discharged May 27, 1906.

The patient has had no menstrual disturbance until a few months ago, when the flow began to increase. Four months ago the periods ceased, and it was thought the menopause was coming on. During the last five months the abdomen

has rapidly increased in size. She experienced no pain until a month ago, when she was confined to bed for ten days. The pain was "jumping and gnawing" in character. The breasts were large and full of colostrum. On examination under ether the tumor is found to extend two inches above the umbilicus, and on the left side reaches the umbilicus. There is some blueness of the mucosa. The cervix is firm, the os slightly patulous. The fundus cannot be made out distinctly, but it appears to be continuous with the abdominal mass.

The history and the examination pointed to pregnancy at about the fourth month, but on account of the markedly myomatous condition of the uterus, it was thought that the patient would not be able to go to term.

Operation. On section of the abdomen the irregular and myomatous uterus showed at least fifteen myomata scattered over its surface. All the uterine vessels seemed dilated, and the body of the uterus was rather boggy. All the tissue was so vascular that even the smallest bleeding point had to be tied. The patient stood the operation well and made a good recovery.

Path. No. 9840. The uterus has been amputated through the cervix. It measures approximately 16 cm. in breadth, 24 cm. in length, and 13 cm. in its anteroposterior diameter. The great increase in size is due to the presence of many myomatous nodules, the largest of which is approximately 12 cm. in diameter and subperitoneal. There are also numerous small ones, some of which are submucous. The uterus contains a fetus which is between three and four months old.

Sections from the endometrium show typical decidua, and we have here and there in it areas of coagulation necrosis and infiltration with small round cells—an indication that a miscarriage would soon have occurred. The muscle-fibers in the myoma show a slight increase in size.

C. H. I. 620. Path. No. 8827.

An Early Pregnancy Discovered after Removal of the Uterus.

E. S., married, aged thirty-five, white. Admitted May 29; discharged June 24, 1905.

The patient had been married for fifteen years, but had never been thought to be pregnant. She had missed two periods, however, just before admission. Upon pelvic examination a myomatous uterus was diagnosed and an operation advised, as there had been a great deal of abdominal pain. On opening the abdomen we found what appeared to be a large myomatous nodule. The uterus was slightly enlarged and rather soft. We considered the possibility of preg-

FIG. 386.—AN EARLY PREGNANCY IN A MYOMATOUS UTERUS. (2 nat. size.)

Gyn. No. 12587. Path. No. 9348. The entire specimen measured 13 x 14 x 16 cm. There are numerous subperitoneal and interstitial myomata. The specimen has been opened from the front. a is a cervical myoma that would have certainly prevented a normal labor; b is a shaggy placental covering of the fetal sac; c, a blood-clot; d is a small submucous myoma that encroaches on the embryonic sac; e is the thickened uterine mucosa.

In the right lower corner is a sketch showing the relation of the submucous myoma to the amniotic sac.




FIG. 386.

nancy, but the cervix was very hard. The uterus was removed, and the patient speedily recovered.

Path. No. 8827. The specimen consists of a myomatous uterus, amputated through the cervix. The uterus contains a small fetus, 1.5 cm. in length. The uterus itself is nodular, and is 16.5 cm. broad, 8 cm. in length, and 8.5 cm. in its anteroposterior diameter. The largest myoma is approximately 11 cm. in diameter, and there is a diffuse myomatous thickening in the other portions of the wall.

Sections from the endometrium show the typical picture of pregnancy. The muscle-fibers, particularly beneath the mucosa, show some thickening.

Sections from the myoma show typical and wide-spread hyaline degeneration, only a few fibers remaining here and there. The interspaces are divided by a substance that is granular (Fig. 84, p. 106). In places it stains slightly, at other points, deeply, the intensity of the stain indicating the density of the fluid filling the spaces.

Diagnosis: interstitial uterine myomata, complicated by a pregnancy of between two and three months.

Gyn. No. 2434. Path. No. 186.

Pregnancy in a Myomatous Uterus. Cesarean Section followed by Supravaginal Hysterectomy.

Mrs. D. S., aged thirty-six, white, admitted November 28, 1893; discharged April 2, 1894. The patient had had one child and one miscarriage. Fetal movements were first noticed on October 16th. The patient was not positive when the menses had ceased. She complained of constant pain in the lower abdomen. After waiting nearly two months, Cesarean section was performed, as a large cervical myoma, 10 x 8 x 8 cm., choked the pelvis. After delivery of the child the uterus was amputated at the cervix. The patient made an uninterrupted convalescence. The child died twenty-four hours after operation, without any apparent cause.

Path. No. 186. The contracted uterus is 16 x 16 x 13 cm. In addition to the large cervical myoma there are several others scattered throughout the uterine walls. The largest of these is 5 cm. in diameter. Apart from the numerous myomata the uterus presented the usual appearance.

After studying the histories the reader may feel that poor surgical judgment was shown in some of the cases. In one case the myomatous uterus reached large proportions, and in the cervix was a myoma that would have effectually blocked normal delivery. In other cases there were already premonitory signs of miscarriage. It is easy to look back and see where improvements might have been made. In some instances it is difficult accurately to determine the condition until the abdomen is opened. With the exact condition before him the operator, on the one hand, wishes to be conservative and not interfere with

gestation, but, on the other hand, he realizes that there is a peculiar proneness for these patients to miscarry, and he also knows that if submucous myomata exist, they are liable to become infected. Furthermore, he cannot lose sight of the fact that, if radical procedures are deferred, in the near future it will become necessary to again subject the patient to an abdominal operation. In one or two of our cases it would have been wiser had we watched the patient, for a few months at least.

The aim in each case should be to effect a normal delivery at term, if that be possible, after which, if it be deemed necessary, the myomata or the uterus can be removed.

Recently Bland-Sutton has drawn attention to what he terms red degeneration of myomata occurring during pregnancy. Our experience with myomata in pregnancy has been so limited that we have had little opportunity of studying this form of degeneration.

CHAPTER XXXIV.

COMPLICATIONS FOLLOWING ABDOMINAL HYSTEROMYOMECTOMY.

Hemorrhage.—Secondary hemorrhage after abdominal hysterectomy has, fortunately, been comparatively rare in our series. In recent years we have made it a rule to tie all the cardinal vessels twice, so that if, by any chance, one ligature is not tight enough, the second will effectually prevent bleeding.

In Case 3997 a densely adherent myomatous uterus, 18 x 8 x 10 cm., was removed through the abdomen. After operation the pulse became very weak and rapid. Hemorrhage was suspected, although no other signs of bleeding were noted. The abdomen was reopened twenty-four hours after the operation, and a large quantity of free and clotted blood was found. The bleeding was from the left ovarian artery. This was tied securely. At the end of the operation the pulse was 160. A liter of saline solution was introduced under the breast. The patient was discharged well.

In Case 7330 the multinodular uterus extended half-way to the umbilicus. One of the nodules had encroached markedly on the anterior vaginal wall. On the tenth day a hematoma was detected, which lay in front of the cervix and filled both broad ligaments as far as the pelvic brim. Through a vaginal opening the clot was removed and the cavity lightly packed. The patient was discharged well on the twenty-seventh day. In this case the bleeding was in all probability due to a continuous ooze from small vessels, and did not come from an artery or vein of any appreciable size.

In Case 9736 a boggy, adherent, myomatous uterus was removed, together with the adherent appendages. The abdominal wound broke down. In the pelvis was an accumulation of blood, and in both broad ligaments, clots. The thickening was more marked on the right side. Vaginal section was done, the pelvis drained, and the clots were removed. Rapid recovery followed. In this case also the bleeding was apparently due to oozing rather than to any free hemorrhage.

In Case 3977 the catgut ligature controlling the left uterine artery absorbed too rapidly, and the patient died from hemorrhage on the eighth day. This case is described in detail on p. 681.

Symptoms Suggesting Hemorrhage.—In Case 3492 hysteromyomectomy was done and the patient had a sudden fainting spell on the nineteenth day; the pulse rose to 130, the respirations became rapid, the hands were clammy, and she presented the picture of hemorrhage. The abdomen was opened with negative results. The case was later supposed to be one of pulmonary embolism. It is reported in detail on p. 669.

In such cases as this it is usually much better to explore the abdomen at once. Naturally, the already existing depression is intensified to some extent by the anesthetic and the exploration, but through a very small opening one can at once determine whether the abdomen contains free blood or not. If there is hemorrhage and prompt action is deferred, the patient may be too weak to stand any operation when the diagnosis becomes certain. Where there are definite signs of hemorrhage, the abdomen should be opened at once.

Elevation of Temperature.—In reading the postoperative histories of patients from whom a myomatous uterus had been removed through the abdomen, we have often been surprised to see it stated that the patient had absolutely no elevation of temperature. This has not been our experience. From the accompanying tabulation of 100 uncomplicated abdominal hysteromyomectomies, taken in their regular sequence, it will be seen that in only 15 per cent. did the temperature remain below 100° F. In over half of the cases it at one time reached some point between 100.2° and 101° F., and in five cases it was over 102° F.

From the statistics, as frequently published, the operator would be alarmed if the temperature reached 101° F., but, as seen from the table, it is of common occurrence, and in the absence of complications should occasion little uneasiness.

TABLE SHOWING MAXIMUM TEMPERATURE IN 100 CASES AFTER AN UNCOMPLICATED HYSTEROMYOMECTOMY.

99	to 100	in	15 per cent.	of the cases
100.2	to 101	in	61 per cent.	" " "
101.2	to 102	in	19 per cent.	" " "
102.2	to 103.8	in	5 per cent.	" " "
—				
100 per cent. " " "				

The maximum temperature usually occurs within four days after operation. It was present on the second day in 52 per cent. of the cases, as seen from the second table.

DAY OF MAXIMUM POSTOPERATIVE TEMPERATURE.

First	day after operation	in	15 per cent.	of the cases.
Second	" "	" "	52 per cent.	" " "
Third	" "	" "	15 per cent.	" " "
Fourth	" "	" "	4 per cent.	" " "
Fifth	" "	" "	6 per cent.	" " "
Sixth	" "	" "	3 per cent.	" " "
Seventh	" "	" "	2 per cent.	" " "
Eighth	" "	" "	2 per cent.	" " "
Ninth	" "	" "	1 per cent.	" " "
—				
Total.....100 per cent. " " "				

Hot Weather as a Cause of Postoperative Elevation of Temperature. We have occasionally noted an unusual postoperative rise of temperature in patients operated upon in excessively warm weather.

Whether this rise is dependent upon the atmospheric condition or not it is impossible to say, but the repeated coexistence of these two phenomena strongly suggests that hot weather predisposes to a postoperative elevation of temperature.

Pulse.—With the elevation of temperature that usually follows an abdominal hysteromyomectomy, there is naturally an acceleration in the pulse-rate.

RANGE OF THE MAXIMUM POSTOPERATIVE PULSE-RATE IN 100 SIMPLE AND SUCCESSFUL ABDOMINAL HYSTEROMYOMECTOMIES.

90 to 100	in 32 per cent. of the cases
102 " 120	" 55 per cent. " " "
122 " 130	" 7 per cent. " " "
132 " 140	" 6 per cent. " " "
<hr/>	
Total100 per cent. " " "

In nearly 68 per cent. the pulse reached 102 or over shortly after operation. The table giving the day of most rapid pulse-rate shows that it occurred most frequently on the second and third days after operation.

DAY OF MAXIMUM POSTOPERATIVE PULSE-RATE.

First	day after operation in 13 per cent. of the cases.
Second	" " " 41 per cent. " " "
Third	" " " 26 per cent. " " "
Fourth	" " " 11 per cent. " " "
Fifth	" " " 5 per cent. " " "
Sixth	" " " 1 per cent. " " "
Seventh	" " " 1 per cent. " " "
Eighth	" " " 1 per cent. " " "
Eleventh	" " " 1 per cent. " " "
<hr/>	
Total100 per cent. " " "

A Rapid Pulse.—When the myoma has been complicated by pus-tubes or a pelvic abscess, it is perfectly natural that the pulse-rate should be rapid not only during, but also after, operation. A quickened pulse is likewise usually noted when peritonitis is developing.

In Case 8495 the patient had palpitation of the heart and shortness of breath, associated with, and probably dependent on, an enlarged thyroid. Spinal cocain anesthesia was employed, and the abdomen opened. The pain was so severe that ether had to be substituted. Hysterectomy was then performed. On leaving the table the patient had a very rapid pulse and rapid and shallow respirations. The pulse varied from 180 to 200 for the first twenty-four hours, and then gradually became slower.

It is difficult to determine whether the spinal anesthesia, the goiter, or both were in any way responsible for the rapid pulse.

These figures will naturally vary somewhat in different clinics, but it is readily seen that, even in the simple uncomplicated abdominal hysteromyomectomies, there is usually a definite rise of temperature and pulse at some period during the convalescence.

Postoperative Retention.—Retention of urine following the average hysteromyomectomy has not been very common in our experience. Where the bladder has been drawn high up on the surface of the tumor, it may be several days before it regains its normal power of contractility, and temporary retention may occur. When the bladder-walls are greatly hypertrophied, retention may occur, as was noted in Case 3445.

As a result of the removal of the uterus, the position of the bladder is naturally altered, and this tends to produce retention for a short period. Supravaginal hysterectomy causes much less alteration in the location of the bladder than does a panhysterectomy, and hence the tardy vesical evacuation is less frequent after the supravaginal operation.

When the patient finds it very difficult to void, a hot-water bag may be applied over the bladder, and hot douches given. Contractions of the bladder may also be favored by making the patient sit up, if it is deemed safe. Catheterization should be avoided whenever possible.

Partial Suppression of Urine.—In Case 7240 a large myomatous uterus was removed from a white woman aged thirty-eight. Prior to operation she had had frequent and profuse uterine hemorrhages. She had a mitral stenosis, with an accompanying hypertrophy. Her hemoglobin was 60 per cent. She did well until the tenth day, when slight dyspnea was noted. There was some edema of the face and legs, and a rapid pulse. During the twenty-four hours she voided only 300 c.c. The cardiac dulness had increased, and the heart's action resembled the fetal type. Digitalis and Epsom salts were administered, and the patient drank freely of cream of tartar water. She was discharged on the twenty-fifth day in excellent condition.

The partial suppression was undoubtedly secondary to the cardiac lesion.

Cystitis.—Inflammation of the bladder very frequently follows abdominal hysterectomy for carcinoma of the cervix. This is primarily due to the fact that it is impossible to perfectly sterilize the carcinomatous growth, and, secondly, because the extensive dissection not only necessitates free handling of the bladder, but often also the cutting off of a portion of the vesical blood-supply.

Where the myomatous uterus is removed supravaginally, the bladder is usually little disturbed, and provided there has been no previous abnormality in this viscus, no trouble follows. We have had relatively few cases of cystitis after hysteromyomectomy.

Nephritis.—We shall consider here only those cases in which recovery took place. Definite signs of renal insufficiency were noted in several of the patients who died of general peritonitis. These cases are discussed at length on p. 673.

In Case 4869, after removal of a large myomatous uterus, a trace of albumin and some hyaline casts were noted. The convalescence, however, was not in any way disturbed.

In Case 10194 the urine was normal before operation. After removal of a multinodular uterus, which reached the umbilicus, the urine contained a trace

of albumin, and some hyaline and granular casts. The temperature reached 102.5° F. twenty-four hours after operation, and on the eleventh day reached 103° F. The patient was discharged in good condition.

Case 7703, in which a severe postoperative nephritis was associated with a large bed-sore and acute mania, is reported in detail on p. 661.

Edema of the Legs.—In Case 7240 hysterectomy was performed for a very large cervical myoma, 16 x 17 x 18 cm. The patient was anemic, and the cardiac dullness was increased. The heart-sounds also suggested dilatation. The patient did well until the tenth day, when the pulse became weak, intermittent, and rapid. There was slight dyspnea, and some edema of the face and legs.

Tincture of digitalis and Epsom salts were administered, and cream of tartar water was given liberally. The patient improved rapidly and left the hospital twenty-five days after operation. The edema in this case was evidently due to the cardiac insufficiency.

Nausea and Vomiting.—Formerly nausea and vomiting were looked for after nearly all serious abdominal operations, but since the introduction of the drop method of administering ether, the giving of large quantities of water to the patient as soon as she desires it after operation, and the raising of the patient's head on pillows, thereby tending to carry the gastric contents downward instead of upward, our experience with nausea and vomiting has been remarkably diminished.

Some patients, however, show a peculiar tendency toward nausea and vomiting. In Case 2699, in which the operation was simple, the patient had almost constant nausea for forty-eight hours. In Case 2129 there was nausea for ten days, but only slight vomiting. In Case 2919 there were obstinate nausea and vomiting for the first six days.

Stereoraceous Vomiting.—Fecal vomiting is relatively common in cases of intestinal obstruction and in peritonitis, but not very often met with in patients that recover.

In Case 9971 the patient had carcinoma of the cervix and adenomyoma of the body of the uterus. For several days after the necessarily extensive hysterectomy she had excessive nausea, vomiting, and diarrhea, and also fecal vomiting. For the first ten days after operation her life hung in the balance, but after that the convalescence was rapid.

Stereoraceous material was washed from the stomach in Case 2598, several days after an abdominal myomectomy. This case is reported in detail on p. 548.

Dark-brown Vomitus.—In very ill patients small or large quantities of a dark-brown material are frequently ejected from the stomach. This fluid resembles coffee-grounds to a certain extent. The coloring is in part due to partly digested blood. Whenever such vomitus is noted, a grave prognosis should be given, as nearly all these patients die.

Case 7560, in which an abdominal myomectomy, and Case 5858, in which

an abdominal hysterectomy, had been performed afford typical examples; both patients died.

Intestinal Worms.—In two of our cases lumbricoid worms were detected after operation. In Case 7460 the myomatous uterus nearly filled the abdomen. Hysteromyomectomy was performed, and the patient made an uneventful recovery. On the eleventh day she passed a lumbricoid worm, 35 cm. long. Ten days later santonin was administered, with the result that a large number of round worms and many eggs came away.

The convalescence in Case 2706 was not quite so smooth. After a hysteromyomectomy the patient had persistent nausea and vomiting until the fourth day, when, after an *ascaris lumbricoides*, 14 cm. long, had been vomited, the nausea and vomiting ceased.

In 1894 Stavelly * gave an interesting account of the symptoms produced by lumbricoid worms after abdominal operations. He found that the most constant and alarming feature in such cases was a peculiarly persistent nausea and severe vomiting, accompanied by colicky pains, disturbed breathing, an anxious expression, palpitation of the heart, and a general feeling of malaise—a complex of symptoms quite different from the simple persistent nausea and discomfort frequently observed after anesthesia.

Occasionally, in our abdominal work, when we have detected worms at operation, they were squeezed between the fingers, later a cathartic was given, and the parasites usually came away dead and somewhat macerated.

Obstipation.—With the patient in the recumbent position it is often difficult to secure a proper evacuation. We usually rely on enemata for the first few days, followed later by some mild laxative. The tendency to obstinate constipation is especially noticeable in very stout individuals.

In some cases the tardy bowel evacuation amounts almost to intestinal obstruction. This was especially noticeable in Case 4172. If there are signs of obstruction, cathartics are contraindicated absolutely. A harmless but efficient laxative is castor oil. The safest plan is to rely entirely on enemata.

Rectal Tenesmus.—In Case 3320 the multinodular myomatous uterus extended above the umbilicus. For the first thirty-six hours after operation there were pronounced symptoms of shock, and the patient had marked rectal tenesmus.

Intestinal Obstruction.—For the fatal cases of obstruction following hysteromyomectomy see p. 677.

In Case 10969 the patient had noticed a small abdominal tumor for over thirty years before admission. At the time of operation the uterus reached to the umbilicus. On the sixth day after operation a loop of small bowel was brought out and opened on account of intestinal obstruction. An unsuccessful attempt was made to close this opening four days later. Finally, however, it

* Albert L. Stavelly, *Intestinal Worms as a Complication in Abdominal Surgery*, Johns Hopkins Hosp. Reports, 1894, vol. iii, p. 371.

was closed two months after operation, and the patient discharged perfectly well.

In Case 12439 the large multinodular uterus was adherent to the bowel in Douglas' cul-de-sac. During liberation of adhesions purulent accumulations in the appendages on both sides were opened up. The surrounding structures were walled off as carefully as possible, to minimize the danger of infection. During the operation just prior to closure of the abdomen the pelvis was drained through the vagina.

On the third day the patient vomited and hiccoughed a good deal. Her general condition was worse, and she had a spot of marked tenderness near the umbilicus. In the abdominal incision was a small amount of slightly blood-tinged turbid fluid. The intestines were moderately distended, and had lost their glistening appearance. A loop of distended small bowel was brought out, sutured to the abdominal wall, and opened several hours later. The fecal fistula persisted for over two months. Finally the patient was discharged in good condition.

Both of these patients would in all probability have died had not the enterostomy been done. In all cases in which there are definite signs of obstruction the safer procedure is to at once explore the abdomen and, if necessary, do an enterostomy.

Fistula in Ano.—In Case 7859, the patient, aged fifty-two, white, as a result of the excessive menstrual flow, had become very weak. Her hemoglobin was 30 per cent, and a soft systolic murmur was audible over the entire precordial region. A large multinodular and adherent myomatous uterus was removed. At the time of her discharge from the hospital her hemoglobin had risen to 59 per cent. One inch to the right of the anus was a small fistulous opening from which a dark grayish material was discharging. The surrounding tissues were indurated.

Cardiac Complications.—We shall include here only those cases in which recovery took place. As noted on p. 453, many of our patients have had a very low hemoglobin, and it is remarkable that so few manifested abnormal cardiac symptoms following operation.

In Case 7240 there was a grave anemia. The heart was enlarged, and a diastolic rumble was heard. A very difficult hysterectomy was performed. The patient did well until the eighth day, when she manifested a slight dyspnea. There was some edema of the face and legs, and a rapid and weak pulse. The area of heart dulness was considerably larger than on admission, but on auscultation no murmurs could be heard. The heart's action was rapid and approached the fetal type. She was given liquid diet, Epsom salts, cream of tartar water, and tincture of digitalis. She was discharged in excellent condition.

In Case 10164 what appeared to be a pseudo-angina developed on the sixteenth day. The pulse became rapid, small, and weak, and there was considerable precordial pain. The attack lasted only a few hours.

In Case 12764 an attack of syncope occurred on the third day. It was thought to be hysterical in character.

In Case 12696 fainting occurred on the second day during the removal of a pelvic drain.

Nervous Phenomena.—In a few of the cases the patients manifested marked mental depression or excessive nervousness prior to operation, but after removal of the uterus these phenomena usually disappeared. Marked nervous symptoms following hysteromyomectomy are rare. They are divisible into two main groups:

1. Nervous symptoms apparently dependent upon local causes.
2. Nervous symptoms without any definite assignable cause.

Nervous Symptoms Dependent upon Local Causes.—In Case 2070 a simple hysteromyomectomy was performed. The patient, a white woman, aged thirty-four, did well until the third day, when her pallor became more marked; the pulse rose to 130, and the temperature to 102.4° F. There were abdominal distention and restlessness. The patient was delirious and nauseated, but on the seventh day a decided improvement was noted, and she made a good recovery. In this case there was probably intestinal atony or a partial obstruction, with absorption from the stagnant intestinal contents.

Nervous Symptoms without any Assignable Cause.—On p. 547 it was noted that in Cases 2710, 7886, and 8259, marked hysterical manifestations developed after an abdominal myomectomy. In Cases 3449, 3535, and 3918 intense nervousness followed the abdominal hysteromyomectomy.

In Case 2806 the nervousness was so severe that it at times bordered on delirium.

Hallucinations.—In Case 11294, the patient, aged fifty, white, had a definite systolic murmur at the apex. As soon as the abdomen was opened, the condition became precarious, and a speedy hysterectomy was imperative. The patient lost a considerable amount of blood and was much shocked after operation.

On the fourth day she began to have hallucinations. These gradually increased in intensity until she became practically insane. Her temperature never rose above 100.5° F., and her general condition was good.

On the fourteenth day after operation she was transferred to the isolation ward. Eleven days later her mental condition was again clear, and she was discharged apparently well. Ten months later her physician reported that she was perfectly well.

This patient was naturally hysterical, exceedingly devout, hypersensitive, and petulant. The loss of mental control was in no way due to an intoxication, but must be attributed to a weak mental balance.

Acute Mania.—In Case 7703 an abdominal hysterectomy was performed for a myomatous uterus of moderate size. Prior to operation the patient, a white woman, aged twenty-nine, had had great difficulty in keeping her mind on the subject under consideration, and gave irrational answers.

After operation she complained a great deal and showed hysterical symptoms. On the sixth day restraint was necessary. Dr. Henry M. Hurd saw her in consultation and diagnosed acute mania. For some days after this she voided and defecated unconsciously, and as a result a very extensive bed-sore developed, notwithstanding all the precautions exercised. She also developed an intense nephritis. She was placed in a continuous bath, and gradually improved mentally and physically. During convalescence she fully appreciated her condition, and referred to the periods of excitement as "bad dreams." When discharged on the forty-fourth day, she seemed quite rational.

In this case also there was a lack of mental poise before operation. We have seen patients go violently insane after minor operations, such as perineal repair, and it is rather remarkable that we have encountered so few postoperative mental disturbances in such a large number of severe abdominal operations when the patient's reserve force is so fully taxed.

Suppuration of the Abdominal Wound.—Infection of the abdominal wall may be limited to a small area or may involve the entire length of the incision. In some cases it is superficial; in a few it involves the entire adipose tissue and extends to the fascia. It is more prone to occur in stout than in thin individuals.

In some cases, in addition to a myomatous uterus, there are pus-tubes or a pelvic abscess. In other instances a submucous myoma has commenced to ulcerate, or there is an endometritis. In all such cases there is a danger of infection of the abdominal wall from the already existing pelvic focus. To avoid such infection the abdominal incision is carefully protected with gauze, and the instruments that have been employed in the pelvis are discarded during the closure of the abdominal incision.

Breaking down of the incision is in some cases undoubtedly due to injury of the tissues by strong traction with the retractors, too small an abdominal incision having been made. Our experience coincides with that of other clinics in that we occasionally have an incision break down when we can find no adequate reason for the infection.

On p. 673 a case is reported in which, on the fifth day, the entire abdominal incision gave way and the omentum was exposed. The patient died a few hours later.

Bed-sore.—In Case 7703, after removal of the uterus, the patient developed acute mania on the sixth day and restraint was necessary. She subsequently voided and defecated unconsciously, and as a result an extensive bed-sore developed. She finally made a good recovery.

Pelvic Infection.—In Chapter XVIII it is recorded that in many of our cases the tubes and ovaries were the seat of an acute or chronic inflammation, and it is little wonder that, after a supravaginal hysterectomy, there should occasionally be a subsequent pelvic accumulation. In the greater number of these cases we guard against a subsequent pelvic abscess by draining through the vagina before closing the abdomen.

We shall here consider only those cases in which no evidence of a recent in-

fection was noted at the time of operation. In all these cases it is, of course, necessary to cut across the cervix, and if, perchance, the uterine cavity is infected, there is great danger that the cervical stump or the surrounding pelvic tissue will become implicated. Again, if a myoma extends far out in the broad ligament and impinges on the lower pelvic wall, it is at times difficult completely to obliterate the resultant cavity, and if there is any oozing into this cavity, the contents are prone to become infected. Such a condition existed in Case 5093, and it was subsequently necessary to drain the abscess through the vagina. In Case 5359 a myoma in the left broad ligament was shelled out: an abscess developed in the broad ligament and opened into the bladder. This case is described on p. 553.

CASES OF PELVIC INFECTION FOLLOWING ABDOMINAL HYSTEROMYOMECTOMY.

Gyn. No.		Highest Temp.			
3614	Diffuse myomatous thickening of uterine wall. Septic temperature.	101.0°	Inflammation of cervical stump.	Cervix dilated; 70 c.c. of pus escaped (Figs. 387 and 388).	Recovery.
4193	Large, densely adherent myomatous uterus. Septic temperature noted on twentieth day.	105.6°	Inflammatory exudate on right side of pelvis.	No operation.	Exudate gradually disappeared.
5093	Myomatous uterus size of a six months' pregnancy. Tumor spread out in left broad ligament. Mild septic temperature.	101.2°	Pelvic abscess.	Opened <i>per vaginam</i> on twenty-sixth day.	Patient perfectly well eleven years later.
6036	Uterus about 11 cm. in diameter. Cervical myoma shelled out. Septic temperature.	102.0°	Encysted pelvic peritonitis.	Opened <i>per vaginam</i> on fourteenth day.	Recovery.
6039	Uterus extended 3 cm. above umbilicus. Broad cervix.	103.5°	Inflammatory mass, 4.5 cm. in diameter, to left of cervix.	Opened <i>per vaginam</i> on fourteenth day.	Recovery.
7237	Densely adherent myomatous uterus. Adnexa unusually adherent.	103.6°	Abscess in cervical stump.	Cervix dilated; 90 c.c. of pus escaped through external os.	Recovery.
10555	Myomatous uterus; subperitoneal nodule 10 cm. Adhesions; slight tear in outer coat of rectum.	101.0°	On eighteenth day induration on right side of pelvis, extending from cervix to pelvic wall. Tenderness.	No operation.	Disappeared in ten days after frequent use of hot douches.
San. No. 1944	Myomatous uterus, 8 x 12 x 12 cm.	100.4°	Thickening around cervix for thirteen days.	No operation.	Recovery.

Treatment.—In some cases it is marvelous how the induration will literally fade away under frequent hot douches. This was well exemplified in Cases 4193 and 10555. From the surgeon's point of view these cases should be divided into two main groups:

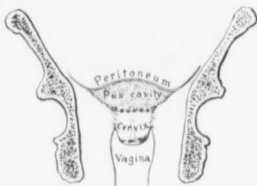

FIG. 387.—A PERULENT ACCUMULATION IN THE CERVICAL STUMP FOLLOWING SUPRAVAGINAL HYSTERECTOMY.

GYN. No. 3614. After supravaginal removal of an adherent myomatous uterus the patient had a temperature ranging from 100° to 101° for several days. On the fifteenth day the cervix was dilated (Fig. 388) and about 70 c.c. of pus escaped. The abscess developed between the cervical stump and the overlying pelvic peritoneum. (After Thomas S. Cullen.)

1. Infection limited to the cervix.
2. Infection involving the broad ligament or extending to Douglas' pouch.

Infection Limited to the Cervix.—If the area of induration is in the cervix and not marked in the broad ligament, it is probable that the infection has come from the cervical canal, as in Fig. 387. In such a case it is only necessary to carefully dilate the cervix and pus escapes (Fig. 388). This method was adopted in Cases 3614 and 7237.

Drainage of Douglas' pouch in either of these cases would have been of little or no value.*

Infection Involving the Broad Ligament or Douglas' Sac.—In these cases vaginal drainage, as described on p. 623, should be carried out.

Multiple Abscesses.—(Case H.) The patient was admitted to the Church Home and Infirmary in June, 1903. On opening the abdomen one of us (Cullen) found a globular myomatous uterus wedged in the pelvis. It was removed in the usual way from left to right, but with considerable difficulty on account of the dense adhesions and the thickened and adherent Fallopian tubes. At the time of operation the patient had a very bad vaginal discharge.

Shortly after operation the temperature rose, and on the eleventh day it reached 103° F. On pelvic examination a definite indurated mass, about 8 cm. in diameter, was felt on the left side. A small transverse incision was made through the vaginal mucosa, just behind the cervix, and blunt dissection continued upward and to the left with the finger. A blunt uterine dilator was in-

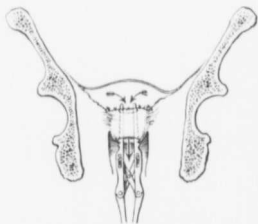


FIG. 388.—DILATING A CERVIX TO REMOVE AN ACCUMULATION OF PUS BETWEEN THE CERVICAL STUMP AND THE PELVIC PERITONEUM. (After Thomas S. Cullen.)

* **Infection Limited to the Cervix.**—In Case 1499, during convalescence the patient had several attacks of pain in the lower abdomen, with a rise in temperature. Following this there was a profuse discharge of pus from the vagina. There had evidently been a purulent accumulation in or near the cervical canal.

roduced, and a considerable amount of bloody fluid and pus escaped. During the afternoon there was a good deal of oozing, and when I returned to the city, after a few hours' absence, the pulse was 130 and the patient had lost a great deal of blood. She was immediately anesthetized. The oozing was found to come from the left side of the cervix, just at the normal site of the uterine vessels. It was impossible to check the bleeding without placing ligatures in very close proximity to the ureter. The abscess cavity was accordingly quickly packed with iodoform gauze which was sewn in place with catgut, the vaginal walls being drawn over it as far as possible. The pulse after operation varied from 150 to 160. Saline infusions and strychnin were employed. On the following day the pulse had dropped to 120 and was of good volume. A few days later an area of induration was noted just posterior to the anus. This gradually increased in size. The overlying skin, although pale, was somewhat edematous. An incision was made, and a pocket of pus containing at least 100 c.c. was found deep in the adipose tissue. The temperature steadily dropped after the abscess had been opened and soon became normal.

A few days later there was pain in the right forearm. The patient had frequently had rheumatism, and her husband, a physician, thought that the pain was similar to that she had previously experienced. We were, however, suspicious of an abscess. The temperature again rose. We made an incision in the right forearm and let out a considerable quantity of pus. Four years later the patient was in excellent condition. We had done our best prior to operation to check the offensive vaginal discharge, but had been unable to do so. The original infection noted in the pelvis at the time of operation and during the hysterectomy had evidently become disseminated.

Phlebitis.—In the accompanying table are the records of 27 cases of phlebitis following abdominal hysteromyomectomy. In 17 the left leg was involved; in 6, the right leg, and in 3 there was thrombosis on both sides. In one case the records are not clear.

In some cases only the saphenous vein was implicated; in others there was definite thrombosis in the femoral vein.

In Case 4955 the myomatous uterus was densely adherent. During convalescence the abdominal incision broke down almost completely, and on the sixteenth day a very severe phlebitis developed in both legs. The patient finally made a good recovery.

In Case 12154 the myomatous uterus extended above the umbilicus and was very adherent. Phlebitis developed in the left leg on the ninth day; in the right on the twenty-third day. The patient made a good recovery.

In two of these cases thrombosis had been noted prior to operation.

In Case 7569 a phlebitis had developed in the left leg after the birth of the second child. During convalescence, after removal of a small myomatous uterus and the repair of a left ureterovaginal fistula, phlebitis developed in the right leg.

In Case 12199 an ovarian tumor had been removed eight years before admission, and during convalescence there had been thrombosis of both femoral veins. After the removal, by abdominal section, of a myomatous uterus the size of that of a four months' pregnancy, thrombosis in both femoral veins again developed.

PHLEBITIS FOLLOWING HYSTEROMYOMECTOMY.

CASE NO.	SIZE OF UTERUS.	HEMOGLOBIN.	DAY AFTER OPERATION.	VEIN THROMBOSIS.	REMARKS.
1666	Nearly filled abdomen.		16th	Left saphenous vein.	Swelling of glands in groin. Edema of foot and leg.
2098	Abdomen half filled.	Anemic.	22d	In left leg and thigh.	Pus in uterine cavity at operation; evidently slight infection after operation. Temperature 99.6° to 103.6°.
3445	Large.	Very anemic.	10th	In left leg.	Very difficult operation.
4369	Reached umbilicus.		16th	Left saphenous.	
4372			10th	In left leg.	
4617			Reached umbilicus.		
4902		Filled large part of abdomen.	15th	Right femoral vein.	Pleurisy on right side during convalescence.
4903	Filled two-thirds of abdomen.		11th	In right leg.	
4955	Moderate size, densely adherent.		16th	Severe in both legs.	Abdominal incision broke down almost completely.
5766	Size of six and one-half months' pregnancy.		20th	Left internal saphenous.	
6372	Fills pelvis.			Slight phlebitis in left groin, thigh, leg, and foot.	
6915	Size of eight months' pregnancy.		23d	In left leg.	Desperate operation.
7569	Small. (Adenomyoma.)			In right leg.	Had had phlebitis in left leg after birth of second child.
8321	Fills pelvis.		14th	Slight swelling in lower right leg.	
10199	(Small pelvic myoma.)	95 per cent.	8th	Left saphenous.	Temperature rose to 102° on twelfth day.
10211	Contained myoma about 7 cm. in diameter.	70 per cent.	10th	Right saphenous.	
10229	Reached umbilicus.	75 per cent.	22d	Right saphenous.	
10281	Half-way to umbilicus.	77 per cent.	10th	Left femoral.	Temperature 100-103.5° from thirteenth to twenty-first day.
10323	Half-way to umbilicus.	49 per cent.	5th	Left femoral.	
10357	Reached to within 4 cm. of umbilicus.		6th	Left femoral.	

PHLEBITIS FOLLOWING HYSTEROMYOMECTOMY.—(Continued.)

CASE NO.	SIZE OF UTERUS.	HEMOGLOBIN.	DAY AFTER OPERATION.	VEIN THROMBOSIS.	REMARKS.
10778	Reaches 5 cm. above umbilicus.		21st	Left femoral.	
10875	Several small myomata; bilateral ovarian cysts.	60 per cent.	20th	Left femoral.	
12154	4 cm. above umbilicus.		9th 25d	In both legs.	
12199	Size of four and one-half months' pregnancy.		?	Both femorals.	After removal of ovarian tumor eight years before she had had phlebitis on both sides.
12811	Fills pelvis.		14th	Left femoral.	
C. H. I. (W)	Size of four and one-half months' pregnancy.		11th	Left femoral.	
C. H. I. (A)	Fills pelvis.		Few days after operation.		

In Case 3492 symptoms suggestive of pulmonary embolism developed, and subsequently there were signs of phlebitis in both legs and the left arm. On account of the lack of clearness in the diagnosis, this case is not included in the tabulation.

As will be seen from the table, thrombosis occurred as early as the fifth day and as late as the twenty-third day. The most common period was between the tenth and the twenty-third days.

In Cases 2098, 4617, and 4955 the phlebitis was associated with infection, and in Case 4902 with pleurisy. In a few of the cases faint hemic murmurs were noted, but in only one case (10323) was there any organic lesion—a mitral insufficiency.

It was impossible to determine the cause of the thrombosis in the above cases. It seemed to develop in certain cases irrespective of whether the tumors were large or small, free or adherent, and whether infection was present or not at operation. It is particularly interesting, however, to note that the greater number of cases of phlebitis developed in four isolated and distinct periods in the history of the hospital. For instance, the table shows that they were most prevalent in the fifth, seventh, eleventh, and thirteenth thousands. All of the patients recovered.

For phlebitis following abdominal myomectomies see p. 555. For those cases complicating vaginal myomectomy see p. 579, and those occurring in the fatal cases, p. 675.

Treatment.—The leg was wrapped in absorbent cotton and elevated, and every precaution taken to avoid much movement of the part. Massage, of course, was prohibited.

Pleurisy.—Three of our patients showed definite signs of pleurisy after the operation.

In Case 3492 a white woman, aged thirty-nine, had a myomatous uterus filling the lower abdomen. For eight days after operation the temperature varied from 99° to 101° F. It then rose to 103.5°, and a dry pleurisy was detected. Suddenly, on the eighteenth day, the patient had a fainting spell and showed symptoms suggestive of intra-abdominal hemorrhage. None was, however, found, and the general consensus of opinion afterward was that the patient had had a pulmonary embolism. After the exploratory section the patient developed phlebitis in both legs and the left arm. She finally made a good recovery.

In Case 4902, during convalescence after removal of a large myomatous uterus, a dry pleurisy developed on the right side, and on the fifteenth day a mild phlebitis of the right femoral vein. Recovery was otherwise uneventful.

In Case 8294 the patient was forty-five years of age and white. The myomatous uterus, which extended 3 cm. above the umbilicus, was easily removed. Gas and ether anesthesia was employed. The same evening the patient complained of pain on the right side. Her temperature was 101° F., and a distinct friction-rub could be made out in the right lower axilla. By the tenth day the temperature had reached normal, but a faint rub could still be heard.

In Cases 3492 and 4902 the pleurisy may possibly have arisen from a secondary infection. In Case 8294, however, it came on too early, and was evidently an entirely independent process.

Bronchitis.—In three instances we encountered a bronchial inflammation during convalescence. In Case 4022 the uterus filled the lower abdomen and the bladder was displaced upward. For eleven days after the operation the temperature ranged from 99° to 101.2° F. On the twenty-first day it rose again, reaching 103.6° F. This rise was apparently due to a bronchitis. The patient was well when she left the hospital.

The myomatous uterus in Case 4894 reached 8 cm. above the umbilicus. On the seventeenth day after the operation the temperature rose to 102° F. A hard, indurated mass was detected in the pelvis, and the patient had a definite bronchitis. The temperature soon fell, the bronchitis disappeared, and the patient made a good recovery.

In Case 12738 a myomatous uterus filled three-fourths of the abdomen. Hysterectomy was rendered difficult on account of intestinal adhesions. On the second day the patient had a temperature of 103° F., due to an acute bronchitis. She was discharged well twenty-eight days after operation.

Whether the bronchitis in the last case was due to the anesthetic or was merely an accidental accompaniment we are unable to say.

Bronchopneumonia.—In the following table are given the cases in which a bronchopneumonia complicated convalescence. In two of the cases the operation had been very difficult, and in a third the patient's heart was dilated and the hemoglobin was only 35 per cent. In the two remaining cases the operation was relatively easy. All these patients recovered.

In Case 11180 there was a bronchopneumonia probably secondary to a pulmonary abscess. This case is mentioned on p. 681.

CASES OF BRONCHOPNEUMONIA AFTER ABDOMINAL HYSTEROMYOMECTOMY.

CASE NO.	OPERATION.	BRONCHOPNEUMONIA.	RESULT.
6792	Difficult; severe hemorrhage.	Bronchopneumonia and right pleurisy.	Recovery.
10204	Easy.	Developed on eighteenth day.	Recovery.
10287	Easy.	Developed on sixth day.	Recovery.
10426	Heart dilated; hemoglobin, 35 per cent. Operation difficult on account of intestinal adhesions. Hemoglobin, 60 per cent.	Developed on second day.	Recovery.
11869	Easy; double pyosalpinx.	Bronchopneumonia.	Recovery.

Pneumonia after Hysteromyomectomy.—In addition to the two cases in which recovery took place are Cases 7381, in which the patient died of lobar pneumonia on the seventeenth day, and Case 6997, in which an intercurrent double basal pneumonia developed during convalescence and death from dysentery took place in the eleventh week. These cases are recorded on p. 681.

CASE NO.	OPERATION.	PART INVOLVED.	DAY AFTER OPERATION.	HIGHEST TEMPERATURE.	RESULT.
934	Easy.	Upper left lobe.	3d	104.8°	Recovery.
12194	Easy.	Posterior part of right lower lobe.	17th	100°	Recovery.

Pulmonary Abscess.—In Case 6933 the patient was thirty-nine years old and white. The greatly enlarged myomatous uterus was removed without difficulty. On the fifteenth day the patient complained of pain at the lower angle of the scapula on the right side. On the seventeenth day there was an elevation of temperature and pulse, slight moaning on deep inspiration, and a cough. On the twenty-eighth day she coughed forcibly once, and there was an immediate escape of several ounces of purulent material which consisted of pus-cells. The patient was much relieved after expectorating the fluid. She left the hospital two days later, still weak, but free from pain.

For pulmonary abscess occurring in the fatal cases see p. 682.

Symptoms Suggesting Abdominal Hemorrhage, but Probably Due to a Pulmonary Embolus.—In Case 3492 the patient, aged thirty-nine, white, had profuse uterine bleeding due to a submucous myoma, 10 cm. in diameter. The multinodular myomatous uterus was removed per abdomen. Her temperature varied from 99° to 101° F. for eight days, when it rose to 103.5° F. and a "dry pleurisy" was detected. Suddenly, on the eighteenth day, she had a fainting

spell. The pulse rose to 130, the respirations became rapid, the hands were clammy, and the patient presented a typical picture of hemorrhage. The abdomen was at once opened, but the area of operation was in a perfect condition. The temperature varied from 99° to 101.5° F. for the next ten days, when it again rose to 103.2° with symptoms of phlebitis in both legs and the left arm. She was discharged well. Pulmonary embolism was probably the cause of the sudden collapse.

The fatal cases of pulmonary embolism are described on p. 680.

COMPLICATIONS FOLLOWING VAGINAL HYSTERECTOMY.

Transitory Lack of Recognition.—In Case 8951 a small myomatous uterus was bisected and removed through the vagina. The patient, aged forty-eight, recovered slowly on account of weakness and anemia.

On the twenty-second day she was irrational, had tingling pains in the right arm, and did not recognize the nurses. This condition lasted for a day or two and gradually disappeared. When discharged, she was in good condition except for the weakness.

In this case we can only surmise as to the sudden and temporary clouding of the intellect.

Delusional Insanity.—In Case 1852, the patient, aged forty-seven, white, had a small retroflexed adherent myomatous uterus removed through the vagina. Two and a half weeks later a strangulated inguinal hernia was reduced and the opening closed.

After the operation the patient developed delusional insanity. Before operation she was weak mentally.

CHAPTER XXXV.

RESULTS OF OPERATIONS FOR UTERINE MYOMATA.

Our material consists of the patients operated upon at the Johns Hopkins Hospital up to July 1, 1906, those coming under the care of Howard A. Kelly at his sanatorium, and those operated upon by Thomas S. Cullen at the Church Home and Infirmary, the Cambridge (Md.) Hospital, and a few at the Emergency Hospital, Frederick, Md.

Cases admitted to the gynecological department of the Johns Hopkins Hospital from the opening of the hospital in 1889, to July 1, 1906.....	1267
Sanitarium (Kelly).....	64
Church Home and Infirmary, Cambridge, and Frederick (Cullen)....	97
Total.....	1428*

In 55 of the cases no radical operation was attempted on account of the weakened condition, or on account of refusal on the part of the patient. In some cases a simple exploratory operation was done, and the hopeless character of the case determined. In some cases no operation was deemed advisable.

Among these 55 cases 21 deaths occurred in the hospital.

In 7 cases death followed an exploratory abdominal section.

In 2 cases death followed a vaginal section.

In 1 case death followed a combined vaginal and abdominal exploration.

In 11 cases no operation was performed.

Total, 21 cases.

When we deduct those cases in which no radical operation could be performed, we still have 1373, † in each of which one or more uterine myomata were removed.

IMMEDIATE RESULTS IN OPERATIONS FOR UTERINE MYOMATA. ‡

Abdominal myomectomy....	296 cases,	280 recoveries,	16 deaths.	Death-rate, 5.4 per cent.
Vaginal myomectomy.....	84 "	79 "	5 "	6 "
Abdominal hysteromyomectomy.....	901 "	851 "	50 "	5.55 "
Abdominal hysteromyomectomy with bisection of uterus.....	68 "	60 "	8 "	11.76+ "
Vaginal hysteromyomectomy.....	24 "	24 "	0 "
	1373	1294	79	5.75+ "

*In addition to this number quite a number of other cases are mentioned in the book. These are all interesting, and either occurred since July 1, 1906, or have been operated upon by others. Two hundred and forty-six cases entered the Johns Hopkins Hospital between July 1, 1906, and Jan. 1, 1909, thus making a total of 1674 myoma cases that have come under our personal observation.

† At least 13 patients were admitted to the hospital more than once, but in the total number of cases only the first hospital number was considered. Each number thus stands for a different individual.

‡ The death-rate in the last two and a half years has been less than one per cent. (see p. 687).

In the remaining 55 cases, no radical operation was performed.

Of these patients, 10 died as the result of the exploratory operation.

Eleven died upon whom no operation was performed.

From the above table we see that, of 1373 patients operated upon, 1294 recovered and 79 died—an average death-rate of over 5.75 per cent.

Immediate Results in Abdominal Myomectomy Cases.—Out of 296 patients, 280 recovered and 16 died, a death-rate of 5.4 per cent. Naturally, abdominal myomectomy is performed only in suitable cases; in other words, in cases in which there is a strong chance of preserving a normal uterus. Under these circumstances we would naturally expect a lower death-rate than in the group of abdominal hysteromyometomies, which included many desperate cases. The rate is slightly lower, but the difference is less than one might expect. We are all aware of the fact that myomectomy offers much more chance for subsequent infection than does hysteromyomectomy.

Abdominal myomectomy is considered in detail in Chapter XXIX. Here also are given *in extenso* the postoperative complications, the causes of death in the fatal cases, and a list of the patients that have subsequently borne children.

Immediate Results Following Vaginal Myomectomy.—From the tabulation it is seen that of 84 cases, 79 patients recovered and 5 died—a death-rate of 6 per cent. In Chapter XXX these fatal cases are recorded in detail, and it will be seen that in 4 out of the 5 cases the patients were in a desperate condition and operation gave the only hope of even temporary salvation. In only one case were we surprised at the fatal issue. This patient had a small submucous myoma twisted from the interior of the uterus. She did well for a short time, and then rapidly grew weaker and died. This case is described in detail on p. 580.

Results after Abdominal Hysteromyometomies.—In 901 cases an abdominal hysteromyomectomy was performed: 851 patients recovered and 50 died—a mortality of 5.55 per cent. In the majority of the cases the uterus was amputated through the cervix. In only 50 cases was a panhysterectomy done.

CAUSES OF DEATH FOLLOWING ABDOMINAL HYSTEROMYOMETOMY.

This table is as accurate as we can make it, but every surgeon will realize that there are numerous chances for error. In some cases we have been forced to rely on the postoperative history for the probable cause of death, no autopsy having been granted. In other cases the patients died of peritonitis, but whether the septic factor was primary or secondary to an obstruction it was difficult to determine.

Probable cause:

General peritonitis in.....	22 cases
Intestinal obstruction in.....	5 "
Shock ".....	7 "
Pulmonary embolism ".....	4 "
Other causes ".....	12 "
Total.....	50 cases

Deaths due to Peritonitis Following Abdominal Hysteromyectomy.—

The tabulation of deaths due to peritonitis after abdominal hysteromyectomy shows that in quite a number of cases it was impossible to trace the source of infection, but in the majority the operation was either complicated by very dense adhesions, sometimes leading to injury of the bowel during the operation, or was associated with an infected uterus, a suppurating myoma or a purulent collection in the adnexa.

In Case 1767 death seemed to be due to separation of the abdominal wound. Removal of the uterus, which reached the umbilicus and contained thirty myomata, was difficult. On the fifth day the abdominal incision was widely separated, and the omentum was bulging up into the incision. Studding the margins of the incision were little foci of pus. The patient, before operation, had many sonorous and whistling râles and severe paroxysms of coughing which continued after the operation and may have been the cause of the giving way of the abdominal sutures. She died with definite signs of peritonitis on the eighth day. In this case it would have been much wiser to have delayed operation until the pulmonary symptoms had entirely subsided.

Infection from a sloughing submucous myoma was noted in Case 4609. The uterus was the size of that of a five months' pregnancy. Examination of the specimen after removal showed, in addition to subperitoneal and interstitial myomata, several submucous nodules. The largest of these was 4 cm. in diameter, and its surface had been converted into a greenish-yellow suppurating tissue. The uterine mucosa near the internal os was hemorrhagic and covered with necrotic material from the suppurating myoma. In addition to the complications already mentioned the urine contained albumin and casts. In this case operation was delayed for eleven days in the hope that the discharge might be lessened and the abdominal operation rendered less dangerous, but the discharge did not abate, and hysterectomy was undertaken.

In such cases the operator is often confronted, on the one hand, by the absolute certainty of the patient's speedy death if she is not relieved, and, on the other hand, by the great risk of infection if any operative interference is attempted.

In Case 7158 the fatal peritonitis was due to a sloughing subperitoneal myoma. The patient at operation was markedly emaciated and was in a most critical condition. Her pulse varied from 120 to 130. The tumor was about the size of a five months' pregnant uterus. When the hand was passed around to the right of the umbilicus, several ounces of thick green fetid pus which had a garlicky odor escaped. It was quickly sponged up. On removal of the uterus this large abscess was found to be due to the breaking-down of a suppurating subperitoneal myoma. The patient was in a desperate condition when she left the table, and died on the third day. In such a case the surgeon has no alternative but to operate. This case is reported in detail in the chapter on Suppurating Myomata (see p. 150).

DEATHS DUE TO PERITONITIS FOLLOWING AN ABDOMINAL HYSTEROMYOMECTOMY.

GYN. No.	AUTOPSY No.	DAY AFTER OPERATION.	CULTURES.	SOURCE OF INFECTIONS AND COMPLICATIONS.
69	55	5th	Staphylococcus aureus.	Volvulus of ileum.
701	4th
729	198	5th	General B. coli.	Diphtheritic enteritis, slight peritonitis.
963	237	3d	Cultures from abd. cavity negative.
1767	385	8th	Staphylococcus aureus.	Separation of abdominal wound, and omentum seen. Cough continuous before and after operation.
2713	6th
3008	561	4th	Cultures negative.	Dense pelvic adhesions.
3198	595	2d	Streptococcus.	Abdomen reopened.
3493	666	17th	Staph. aureus.
3882	14th	Slow general infection.
3898	6th	Dense adhesions, tear in external coat of ileum, with subsequent perforation.
4609	6th	Sloughing submucous myoma.
5302	954	10th	B. coli.	Dense adhesions with perforation of sigmoid.
5858	2d	Streptococcus.	Carcinoma of body of uterus. (See Cullen's "Cancer of the Uterus," p. 454, Fig. 237.)
7158	3d	Suppurating myoma.
7863	8th	Slow general infection.
8732	1734	7th	Streptococcus.	Sarcomatous degeneration of myoma.
10669	2162	4th	General peritonitis. Rent in rectum.
10749½	4th
12209	7th	Dense intestinal and pelvic adhesions and rupture of an ovarian abscess.
12587	2651	5th
C. H. I. K.	10th	Advanced carcinoma of body (Fig. 180, p. 286).

Cases 5858 and C. H. I. K. (see p. 286) afford typical examples of peritonitis developing when a supravaginal hysterectomy has been performed in cases of supposedly simple myoma, but where carcinoma of the body was also present. The foul discharge is very prone to infect the field of operation, and peritonitis speedily follows. Death in Case 5858 occurred on the second day and was due to a streptococcal infection. This case is reported in detail in Cullen's "Cancer of the Uterus," p. 454 (Fig. 237). In Case 8732 peritonitis resulted from accidental soiling of the peritoneum with sarcomatous tissue. After we had tied the left ovarian vessels and round ligament and had begun to work down to the left uterine vessels a slight tear in the large tumor allowed a brain-like material to ooze out near the uterine vessels. Sarcoma was at once diagnosed, and complete, instead of supravaginal, hysterectomy performed. The patient,

however, died of general peritonitis on the seventh day. Large sarcomatous areas are especially prone to undergo coagulation necrosis and become infected. The case is reported in detail on p. 215.

In Case 12209 the death was certainly due to infection from a large ovarian abscess. The pulse before operation was between 150 and 160. Filling the entire right lower abdomen was a tumor. Above this the intestines and omentum were everywhere adherent. On gradually loosening up the mass we found it to be composed of a myomatous uterus with a densely adherent ovarian abscess on the right. The abscess was firmly adherent to the intestinal loops. Its walls ruptured, and about ten ounces of greenish-yellow pus were evacuated, with little soiling. Abdominal hysterectomy was performed. The patient's condition was desperate, and that night her temperature reached 105° F. On the fifth day she developed phlebitis in the left leg. She died on the seventh day. In such a case little else could have been done. Where there are signs of an abscess low down in the pelvis, however, the better plan is to attempt evacuation through the vagina, and it is astonishing to see how the densely adherent pelvic structures loosen up and the tumors that at the first operation were so firmly fixed that their enucleation would have been impossible can now be removed with relatively little difficulty. The disappearance of the induration is often as striking as that noted when evacuation of an appendix abscess is followed months later by the easy removal of the appendix. In the case just cited, however, the abscess was too high up to be readily attacked from below, and immediate operation was imperative.

In Cases 3898 and 5302 the peritonitis was, in a large measure at least, due to injury of the bowel at operation. In Case 3898 the omentum, rectum, and loops of small bowel were densely adherent to the enlarged uterus. During the liberation of adhesions the outer coat of the small bowel was injured at one point. This tear was closed with three sutures. The temperature and pulse rose gradually after operation, and on the second day the patient complained of excruciating pain on the right side, over the site of the intestinal suture. This pain became so intense that the abdomen was opened, and perforation of the bowel found at the point of suture. Death soon followed. It looks very much as if the injury at the time of operation had involved not merely the outer, but also the middle and inner, intestinal coats. We have noted that where dense intestinal adhesions exist, the lumen of the bowel may be drawn out as a filiform tube for a considerable distance into the abdomen. Such adhesions should be as carefully turned in as an appendix stump, otherwise there may be danger of general peritoneal infection.

In Case 10749½ a colored woman, aged forty-three, had marked pain in the lower abdomen. The myomatous uterus reached to the costal margin on the right side. The pelvic portion of the tumor was embedded in adhesions. Accordingly, the hysterectomy was very difficult. Two vaginal and two abdominal drains were employed. On the evening of the third day an enema consisting of

500 c.c. of soapsuds was given. This was expelled clear. Just at this time the patient complained of acute pain in the lower abdomen, flanks, and also beneath the right costal margin. The pulse rose to 140, but the temperature remained at 99.5°. The patient vomited much clear fluid and was in a profuse perspiration. Two hours later she was lying with the legs drawn up; the respirations were rapid. She became delirious, the pulse gradually grew weaker, and she died early on the following morning. The autopsy showed a general fibrinous peritonitis, and at the junction of the sigmoid with the lower portion of the rectum an opening in the bowel 3 cm. long. Through this the enema had been injected into the abdominal cavity.

At times the pelvis presents such a ragged appearance as a result of the dense adhesions that a hole in the bowel may be readily overlooked. In every case in which there had been the slightest possibility of injury the most careful inspection should be made.

In Case 5302 the lower two-thirds of the abdomen was filled with a myomatous growth. At operation dense adhesions were encountered. There was an appendix abscess, a right pyosalpinx, and an abscess of the right ovary. The tumor was firmly fixed to the pelvic floor, rectum, colon, sigmoid flexure, and anterior abdominal wall. The urine before operation contained a moderate amount of albumin and some hyaline casts. After operation it showed many casts. The patient died on the tenth day. At autopsy perforation of the sigmoid flexure was found. This had first given rise to a localized peritonitis, and later the general peritoneal cavity had become involved.

The patients who succumbed to peritonitis usually died within the first six days, but in some cases the infection was a slower one; in Case 3882, for instance, the patient lived until the fourteenth day, and in Case 3493, until the seventeenth day. Where the infection is streptococic, as in Case 5858, the termination may be appallingly rapid, this patient dying on the second day.

We regret that our bacteriologic examinations are not complete. In those cases in which the second operation was undertaken the patient was usually in such a desperate condition that all efforts were directed to doing what was necessary and getting the patient off the table at the earliest possible moment.

In the rapid streptococic peritonitis cases operation avails little unless performed within the first few hours, before the infection has become general. Careful wiping off of the pelvic walls and the intestinal loops in the vicinity, with wide-spread drainage of the pelvis with gauze, occasionally yields good results. In the slow peritoneal infections wide-spread drainage is practically all that can be accomplished. Where it is necessary to reopen the abdomen, we have found it wiser to make a new incision instead of opening up the old abdominal wound.

From the foregoing it will be seen that in many of the cases peritonitis undoubtedly developed from an already existing pelvic infection, and in nearly every case the hysterectomy was a very difficult one.

Deaths from Intestinal Obstruction Following Abdominal Hysteromyomectomy.

—In Case 6217 great difficulty was experienced in covering in the raw areas on account of the marked distention of the intestines. Finally, it was necessary partly to eviscerate the patient before the parts could be properly approximated. This maneuver was probably responsible for the subsequent obstruction, as in replacing the intestine some kinking might have taken place, and, as was pointed out at a recent meeting of the American Medical Association, much handling of the bowel is often followed by prolonged atony. There are certain patients that have marked distention of the intestine notwithstanding the most careful preliminary preparations.

In Case 10486 the patient left the operating table in good condition, but on the third day the temperature rose to 101.6° F, and the pulse to 104. On the fourth day an enterostomy was done. The intestines were enormously distended, owing to the presence of a stricture in the small bowel, 10 cm. from the ileocecal valve, a loop of bowel having become adherent to a raw area near the pelvic brim. This case again emphasizes the great importance of covering over any raw areas with peritoneum, thus leaving no point at which intestines may adhere.

In Case 12216 we were dealing with a large myomatous uterus. A subperitoneal nodule had suppurated (Fig. 104, p. 136) and become adherent to the anterior abdominal wall. Our attempts to draw the peritoneum over the raw area left on the anterior abdominal wall were not very successful on account of the indurated condition of the surrounding tissue. Partial obstruction developed on the sixth day. On the eighth day the gut was found adherent to the anterior abdominal wall, and kinked at this point. Death followed the same day. In this case we are certainly open to criticism, as, knowing the dangers at operation, we should have opened the abdomen as soon as the obstruction commenced. Our reason for delay, however, arose from the fact that the bowels had been thoroughly moved a few days after operation.

DEATHS DUE TO INTESTINAL OBSTRUCTION FOLLOWING AN ABDOMINAL HYSTEROMYOMECTOMY.

GYN. NO.	ACT. NO.	DAY AFTER OPERATION.	SECONDARY OPERATION.	COMPLICATIONS.
6217	118	5th.	None.	Great difficulty in getting a proper exposure on account of distended intestines.
6521	8th.	Exploratory.	Partial obstruction before hysterectomy.
10486	4th.	Release of obstruction.	Ileum adherent to edge of pelvis after operation.
12216	8th.	Exploratory.	Suppurating myoma adherent to anterior abdominal wall. Post-operative intestinal adhesions at that point.
S. 1566	8th.	None.

Deaths from Shock Following Abdominal Hysteromyomectomy.—The cause of death in Case 1703 is not clear. After removal of the uterus, which extended up to the ribs, a Mikuliez drain was introduced and the abdomen closed. The patient never rallied satisfactorily after the operation, notwithstanding the fact that little blood was lost. The pulse rapidly rose to 168 and the respirations to 40. She died fourteen hours after operation.

Case 4607 was one of carcinoma of the cervix associated with a submucous myoma. When the necessary extensive hysterectomy had been completed, the pulse was hardly perceptible. In this case the tuberculosis of the hip prevented the necessary flexion of the thigh, and rendered the proper exposure of the pelvic structures difficult. Much blood was lost. The patient never recovered from the effects of the operation and died twelve hours after leaving the table.

In Case 5010 the patient entered the hospital in a precarious condition. Operation was delayed in the hope that there might be some improvement, but she steadily lost in strength. The abdomen having been opened and the omentum drawn gently back, free pus welled up out of the pelvis. The condition present was exactly as if one had poured half a liter or more of pus into a pelvis partially filled with a multinodular and firmly adherent myomatous uterus. It was impossible properly to drain the various pockets. Hysterectomy was attempted, but the tissues were everywhere almost like cartilage. The pulse, which was 120 and weak, rapidly increased as the operation progressed, and the patient died just as the abdomen was being closed. Had we known of the bisection method at this time the operation could have been performed much more speedily, and it is possible that the patient might have been saved.

DEATHS DUE TO SHOCK FOLLOWING ABDOMINAL HYSTEROMYOMECTOMY.

GYN. NO.	AUTOPSY NO.	TIME AFTER OPERATION.	COMPLICATIONS.
1703	14 hours.
4607	12 hours.	Carcinoma of cervix; tuberculosis of hip.
5010	908	On table.	Abscess in myoma; chronic adhesive pericarditis; fatty degeneration of liver.
5617	On table.	Bronchitis, "weak heart."
6017	Secondary.	Sloughing submucous myoma.
6760 } 7036 }	1387	On table.	Abdominal myomectomy two months before; later profuse hemorrhage; intestinal adhesions to uterine wound.
9030	8 hours.	Rupture of large infected ovarian cyst into abdominal cavity.

In Case 5617 there was weakness and shortness of breath. The pulse was 130 and feeble. On account of bronchitis, chloroform was first used, but the respirations ceased. After resuscitation ether was administered. The pulse rose to 168,

becoming weaker and irregular, and the patient died on the table. The large myomatous tumor had suppurated and broken through into the uterine cavity. The wisdom of operating on such a case may be questioned, but it is perfectly clear that without operation death was certain, and in other apparently more desperate cases patients have survived the operation and have been restored to perfect health.

In Case 6017 there were great weakness, shortness of breath, and swelling of both legs. The vagina was filled with a large, rounded mass, slightly gangrenous in several places. This tumor was continuous with the myomatous uterus, which extended to the umbilicus. At operation vaginal myomectomy was done and the uterus removed from above. The hysterectomy was very difficult, the growth being to a great extent behind the bladder. The entire operation occupied three hours. After infusion the patient steadily improved until 4 A. M. on the next morning, when she suddenly felt faint. The pulse and respirations became very rapid, and she presented the typical symptoms of hemorrhage. The abdomen was opened, but there was no sign of bleeding. She died just as the abdomen was closed.

We are certainly open to criticism in this case. When a sloughing submucous myoma is present, this should be completely, or as far as possible, removed. Under no circumstances should the hysterectomy be undertaken until the dangers of infection from the necrotic submucous growth are past.

The operation in Case 7036 was secondary to a myomectomy done two months before. The patient was so weak as a result of the intestinal obstruction that she died on the table. For the full details of this case see p. 566.

In Case 9030 the patient was so weak and anemic on admission that operation was deferred. Later a large myomatous uterus was exposed, and filling the right lumbar region and extending to the right side of the uterine mass as far as the costal margin was a large cystic accumulation with walls varying in thickness. This was everywhere adherent to the intestines. During its liberation the cyst ruptured, and a large amount of foul-smelling purulent material was scattered throughout the abdominal cavity. This was immediately flushed out with a large amount of salt solution, and the uterus quickly removed. Immediately after the operation the patient was in a state of collapse. She soon rallied, and a few hours later the pulse was easily counted. Toward evening there were signs of collapse. The pulse could not be counted. The patient was gasping for air and was very cyanotic. She died eight hours after operation.

In this case also operation offered the only hope. With our present knowledge of the operative technic we would wipe out the pus that had escaped, and under no circumstance run the risk of spreading it by flushing the abdominal cavity.

From the above it is seen that in six of the seven deaths from shock following abdominal hysteromyomectomy the fatal termination was not unlooked for, all being desperate cases. In Case 1703 we are at a loss to account for the death.

Fatal Pulmonary Embolism, Following Abdominal Hysteromyomectomy.—In four of the 901 abdominal hysteromyomectomies the patients died of pulmonary embolism.

In Case 7361 there was a simple, uncomplicated, supravaginal hysteromyomectomy. The appendages, which were normal, were left *in situ*. The patient did well until the fourteenth day, when, while talking to another patient, she complained of feeling ill, grew pale, and suffered from dyspnea and suffocation. The face was covered with beads of perspiration. She responded to questions and complained of a "weight" on the chest. The pulse was slow and full, but irregular. About an hour later dilatation of the left pupil was noted, and the patient responded to questions by nodding the head. There seemed to be paralysis of the left arm and the right side of the face. The breathing was now very stridulous. The condition improved somewhat during the day, but toward evening the pulse became irregular and dropped a beat frequently. Shortly after midnight, just fifteen hours after the onset, the patient gave a gasp and died. Autopsy showed embolism and thromboses in the pulmonary arteries, and old tuberculous lesions in both lungs.

DEATHS FROM PULMONARY EMBOLISM FOLLOWING AN ABDOMINAL
HYSTEROMYOMECTOMY.*

GYN. NO.	AUTOPSY NO.	CHARACTER OF OPERATION.	POSTOPERATIVE CONDITION.	DAY OF DEATH.
7361	1445	Simple.	Good.	Fifteenth.
9675	1936	Simple.	Thrombosis of left ovarian vein.	Fifth.
S. 1682	Simple.	Good.	Twelfth.
S. 1872	Simple.	Good.	Fourth.

In Case 9675 the patient was a stout, rather weak woman. She had a chronic nephritis. The uterus was free from adhesions, and could have been easily removed had it not been for the difficulty in obtaining the necessary exposure. The patient did fairly well for two days, but grew weak on the fifth day, and died apparently as the result of profound asthenia. At autopsy thrombosis of the left ovarian vein was found. The left pulmonary artery was normal, but on opening the right a large thrombosed mass was found lying in the branch to the lower lobe. This thrombus did not completely fill the vessel. It was rough, of a grayish color, and had other clots attached to it. Its central portion was apparently undergoing softening.

In San. No. 1682 the uterus was easily removed, and the appendages were normal. The patient died suddenly, apparently of pulmonary embolism, on the twelfth day.

* In Case 12587 death was due primarily to a general peritonitis. At autopsy, in addition to thrombosis of the uterine and vesical veins, pulmonary embolism was noted. The lungs were also the seat of abscesses, bronchopneumonia, acute bronchiectasis and bronchitis, and there was an acute fibrinous pleuritis.

In San. No. 1872 the patient was a very frail woman, fifty-one years old, with a hemoglobin of 50 per cent. The myomatous uterus was removed without difficulty. On the fourth day she was as bright as usual, when suddenly she screamed, became unconscious, and died within a few minutes. Embolism was probably the cause of death.

In not one of the four cases in which the patient died of pulmonary embolism had we any evidence of the embolus being due to pelvic infection. In each case the operation was a simple uncomplicated one and the convalescence was normal until the symptoms of embolism developed.

OTHER CAUSES OF DEATH FOLLOWING AN ABDOMINAL HYSTEROMYOMECTOMY.

In addition to the deaths following abdominal hysteromyomectomy and due to general peritonitis, intestinal obstruction, shock, and pulmonary embolism, there were 12 other cases. The cause of the death in these cases is shown in the following table:

OTHER CAUSES OF DEATH FOLLOWING AN ABDOMINAL HYSTEROMYOMECTOMY.

GYN. NO.	AUTOPSY NO.	CAUSE OF DEATH.
3977	742	Fatal hemorrhage from a uterine artery on the eighth day due to too early absorption of the catgut ligature.
7381	Lobar pneumonia on seventeenth day.
11180	2293	Abscess of lung and bronchopneumonia. Death on twentieth day.
6997	Convalescence interrupted by double basal pneumonia. Symptoms suggestive of gastric carcinoma. Death from acute dysentery in eleventh week.
8024	Did well till twenty-first day, then developed severe diarrhea and died on twenty-eighth day.
9652	Persistent nausea. Abdomen opened on fourteenth day. No signs of obstruction or peritonitis. Death the same evening.
10593	Persistent nausea; abdomen reopened, no signs of obstruction or peritonitis. Death on third day.
12611	Chronic diffuse nephritis. Death on fifth day. Abdomen reopened; no peritonitis or obstruction.
C. H. I., 511	Acute suppression of urine, due to a chronic diffuse nephritis. Death on the second day. Operation: complete removal of uterus by the Wertheim method for carcinoma of the cervix. The diffuse adenomyoma of the body was discovered only in the laboratory. (Reported in full in "Adenomyoma of the Uterus," p. 211.)
8183	Found dead in bed on twenty-fifth day. Had had previous attacks of syncope.
10095	Probable myocarditis; death on fourth day. No autopsy.
13016	Myocarditis; death on twelfth day.

Fatal Secondary Hemorrhage.—In Case 3977, as a result of too early absorption of the catgut ligature controlling the left uterine artery, the patient died of sudden and fatal hemorrhage from this vessel on the eighth day.

In this case the pelvis was filled with a large globular mass about the size of a fetal head and the cervix was drawn up high. The myomatous uterus

reached the umbilicus. The operation proved to be relatively simple. On the eighth day the patient called a nurse, saying that she felt faint. Her pulse rapidly became imperceptible, she was gasping for breath, her face was cyanotic, the extremities were cold; death resulted in a few minutes. At autopsy a considerable amount of fluid, especially clotted blood, was found in the abdominal cavity. The hemorrhage appeared to have come from the left uterine artery, probably as result of too early an absorption of the catgut ligatures. There was slight atheroma of the coronary arteries and faint evidences of a myocarditis. Death was undoubtedly due to the hemorrhage.

Pulmonary Abscess.—In Case 11180 a large multinodular myomatous uterus was removed. On the fourth day an area of dulness could be detected in the right lung. It was demonstrable both in front and behind. The temperature varied from 102° to 104.5° F. for a week, and when the patient was transferred to the medical ward on the sixteenth day, it was about 100.5° F. The pulse was rapid and the general condition unfavorable. She died eighteen days after operation. Autopsy revealed a bronchopneumonia of the left lung, with a large encapsulated gangrenous abscess in the lower lobe. There is no evidence that the operation was in any way responsible for the pneumonia or for the pulmonary abscess.

In Case 12587 the patient was a negress, thirty-nine years of age. After removal of a large myomatous uterus she developed a bronchopneumonia and died on the fourth day. At autopsy acute fibrinous pelvic peritonitis, thrombosis of the uterine and vesical veins, embolism of the pulmonary arteries, pulmonary abscesses, bronchopneumonia, acute bronchiectasis and bronchitis, acute fibrinous pleuritis, and acute diphtheric colitis were found. The pulmonary abscesses were probably secondary to the emboli. This case is included among the deaths from peritonitis on p. 674.

Acute Suppression of Urine.—The death in case C. H. I. 511, from acute suppression, followed a Wertheim operation for carcinoma of the cervix in a patient with chronic nephritis. The exact conditions and dangers were explained to the patient before, and she chose operation.

The adenomyoma was not recognized until after removal of the uterus. This case in a sense should not be included under deaths following operations for myomata, but, as it forms one of our total number of myoma cases, it hardly seems fair to include it in one place and omit it in another. In order, therefore, to remove even the slightest possible suggestion of bias and to be on the safe side we have included it. The same may be said of Case 8183, in which the carcinoma of the cervix was the dominant lesion and the myoma was not large.

Myocarditis.—The clinical picture in Case 10095 suggested myocarditis, but the exact condition could not be ascertained, as no autopsy was obtainable.

In Case 13016, a negress, thirty years old, was well nourished and healthy looking. There was marked pulsation in the arteries on the right side of the neck. There was a faint, blowing, systolic murmur heard most distinctly in the

second left intercostal space. It was traceable to the vessels of the neck. Filling the lower abdomen was a myomatous uterus. This was removed without difficulty, and up to within five minutes of her death, on the twelfth day, the patient had improved steadily. Two hours before she had complained of pain in the right leg. This, however, was not severe. The patient suddenly gasped for breath, became semiconscious, and died in five minutes. The coincident pain in the right leg and the sudden death naturally suggested pulmonary embolism, but at autopsy acute myocarditis (degenerative), chronic fibrous myocarditis, and cardiac dilatation, together with lymphatic hyperplasia, were found.

DEATH FOLLOWING BISECTION OF THE UTERUS.

In 68 of the abdominal hysterectomy cases, prior to removal of the uterus, it was bisected. On account of the newness of this operation, we have considered these cases by themselves. Eight of the patients died, an exceedingly high mortality, namely, 11.76 per cent.

CAUSES OF DEATH.	NUMBER OF CASES.
General peritonitis.....	3
Intestinal obstruction.....	1
Shock.....	2
Pulmonary embolism.....	1
Bronchopneumonia (wide-spread metastases from sarcomatous degeneration of a myoma).....	1
	—
	8

Peritonitis.—The death in Case 7474 was due to the fact that necrotic sarcomatous tissue in the center of a large myoma was set free by the bisection. The case is reported in detail on p. 208.

In Case 8593 a negress, twenty-nine years old, had a hemoglobin of 24 per cent. On section of the abdomen dense adhesions were found between the tumor, the pelvic walls and rectum. The right side was first freed and during the manipulations an abscess ruptured and a considerable amount of creamy pus escaped. The outer coat of the rectum was slightly torn. Bisection was at once resorted to to save time. The two halves of the uterus were removed, and the pelvis was packed. The patient was markedly shocked. She slowly rallied, but two weeks after operation grew weaker, and died on the sixteenth day with signs of general peritonitis.

In Case 9132 a negress, forty-two years old, had a weak and rapid pulse during operation. On account of intestinal and general pelvic adhesions the uterus was bisected. She rallied slightly after operation, but on the third day grew weaker and died on the following day. Aut. No. 1809 revealed a general purulent peritonitis.

Intestinal Obstruction.—In Case 9536 the operator found the tumor filling the pelvis and firmly fixed by dense adhesions. Bisection offered the best

prospects. Posteriorly, the tumor was so densely adherent to the rectum that a portion of it had to be left attached to the bowel. The pelvis was packed with gauze, and the patient left the table in good condition. During the next day she had severe pain in the left side of the pelvis; the pulse was 110, the temperature 101.5° F. Vomiting and distention developed, and the patient died on the fourth day with definite signs of obstruction. This case is reported in detail on p. 180. Here it will be seen that the entire central portion of a large sub-peritoneal myoma had undergone sarcomatous transformation, and that the center of the malignant growth had become necrotic. Local infection naturally followed, with kinking of the bowel.

Death from Shock Following Bisection.—In Case 8836 the patient was a white woman, forty-eight years of age. Filling the pelvis, and extending halfway to the umbilicus, was a myomatous uterus. On account of numerous dense adhesions bisection was carried out. In order to free adhesions as rapidly as possible the bladder and rectum were both opened, but later accurately closed. The patient, on leaving the table, was in a desperate condition; the pulse was 130, very weak, and irregular; the extremities were very cold. In spite of stimulation she died within a few hours. In this case the subsequent steps of the operation clearly demonstrate that we had shown very poor judgment in opening the bladder and rectum, as the time saved by opening them was more than lost during the subsequent closure.

In Case 8872 the patient was a white woman, fifty-two years of age, and well nourished. After a long median incision through very thick walls had been made, a large multinodular uterus was exposed. This tumor was not adherent, but had developed mainly in the cervical region. Eneucleation was carried out by first clamping the ovarian vessels on both sides and then bisection. The hemorrhage was very profuse. After splitting down to the cervix, the operator pulled the tumor from its capsule, but the bleeding still persisted. Both halves of the uterus were then removed. The patient was almost pulseless on leaving the table. Toward midnight she became delirious, and died at 6 A. M. Extensive development of a tumor usually renders the hysterectomy difficult, but with slow and patient traction we would probably have been able to remove the uterus intact and to save our patient. Death was clearly due to the great amount of blood lost during the operation.

Death from Pulmonary Embolism Following Bisection.—In Case 8713 the patient was a negro, forty years of age. On section of the abdomen the pelvis was found filled with a multinodular myomatous uterus. Bisection was easily done, and the right structures were removed without difficulty. The left appendages were very adherent. The gall-bladder was opened, and several stones removed. Convalescence was normal until the sixth day. The night nurse heard her cough and gasp, and by the time she reached the bed the patient was dead. Aut. No. 1733 showed a perfectly smooth peritoneal cavity, but thrombosis of the left common iliac vein. Unfortunately, the pathologist was unaware

of the apparent cause of death, and the lungs were removed in the ordinary way and no embolism was detected. Both lungs showed some petechial subpleural hemorrhages.

The clinical picture, coupled with the thrombosis of the iliac vein, leaves little doubt that the patient died of pulmonary embolism.

Bronchopneumonia Causing Death after Bisection.—In Case 7604 the patient was a white woman, aged forty-four. The enlarged uterus extended above the umbilicus, and the bladder was drawn up as far as the umbilicus. The tumor was adherent to the rectum, and each tube was the seat of a hydrosalpinx. The uterus was bisected. From the cavity blood-stained serous fluid escaped, and from the lower part of the uterus a soft stringy substance, softer, darker, and more vascular than ordinary muscle tissue. From an accidental rent in the bladder infected urine escaped into the pelvis. The patient gradually grew weaker and died on the twelfth day. Aut. No. 1503 revealed gangrene of the left ovary, sarcomatous metastases in the lungs, bronchopneumonia, metastases in the chordae tendineae, on the tricuspid valves, and acute endocarditis. This case is reported in detail on p. 220.

The majority of the cases in which death followed bisection were most difficult, and in some instances impossible of accomplishment by any other method. A study of the cases, however, shows that wherever there is infection of the uterine cavity or malignant degeneration in the myomata, the danger of immediate general peritonitis is great. In some cases, also, great loss of blood follows the bisection. This operation should never be performed in myoma cases, when the uterus can be removed intact. In a certain group of otherwise inoperable cases the procedure, however, is of the greatest value to the surgeon.

RESULTS IN VAGINAL HYSTEROMYOMECTOMY.

As seen from the table, we had 24 vaginal hysteromyomectomies with no deaths. In practically all these cases the uterus was small and mobile and was taken out readily from below. In many of the cases these myomata were associated with prolapsus of the uterus, and the operation was for the prolapse rather than for the myoma.

In nearly all cases in which the myomata are of moderate or large size we prefer opening the abdomen and removing the uterus from above. We are thus enabled to see clearly each step in the operation, and to cope successfully with the various and unexpected complicating conditions that are so frequently met with.

FINAL RESULTS AFTER OPERATIONS FOR UTERINE MYOMATA.

After abdominal myomectomy the results are, on the whole, very satisfactory (Chapter XXIX, p. 506). The dragging sensations in the lower abdomen and the backache, so frequently noted, disappear, and the patient feels perfectly

well. In a few instances, as noted on p. 561, a subsequent hysterectomy may be necessary on account of the development of other myomatous nodules.

In cases in which a simple supravaginal hysterectomy has been performed and the ovaries have been saved, the final results are also very satisfactory, and in many cases the unpleasant phenomena of the premature menopause have been avoided. (See p. 603.)

In cases in which there has been much hemorrhage, the rapidity with which the patients improve after operation is often little short of marvelous, and the hemoglobin, which prior to operation has been below 30 per cent., rapidly rises to 60 or 70 per cent., and in the course of a few weeks is nearly normal. In Case M., seen in consultation with Dr. E. W. Meisenhelder, at York, Pa., on January 2, 1903, affords an excellent example of such improvement. The patient at operation was almost colorless, and during the operation the blood on the sponge left no deeper stain than if dipped in port wine. There had been excessive hemorrhages, due to a very large submucous myoma. At the end of ten weeks the patient had improved markedly and had a good color. The improvement was so great that her intimate friends, meeting her on the street, did not recognize her.

Our death-rate, on the whole, has been relatively large, but it must be remembered that the series includes the cases from the time the hospital opened in 1889 until July 1, 1906. In the early days the operative technic for the removal of myomata was still in the transition stages and many cases that called for an operation, at that time formidable and attended with grave dangers, are now relatively easy and can be properly cared for with but little risk. Furthermore, many of the patients had passed from clinic to clinic, the condition having been regarded as inoperable, so that, so far as we were concerned, removal of the tumor was attempted as a last resort. Such patients would now be operated upon before adhesions, suppuration, or marked degenerative changes had taken place. A glance at the results of the last two and a half years will show that our operative mortality has been less than one per cent.

The remarkable improvement that can often be obtained by removing sloughing submucous myomata from patients who, as a result of the septic absorption, have a high temperature, a rapid and weak pulse, and are apparently almost moribund, is simply astonishing. (See p. 577.)

Naturally, the removal of any tumor of considerable size and weight affords physical relief, which in some cases is almost indescribable.

Taken as a whole, few operations in surgery give as much permanent satisfaction as those for the removal of uterine myomata.

RESULTS IN MYOMA CASES AT THE JOHNS HOPKINS HOSPITAL FROM JULY 1, 1906, TO JANUARY 1, 1909.

	CASES.	DEATHS.	PERCENTAGE.
Abdominal myomectomy.....	38	0	0
Vaginal myomectomy.....	6	0	0
Abdominal hysteromyomectomy.....	192	2	1+
Vaginal hysteromyomectomy.....	2	0	0
	—	—	—
Total operations.....	238	2	.85
	—	—	—
Not treated.....	8	.	..

In the series of 246* cases there were 3 deaths, two following abdominal hysteromyomectomy, and one in which no operation had been performed. This gives a mortality of .85, or less than 1 per cent.

In the 194 hysteromyomectomies all but two of the patients (Gyn. Nos. 14662 and 15252) recovered—a mortality of a little over 1 per cent. In Case 14662 the patient died of postoperative intestinal obstruction on the twenty-second day. In case 15252 the woman was forty-four years of age. At operation complicating the myomatous condition of the uterus a general peritoneal carcinosis was found. The origin of these papillary carcinomatous masses could not be determined.

In case 15477 the patient was admitted to the hospital in a state of extreme asthenia and was markedly anemic. She died in a state of shock on the following day. In this case, of course, operation was out of the question.

The reduction of the operative mortality in the last two and one-half years to less than 1 per cent. is particularly gratifying. It is due in part to the fact that many patients came to the operation before serious complications developed, but in a large measure to the improved methods which naturally follow where many cases of the same kind are operated upon in the same clinic.

* A number of cases have been omitted, as the myomata were too small and as the operation was performed for some other cause.



INDEX OF CASES ARRANGED ACCORDING TO THEIR GYNECOLOGICAL NUMBERS.

This list does not include all the cases operated upon, but merely those that are more or less fully described in the text. The pathological and autopsy numbers are given in the accompanying lists.

PAGE	PAGE	PAGE
Gyn. No. 57..... 533	Gyn. No. 1249..... 530	Gyn. No. 1872..... 681
Gyn. No. 62..... 548	Gyn. No. 1258..... 505	Gyn. No. 1879..... 457
Gyn. No. 65..... 509, 533	Gyn. No. 1260..... 568	Gyn. No. 1916..... 570
Gyn. No. 69..... 464, 674	Gyn. No. 1317..... 572, 579, 585,	Gyn. No. 1946..... 384, 625
Gyn. No. 77..... 354, 423, 426	586	Gyn. No. 1949..... 504, 505
Gyn. No. 121..... 546	Gyn. No. 1329..... 449, 511	Gyn. No. 1966..... 448
Gyn. No. 143..... 504, 505	Gyn. No. 1373..... 504, 505	Gyn. No. 2005..... 445
Gyn. No. 182..... 504, 505	Gyn. No. 1379..... 505	Gyn. No. 2039..... 546, 548
Gyn. No. 213..... 504, 505	Gyn. No. 1383½..... 35, 451, 625	Gyn. No. 2042..... 435, 568
Gyn. No. 278..... 415	Gyn. No. 1405..... 504, 505	Gyn. No. 2052..... 448
Gyn. No. 288..... 505	Gyn. No. 1422..... 507	Gyn. No. 2070..... 661
Gyn. No. 301..... 579	Gyn. No. 1441..... 581	Gyn. No. 2073..... 376
Gyn. No. 337..... 77, 448	Gyn. No. 1455..... 346, 527, 570	Gyn. No. 2098..... 666
Gyn. No. 362..... 461, 546	Gyn. No. 1489..... 546, 568, 572,	Gyn. No. 2108..... 465
Gyn. No. 482..... 534	579, 587	Gyn. No. 2129..... 463, 658
Gyn. No. 515..... 570	Gyn. No. 1499..... 386, 664	Gyn. No. 2142..... 592
Gyn. No. 516..... 376, 504, 505	Gyn. No. 1551..... 448, 579, 580,	Gyn. No. 2158..... 448
Gyn. No. 562..... 419	586	Gyn. No. 2172..... 346
Gyn. No. 615..... 505	Gyn. No. 1558..... 234, 440	Gyn. No. 2182..... 587
Gyn. No. 659..... 382, 461	Gyn. No. 1576..... 554, 570	Gyn. No. 2183..... 585
Gyn. No. 660..... 555	Gyn. No. 1579..... 371	Gyn. No. 2189..... 570
Gyn. No. 694..... 16, 436, 449	Gyn. No. 1593..... 586	Gyn. No. 2291..... 572
Gyn. No. 701..... 11, 674	Gyn. No. 1610..... 71, 441, 574,	Gyn. No. 2432..... 270
Gyn. No. 706..... 562	575, 579, 587	Gyn. No. 2434..... 433, 652
Gyn. No. 729..... 674	Gyn. No. 1628..... 436	Gyn. No. 2500..... 547, 570
Gyn. No. 832..... 420	Gyn. No. 1637..... 348, 349	Gyn. No. 2570..... 9
Gyn. No. 858..... 546, 547	Gyn. No. 1664..... 436	Gyn. No. 2593..... 573, 587
Gyn. No. 891..... 465, 504, 505	Gyn. No. 1666..... 666	Gyn. No. 2598..... 548, 658
Gyn. No. 909..... 586	Gyn. No. 1672..... 511, 543, 625	Gyn. No. 2606..... 444
Gyn. No. 934..... 669	Gyn. No. 1682..... 366, 387, 436	Gyn. No. 2634..... 405
Gyn. No. 939..... 505	Gyn. No. 1685..... 451, 570	Gyn. No. 2658..... 314, 315
Gyn. No. 963..... 674	Gyn. No. 1691..... 288	Gyn. No. 2666..... 587
Gyn. No. 1033..... 510, 562	Gyn. No. 1703..... 678, 679	Gyn. No. 2691..... 7, 631
Gyn. No. 1039..... 376	Gyn. No. 1716..... 71, 574, 575,	Gyn. No. 2699..... 432, 658
Gyn. No. 1049..... 436	579, 587	Gyn. No. 2706..... 311, 387, 659
Gyn. No. 1069..... 288, 625	Gyn. No. 1752..... 541	Gyn. No. 2709½..... 443, 558
Gyn. No. 1112..... 508	Gyn. No. 1767..... 673, 674	Gyn. No. 2710..... 547, 661
Gyn. No. 1135..... 264	Gyn. No. 1782..... 288	Gyn. No. 2713..... 451, 630, 674
Gyn. No. 1150..... 572, 587	Gyn. No. 1787..... 447	Gyn. No. 2744..... 453
Gyn. No. 1151..... 448	Gyn. No. 1821..... 570	Gyn. No. 2746..... 132
Gyn. No. 1173..... 416, 540	Gyn. No. 1852..... 463, 670	Gyn. No. 2754..... 374
Gyn. No. 1212..... 449, 547	Gyn. No. 1862..... 535	Gyn. No. 2763a..... 356, 462

PAGE		PAGE		PAGE	
Gyn. No. 2772	448, 462, 547	Gyn. No. 3394	436	Gyn. No. 4193	603, 604
Gyn. No. 2777	367	Gyn. No. 3408	332	Gyn. No. 4203	323, 447
Gyn. No. 2800	302, 436	Gyn. No. 3416	462	Gyn. No. 4252	359
Gyn. No. 2806	463, 661	Gyn. No. 3418	302	Gyn. No. 4262	287
Gyn. No. 2822	306	Gyn. No. 3426	436, 581	Gyn. No. 4285	457
Gyn. No. 2838	448	Gyn. No. 3437	324, 457	Gyn. No. 4297	509
Gyn. No. 2852	124, 317, 325	Gyn. No. 3440	436, 464, 631	Gyn. No. 4314	77
Gyn. No. 2873	71, 573, 575, 581	Gyn. No. 3444	451	Gyn. No. 4330	365
Gyn. No. 2881	11	Gyn. No. 3445	370, 657, 666	Gyn. No. 4341	132
Gyn. No. 2899	378, 381, 382, 436	Gyn. No. 3449	158, 314, 436, 661	Gyn. No. 4364	129, 132
Gyn. No. 2902	457	Gyn. No. 3461	254	Gyn. No. 4365	517
Gyn. No. 2919	306, 658	Gyn. No. 3488	158	Gyn. No. 4369	666
Gyn. No. 3008	8, 308, 313, 320, 349, 674	Gyn. No. 3490	398	Gyn. No. 4370	387, 441
Gyn. No. 3014	126, 132	Gyn. No. 3491	307	Gyn. No. 4372	666
Gyn. No. 3038	318, 321, 327	Gyn. No. 3492	318, 654, 668, 669	Gyn. No. 4382	435, 571, 579
Gyn. No. 3066	448, 453, 573, 574	Gyn. No. 3493	298, 441, 674, 676	Gyn. No. 4415	89, 511, 554, 555
Gyn. No. 3107	84	Gyn. No. 3504½	105	Gyn. No. 4441	441
Gyn. No. 3111	308, 448	Gyn. No. 3508	582	Gyn. No. 4471	527
Gyn. No. 3113	76, 123, 247, 291, 317, 329, 371, 385, 438, 466	Gyn. No. 3535	661	Gyn. No. 4485	116
Gyn. No. 3119	630	Gyn. No. 3538	18	Gyn. No. 4517	559
Gyn. No. 3130	132, 328	Gyn. No. 3583	449	Gyn. No. 4526	448
Gyn. No. 3133	76, 164, 166, 304, 307, 324, 332, 376, 379, 387	Gyn. No. 3590	371, 385	Gyn. No. 4537	552
Gyn. No. 3154	443	Gyn. No. 3600	511	Gyn. No. 4599	377, 451
Gyn. No. 3198	469, 674	Gyn. No. 3614	312, 663, 664	Gyn. No. 4607	265
Gyn. No. 3199	154, 302, 449	Gyn. No. 3614	312, 663, 664	Gyn. No. 4609	358, 673, 674
Gyn. No. 3209	322	Gyn. No. 3603	489	Gyn. No. 4617	436, 666
Gyn. No. 3216	86, 137, 320	Gyn. No. 3774	436	Gyn. No. 4635	603
Gyn. No. 3218	314	Gyn. No. 3778	132	Gyn. No. 4663	572, 586
Gyn. No. 3232	323, 324	Gyn. No. 3842	50, 372	Gyn. No. 4699	465
Gyn. No. 3272	382	Gyn. No. 3844	132	Gyn. No. 4731	441, 623
Gyn. No. 3281	319, 380, 436	Gyn. No. 3882	674, 676	Gyn. No. 4732	341
Gyn. No. 3293	315	Gyn. No. 3985	132	Gyn. No. 4761	368
Gyn. No. 3294	354	Gyn. No. 3898	674, 675	Gyn. No. 4771	352
Gyn. No. 3295	248, 280, 585	Gyn. No. 3918	661	Gyn. No. 4794	579
Gyn. No. 3296	19, 154, 355	Gyn. No. 3950	17, 132	Gyn. No. 4801½	130, 132, 460
Gyn. No. 3319	335, 336, 371	Gyn. No. 3960	317, 349	Gyn. No. 4814	570
Gyn. No. 3320	165, 166, 332, 659	Gyn. No. 3971	55, 379	Gyn. No. 4828	386, 449, 619
Gyn. No. 3338	449, 630	Gyn. No. 3974	18	Gyn. No. 4832	366, 603
Gyn. No. 3340	132, 333, 436, 603	Gyn. No. 3977	654, 681	Gyn. No. 4844	509, 568, 579
Gyn. No. 3345	102	Gyn. No. 3985	3	Gyn. No. 4856	525
Gyn. No. 3349	104, 303	Gyn. No. 3991	97	Gyn. No. 4869	359, 657
Gyn. No. 3353	449	Gyn. No. 3997	654	Gyn. No. 4870	631
Gyn. No. 3357	158	Gyn. No. 4016	449, 527	Gyn. No. 4873	548
Gyn. No. 3385	320, 321, 431	Gyn. No. 4020	348, 349, 368, 369	Gyn. No. 4877	456
Gyn. No. 3387	33, 469	Gyn. No. 4022	352, 368, 369, 668	Gyn. No. 4894	668
		Gyn. No. 4055	511, 546, 570	Gyn. No. 4902	666, 668
		Gyn. No. 4097	387, 631	Gyn. No. 4903	456, 666
		Gyn. No. 4160	132, 570	Gyn. No. 4925	77, 511, 519, 562
		Gyn. No. 4165	587	Gyn. No. 4929	546
		Gyn. No. 4168	380, 448	Gyn. No. 4955	327, 665, 666
		Gyn. No. 4172	659	Gyn. No. 4959	446
				Gyn. No. 4965	335, 336

PAGE		PAGE		PAGE	
Gyn. No. 4967	462, 575	Gyn. No. 5826	511, 552,	Gyn. No. 6521	447, 677
Gyn. No. 4972	448		554, 568	Gyn. No. 6570	78
Gyn. No. 4975	132	Gyn. No. 5843	441	Gyn. No. 6582	370
Gyn. No. 4990	529	Gyn. No. 5846	439, 560	Gyn. No. 6604	576, 579, 587
Gyn. No. 5010	10, 453, 678	Gyn. No. 5858	283, 658,	Gyn. No. 6607	387, 388
Gyn. No. 5014	387, 388, 448		674, 676	Gyn. No. 6610	388
Gyn. No. 5076	500	Gyn. No. 5871	462	Gyn. No. 6615	453
Gyn. No. 5081	530	Gyn. No. 5871½	579	Gyn. No. 6628	463
Gyn. No. 5086	511	Gyn. No. 5873	554	Gyn. No. 6667	320, 337, 367
Gyn. No. 5092	398, 461	Gyn. No. 5907	252	Gyn. No. 6722	452, 463, 621
Gyn. No. 5093	603	Gyn. No. 5943	441	Gyn. No. 6724	222, 546, 547
Gyn. No. 5103	363, 626	Gyn. No. 5946	78, 329, 330,	Gyn. No. 6760	566, 570
Gyn. No. 5123	461, 639		375, 436	Gyn. No. 6762	510, 550
Gyn. No. 5124	542	Gyn. No. 5957	284	Gyn. No. 6773	525, 569
Gyn. No. 5133	585	Gyn. No. 5965	569	Gyn. No. 6774	44
Gyn. No. 5141	355, 441	Gyn. No. 5987	391	Gyn. No. 6781	508
Gyn. No. 5153	507, 517	Gyn. No. 5993	147	Gyn. No. 6791	625
Gyn. No. 5193	623	Gyn. No. 6002	85, 587	Gyn. No. 6792	465, 622, 669
Gyn. No. 5239	603	Gyn. No. 6017	379, 451, 679	Gyn. No. 6833	132, 579, 587
Gyn. No. 5242	574, 586	Gyn. No. 6036	603	Gyn. No. 6843	59, 452
Gyn. No. 5249	391	Gyn. No. 6039	603	Gyn. No. 6855	68, 439, 578,
Gyn. No. 5277	603	Gyn. No. 6045	223		587
Gyn. No. 5279	507	Gyn. No. 6047	507	Gyn. No. 6863	355, 368
Gyn. No. 5289	448	Gyn. No. 6070	569	Gyn. No. 6915	362, 372, 622,
Gyn. No. 5296	574, 579, 587	Gyn. No. 6129	354, 462		632, 666
Gyn. No. 5302	390, 674, 676	Gyn. No. 6143	587	Gyn. No. 6933	669
Gyn. No. 5303	132, 568	Gyn. No. 6145	570	Gyn. No. 6950	570
Gyn. No. 5325	387, 603	Gyn. No. 6169	299	Gyn. No. 6972	603
Gyn. No. 5332	510	Gyn. No. 6178	370, 623	Gyn. No. 6991	336, 464
Gyn. No. 5359	510, 546,	Gyn. No. 6185	422, 426, 582	Gyn. No. 6997	609, 681
	550, 553	Gyn. No. 6190	355	Gyn. No. 7010	587
Gyn. No. 5421	376	Gyn. No. 6198	441, 619	Gyn. No. 7011	464
Gyn. No. 5447	509, 512, 520	Gyn. No. 6199	391	Gyn. No. 7014	452
Gyn. No. 5452	509, 517, 546	Gyn. No. 6206	622	Gyn. No. 7025	509
Gyn. No. 5493	507, 509, 520	Gyn. No. 6217	677	Gyn. No. 7029	509
Gyn. No. 5496	252, 579, 586	Gyn. No. 6240	442	Gyn. No. 7036	566, 679
Gyn. No. 5528	295, 348	Gyn. No. 6272	32, 453, 626	Gyn. No. 7040	212
Gyn. No. 5560	553	Gyn. No. 6324	42	Gyn. No. 7049	108, 372, 385
Gyn. No. 5588	547	Gyn. No. 6330	270	Gyn. No. 7050	571, 579
Gyn. No. 5614	509	Gyn. No. 6344	347, 348, 382	Gyn. No. 7063	343, 376
Gyn. No. 5617	148, 307, 678	Gyn. No. 6372	603, 666	Gyn. No. 7064	355, 368,
Gyn. No. 5622	579	Gyn. No. 6376	446		620, 621
Gyn. No. 5635	252, 558	Gyn. No. 6381	338, 446	Gyn. No. 7073	559, 570
Gyn. No. 5638	536	Gyn. No. 6395	507, 517	Gyn. No. 7086	264
Gyn. No. 5644	78	Gyn. No. 6407	257	Gyn. No. 7102	415
Gyn. No. 5647	372	Gyn. No. 6418	33, 381	Gyn. No. 7120	622
Gyn. No. 5687	572, 587	Gyn. No. 6432	116, 464	Gyn. No. 7133	71, 575
Gyn. No. 5697	371, 391	Gyn. No. 6433	61	Gyn. No. 7158	150, 456,
Gyn. No. 5734	306, 351,	Gyn. No. 6439	408		673, 674
	352, 623	Gyn. No. 6441	446, 451,	Gyn. No. 7159	509, 568
Gyn. No. 5752	33		579, 587	Gyn. No. 7181	385, 636, 637
Gyn. No. 5766	666	Gyn. No. 6474	550, 555	Gyn. No. 7212	212
Gyn. No. 5784	27, 78	Gyn. No. 6479	130, 132,	Gyn. No. 7216	452
Gyn. No. 5801	548		332, 348	Gyn. No. 7218	370
Gyn. No. 5808	333	Gyn. No. 6508	648		

	PAGE		PAGE		PAGE
Gyn. No. 7220	21, 437,	Gyn. No. 8008	439, 636	Gyn. No. 8804	454, 456, 584
	508, 546	Gyn. No. 8024	363, 681	Gyn. No. 8831	587
Gyn. No. 7226	44, 158, 366	Gyn. No. 8089	547	Gyn. No. 8836	229, 373, 684
Gyn. No. 7237	354, 631,	Gyn. No. 8106	441	Gyn. No. 8844	439, 509, 546
	663, 664	Gyn. No. 8114	394	Gyn. No. 8866	356
Gyn. No. 7240	58, 452,	Gyn. No. 8115	387	Gyn. No. 8872	684
	657, 658, 660	Gyn. No. 8147	414	Gyn. No. 8882	112
Gyn. No. 7263	496	Gyn. No. 8159	571, 587	Gyn. No. 8807	531
Gyn. No. 7266	452, 621	Gyn. No. 8183	681	Gyn. No. 8936	60, 454,
Gyn. No. 7276	621	Gyn. No. 8197	465		455, 565
Gyn. No. 7295	452, 463	Gyn. No. 8220	336	Gyn. No. 8943	449
Gyn. No. 7313	67, 195, 355	Gyn. No. 8251	496	Gyn. No. 8951	454, 670
Gyn. No. 7330	654	Gyn. No. 8259	548, 661	Gyn. No. 8963	455
Gyn. No. 7361	439, 680	Gyn. No. 8264	391	Gyn. No. 8985	341, 342
Gyn. No. 7381	669, 681	Gyn. No. 8266	449	Gyn. No. 8990	342
Gyn. No. 7383	69, 572	Gyn. No. 8270	127, 132	Gyn. No. 9004	266
Gyn. No. 7438	453, 465	Gyn. No. 8294	668	Gyn. No. 9012	290
Gyn. No. 7441	441	Gyn. No. 8306	460, 603	Gyn. No. 9013	448
Gyn. No. 7460	436, 461, 659	Gyn. No. 8310	508	Gyn. No. 9024	511, 569
Gyn. No. 7474	208, 621, 683	Gyn. No. 8321	382, 666	Gyn. No. 9027	43
Gyn. No. 7511	93	Gyn. No. 8354	319, 320,	Gyn. No. 9029	603
Gyn. No. 7528	355		330, 461	Gyn. No. 9030	346, 496, 679
Gyn. No. 7549	65, 69, 142,	Gyn. No. 8368	328, 451	Gyn. No. 9057	376, 437
	461, 613	Gyn. No. 8371	362	Gyn. No. 9078	45, 456
Gyn. No. 7560	536, 658	Gyn. No. 8389	511, 550, 554		463, 603
Gyn. No. 7566	558	Gyn. No. 8391	380, 381	Gyn. No. 9090	351, 494
Gyn. No. 7569	452, 453,	Gyn. No. 8410	64, 586	Gyn. No. 9107	502
	665, 666	Gyn. No. 8415	510, 562	Gyn. No. 9118	237, 507, 511
Gyn. No. 7583	376, 623	Gyn. No. 8437	371	Gyn. No. 9132	326, 683
Gyn. No. 7597	381	Gyn. No. 8462	447, 516,	Gyn. No. 9137	576, 587
Gyn. No. 7600	440		517, 550	Gyn. No. 9138	451
Gyn. No. 7604	220, 685	Gyn. No. 8476	546, 547	Gyn. No. 9141	289
Gyn. No. 7615	64, 300, 454	Gyn. No. 8477	244	Gyn. No. 9196	585
Gyn. No. 7630	365, 370, 452	Gyn. No. 8495	60, 452,	Gyn. No. 9197	509
Gyn. No. 7688	452, 462		460, 656	Gyn. No. 9203	60, 454, 565
Gyn. No. 7695	78	Gyn. No. 8514	465	Gyn. No. 9215	570
Gyn. No. 7696	603	Gyn. No. 8517	587	Gyn. No. 9221	547
Gyn. No. 7699	280, 329, 585	Gyn. No. 8526	354	Gyn. No. 9243	342, 526, 568
Gyn. No. 7703	603, 658,	Gyn. No. 8593	683	Gyn. No. 9286	603
	661, 662	Gyn. No. 8600	587	Gyn. No. 9304	546
Gyn. No. 7721	570	Gyn. No. 8610	231, 360	Gyn. No. 9329	555, 568, 569
Gyn. No. 7739	49, 619, 631	Gyn. No. 8667	465	Gyn. No. 9439	562
Gyn. No. 7753	550	Gyn. No. 8675	348	Gyn. No. 9443	277
Gyn. No. 7775	132, 345, 346	Gyn. No. 8690	619	Gyn. No. 9457	348, 349,
Gyn. No. 7779	563	Gyn. No. 8693	334		379, 462
Gyn. No. 7795	132, 325, 342	Gyn. No. 8698	447, 570	Gyn. No. 9470	569
Gyn. No. 7819	267	Gyn. No. 8705	603	Gyn. No. 9527	603
Gyn. No. 7849	342	Gyn. No. 8713	363, 465, 684	Gyn. No. 9536	180, 683
Gyn. No. 7859	359, 452, 660	Gyn. No. 8726	509	Gyn. No. 9540	40
Gyn. No. 7863	674	Gyn. No. 8732	130, 132,	Gyn. No. 9593	451, 454,
Gyn. No. 7872	570		215, 674		455, 456
Gyn. No. 7886	548, 564, 661	Gyn. No. 8738	309, 390	Gyn. No. 9608	498
Gyn. No. 7889	130, 132	Gyn. No. 8764	554, 555	Gyn. No. 9629	517
Gyn. No. 7978	521	Gyn. No. 8767	146	Gyn. No. 9636	336
Gyn. No. 7992	295	Gyn. No. 8773	517, 553	Gyn. No. 9637	434, 435, 507

	PAGE		PAGE		PAGE
Gyn. No. 9638	572	Gyn. No. 10440	488	Gyn. No. 11422	370
Gyn. No. 9652	435, 681	Gyn. No. 10453	604	Gyn. No. 11428	341
Gyn. No. 9674	51	Gyn. No. 10462	279	Gyn. No. 11472	604
Gyn. No. 9675	360, 680	Gyn. No. 10479	509, 568	Gyn. No. 11572	157
Gyn. No. 9678	451, 454, 609	Gyn. No. 10486	677	Gyn. No. 11587	376
Gyn. No. 9694	387	Gyn. No. 10490	486, 487	Gyn. No. 11630	350
Gyn. No. 9707	327, 451, 454, 457	Gyn. No. 10491	351, 495	Gyn. No. 11634	622
Gyn. No. 9736	496, 654	Gyn. No. 10497	548	Gyn. No. 11647	388
Gyn. No. 9767	352	Gyn. No. 10555	445, 495, 663, 664	Gyn. No. 11681	604
Gyn. No. 9769	63, 452	Gyn. No. 10558	604	Gyn. No. 11688	604
Gyn. No. 9780	56	Gyn. No. 10573	517, 555	Gyn. No. 11694	152
Gyn. No. 9786	31, 451, 454, 455, 457	Gyn. No. 10580	604	Gyn. No. 11722	604
Gyn. No. 9788	603	Gyn. No. 10587	526, 547	Gyn. No. 11792	133
Gyn. No. 9798	57, 376, 594	Gyn. No. 10588	518, 537, 538	Gyn. No. 11869	669
Gyn. No. 9818	603	Gyn. No. 10593	681	Gyn. No. 11889	454, 455, 572, 577, 579, 587
Gyn. No. 9843	603	Gyn. No. 10618	457, 579, 589	Gyn. No. 11898	15, 128, 133
Gyn. No. 9875	572, 587	Gyn. No. 10635	579, 587	Gyn. No. 11919	625
Gyn. No. 9924	94, 449	Gyn. No. 10667	604	Gyn. No. 11927	435
Gyn. No. 9928	451, 603	Gyn. No. 10669	363, 674	Gyn. No. 11944	232, 442, 443, 451, 501
Gyn. No. 9934	293	Gyn. No. 10749	391, 674, 675	Gyn. No. 11949	258
Gyn. No. 9953	445	Gyn. No. 10778	667	Gyn. No. 11984	462, 604
Gyn. No. 9971	658	Gyn. No. 10872	572, 586	Gyn. No. 11989	88, 383
Gyn. No. 10059	546, 547	Gyn. No. 10875	346, 667	Gyn. No. 12000	392, 448
Gyn. No. 10085	291	Gyn. No. 10916	307, 373	Gyn. No. 12021	329
Gyn. No. 10095	349, 681, 682	Gyn. No. 10917	346	Gyn. No. 12028	555, 569
Gyn. No. 10102	352	Gyn. No. 10969	436, 659	Gyn. No. 12034	346, 527
Gyn. No. 10161	660	Gyn. No. 10983	547, 549	Gyn. No. 12036	440, 462, 511
Gyn. No. 10172	454, 455	Gyn. No. 10991	376	Gyn. No. 12041	348
Gyn. No. 10183	560	Gyn. No. 10995	594	Gyn. No. 12056	263
Gyn. No. 10194	657	Gyn. No. 10997	281	Gyn. No. 12079	579, 586
Gyn. No. 10199	451, 666	Gyn. No. 11000	568	Gyn. No. 12086	306, 604
Gyn. No. 10204	373, 381, 496, 669	Gyn. No. 11010	572	Gyn. No. 12119	336
Gyn. No. 10211	666	Gyn. No. 11013	373, 377, 457	Gyn. No. 12139	257, 302, 619
Gyn. No. 10220	278	Gyn. No. 11052	546, 547, 555	Gyn. No. 12154	449, 451, 665, 667
Gyn. No. 10229	666	Gyn. No. 11067	78, 462	Gyn. No. 12155	200, 332, 461
Gyn. No. 10237	340, 341	Gyn. No. 11110	539	Gyn. No. 12165	452, 527
Gyn. No. 10257	518, 568	Gyn. No. 11111	569	Gyn. No. 12185	604
Gyn. No. 10281	666	Gyn. No. 11133	497	Gyn. No. 12194	49, 669
Gyn. No. 10287	669	Gyn. No. 11139	454	Gyn. No. 12199	666, 667
Gyn. No. 10300	517, 547, 548	Gyn. No. 11169	518	Gyn. No. 12209	674, 675
Gyn. No. 10314	155, 578, 579	Gyn. No. 11180	366, 669, 681, 682	Gyn. No. 12216	135, 435, 447, 677
Gyn. No. 10323	666	Gyn. No. 11216	604	Gyn. No. 12221	302, 303
Gyn. No. 10337	426, 427	Gyn. No. 11217	604	Gyn. No. 12234	332, 451, 452, 454
Gyn. No. 10351	509, 510, 517, 537	Gyn. No. 11224	74	Gyn. No. 12257	572, 579, 587
Gyn. No. 10357	604, 666	Gyn. No. 11243	446, 572, 587	Gyn. No. 12291	465
Gyn. No. 10376	183, 572, 579, 580	Gyn. No. 11251	463	Gyn. No. 12293	376, 452
Gyn. No. 10394	509, 546, 547, 550	Gyn. No. 11256	511, 549	Gyn. No. 12297	260
Gyn. No. 10403	2	Gyn. No. 11293	266	Gyn. No. 12301	604
Gyn. No. 10426	669	Gyn. No. 11294	661	Gyn. No. 12323	577
		Gyn. No. 11296	542	Gyn. No. 12369	449, 463, 604
		Gyn. No. 11337	426, 427, 454, 455		
		Gyn. No. 11392	449, 463, 604		

	PAGE		PAGE		PAGE
Gyn. No. 12380	342	Gyn. No. 14709	30	C. H. I., F.	461
Gyn. No. 12439	660	Gyn. No. 14942	145	C. H. I., A.	464
Gyn. No. 12452	460	Gyn. No. 15252	687	C. H. I., S.	468
Gyn. No. 12488	604	Gyn. No. 15281	139	C. H. I., M.	469
Gyn. No. 12490	323	Gyn. No. 15283	51	C. H. I., Dr. Ernest John-	
Gyn. No. 12504	555, 556	Gyn. No. 15477	687	ston's Case	480
Gyn. No. 12520	387	B. H., Dec. 5, 1908	362	C. H. I., P. June 17, 1906	485
Gyn. No. 12522	103, 604	San. No. 471	240	C. H. I., S. Feb. 1904	500
Gyn. No. 12525	604	San. No. 581	256	C. H. I., B.	509
Gyn. No. 12583	547, 552	San. No. 577	249	C. H. I., S.	509
Gyn. No. 12585	511	San. No. 836	163	C. H. I., B.	510
Gyn. No. 12587	648, 674, 680, 682	San. No. 858	339	C. H. I., S.	512
Gyn. No. 12591	491, 571, 586	San. No. 941	87	C. H. I., H.	517
Gyn. No. 12611	681	San. No. 1011	101	C. H. I., W.	544
Gyn. No. 12656	417	San. No. 1049	374, 436, 631	C. H. I., S. June 9, 1903	551
Gyn. No. 12681	438, 439	San. No. 1058	363	C. H. I., G.	565
Gyn. No. 12689	563	San. No. 1497	587	C. H. I., Peth.	569
Gyn. No. 12696	604, 661	San. No. 1530	2	C. H. I., J.	587
Gyn. No. 12709	81	San. No. 1545	568	C. H. I., S. Dec. 15, 1906	588
Gyn. No. 12725	270, 459	San. No. 1566	677	C. H. I., R.	594
Gyn. No. 12738	668	San. No. 1593	586	C. H. I., H. Mar. 16, 1903	621
Gyn. No. 12764	604, 661	San. No. 1682	680	C. H. I., K. Mar. 14, 1903	637
Gyn. No. 12779	133, 388	San. No. 1691	604	C. H. I., H.	636
Gyn. No. 12788	243	San. No. 1702	604	C. H. I., H. June, 1903	664
Gyn. No. 12811	446, 667	San. No. 1773	604	C. H. I., A.	667
Gyn. No. 12841	387	San. No. 1837	454, 456	C. H. I., W.	667
Gyn. No. 12852	509, 525	San. No. 1847	149	C. H. I., K.	674
Gyn. No. 12864	97, 239, 373, 436	San. No. 1852	280	C. H. I., No. 78	184
Gyn. No. 12866	336, 341, 384	San. No. 1857	206	C. H. I., No. 382	604
Gyn. No. 12890	454	San. No. 1868	454	C. H. I., No. 392	452, 604
Gyn. No. 12902	649	San. No. 1872	300, 360, 681	C. H. I., No. 409	587
Gyn. No. 12912	346	San. No. 1879	204	C. H. I., No. 495	38
Gyn. No. 12937	604	San. No. 1924	94, 356	C. H. I., No. 511	681, 682
Gyn. No. 12944	604	San. No. 1925	108	C. H. I., No. 620	105, 604, 650
Gyn. No. 12964	452	San. No. 1944	454, 663	C. H. I., No. 673	604
Gyn. No. 13014	579, 587	San. No. 1973	259	C. H. I., No. 686	260
Gyn. No. 13015	271	San. No. 2142	592	C. H. I., No. 728	455
Gyn. No. 13016	376, 449, 681, 682	San. No. 2144	604	C. H. I., No. 793	463
Gyn. No. 13025	362, 452	San. No. 2164	604	C. H. I., No. 930	525
Gyn. No. 13039	23, 452, 453, 604	San. No. 2178	564	C. H. I., No. 949	381, 604, 624
Gyn. No. 13056	263	San. No. 2189	133	C. H. I., B. No. 1019	509, 510, 525
Gyn. No. 13067	74	San. No. 2368	339	C. H. I., C. Aug. 12, 1902	81
Gyn. No. 13204	482	C. H. I., P.	35	C. H. I., No. 1095	604
Gyn. No. 13272	474	C. H. I., R. Oct. 25, 1902	62	C. H. I., No. 1201	587
Gyn. No. 13423	121	C. H. I., C. Aug. 12, 1902	81	C. H. I., No. 1205	439
Gyn. No. 13498	487, 488	C. H. I., W. Jan. 22, 1903	190, 442, 464, 511	C. H. I., No. 1552	625
Gyn. No. 13625	118	C. H. I., K.	286	C. H. I., No. 1552	625
Gyn. No. 13626	438	C. H. I., B.	355	Case C., Hagerstown, Md.	24
Gyn. No. 13629	368	C. H. I., MeA.	362, 436, 512, 555	Mrs. B., Frederick Emer- gency Hospital, Oct. 30,	
Gyn. No. 14373	310	C. H. I., F. Aug. 10, 1902	120, 375	1904	24
Gyn. No. 14662	687	C. H. I., R. Oct. 24, 1902	382	Dr. J. Mason Hundley's	
		C. H. I., B. April 28, 1904	436	case	47
				C. G., Hagerstown, Md.	50

	PAGE	PAGE	PAGE
Dr. Curtis Burnham's case	70	Case O., Hebrew Hospital	451
Professor Raffaele Bastianelli's case	79	A. P., Cambridge Hospital, March 4, 1906	470
Dr. George E. Holtzapple's case	130	Dr. T. A. Erek's case (Philadelphia)	477
Dr. Houston, Troy, N. Y., case	144	Dr. James Bosley's case	493
Dr. Hunner's case	175	U. P. I.	517
Dr. Paul Owsley's case	276	S. (Toronto), June, 1903	534
Dr. Homer Gage's case	335	Case G., Frederick	531
		O., Hebrew Hospital	551
		U. P. I., G.	565
		J. (Kelly), Dec. 9, 1899	588
		A. W., Cambridge, Md., Hospital, May 24, 1905	641
		Dr. E. W. Meisenhelder, York, Pa., Jan. 2, 1903	686
		Dr. Stansbury Sutton	643,
			644
		Dr. Geo. Ben Johnston	645,
			646



PATHOLOGICAL NUMBERS.

This list includes only those cases that are more or less fully discussed in the text. The genealogical numbers and the autopsy numbers are given in the accompanying lists.

	PAGE		PAGE		PAGE
Path. No. 101	270	Path. No. 591	312	Path. No. 1307	358
Path. No. 119	270	Path. No. 592	309, 336	Path. No. 1318	358
Path. No. 162	9	Path. No. 605	144	Path. No. 1327	66, 68
Path. No. 178	68	Path. No. 607	5, 132, 333	Path. No. 1382	326
Path. No. 186	433, 652	Path. No. 610	104, 303	Path. No. 1392	132
Path. No. 196	309	Path. No. 616	102	Path. No. 1434	359
Path. No. 204	405	Path. No. 618	158	Path. No. 1484	327
Path. No. 213	314, 315	Path. No. 634	320, 321, 431	Path. No. 1499	336
Path. No. 222	405	Path. No. 641	33	Path. No. 1500	132
Path. No. 245	311	Path. No. 659	332	Path. No. 1521	529
Path. No. 246	432	Path. No. 661	302	Path. No. 1536	10
Path. No. 250	309	Path. No. 674	5, 7	Path. No. 1599	147
Path. No. 259	5	Path. No. 682	254	Path. No. 1628	529
Path. No. 265½	7	Path. No. 683	158, 314	Path. No. 1631	398
Path. No. 266	68	Path. No. 707	158	Path. No. 1750	68
Path. No. 276	132	Path. No. 711	318	Path. No. 1755	132
Path. No. 286	356	Path. No. 713	307	Path. No. 1815	240
Path. No. 312	5, 302	Path. No. 715	298	Path. No. 1899	252
Path. No. 347	124, 317, 325	Path. No. 719	105	Path. No. 1962	148, 307
Path. No. 359	4, 7	Path. No. 740	643, 644	Path. No. 1973	252
Path. No. 380	306	Path. No. 742	18	Path. No. 1990	628
Path. No. 435	8, 308, 313, 320	Path. No. 788	312	Path. No. 2034	306, 351
Path. No. 443	126, 132	Path. No. 828	489	Path. No. 2055	53
Path. No. 452	318, 321, 327	Path. No. 872	132	Path. No. 2101	333
Path. No. 460	68	Path. No. 910	132	Path. No. 2146	283
Path. No. 472	84	Path. No. 964	5	Path. No. 2222	252
Path. No. 479	5, 308, 309	Path. No. 970	132	Path. No. 2238	284
Path. No. 487	76, 123, 317, 329, 247, 294	Path. No. 971	318, 349	Path. No. 2242	329, 330
Path. No. 494	76, 164, 166, 303, 304, 305, 307, 324, 332	Path. No. 977	55	Path. No. 2275	85
Path. No. 499	5, 132, 328	Path. No. 980	18	Path. No. 2311	223
Path. No. 524	5, 154, 302, 318	Path. No. 986	3, 132	Path. No. 2314	223
Path. No. 533	313, 469	Path. No. 990	97	Path. No. 2372	256
Path. No. 534	86, 137, 320	Path. No. 1009	369	Path. No. 2402	249
Path. No. 539	314	Path. No. 1012	369	Path. No. 2413	68
Path. No. 540	322	Path. No. 1084	132	Path. No. 2426	299
Path. No. 543	323, 324	Path. No. 1116	323	Path. No. 2441	68, 422, 582
Path. No. 573	319	Path. No. 1137	287	Path. No. 2530	32
Path. No. 580	19	Path. No. 1152	309	Path. No. 2538	306
Path. No. 582	248, 280	Path. No. 1165	132	Path. No. 2584	270
Path. No. 583	315	Path. No. 1170	129, 132	Path. No. 2592	347
Path. No. 589	5, 165, 166, 332	Path. No. 1207	89	Path. No. 2653	61
		Path. No. 1245	116	Path. No. 2661	116
		Path. No. 1304	265	Path. No. 2700	132, 332


	PAGE		PAGE		PAGE
Path. No. 2808	411	Path. No. 4878	499	Path. No. 7276	500
Path. No. 2900	320, 337	Path. No. 4898	334	Path. No. 7364	497
Path. No. 2946	222	Path. No. 4931	132, 215	Path. No. 7448	72, 74, 75
Path. No. 3052	566	Path. No. 4935	389, 390	Path. No. 7555	184
Path. No. 3075½	132	Path. No. 4959	146, 313	Path. No. 7800	157
Path. No. 3080	59	Path. No. 5032	229	Path. No. 7867	350
Path. No. 3170	632	Path. No. 5072	111, 112	Path. No. 7895	528, 531
Path. No. 3177	68	Path. No. 5159	341	Path. No. 7903	175
Path. No. 3277	336	Path. No. 5176	266	Path. No. 7925	24, 25
Path. No. 3312	212	Path. No. 5180	290	Path. No. 7933	155
Path. No. 3315	566	Path. No. 5223	266	Path. No. 8116	133
Path. No. 3318	108	Path. No. 5234	45, 47	Path. No. 8284	15, 128, 133
Path. No. 3354	343	Path. No. 5247	494	Path. No. 8297	68, 577
Path. No. 3373	264	Path. No. 5265	502	Path. No. 8325	645, 646
Path. No. 3390	264	Path. No. 5274	237	Path. No. 8346	149
Path. No. 3431	150	Path. No. 5286	326	Path. No. 8347	280
Path. No. 3472	212	Path. No. 5312	280	Path. No. 8349	206
Path. No. 3476	21	Path. No. 5378	60	Path. No. 8350	232
Path. No. 3486	44, 158, 159	Path. No. 5471	395	Path. No. 8351	258
Path. No. 3491	68, 69	Path. No. 5671	277	Path. No. 8370	190
Path. No. 3502	58	Path. No. 5730	180	Path. No. 8432	363, 364
Path. No. 3576	68, 195	Path. No. 5799	498	Path. No. 8445	88
Path. No. 3601	4	Path. No. 5816	131, 133	Path. No. 8447	392
Path. No. 3635	69	Path. No. 5825	336	Path. No. 8458	204
Path. No. 3673	67, 68, 195	Path. No. 5870	360, 361	Path. No. 8502	329
Path. No. 3674	316, 588	Path. No. 5912	327	Path. No. 8579	449
Path. No. 3703	162, 163	Path. No. 5982	63	Path. No. 8655	579
Path. No. 3706	339	Path. No. 5996	56	Path. No. 8714	336
Path. No. 3729	208	Path. No. 6013	57	Path. No. 8723	200, 332
Path. No. 3757	93	Path. No. 6046	120	Path. No. 8727	306
Path. No. 3799	65, 69, 142	Path. No. 6118	94, 96	Path. No. 8750	257
Path. No. 3865	220	Path. No. 6127	293	Path. No. 8776	49
Path. No. 3879	64, 300	Path. No. 6226	62	Path. No. 8824	94, 95
Path. No. 3948	248, 280, 329	Path. No. 6275	291	Path. No. 8825	135
Path. No. 4043	132, 345	Path. No. 6299	352	Path. No. 8827	105, 650
Path. No. 4055	132, 325	Path. No. 6418	278	Path. No. 8829	260
Path. No. 4074	267	Path. No. 6421	133, 190, 442,	Path. No. 8832	303
Path. No. 4090	353			Path. No. 8838	108
Path. No. 4113	87	Path. No. 6430	340	Path. No. 8844	332
Path. No. 4122	359	Path. No. 6479	2	Path. No. 8887	260
Path. No. 4136	132	Path. No. 6531	155	Path. No. 8932	152, 641
Path. No. 4252	359	Path. No. 6596	183	Path. No. 9129	259
Path. No. 4403	336	Path. No. 6618	2	Path. No. 9186	323
Path. No. 4453	132	Path. No. 6644	488	Path. No. 9233	103
Path. No. 4479	286	Path. No. 6685	279	Path. No. 9348	648
Path. No. 4508	101	Path. No. 6712	495	Path. No. 9349	491
Path. No. 4539	319, 320, 330	Path. No. 6727	486	Path. No. 9473	438
Path. No. 4554	328	Path. No. 6730	279	Path. No. 9502	270
Path. No. 4576	511	Path. No. 6811	276	Path. No. 9545	82
Path. No. 4593	64	Path. No. 6908	363	Path. No. 9546	270
Path. No. 4616	363	Path. No. 6920	54	Path. No. 9558	564
Path. No. 4672	244	Path. No. 7089	153	Path. No. 9642	133
Path. No. 4716	60	Path. No. 7162	307	Path. No. 9662	243
Path. No. 4823	231	Path. No. 7192	549	Path. No. 9755	336, 384
Path. No. 4851	480, 482	Path. No. 7246	281	Path. No. 9810	470

	PAGE		PAGE		PAGE
Path. No. 9840.....	649	Path. No. 10311.....	97, 99, 239	Path. No. 11191.....	339
Path. No. 10015.....	133	Path. No. 10382.....	512	Path. No. 11651.....	118
Path. No. 10033.....	271	Path. No. 10417.....	474	Path. No. 12090.....	310
Path. No. 10039.....	23	Path. No. 10494.....	492, 493	Path. No. 12618.....	28, 30
Path. No. 10076.....	73, 74	Path. No. 10677.....	121	Path. No. 12963.....	145
Path. No. 10077.....	263	Path. No. 10776.....	487	Path. No. 13121.....	139
Path. No. 10278.....	482	Path. No. 11044.....	70	Path. No. 13199.....	52



AUTOPSY NUMBERS.

	PAGE		PAGE		PAGE
Aut. No. 23.....	395	Aut. No. 610.....	395	Aut. No. 1503.....	221, 685
Aut. No. 48.....	533	Aut. No. 653....	395, 396, 397	Aut. No. 1593.....	395
Aut. No. 52.....	534	Aut. No. 666.....	674	Aut. No. 1605.....	414, 428
Aut. No. 55.....	674	Aut. No. 680.....	395	Aut. No. 1666.....	395
Aut. No. 69.....	395, 397, 423, 428	Aut. No. 682.....	395	Aut. No. 1689.....	442
Aut. No. 117....	395, 415, 428	Aut. No. 689....	395, 398, 428	Aut. No. 1703.....	395
Aut. No. 118.....	677	Aut. No. 700.....	395	Aut. No. 1734.....	674
Aut. No. 136....	395, 421, 428	Aut. No. 722.....	395	Aut. No. 1745.....	397
Aut. No. 172.....	419, 428	Aut. No. 742.....	681	Aut. No. 1754.....	395
Aut. No. 188....	382, 395, 397	Aut. No. 810.....	398, 428	Aut. No. 1809.....	683
Aut. No. 198.....	674	Aut. No. 901.....	395	Aut. No. 1823.....	395
Aut. No. 211....	420, 428	Aut. No. 908....	395, 396, 397, 678	Aut. No. 1869.....	395
Aut. No. 237.....	674	Aut. No. 926.....	398, 428	Aut. No. 1898.....	395, 428
Aut. No. 277....	395, 416, 428, 540	Aut. No. 954.....	390, 674	Aut. No. 1936.....	680
Aut. No. 288.....	396, 397	Aut. No. 994.....	396, 397	Aut. No. 2080.....	395
Aut. No. 322.....	395	Aut. No. 1085....	223, 395, 428	Aut. No. 2088....	395, 427, 428
Aut. No. 353.....	234	Aut. No. 1112....	397, 422, 428, 583	Aut. No. 2162.....	674
Aut. No. 385.....	674	Aut. No. 1220....	408, 428	Aut. No. 2202.....	395
Aut. No. 474....	395, 428	Aut. No. 1310....	395	Aut. No. 2230.....	395
Aut. No. 451.....	396, 397	Aut. No. 1337.....	395	Aut. No. 2293.....	681
Aut. No. 505.....	405, 428	Aut. No. 1363.....	395	Aut. No. 2319.....	427, 428
Aut. No. 519.....	395	Aut. No. 1371.....	428	Aut. No. 2404.....	395
Aut. No. 532.....	395	Aut. No. 1387.....	678	Aut. No. 2426.....	395
Aut. No. 561.....	674	Aut. No. 1407....	415, 428	Aut. No. 2558.....	393
Aut. No. 579.....	395	Aut. No. 1445....	680	Aut. No. 2651.....	674
Aut. No. 595.....	674			Aut. No. 2671.....	417, 428
				Aut. No. 2987.....	66



INDEX

- ABDOMINAL** cavity, bleeding into, after bi-manual examination for subperitoneal pedunculated myoma, 444
 irrigation of, after abdominal hysteromyectomy, 620
 passage of enema into, after hysteromyectomy, 391
- Abdominal contour** in myoma cases, 436
 hemorrhage, symptoms suggesting, after abdominal hysteromyectomy, 669
 hysteromyectomy, 588. *See also Hysteromyectomy, abdominal.*
 metastases with myosarcoma, 200
- Abdominal myomectomy**, 506. *See also Myomectomy, abdominal.*
 operations necessary subsequent to, 556
 pain after, 549
- Abdominal pregnancy**, myoma and, differentiation, 473-477
 veins, enlargement of, 437
- Abdominal walls**, lipoma of, associated with myoma, 461
 perforation of, by myosarcoma of uterus, 176
 thick, rendering hysteromyectomy difficult, 630
 vessels from, supplying nourishment to parasitic myoma, 51
- Abdominal wound**, suppuration of, after hysteromyectomy, 662
- Abscess** beneath broad ligament in myosarcoma of uterus, 196
 between intestines and omentum due to suppurating myoma, 139
 burrowing along vagina, 196
 of broad ligament after abdominal myomectomy, 553
 with myoma, 355
 of kidney with uterine myomata, 397, 422
 of lung after hysteromyectomy, 682
 of ovary with myoma, 344, 396, 637, 639
 omental, with uterine myoma, 637
 on surface of uterus due to perforation of suppurating interstitial myoma, 150
- Abscess**, pelvic, anterior to myomatous uterus, 636
- Abscess**, pelvic, evacuation of, after abdominal myomectomy, 559, 635
 myoma associated with, abdominal hysterectomy in, 635
 with myomata of uterus, 635
 perirectal, 391
 pulmonary, after abdominal hysteromyectomy, 669, 682
 tubo-ovarian, associated with myoma, 344, 396
 with carcinoma of body and myoma, 290
- Abscesses**, multiple, after abdominal hysteromyectomy, 664
- Accessory uterine artery**, almost fatal bleeding from, 623
- Adenocarcinoma of ovary**, associated with myoma, 348
 of uterus, associated with myoma, 274, 275, 276, 278
 early, associated with myoma, 294, 295
 with suspicious changes in myoma, 248
 extensive, overlooked at operation, 286
 following submucous myoma, 248
 growing into myoma, 405
 inspection of cavity for, 594
 myomectomy in case of, 416
 rare form of, 489
 with metastases, in lymph-glands 405, 414
 in left adrenal body, 408
 in liver, 408
 in lungs, 408
 in mesentery, 408
 in omentum, 405, 408
 in pancreas, 408
 in peritoneum, 405, 408
 in pleura, 408
 in spleen, 414
- Adenocarcinoma of uterus** with tubo-ovarian abscess, 290
- Adenocystoma of ovary** with uterine myoma, 346, 396, 417
- Adenomyoma of round ligaments** with myoma, 364
 of utero-ovarian ligament with myoma, 360
 of uterus, 167, 168

- Adenomyoma of uterus, abdominal myomec-
tomy for, 511
diffuse, in one horn of bicornate uterus,
157
removal of, per abdomen, 511
with apparently independent round-celled
sarcoma of uterus, 280
with double cervix and double vagina,
155
with squamous-celled carcinoma of cervix,
262
- Adhesions, appendiceal, affording blood-supply
to parasitic myoma, 39
between liver and myoma, 464
between myoma and rectum, 386
gradual absorption of, after abdominal
hysteromyomectomy, 641
in myoma cases, found at autopsy, 395
intestinal, 633
after abdominal myomectomy, 566
extensive, method of dealing with, 635
of bladder in myoma cases, rôle played by,
366
ovarian, release of, after abdominal myo-
mectomy, 556
to broad ligaments in myoma cases, 354
vesical, release of, after abdominal myo-
mectomy, 556
- Adipose tissue in myoma, 162, 166
- Adrenal body, metastases in, from adenocar-
cinoma of uterus, 408
- Anastomosis, uretero-ureteral, 383
intestinal, 635
- Anesthesia in abdominal hysteromyomectomy,
590
- Angiomyoma of uterus, 158
- Anus, artificial, with complete control, 190
- Appendicitis associated with myoma, 463
- Appendix, removal of, in myoma cases,
463
- Areas, raw, with abdominal hysteromyomec-
tomy, 619
- Artery, uterine, almost fatal bleeding from
accessory branch, during abdominal
hysteromyomectomy, 623
fatal hemorrhage from, due to absorption
of catgut, 681
passage of silk ligature from, into bladder,
375
tearing of, during abdominal myomec-
tomy, 525
- Asepsis associated with myoma, 30
- Autopsy, carcinoma of body of uterus and
myoma found at, 404
of cervix with uterine myoma
found at, 398
- Autopsy changes found in ureter associated
with myoma, 396
condition of Fallopian tubes in cases of
uterine myoma, 395
of ovaries in myoma cases, 395
findings in myoma cases, 394, 428
myosarcoma and myoma found at, 420
perforation of rectum found at, after hystero-
myomectomy, 390
- BALLOTTEMENT with uterine myoma, 469
- Bastianelli, Raffaele, 79
- Bed-sore following abdominal hysteromyomec-
tomy, 662
abdominal myomectomy, 555
- Bicornate uterus, diffuse adenomyoma in one
horn of, 157
- Bimanual examination of a subperitoneal
pedunculated myoma, bleeding into ab-
dominal cavity after, 444
- Bisection of uterus, 608. See also under *Hys-
teromyomectomy*.
dangers of, 181, 609
death after, 683
followed by intestinal obstruction, 683
for submucous myoma, 574
- Bladder, adhesions of, after abdominal myo-
mectomy, 556
rôle played by, in myoma cases, 366
adventitious vessels furnished by, 48
ascent of, with growth of myoma, 366
blood supply from, to parasitic myoma, 50
calculus in, associated with uterine myoma,
375
carcinoma of, secondary to cervical carcino-
ma, 401
displacement of, by myoma, 365, 368
full, simulated by encysted peritonitis, 371
in myoma cases, 365-377
inflammation of, after abdominal myomec-
tomy, 549
in myoma cases, 377
injury of, during removal of uterine myoma,
371
loss of control of, 376
manipulation of, in abdominal hysteromyo-
mectomy, 374
passage of silk ligature from uterine artery
into, 375
pressure on, by myoma, 365
retention of urine, 376
sacculatation of, in myoma cases, 370
sarcoma of, with uterine myoma, 420
spontaneous evacuation of broad ligament
abscess into, 553
symptoms attributable to myoma, 376

- Bladder wall, condition of, in myoma cases, 370
- Bleeder, constitutional, successful hysteromyomectomy on, 625
- Bleeding. *See Hemorrhage.*
- Bleeding, intermenstrual, in myoma cases, 444
into abdominal cavity on bimanual examination of subperitoneal pedunculated myoma, 444
- Blood in uterine cavity in myoma cases, 309
- Blood supply of myomata, 6
of parasitic myoma, 16, 38, 39, 41, 48
- Blood-vessels of broad ligament, dilatation of, with myoma, 354
of uterine mucosa, alterations in, with myoma, 317
- Bluish color of vaginal mucosa with myoma, 439
- Breasts, carcinoma of, associated with myoma, 450
colostrum in, with uterine myoma, 449
condition of, with uterine myoma, 449
in differential diagnosis of myoma and pregnancy, 467
tumors of, benign, with myoma, 450
- Broad ligament, abscess beneath, associated with myosarcoma of uterus, 196
abscess in, after removal of myoma, 553
associated with uterine myoma, 355
adhesions to, in myoma cases, 354
alterations in, associated with uterine myoma, 354
cyst in, 396
dilatation of blood-vessels of, with uterine myoma, 354
dilated lymph-spaces in, with myoma, 355
hematoma in, during abdominal hysteromyomectomy, 623
infection of, after abdominal hysteromyomectomy, 664
myoma of, 51, 53, 354, 510
abdominal myomectomy for, 510
secondary nodule in, from myosarcoma of uterus, 195
thickening of, with uterine myoma, 355
- Bronchial lymph-glands, metastases in, from adenocarcinoma of uterus, 405
from squamous-celled carcinoma of cervix, 399
- Bronchitis after abdominal hysteromyomectomy, 668
myomectomy, 554
- Bronchopneumonia after abdominal hysteromyomectomy, 668, 685
* myomectomy, 555
- 45
- CALCAREOUS nodules in mesentery, 464
plates in an arterial wall, 129
- Calcification of heart muscle associated with uterine myoma, 424
of myoma, 126, 130, 132, 133, 268
- Calcium salts, how deposited, in myoma, 127
- Calculus, uterine, with myoma, 130
vesical, associated with myoma, 375
- Capillaries, marked proliferation of endothelium of, in myoma, 99
- Carcinoma of body of uterus, unsuspected during abdominal myomectomy, 540
with myoma, detected at autopsy, 404
of breast, associated with myoma, 450
of cervix, associated with myoma, 262
found at autopsy, 398
early, with myoma, 269
stimulated by submucous myoma, 487
suspicion of, with myoma, 304
with primary carcinoma of ovary and myoma, 271
with sloughing submucous myoma, 398
- Carcinoma of Fallopian tube, secondary, with myoma, 396
of omentum, myoma and, differentiation, 499
of ovary, primary, with carcinoma of cervix and myoma, 271
with myoma, 396
with carcinoma of stomach, 396
of rectum, associated with uterine myoma, 391, 417
of uterus, associated with myoma, found at autopsy, 404
histological changes in myoma suggesting, 491
myoma and, differentiation, 485
secondary, with uterine myoma, 295
- Cardiac hyaline degeneration, with necrotic uterine myoma, 423
hypertrophy, with uterine myoma, 414, 423
lesions, possibly attributable to uterine myoma, 421
sounds in myoma cases, 451
- Cardinal vessels, clamping and application of ligatures later, 600
- Catgut, death following use of, in abdominal myomectomy, 541
too early absorption of, with fatal hemorrhage, after hysteromyomectomy, 681
- Cecum, suppurating myoma opening into, 46
- Cells in myoma, 9
- Cerebral embolus following abdominal myomectomy, 537
- Cervical endometritis with myoma, 302
glands, dilatation of, with myoma, 298
unfolding of, with myoma, 302

Cervical lips, edema of, with myoma, 441
 lymph-glands, metastases in, from adenocarcinoma of body of uterus, 297, 307
 Cervical mucosa, changes in, with myoma, 297, 307
 extensive removal of, during supravaginal hysteromyectomy, 604
 polyp of, with myoma, 298, 300
 Cervical myoma, 53
 abdominal myometery for, 510
 associated with adenocarcinoma of uterus, 278
 extensive, hysterectomy for, difficult, 58
 large, with adenocarcinoma of body, 289
 removal of, through abdomen, 510
 Cervical stump, rupture of, after abdominal hysteromyectomy, 599
 hemorrhage from secondary sarcoma in, 190
 return of myosarcoma in, 176, 190
 Cervix, almost obliterated, with myoma, 441
 atrophy of, associated with myoma, 78, 297
 carcinoma of, associated with myoma, 262, 305, 308
 simulated by submucous myoma, 487
 of myoma and primary carcinoma of ovary, 271
 with elongating submucous myoma, 398
 Cervix, closure of, after hysteromyectomy, 396
 condition of, in cases of myoma, 440
 double, associated with submucous adenomyoma, 155
 elongation of, with myoma, 441, 442
 hypertrophy of, with myoma, 297, 441
 in differential diagnosis of myoma and pregnancy, 467
 infection of, following abdominal hysteromyectomy, 604
 involvement of, by myoma, 57
 jammed down on perineum in myoma cases, 441
 normal, with myoma, 441
 pushed up behind symphysis in myoma cases, 441
 return of sarcoma in, 212
 torsion of, 77, 79
 transverse section of, as preliminary step in abdominal hysteromyectomy, 617
 Cervicium section with death four years after abdominal myometery, 572
 Chloëtic tendency, metastases in, from sarcoma of uterus, 222
 Chorio-epithelium simulating myomatous uterus, 487
 Lockscomb sarcoma on surface of uterus, 184
 Cyclic, renal, with myoma, 466
 Valon, suppurating subperitoneal myoma opening into, 142
 Transverse, descent of, with myoma, 463
 Cysto-tram in breasts with myoma, 449
 Cystic entrance of right ventricle, metastases in, following sarcoma of uterus, 222
 Constipation after abdominal hysteromyectomy, 639
 Tomy, 639
 with uterine myoma, 445
 Cervical pregnancy, ruptured, simulating myoma, 477
 Corpus luteum cysts with myoma, 346
 Gullon, Church Home cases, 671
 Cystadenoma, multilocular, of ovaries, with myoma, 346, 396, 417
 Cystic areas containing emulsified fat, 92, 124
 degeneration of myoma, 83, 92, 102, 111
 myoma, 112
 abdominal myometery for, 512
 diameter of fluid in, 91
 resembling heart cavity, 122
 resembling ovarian cyst, 111
 Cystitis, associated with myoma, 277
 following abdominal hysteromyectomy, 627
 following myometery, 549
 Cyst, corpus luteum, with uterine myoma, 346
 dermoid, of ovaries, with uterine myoma, 349
 formation, early, in myoma, 96
 Graafian follicle, with uterine myoma, 344
 in myosarcoma, 197, 198
 labial, with uterine myoma, 438
 large, due to hyaline degeneration in myoma, 96
 of ovary, bilateral, and myoma, differential, 498
 in myoma cases, 344
 myoma and, differentiation, 495
 papillo-cystomatous, 498
 removal of, during abdominal myometery, 527
 of umbilicus associated with myoma, 463
 of uterus associated with myoma, 463
 of utero-ovarian ligaments in myoma cases, 356
 parovarian, with uterine myoma, 333
 retention, in kidney, with myoma, 427
 tubo-ovarian, with myoma, 340
 vaginal, with myoma, 439

Cervical lips, edema of, with myoma, 441
 lymph-glands, metastases in, from adenocarcinoma of body of uterus, 297, 307
 Cervical mucosa, changes in, with myoma, 297, 307
 extensive removal of, during supravaginal hysteromyectomy, 604
 polyp of, with myoma, 298, 300
 Cervical myoma, 53
 abdominal myometery for, 510
 associated with adenocarcinoma of uterus, 278
 extensive, hysterectomy for, difficult, 58
 large, with adenocarcinoma of body, 289
 removal of, through abdomen, 510
 Cervical stump, rupture of, after abdominal hysteromyectomy, 599
 hemorrhage from secondary sarcoma in, 190
 return of myosarcoma in, 176, 190
 Cervix, almost obliterated, with myoma, 441
 atrophy of, associated with myoma, 78, 297
 carcinoma of, associated with myoma, 262, 305, 308
 simulated by submucous myoma, 487
 of myoma and primary carcinoma of ovary, 271
 with elongating submucous myoma, 398
 Cervix, closure of, after hysteromyectomy, 396
 condition of, in cases of myoma, 440
 double, associated with submucous adenomyoma, 155
 elongation of, with myoma, 441, 442
 hypertrophy of, with myoma, 297, 441
 in differential diagnosis of myoma and pregnancy, 467
 infection of, following abdominal hysteromyectomy, 604
 involvement of, by myoma, 57
 jammed down on perineum in myoma cases, 441
 normal, with myoma, 441
 pushed up behind symphysis in myoma cases, 441
 return of sarcoma in, 212
 torsion of, 77, 79
 transverse section of, as preliminary step in abdominal hysteromyectomy, 617
 Cervicium section with death four years after abdominal myometery, 572
 Chloëtic tendency, metastases in, from sarcoma of uterus, 222

- DEATH after abdominal myomectomy probably due to infection from Fallopian tubes, 541 apparently from diarrhea following abdominal hysteromyomectomy, 681 causes of, in patients succumbing years after abdominal myomectomy, 570 due directly to myoma, 426, 427 due to bronchopneumonia after bisection, 685 due to peritonitis following abdominal hysteromyomectomy, 673 following abdominal hysteromyomectomy, 672, 677, 678, 680, 681, 682, 684 myomectomy, 532, 533, 538, 541, 543, 544, 672 bisection of uterus, 683 Cesarean section four years after abdominal myomectomy, 568 uterine hemorrhage, 399 vaginal myomectomy, 672
- Death from submucous myoma, no operation performed, 584 immediate, following abdominal myomectomy, 532 vaginal myomectomy, 580 myocarditis probable cause of, after abdominal myomectomy, 544 on table, 543 years after vaginal myomectomy, 586
- Death-rate, marked reduction in, in last two years, 687
- Decidua simulated by sarcoma, 218
- Defecation, painful, with myoma, 446
- Degeneration, cystic, of myoma, 83. See also *Degeneration, hyaline.*
- Degeneration, hyaline, of myoma, 8, 83-125, 395
- Delirium after vaginal myomectomy, 580
- Delusional insanity after vaginal hysteromyomectomy, 670
- Dermoid cysts of ovaries with myoma, 349
- Diagnosis of myoma, 467-503
- Discharge. See *Vaginal discharge.*
- Discrete myoma, 3
- Dislocation of ureters with myoma, 378
- Displacement of bladder, by myoma, 365, 368 of rectum, upward, by myoma, 386
- Diverticula, ruptured, rectal, 500
- Double ureter with myoma, 381
- Drainage, vaginal, following abdominal hysteromyomectomy, 623, 624
- EDEMA of cervical lips with myoma, 441 mucosa with myoma, 297 of legs after abdominal hysteromyomectomy, 658
- Edema of lower extremities associated with myoma, 450 of myoma, 88 of uterine mucosa with myoma, 322
- Edematous myoma, giant-cells in, 250
- Electrical treatment for myoma, 588
- Embolism, pulmonary, fatal, following abdominal hysteromyomectomy, 680 following bisection, 684
- Embolus, cerebral, following abdominal myomectomy, 537
- Emulsification of hyaline myomatous tissue, 92, 124
- Encysted peritonitis suggesting full bladder, with myoma, 371
- Endocarditis, acute vegetative, with sloughing submucous uterine myoma, 422 chronic, with myoma, 414
- Endocardium, metastases in, from myosarcoma of uterus, 220
- Endometritis, cervical, with myoma, 302 chronic, associated with suppurating interstitial myoma, 148 with myoma, 148, 302, 334
- Endometrium, inflammation of, with myoma, 334 tuberculosis of, with myoma, 335
- Epithelium lining uterine cavity, atypical changes in, with myoma, 332
- Erysipelas following vaginal operations for myoma, 579
- Exophthalmic goiter associated with myoma, 460
- Extra-uterine pregnancy and myoma, differentiation, 477
- FALLOPIAN tubes, adherent, with myoma, 338 affording blood-supply to parasitic myoma, 38 carcinoma of, secondary, 396 condition of, at autopsy, in myoma cases, 395 with myoma, 337 with myosarcoma of uterus, 177 hematosalpinx, with myoma, 338, 396 hydrosalpinx, with myoma, 338, 396 infection from fluid liberated from, 541 inflammation of, in myoma cases, 338 mechanical alterations in relations of, with myoma cases, 343 myoma of, 341 nourishing partially parasitic myoma, 38 operations on, during abdominal myomectomy, 526

- Fallopian tubes, pyosalpinx, with myoma, 396
rudimentary, with myoma, 340
salpingitis, with myoma, 338
tuberculosis of, with myoma, 341, 396
- Family history in cases of uterine myoma, 430
- Fat, emulsified, with cystic areas, in myoma, 92, 124
- Fecal fistula, temporary, following removal of ruptured suppurating myoma, 142
- Femoral hernia associated with myoma, 462
- Fertility in cases of uterine myoma, 457
- Fetus, dead, resembling myomatous uterus, 473
death of, with supuration and perforation of uterine wall, 470
myoma resembling, in contour, 469
resembled by myoma, 6
- Fever with submucous uterine myoma, 572
- Fibroids of uterus, 1. See also *Myoma*,
recurrent, 178, 179, 252, 586
operation for, after vaginal myomectomy, 586
- Fibroma of ovary, 493
and myoma, differentiation, 493-495
with myoma, 351
of uterus, 1. See also *Myoma*.
- Fibromyoma of uterus, 1. See also *Myoma*.
- Fistula in ano following abdominal hysteromyomectomy, 660
- Fluid in cystic myoma, 91
- Flushes, hot, after hysteromyomectomy, 603, 604
- GALL-BLADDER, adhesions to, with myoma, 464
- Gangrene of ovary after hysteromyomectomy, 222
- Gangrenous submucous myoma, 66
- Giant cells in suspicious myoma, 250
- Glands. See *Lymph-glands*.
- Glands, cervical, dilatation of, with myoma, 298
unfolding of, with myoma, 302
hypertrophy of, with myoma, 316, 325
- Glands, running parallel to surface of uterine mucosa, 316
unusual shapes of, associated with uterine myoma, 321
- Glands, uterine, dilatation of, with myoma, 323
hypertrophy of, with myoma, 325
- Glycosuria with uterine myoma, 465
- Goiter with uterine myoma, 460
- Graafian follicle cysts with uterine myoma, 344
- Gritty particles in myoma, 126
- HALLUCINATIONS following abdominal hysteromyomectomy, 661
- Heart cavity, cystic myoma resembling, 122
- Heart complications after abdominal hysteromyomectomy, 660
hypertrophy of, with necrotic myoma, 423
in myoma cases, 451
lesions, possibly attributable to myoma, 421
muscle, calcification of, with myoma, 424
hyaline degeneration of, with necrotic myoma, 423
metastases in, from myosarcoma of uterus, 176
sounds in myoma cases, 451
- Heart-shaped myoma, 5
- Hematoma during abdominal hysteromyomectomy, 623
- Hematosalpinx with myoma, 338, 396
- Hemoglobin in cases of myoma, 451, 453, 455, 517
- Hemorrhage, abdominal, from sarcoma of cervical stump, 190
symptoms suggesting, after abdominal hysteromyomectomy, 669
due to general oozing from pelvis, 621
due to slipping of ligature during abdominal hysteromyomectomy, 623
during abdominal hysteromyomectomy, 620, 621, 622
during vaginal myomectomy, 576
following abdominal hysteromyomectomy, 654, 681
abdominal myomectomy, 548
in cases of submucous myoma, 572
local applications as means of checking, 588
method of controlling, where needle cannot be employed, 620
secondary, as cause of death after abdominal hysteromyomectomy, 681
- Hemorrhoids with uterine myoma, 446
- Heredity as cause of myoma, 430
- Hernia, femoral, with myoma, 462
inguinal, with myoma, 462
umbilical, strangulated, 120
with carcinoma of cervix and myoma, 398
with myoma, 120, 461, 639
- Hernial sac, postoperative, containing myomatous nodule, 463
- Histologic appearance of early myoma, 431
of myosarcoma, 172
- Hot flushes after abdominal hysteromyomectomy, 604
- Hot weather as cause of postoperative elevation of temperature, 655
- Hyaline degeneration, advanced, with liquefaction and formation of small cysts, 88
bright yellow areas of, 87
cases showing various types of, 93
giving water-core appearance, 95

- Hyaline degeneration in muscle bundles of myoma, 85
 of blood-vessel walls in myoma, 86
 of heart muscle with necrotic myoma, 423
 of myoma, 8, 12, 83-125
 relation to sarcomatous transformation, 93, 232
 with formation of large cysts in myoma, 90
 with liquefaction and cyst formation, 88, 89
- Hyaline material degenerated and containing cholesterol crystals, 92, 124, 125
 tissue, gradual liquefaction of, 103
- Hydatidiform mole resembling myomatous uterus, 480
- Hyronephrosis with myoma, 397
- Hydrosalpinx in myoma cases, 338, 396
- Hydroureter with uterine myoma, 381, 396, 399, 414
- Hypertrophy, cardiac, with myoma, 414
 of bladder wall, 370
 of cervical mucosa in myoma cases, 297
 of cervix in myoma cases, 441
 of round ligaments in myoma cases, 363
 of uterine glands with myoma, 316, 325
 of uterus, with myoma, 11
- Hysterectomy for myoma. *See Hysteromyomectomy.*
- Hysterical manifestations following abdominal myomectomy, 547
- Hysteromyomectomy, abdominal, 588, 626, 641
 accidental ligation of ureter during, 382
 acute mania after, 661
 adenocarcinoma of body of uterus overlooked at, 286
 after abdominal myomectomy, 559
 on account of development of other myoma, 561
 after-treatment, 627
 almost fatal bleeding from accessory branch of uterine artery in, 623
 anesthetic in, 590
 appearance of cervical stump after, 599
 bed-sore after, 662
 bisection of uterus in, 608, 683, 684, 685.
 See also Bisection of uterus.
 bronchitis after, 668
 bronchopneumonia after, 668
 cardiac complications after, 660
 clamping of cardinal vessels and application of ligatures, 600
 closure of cervix in, 596
 complications following, 654, 668
 constipation after, 659
 cystitis after, 657
- Hysteromyomectomy, abdominal, dark-brown vomitus after, 658
 death after, causes of, 672, 673, 681, 682, 683, 684, 685
 difficult, 58, 630
 edema of legs after, 658
 employment of round ligaments in suspension of cervical stump in, 603
 extensive removal of cervical mucosa during, 691
 fistula in ano after, 660
 from below upward, 612
 gangrene of ovary and, 222
 gradual absorption of adhesions after, 644
 hallucinations after, 661
 heart complications after, 660
 hematoma during, 623
 hemorrhage after, 654, 681
 during, 620-623
 local applications as means of checking, 588
 hot flushes after, 603
 immediate removal of appendages in, 607
 results from, 672
 in apparently inoperable myoma case, 636
 in constitutional bleeder, 625
 in intestinal adhesions, 633
 in kidney diseases, 625
 in myoma adherent to abdominal wall, 630
 associated with pelvic abscess, 635
 filling pelvis, 631
 in syphilis, 625
 indications for, 590
 infection of cervix after, 664
 injury of bladder during, 371, 374
 to rectum during, 387
 to ureter during, 382
 inspection of uterine cavity for cancer and myoma for sarcoma in, 594
 intestinal obstruction after, 659, 677
 worms after, 659
 irrigation of abdominal cavity after, 629
 left to right, with removal of appendages, 606
 location of ureters during, 385
 multiple abscesses after, 664
 myocarditis as cause of death after, 682
 nausea after, 658
 nephrectomy after, 384, 385
 nephritis after, 657
 nervous phenomena after, 661
 obstipation after, 659
 operative complications, 630
 partial suppression of urine after, 657
 passage of enema into abdominal cavity after, 391

- Hysteromyomectomy, abdominal, pelvic infection after, 662, 663, 664
 involving broad ligament or Douglas' sac after, 664
 limited to cervix after, 664
 perforation of rectum after, 390
 on account of adhesions after abdominal myomectomy, 559
 peritonitis as cause of death after, 673
 phlebitis after, 665, 667
 pleurisy after, 667
 pneumonia after, 669
 preliminary treatment, 626
 present health after, 605
 preservation of ovaries in, 594, 603
 pulmonary abscess after, 669, 682
 embolism as cause of death after, 680
 pulse after, 656
 raw areas after, 619
 rectal tears in, 387
 tenesmus after, 659
 removal of tuberculous kidney after, 384
 resection of sigmoid flexure during, 389
 results, 672
 right to left, with removal of appendages, 606
 secondary hemorrhage as cause of death after, 681
 shock as cause of death after, 678
 silk ligature from uterine artery passed into bladder after, 375
 subsequent to abdominal myomectomy, 559
 vaginal myomectomy, 585
 suppuration of abdominal wound after, 662
 tearing of ovarian vessels during, 621
 temperature after, 655
 thrombosis of ovarian veins and, 222
 transverse section of cervix in, 612
 tying cardinal vessels and removing uterus in, 595
 urine, partial suppression after, 657
 retention after, 657
 vaginal drainage after, 623
 vermicular contraction of ureters during, 385
 vicarious menstruation after, 605
 vomiting after, 658
 when abdominal walls are thick, 630
 when pelvic abscess exists, 635
- Hysteromyomectomy, supravaginal, for myoma, 593
 myosarcoma overlooked during, 190
 vaginal, 629
- Hysteromyomectomy, vaginal, complications after, 670
 delusional insanity after, 670
 results after, 685
 transitory lack of recognition after, 670
- Hysterotomy, 509, 510
- ILIAC VEINS, compression of, by tumor, 234
 incarcerated myoma, 365
- Incontinence of urine with myoma cases, 376
- Induration of vaginal vault with myoma, 440
- Inflammation of bladder after abdominal myomectomy, 549
 with myoma, 377
 of cervical mucosa in myoma cases, 302
 of endometrium in myoma cases, 334
 of Fallopian tubes in myoma cases, 338
- Inguinal glands, metastases in, from squamous-celled carcinoma of cervix, 399
 hernia associated with myoma, 462, 463
 lymph-glands, carcinoma of, secondary to adenocarcinoma of body of uterus, 465
- Insanity following vaginal hysterectomy, 670
- Intermenstrual bleeding with myoma, 444
- Interstitial myoma, 1
 abdominal myomectomy for, 508, 521
 invaded by squamous-celled carcinoma of cervix, 403
 suppurating, 144
 results after operation for, 153
- Interstitial myosarcoma of uterus, 171
- pregnancy simulating myomatous uterus, 477
- Intestinal adhesions, 556, 633, 635
- Intestinal obstruction after abdominal hysteromyomectomy, 659, 677
 myomectomy, 333, 552, 566
 after bisection of uterus for myoma, 683
 years after abdominal myomectomy, 557
 vessels furnishing nourishment to myoma, 41
 worms following abdominal hysteromyomectomy, 659
- Intestine, sarcoma of, secondary to uterine sarcoma, 234
 small, nourishing parasitic myoma, 47
 ovarian abscess opening into, 639
 suppurating myoma opening into, 47
- Intraligamentary myoma, 1, 187
 suppurating, 137
 upward pressure of, 365
- Intraligamentary myosarcoma of uterus, 171
- Inversion of uterus with submucous myoma, 71
- Irrigation of abdominal cavity after hysteromyomectomy, 620

- Johns Hopkins Hospital autopsy records, 394
 cases, 671
- KELLY sanitarium cases, 671
- Kidney, changes in, at autopsy, in myoma cases, 397
- complications following abdominal hysteromyomectomy, 657
- dilatation of pelvis of, with myoma, 397
- diseases of, abdominal hysteromyomectomy in, 625
- miliary abscesses of, with myoma, 397, 422
- misplaced, with myoma, 465
- nodules in, with myoma, 465
- removal of, subsequent to injury of ureter, 383
- retention cysts in, 427
- tuberculous, removal of, after hysteromyomectomy, 384
- Kidney-shaped myoma, 4
- LABIAL cyst with myoma, 438
- Lateral anastomosis where extensive intestinal adhesions exist, 635
- Left to right abdominal hysteromyomectomy, 606
- Legs, edema of, with myoma, 450; after abdominal hysteromyomectomy, 638
- Leukocytosis following abdominal myomectomy, 553
- in myoma cases, 152
- Leukorrhœa with submucous myoma, 571
- Ligament, broad, abscess in, after abdominal myomectomy, 553
- adhesions to, with myoma, 354
- alterations in, associated with myoma, 354
- dilatation of vessels of, with myoma, 354
- dilated lymph-spaces in, with myoma, 355
- hematoma in, during abdominal hysteromyomectomy, 623
- myoma of, 354, 510
- sarcoma in, secondary to myosarcoma of uterus, 195
- thickening of, with myoma, 355
- used to cover over myomectomy incision, 525
- Ligaments, round, adenomyoma of, in myoma cases, 364
- alterations in, with myoma, 361, 362
- employment of, in suspension of cervical stump in abdominal hysteromyomectomy, 598, 603
- hypertrophy of, with myoma, 363
- myoma of, 363
- Ligaments, utero-ovarian, adenomyoma of, in myoma cases, 360
- changes in, with myoma, 356
- cysts of, with myoma, 356
- myoma of, 358
- secondary sarcomatous nodules in, with myoma, 360
- Ligation of ureters, accidental, during hysteromyomectomy, 382
- Ligature, passage of, from cervical stump into bladder, 375
- slipping of, with hemorrhage, during abdominal hysteromyomectomy, 623
- Lipoma of abdominal wall associated with myoma, 461
- Lipomyoma of uterus, 162
- Lips, cervical, edema of, with myoma, 441
- Liquefaction of hyaline myoma, 88, 89, 103, 104
- Liver, and myoma, adhesions between, 464
- condition of, with myoma, 464
- metastases in, from adenocarcinoma of uterus, 408
- myosarcoma of uterus, 176, 201
- sarcoma of, secondary to sarcoma of uterus, 234
- thickening of, associated with myoma, 464
- Lobar pneumonia after abdominal hysteromyomectomy, 669
- myomectomy, 555
- Lumbar glands, metastases in, from sarcoma of uterus, 222
- Lungs, abscess of, and bronchopneumonia, after hysteromyomectomy, 682
- metastases in, from adenocarcinoma of uterus, 408
- from myosarcoma of uterus, 176, 195, 220, 234
- from squamous-celled carcinoma of cervix, 399
- septic infarction of, with sloughing submucous myoma, 422
- Lymphatic activity in parasitic myoma, 14
- Lymphatics, omental, dilatation of, 14, 20, 22
- uterine, dilatation of, associated with myoma, 72, 76
- Lymph-channels, dilated, in myoma cases, 123
- Lymph-glands, bronchial, metastases in, from adenocarcinoma of uterus, 405
- from squamous-celled carcinoma of cervix, 399
- cervical, metastases in, from adenocarcinoma of uterus, 405
- from myosarcoma of uterus, 195
- inguinal, metastases in, from adenocarcinoma of body of uterus, 405

- Lymph-glands, inguinal, metastases in, from squamous-celled carcinoma of cervix, 399
- lumbar, metastases in, from sarcoma of uterus, 222
- mediastinal, metastases in, from adenocarcinoma of uterus, 414
- mesenteric, metastases in, from squamous-celled carcinoma of cervix, 399
- sarcoma of, secondary to sarcoma of uterus, 234
- pelvic, metastases in, from squamous-celled carcinoma of cervix, 399
- pericardial, metastases in, from adenocarcinoma of uterus, 405
- peripancreatic, sarcoma of, 234
- Lymph-spaces, dilated, in broad ligament, in myoma, 355
- MALFORMATIONS** of uterus, myoma associated with, 155, 157
- Mania, acute, after abdominal hysteromyomectomy, 661
- Mediastinal lymph-glands, metastases in, from adenocarcinoma of uterus, 414
- Menstrual flow, retained, enlargement of uterus due to, 485
- history in myoma cases, 443
- Menstruation in differential diagnosis of myoma and pregnancy, 467
- influence of myoma on, 443
- vicarious, after abdominal hysteromyomectomy, 605
- Mesenteric lymph-glands, sarcoma of, secondary to sarcoma of uterus, 234
- vessels affording blood-supply to parasitic myoma, 39
- Mesentery, abnormally long, in myoma cases, 464
- calcareous nodules in, with myoma, 464
- metastases in, from adenocarcinoma of uterus, 408
- from squamous-celled carcinoma of cervix, 399
- sarcoma of, secondary to sarcoma of uterus, 234
- Metastases, abdominal, with myosarcoma of uterus, 200
- from adenocarcinoma of uterus to bronchial lymph-glands, 405
- to cervical lymph-glands, 405
- to inguinal lymph-glands, 405
- to omentum, 405
- to pericardial lymph-glands, 405
- to peritoneum, 405
- Metastases from sarcoma of uterus to peripancreatic lymph-glands, 234
- in adrenal body from adenocarcinoma of uterus, 408
- in bronchial lymph-glands from squamous-celled carcinoma of cervix, 399
- in inguinal lymph-glands from squamous-celled carcinoma of cervix, 399
- in intestine, secondary to sarcoma of uterus, 234
- in liver from adenocarcinoma of uterus, 234, 408
- in lumbar glands from sarcoma of uterus, 222
- in lungs from adenocarcinoma of body of uterus, 408
- from squamous-celled carcinoma of cervix, 399
- secondary to sarcoma of uterus, 195, 234
- in mediastinal lymph-glands from adenocarcinoma of uterus, 414
- in mesenteric lymph-glands, from squamous-celled carcinoma of cervix, 399
- secondary to sarcoma of uterus, 234
- in mesentery, from adenocarcinoma of uterus, 408
- secondary to sarcoma of uterus, 234
- in omentum, 499
- from adenocarcinoma of uterus, 408
- secondary to sarcoma of uterus, 234
- in pancreas, from adenocarcinoma of uterus, 408
- in peritoneum, from adenocarcinoma of uterus, 408
- from squamous-celled carcinoma of cervix, 399
- secondary to sarcoma of uterus, 195, 234
- in pleura, from adenocarcinoma of uterus, 408, 414
- from squamous-celled carcinoma of cervix, 399
- secondary to sarcoma of uterus, 234
- in spleen, from adenocarcinoma of body of uterus, 414
- in stomach, secondary to sarcoma of uterus, 234
- of chordæ tendineæ of tricuspid valve following sarcoma of uterus, 222
- Miscarriages in myoma cases, 458
- Mobility of myomata, 444
- importance of determining, before operation, 445
- Mole, hydatid, myoma and, differentiation, 480
- Mortality. See *Death*.
- Mucosa, cervical, changes in, in myoma cases, 297, 298, 302

- Mucosa, cervical, extensive removal of, during supravaginal hysteromyomectomy, 601
- Mucosa, uterine, blood-vessels of, alterations in, in myoma cases, 317
 condition of, with myoma, 297, 310, 316, 317, 322, 334
 in myosarcoma of uterus, 176
 small myoma developing in, 333
 thrombosis of veins in, with myoma, 320
 unusual gland shapes in, associated with myoma, 321
- Mucosa, vaginal, bluish color of, in myoma cases, 439
- Mulberry-shaped myoma, 1, 2, 5
- Multilocular cystadenoma of ovary with myoma, 346, 396, 417
- Muscle bundles, hyaline degeneration in, 85
 extension of, into uterine mucosa, 317
 heart, calcification of, with myoma, 424
 uterine, and myoma, line of junction between, 8
 condition of, with myoma, 11
 myoma extending into, 9
- Myocarditis as probable cause of death after abdominal hysteromyomectomy, 682
 myomectomy, 544
- Myoglia in myoma, 9
- Myoma, 1
 abdominal contour in, 436
 hysterectomy for, 588. See also *Hysteromyomectomy, abdominal*.
 myomectomy for, 506. See also *Myomectomy, abdominal*.
 abdominal pregnancy and, differentiation, 473
 abdominal veins, enlargement of, with, 437
 abnormally long mesentery with, 464
 abscess of broad ligaments with, 355
 of omentum with, 637
 of ovary with, 344, 396, 637, 639
 adenocarcinoma of ovary and, 348
 of uterus associated with, 274. See also *Adenocarcinoma of uterus*.
 adenoecystomata of ovary with, 346, 396, 417
 adenomyoma of round ligaments with, 364
 of utero-ovarian ligament with, 360
 adherent Fallopian tubes with, 338
 to abdominal wall, abdominal hysterectomy for, 630
 adhesions with, found at autopsy, 395
 of bladder in, rôle played by, 366
 to broad ligaments with, 354
 to gall bladder with, 464
 to liver with, 464
 to rectum with, 386
- Myoma, advanced hyaline degeneration of, with liquefaction and formation of small cysts, 88
 age of incidence of, 434
 alveolar appearance of, due to proliferation of endothelium of blood capillaries, 99
 apparently inoperable, abdominal hysterectomy for, 636
 appendicitis associated with, 463
 areas of adipose tissue in, 162, 166
 ascites associated with, 30
 autopsy findings in cases of, 394, 397, 428
 ballottement with, 469
 bilateral ovarian cysts and, differentiation, 498
 bisection of uterus for, 608
 bladder and, 365, 370, 377
 blood in uterine cavity with, 309
 blood-supply of, 6
 bluish color of vaginal mucosa with, 439
 breasts in cases of, 449, 450
 calcareous nodules in mesentery in, 464
 plates in walls of artery in, 129
 calcification of, 126, 268
 carcinoma extending into, 405
 of breast associated with, 450
 of cervix associated with, 262, 398
 of Fallopian tube with, 396
 of ovary with, 396
 of rectum with, 391, 417
 of stomach and ovary with, 396
 of uterus with, 404, 485
 associated with, cases of, 274
 cardiac hypertrophy with, 414
 cause of, 430
 cells of, 9
 changes in, suggesting sarcoma, 238, 242, 243
 transition into sarcoma cells, 188, 225, 226, 227, 228
- Myoma, cervical, 53
 abdominal myomectomy for, 510
 adenocarcinoma of uterus and, 278, 289
 endometritis with, 302
 polypi with, 298
 cervix almost obliterated with, 441
 jammed down on perineum with, 441
 up behind symphysis with, 441
 chorio-epithelioma and, 482
 chronic endocarditis with, 414
 cleavage from uterine muscle with, 8
 clinical course of, 431
 clinically overshadowing adenocarcinoma of uterus, 275
 colostrum of breasts with, 449
 constipation associated with, 445

- Myoma, corpus luteum cysts with, 346
 cystic, abdominal myomectomy for, 512
 cystic degeneration of, 83. See also *Hyaline degeneration*,
 cystitis with, 377
 cysts of ovary with, 344
 of urachus with, 463
 of utero-ovarian ligaments with, 356
 dead fetus resembling, 473
 death due directly to, 426
 degeneration in, found at autopsy, 395
 dermoid cyst with, 349, 396
 diagnosis of, differential, 467-503
 dilatation of cervical glands with, 298
 of deep uterine lymphatics associated with,
 76
 of renal pelvis with, 397
 of superficial uterine lymphatics asso-
 ciated with, 72
 of ureters with, 378
 of uterine glands with, 323
 of vessels of broad ligaments with, 354
 dilated lymph-channels in, 123
 lymph-spaces in broad ligament with, 355
 disappearance of, after pregnancy, 646
 discrete, 3
 duration of, before operation, 435
 edema of, 88
 effect of removal of ovaries on, 504
 electrical treatment of, 588
 elongation of supravaginal portion of cervix
 with, 442
 of vaginal portion of cervix with, 441
 emulsification of hyaline material in, 92, 124
 encysted peritonitis suggesting a full bladder
 with, 371
 endometritis with, 334
 extending into uterine muscle, 9
 extra-uterine pregnancy and, 477
 Fallopian tubes and, 338, 340
 family history and, 430
 femoral hernia associated with, 462
 fertility and, 457
 fibroma of ovary and, 351, 493
 free in broad ligament, 51, 187
 gall-bladder with, 464
 giant cells in, 250
 gland hypertrophy of mucosa with, 316, 325
 glands, unusual shapes of, associated with,
 321
 running parallel to surface of uterine
 mucosa with, 316
 glycosuria with, 465
 goiter with, 460
 Graafian follicle cysts with, 344
 gritty particles in, 126
- Myoma, heart in cases of, 421, 451
 heart-shaped, 5
 hematosalpinx with, 338, 396
 hemoglobin percentage with, 451, 453, 455,
 517
 hemorrhoids associated with, 446
 heredity and, 430
 histologic appearances of, 7
 changes in, suggesting carcinoma, 491
 hyaline degeneration of, 83. See also
 Hyaline degeneration,
 hydatid mole and, 480
 hydronephrosis with, 397
 hydrosalpinx with, 338, 396
 hydroureter with, 381, 396, 399, 414
 hypertrophy of bladder wall with, 370
 of cervical mucosa with, 297
 of cervix uteri with, 441
 of round ligaments with, 363
 of uterine glands with, 325
 hysterectomy for. See *Hysteromyomectomy*,
 in contour resembling a fetus, 469
 in old age, 395
 incarcerated, 365
 incontinence of urine with, 376
 induration of vaginal vault with, 440
 inguinal hernia associated with, 462
 inoperable, treatment of, 636
- Myoma, interstitial, 1
 abdominal myomectomy for, 508
 intestinal obstruction associated with, 447
 intraligamentary, 1, 365
 irregular growth of, 10
 kidney, miliary abscesses in, complicating, 397
 misplaced, with, 465
 nodules in, associated with, 465
 kidney-shaped, 4
 labial cyst with, 438
 large ovary with, 352
 leukocytosis with, 152
 lipoma of abdominal wall with, 461
 liquefaction of, 88, 89
 liver and, 464
 loss of weight with, 456, 572
 macroscopic appearances of, 1
 malformation of uterus with, 155
 menstrual history in cases of, 443
 merging of, into an ovary, 353
 mesentery, findings in, associated with, 464
 microscopic appearances of, early, 431
 miscarriages with, 458
 mobility of, 444
 mulberry-shaped, 1, 2, 5
 multicystic, 112
 myoglia in, 9
 nausea associated with, 447

- Myoma, necrotic, 153
 with cardiac hypertrophy, 423
 with hyaline degeneration of heart muscle, 423
 with pyonephrosis, 423
- Myoma, number of, 3
 removed by abdominal myomectomy, 517
- obliteration of cervix with, 441
 of umbilical depression with, 461
 of broad ligament, 51, 53, 354, 510
 abdominal myomectomy for, 510
- of Fallopian tubes, 341
 of round ligaments of uterus, 363
 of utero-ovarian ligaments, 358
 omental carcinoma and, 499
 origin of, 433
 ovarian cysts and, 344, 495
 pain with, 448, 449
 painful defecation associated with, 446
 urination with, 376
- panhysterectomy for, 593, 616
- papillocystoma of ovaries and adenocarcinoma of uterus with, 408
 of ovary with, 346
- Myoma, parasitic, 13. See also *Parasitic myoma*.
 parovarian cysts with, 353
 pear-shaped, 4
 pedunculated, 1, 2
 pelvic abscess with, 635, 636
 molds and, 6
 peritonitis with abscess formation and, 344
 perirectal abscess with, 391
 phleboliths in vaginal wall with, 440
 polypi of cervical mucosa with, 298
 of uterus associated with, 325, 328, 329
- pregnancy and, 467, 473, 477, 507, 643
 pressure of, on bladder, 365
 on iliac veins, 234
 on ureters, 381
 pains with, 448
- prolapse of rectum with, 391
 of uterus with, 460
- pruritus and associated with, 446
 vulvæ with, 444
- pyelonephrosis with, 397
 pyometra associated with, 310
 pyosalpinx with, 338, 340, 396
 rectal diverticula, rupture of, and, 500
 rectum and, 386
 removal of, in apparently inoperable cases, 636
 renal colic with, 466
 resemblance of, to fetus, 6
 respiration and, 450
 results of operations for, 671
- Myoma, retention cysts in kidney with, 427
 of urine with, 376
 retraction of umbilicus with, 461
 retroperitoneal, development of, 631
 sarcoma and, 501
 sacculation of bladder with, 370
 sacral markings with, 5
 saddle-bag appearance of uterus with, 5
 salpingitis with, 338
 sarcoma developing from, 169, 172, 173, 180, 208, 420
 of bladder associated with, 420
 of uterus and, 492
 secondary carcinoma of uterus with, 295
- Myoma, sessile, 1, 2
 shape of, 4
 simulated by chorio-epithelioma, 482
 by extra-uterine pregnancy, 477
 by hydatidiform mole, 480
 by omental metastases, 499
 by retained menstrual flow, 485
 by retroperitoneal sarcoma, 501
 by simple ovarian cysts, 497
- size of, 3
 small developing in uterine mucosa, 333
 unattached to uterus and situated between tube and ovary, 364
 snugly filling pelvis, rendering abdominal hysteromyomectomy difficult, 631
 sterility associated with, 457
- Myoma, submucous, 1, 59, 571. See also *Submucous myoma*.
- Myoma, subperitoneal, 1, 45, 81, 134, 249, 444, 508
- Myoma, subvesical, 365, 510
- Myoma, suppurating, 134-153
 cause of, 152
 interstitial, 144
 intraligamentary, 137
 opening into cecum, 45
 into colon, 142
 into small bowel, 47
 subperitoneal, 134, 135, 139
 communicating with bowel, 134
 suspicion of carcinoma of cervix with, 302, 304
 symptoms of, 434-459
 temperature with, 457
 thickening of broad ligaments with, 355
 of left lobe of liver with, 464
 three-leaf-clover-shaped, 5
 thrill felt on vaginal examination with, 442
 thrombosis of veins in mucosa with, 320
 torsion of cervix with, 77
 of uterus with, 77, 79
 transition of, into sarcoma, 182

- Myoma, transverse colon, descent of, with, 463
 treatment of, 504, 506, 571, 588, 629, 630, 671
 tubal pregnancy with, 342
 tuberculosis of endometrium with, 335
 of Fallopian tubes with, 341, 396
 of uterus associated with, 421
 tuberculous peritonitis associated with, 464
 tubo-ovarian abscess with, 290, 344, 396
 cysts with, 340
 ulceration of vagina with, 440
 umbilical cyst associated with, 462
 hernia associated with, 461, 639
 umbilicus and, 461
 unfolding of cervical glands with, 302
 unrecognized sarcomatous degeneration in, 193
 ureters in cases of, 378-385
 urination and, 376
 uterine cavity and, 305
 polypi associated with, 325
 stones in, 130
 vagina, size of, with, 439
 vaginal, associated with uterine myoma, 234, 440
 cysts with, 439
 hysterectomy for, 629. See also *Vaginal hysterectomy*.
 myoma associated with, 440
 myomectomy for, 571. See also *Myomectomy, vaginal*.
 stones in, 440
- Myoma, varieties of, 1
 vein stones in vagina with, 440
 vesical adhesions with, 366
 calculus with, 375
 vomiting associated with, 417
 weakness with, 457
 weight of, 119, 512
- Myomatous tendency, 4
- Myomectomy, abdominal, 506
 abscess in broad ligament after, 553
 age of patients in cases of, 506, 518
 and hysterectomy on account of development of other myomata, 561
 bed-sores after, 555
 bronchitis after, 554
 bronchopneumonia after, 555
 carcinoma of uterus not discovered during, 416
 cystitis after, 549
 death after, 532, 533, 537, 538, 540, 541, 543, 544, 568
 during pregnancy, 528, 529, 538
 evacuation of pelvic abscess after, 559
 for adenomyoma of uterus, 511
 Myomectomy, abdominal, for cervical myoma, 510
 for cystic myoma, 512
 for interstitial myoma, 508, 521
 for myoma of broad ligament, 510
 for pedunculated myoma, 521
 for submucous myoma, 509, 523
 for subperitoneal pedunculated myoma, 508
 for subvesical myoma, 540
 for suppurating subperitoneal myoma, fecal fistula after, 142
 foul discharge from uterus after, 550
 hemoglobin, low, as contraindication to, 517
 hemorrhage after, 548
 hysterectomy after, 559, 560
 hysterical manifestations after, 547
 results after, 568, 569, 570, 672
 in syphilitic patient, 518
 intestinal adhesions after, 566
 obstruction after, 533, 552, 557
 leukocytosis after, 553
 lobar pneumonia after, 555
 location of myoma and, 507
 myocarditis with, 544
 nausea after, 548
 nephritis after, 550
 number of myomata removed by, 517
 operations on tubes and ovaries during, 526
 performed in conjunction with, 526
 subsequent to, 556, 570
 pain after, 549
 peritonitis after, 533, 552
 phlebitis after, 555
 pleurisy after, 554
 postoperative complications and, 544
 pregnancy following, 566
 preservation of portion of fundus in, 525
 pulse after, 545, 546
 pus from urethra after, 550
 release of adhesions after, 556
 removal of ovarian cysts during, 527
 of ovaries after, 558
 of tubes or ovaries during, 526
 of vermiform appendix and, 463, 557, 558
 repair of perineum during, 527
 repeated, 558
 size of myomata removed, 511
 sloughing of uterine wall after, 551
 suspension of uterus during, 528
 syphilis as contraindication to, 518
 tearing of uterine artery during, 525
 technic of, 521, 523
 temperature after, 545, 546
 tonsillitis after, 554
 vomiting after, 548

- Myomectomy, vaginal, 571, 577**
 bisection of myoma in, 574
 complications after, 578
 during, 576
 death after, 580-583, 586
 delirium after, 580
 erysipelas after, 579
 for infected and disintegrating submucous myoma, 575
 for non-infected submucous myoma, 573
 hemorrhage during, 576
 hysterectomy subsequent to, 585
 operation for recurrent fibroids after, 586
 operations subsequent to, 585
 other operations during, 578
 phlebitis after, 579
 pregnancy after, 587
 pulse after, 578
 results after, 584, 586, 587, 672
 rupture of uterus during, 576
 temperature after, 578, 579
- Myosarcoma of uterus, 169-261**
 abscess in broad ligament with, 196
 age of incidence, 178
 cervical stump, return in, 176, 190
 clinical history, 177-179
 condition of Fallopian tubes with, 177
 of ovaries with, 177
 of uterine mucosa with, 176, 190
 cysts in, 197, 198
 developing from connective tissue of myoma, 172
 from degenerated myoma, 188
 from muscular elements of myoma, 173
 in center of myoma, 208
 gross appearances of, 170
 suggesting, 236-245
 histologic appearances, 172
 incidence of, suggesting, 245-261
- Myosarcoma of uterus, interstitial, 171**
Myosarcoma of uterus, intraligamentary, 171
 metastases in abdomen from, 200
 in cervical lymph-glands from, 195
 in chordæ tendineæ of tricuspid valve from, 222
 in columnæ carneæ of right ventricle from, 222
 in endocardium from, 220
 in heart muscle from, 176
 in liver from, 176, 201
 in lungs from, 176, 195, 220
 in lymph-glands from, 176
 in omentum from, 176
 in pleura from, 195
 in skin from, 176
 in vertebrae from, 176
- Myosarcoma of uterus, overlooked at operation, 190**
 in laboratory, 193, 200, 204
 perforation of abdominal wall with, 176
 rapidity in growth of, 176
 recurrence of, 176
 relation of hyaline degeneration to, 232
 of recurrent fibroids to, 178
 secondary growths of, 175
 nodules of, in right broad ligament, 195
- Myosarcoma of uterus, submucous, 171**
Myosarcoma of uterus, subperitoneal, 171
 transition of muscle fibers into sarcoma cells in, 225, 226, 227, 228
 treatment of, 179
- NAUSEA after abdominal hysteromyomectomy, 658**
 myomectomy, 548
 associated with myoma, 447
- Necrotic myoma, 153**
Nephrectomy after hysteromyomectomy, 384, 385
Nephritis after abdominal hysteromyomectomy, 657, 681
 myomectomy, 550
- Nervous phenomena after abdominal hysteromyomectomy, 661**
Number of myomata, 3
- OBSTIPATION after abdominal hysteromyomectomy, 659**
- Omental adhesions with parasitic myoma, 15**
carcinoma, myoma and, differentiation, 499
 metastases, 499
 from adenocarcinoma of uterus, 405, 408
 from myosarcoma of uterus, 176
 vessels, friability of, 16
- Omentum, abscess in, with myoma, 637**
 affording part of blood-supply to parasitic myoma, 16-30
 changes in, with parasitic myoma, 13
 dilated lymphatics of, 14, 20, 22
 gradual disappearance of fat in, with parasitic myoma, 22, 23, 25, 28
 greatly dilated vessels of, with parasitic myoma, 24
 secondary sarcoma of, 234
- Ovarian adhesions, release of, after abdominal myomectomy, 556**
 cysts, myoma and, differentiation, 495, 498
 papillomatous, 498
 removal of, during abdominal myomectomy, 527

- Ovarian cysts, simple, resembling myoma, 497
 simulated by myoma, 111, 119, 495
 veins, thrombosed, after hysteromyomec-
 tomy, 222
 vessels, tearing of, during abdominal hystero-
 myomectomy, 621
- Ovary, abscess of, with myoma, 344, 637, 396,
 639
 adenocarcinoma of, with myoma, 348
 adenocystoma of, with uterine myoma, 346,
 396, 417
 alterations in location of, with myoma, 352
 carcinoma of, carcinoma of cervix with, 271
 of stomach with, 396
 primary, with myoma, 396
 condition of, with myoma, 337, 343, 395
 with myosarcoma of, uterus, 177
 corpus luteum cyst of, with myoma, 346
 cysts of, with myoma, 344
 dermoid cyst of, 349, 396
 effect of removal of, on myoma, 504, 505
 fibroma of, 351, 493
 gangrene of, following hysteromyomectomy,
 222
 Graafian follicle cysts of, with myoma, 344
 large, with myoma, 352
 merging of myoma into, 353
 multilocular cystadenoma of, with myoma,
 346, 396, 417
 operations on, during abdominal myomec-
 tomy, 525
 papillocystoma of, 346, 408, 498
 preservation of, in abdominal hysteromyo-
 mectomy, 594, 603
 removal of, after abdominal myomectomy,
 558
 during abdominal myomectomy, 526
- PAIN, abdominal, after myomectomy, 549
 with myoma, 376, 446, 448
- Pancreas, metastases in, from adenocarcinoma
 of uterus, 408
- Panhysterectomy for myoma, 593, 616
 for suspected myosarcoma, 180
- Papillocystoma of ovary with myoma, 346
 with myoma and adenocarcinoma of
 uterus, 408
- Parasitic myoma, 13
 abdominal walls affording blood-supply
 to, 51
 ascites associated with, 30, 31, 497
 bladder affording blood-supply to, 48, 49, 50
 etiology of, 14
 extruded from uterus and lying free in
 broad ligament, 39, 51
 Parasitic myoma, Fallopian tubes affording
 blood-supply to, 38
 free from uterus, 29, 39
 intestinal vessels affording blood-supply
 to, 41
 lymphatic activity in, 14
 mesenteric vessels, peritoneum, and ap-
 pendiceal adhesions affording blood-
 supply to, 39
 omental adhesions with, 15
 omental changes with, 13
 omentum affording part of blood-supply
 to, 16-30
 opening into bowel, 47
 into cecum, 45
- Parovarian cysts with myoma, 353
- Parovarium, alteration in, with myoma, 355
- Pear-shaped myoma, 4
- Pedunculated myoma, 1, 2, 521
 subperitoneal, abdominal myomectomy
 for, 508
 submucous myoma, 59, 61
 suppurating subperitoneal myoma, 139
- Pelvic abscess, anterior to myoma, 636
 evacuation of, after abdominal myomec-
 tomy, 559
 myoma associated with, 635
 floor, hemorrhage from vessels of, during
 abdominal hysteromyomectomy, 622
 infection after abdominal hysteromyomec-
 tomy, 662, 663, 664
- Pelvic lymph-glands, metastases in, from squa-
 mous-celled carcinoma of cervix, 399
 molds and myoma, 6
- peritonitis after abdominal myomectomy,
 552
 with abscess formation in myoma cases,
 344
- Pelvis, myoma filling, abdominal hysterectomy
 for, 631
 of kidney, dilatation of, with myoma, 397
- Pericardial lymph-glands, metastases in, from
 adenocarcinoma of uterus, 405
- Pericardium, metastases in, from myosarcoma
 of uterus, 176
- Perineum, repair of, during abdominal myo-
 mectomy, 527
- Peripancreatic lymph-glands, secondary sar-
 coma of, 234
- Perirectal abscess with myoma, 391
- Peritoneal cavity, large suppurating interstitial
 myoma opening into, 151
- Peritoneum affording blood-supply to para-
 sitic myoma, 39
 carcinoma of, secondary to adenocarcinoma
 of uterus, 405

- Peritoneum, metastases in, from adenocarcinoma of uterus, 408
 from squamous-celled carcinoma of cervix, 399
 secondary sarcoma of, 234
- Peritonitis as cause of death after abdominal hysteromyectomy, 673-676
 myomectomy, 553
 bisection of uterus for myoma, 683
 encysted, suggesting a full bladder with myoma, 371
- Peritonitis, pelvic, after abdominal myomectomy, 552
 with abscess formation, with myoma, 344
 tuberculous, associated with myoma, 464
- Phlebitis after abdominal hysteromyectomy, 665, 666, 667
 myomectomy, 555
 vaginal myomectomy, 579
- Phleboliths in vaginal wall with myoma, 440
- Pleura, metastases in, from adenocarcinoma of uterus, 408, 414
 from squamous-celled carcinoma of cervix, 399
 probable metastases in, from myosarcoma of uterus, 195, 234
- Pleurisy, acute, with sloughing submucous myoma, 422
 after abdominal hysteromyectomy, 667
 myomectomy, 554
- Pneumonia after abdominal hysteromyectomy, 669, 682
 myomectomy, 555
- Polypi of cervical mucosa with myoma, 298
 uterine, associated with myoma, 325, 328, 329
- Pregnancy, abdominal, myoma and, differentiation, 473-477
 myomectomy during, 528, 529, 530, 531, 538
 after abdominal myomectomy, 566-568
 after vaginal myomectomy, 587
 changes in myoma due to, 645
 complicated by large cervical myoma, 532
- Pregnancy, cornual, rupture of, myoma and, differentiation, 477
 disappearance of myoma after, 646
 extra-uterine, myoma and, differentiation, 477
 fatal abdominal myomectomy in case of, 538
 interstitial, rupture of, myoma and, 477
 myoma and, 459, 467, 507, 643, 648
 ruptured cornual or interstitial, simulating myoma, 477
 tubal, and myoma, 342
- Pressure on ureters by myomata, 381
 pains with myoma, 448
 symptoms with submucous myoma, 572
- Prolapse of rectum with myoma, 391
 of uterus associated with myoma, 460
- Pruritus ani associated with myoma, 446
 vulvae associated with myoma, 444
- Pulmonary abscess after abdominal hysteromyectomy, 669, 682
 embolism as cause of death after abdominal hysteromyectomy, 680, 684
- Pulse after abdominal hysteromyectomy, 656
 myomectomy, 545, 546
 vaginal myomectomy, 578
- Pus, escape of, from urethra, after abdominal myomectomy, 550
 in uterine cavity with myoma, 310
- Pyelonephrosis with myoma, 397
- Pyometra associated with myoma, 310
- Pyonephrosis with necrotic myoma, 423
- Pyosalpinx associated with myoma, 338, 340, 396
- RAW areas, covering of, after abdominal hysteromyectomy, 619
- Rectal diverticula, rupture of, myoma and, 500
 tears, 387
 tenesmus after abdominal hysteromyectomy, 650
- Rectum and myoma, adhesions between, 386
 carcinoma of, associated with myoma, 417
 displacement of, upward, by myoma, 386
 injury to, during hysteromyectomy, 387, 390
 perforation of, after hysterectomy for myoma, 390
 prolapse of, with myoma, 391
- Recurrent fibroids, 178, 179, 252, 586
 relation of, to myosarcoma, 178
- Renal colic with myoma, 466
 insufficiency, 451
 lesions, abdominal hysteromyectomy in patients suffering from, 625
- Resection of sigmoid flexure and removal of myoma, 389
- Respiration, effect of myoma on, 450
- Retention cysts in kidney, 427
 of urine after abdominal hysteromyectomy, 657
 with myoma, 376
- Retraction of umbilicus with myoma, 461
- Retropitoneal development of myoma, 631
 sarcoma, myoma and, differentiation, 501
- Round ligaments, adenomyoma of, 364
 altered relations of, 361
 as tense bands with myoma, 362

- Round ligaments, changes in, with myoma, 361
 hypertrophy of, with myoma, 363
 inserted in cervical stump, 596, 603
 lengthening of, with myoma, 362
 myoma of, 363
- Rudimentary Fallopian tube with myoma, 340
- Rupture of rectal diverticula, myoma and, differentiation, 500
 of uterus during vaginal myomectomy, 576
- SACRAL markings on myoma, 5
- Saddle-bag appearance of uterus with myoma, 5
- Salpingitis with myoma, 338
- Salts, calcium, deposit of, in myoma, 127
- Sarcoma and myoma, 169-261
 colony development of cells in, 211
 developing from connective tissue of myoma, 172, 173
 inspecting myoma for, during operation, 594
 of bladder associated with myoma, 420
 of cervical stump, abdominal hemorrhage from, 190
 of liver secondary from uterus, 234
 of omentum secondary to sarcoma of uterus, 234
- Sarcoma of uterus, 169, 492
 metastases from, 222, 234, 360
 myoma and, 492
 resembling myoma, 216
 relation of hyaline degeneration to, 93
 resembling decidua, 218
 retroperitoneal, myoma and, differentiation, 501
 return of, in cervix, 190, 212
 suggested by cell changes in myoma, 242, 243, 245
 unusual, on surface of uterus, 184
 with fading of myoma, 217
- Sarcomatous change in myoma, 169, 420. See also *Miyosarcoma of uterus*.
- Sausage-shaped sloughing submucous myoma, 70
- Sessile myoma, 1, 2
- Shapes of myomata, 4
- Shock as cause of death after abdominal hysteromyomectomy, 678
 bisection of uterus for myoma, 684
- Sigmoid flexure, carcinoma of, with myoma, 389, 391
 furnishing vessels to myoma, 44
 hematoma of, during abdominal hysteromyomectomy, 623
 resection of, and removal of myoma, 389
- Skin metastases from myosarcoma of uterus, 176
- Slipping of ligature with hemorrhage during abdominal hysteromyomectomy, 623
- Sloughing of uterine wall after abdominal myomectomy, 551
- Sloughing submucous myoma, 63, 64, 67, 68, 70, 398
- Spleen, metastases in, from adenocarcinoma of uterus, 414
- Squamous-celled carcinoma of cervix, invading myoma, 403
 metastases from, 399, 401
 with adenomyoma of uterus, 262
 with fatal hemorrhage, 399
 with myoma, 262
- Stercoraceous vomiting after abdominal hysteromyomectomy, 658
 myomectomy, 548
- Sterility associated with adenocarcinoma of uterus, 274
 with myoma, 457
- Stomach, carcinoma of, with carcinoma of ovary, 396
 sarcoma of, secondary to sarcoma of uterus, 234
- Stones, uterine, with myoma, 130
- Strangulated umbilical hernia, 120
 inguinal hernia associated with myoma, 463
- Submucous myoma, 1, 59, 571
 abdominal myomectomy for, 509
 technic of, 523
 age of incidence, 571
 death without operation in, 584
 fever and chills with, 572
 gangrenous, 66
 hemorrhage from, 572
 hysterotomy for, 510
 infected and disintegrating, vaginal myomectomy for, 575
 inversion of uterus associated with, 71
 leukorrhoea with, 571
 loss of weight with, 572
 myomectomy for, 571. See also *Myomectomy, vaginal*.
 pedunculated, 59, 61
 pressure symptoms from, 572
 removal of, 509, 523
 simulating carcinoma of cervix, 487
 size of, 59
 sloughing, 63
 abscesses, miliary, in left kidney with, 422
 carcinoma of cervix with, 398
 causing toxemia, 427
 histologic appearances of, 68
 lung, septic infarction of, complicating, 422
 odor from, 67
 pleurisy with, 422

- Submucous myoma, sloughing, sausage-shaped, 70
 size of, 64
 vaginal discharge from, 67
 vegetative endocarditis with, 422
 suspicious changes in, 248, 281
 symptoms of, 571
 thrombi of vessels with, 67
 vaginal discharge with, 571
- Submucous myosarcoma of uterus, 171
- Subperitoneal myoma, 1, 135-144
 edema in, 249
 hemorrhage from pedicle of, 621
 suppurating, 134, 139
 adherent to abdominal wall, 136
 communicating with bowel, 134
 torsion of, 81
- Subperitoneal myosarcoma of uterus, 171
 pedunculated myoma, abdominal myomectomy for, 508
 bleeding into abdominal cavity after bimanual examination of, 444
- Subvesical myoma, 365, 510
- Suppression of urine after hysteromyomectomy, 657, 682
- Suppurating interstitial myoma, 144, 146-152
 results after operation for, 153
 with perforation of uterus, 150
 intra-ligamentary myoma, 137
- Suppurating myoma, 134-154
 cause of, 152
 opening into cecum, 45
 into small bowel, 47
 results after operation for, 153
 symptoms of, 152
 treatment of, 153
- subperitoneal myoma, 134-144
 adherent to abdominal wall, 136
 communicating with bowel, 134
 pedunculated, 139
 results after operation, 153
 rupture of, 139
- Suppuration of abdominal wound after abdominal hysteromyomectomy, 662
 of uterine wall after death of fetus, 470
- Supravaginal hysterectomy for myoma, 593
 portion of cervix, elongation of, with myoma, 442
- Suspension of uterus after abdominal myomectomy, 525, 528
- Syphilis, abdominal hysteromyomectomy in, 625
 as contraindication to abdominal myomectomy, 518
- TEARS into rectal lumen during hysteromyomectomy, 387
- Temperature after abdominal hysteromyomectomy, 655
 after abdominal myomectomy, 545, 546
 after vaginal myomectomy, 578, 579
 in myoma cases, 457
- Tenesmus, rectal, after abdominal hysteromyomectomy, 659
- Three-leaf-clover-shaped myoma, 5
- Thrill felt on vaginal examination with myoma, 442
- Thrombosed ovarian veins after hysteromyomectomy, 222
- Thrombosis of blood-vessels in sloughing submucous myoma, 67
 of veins in uterine mucosa with myoma, 320
- Tonsillitis after abdominal myomectomy, 554
- Torsion of cervix uteri with myoma, 77
 of subperitoneal myoma, 81
 of uterus with myoma, 77, 79
- Toxemia from sloughing submucous myoma, 427
- Treatment of myoma, 504, 506, 571, 588, 629, 630, 654, 671
- Tubal pregnancy with myoma, 342
- Tuberculosis of endometrium with myoma, 335
 of Fallopian tubes with myoma, 341, 396
 of uterus associated with myoma, 421
- Tuberculous kidney, removal of, after hysteromyomectomy, 384, 385
 peritonitis associated with myoma, 464
- Tubo-ovarian abscess with myoma, 344
 and adenocarcinoma of uterus, 290
 cysts with myoma, 340
- Tumors of breast, benign, with myoma, 450
- ULCERATION of vagina with myoma, 440
- Umbilical cyst associated with myoma, 462
 depression, obliteration of, associated with myoma, 461
 hernia, strangulated, 120
 with carcinoma of cervix and myoma, 398
 with myoma, 461, 639
- Umbilicus, condition of, with myoma, 461
- Uraechus, cysts of, associated with myoma, 463
- Ureter, accidental cutting of, during hysteromyomectomy, 383
 and myoma, 378-385
 condition of, in myoma cases, 396
 dilatation of, in myoma cases, 378
 dislocation of, in myoma cases, 378
 double, in myoma cases, 381
 injury to, during hysteromyomectomy, 382, 383, 384
 ligation of, accidental, during hysteromyomectomy, 382
 location of, during hysteromyomectomy, 385

- Ureter, position of, in myoma cases, 378
 pressure on, by myoma, 381
 vermicular contraction of, 385
- Uretero-ureteral anastomosis, with subsequent removal of kidney, 383
- Urethra, escape of pus from, after abdominal myomectomy, 550
- Urination in myoma cases, 376
- Urine, retention of, after abdominal hysteromyomectomy, 657
 suppression of, after abdominal hysteromyomectomy, 657, 682
- Uterine artery, bleeding from accessory branch of, during abdominal hysteromyomectomy, 623
 fatal hemorrhage from, due to catgut absorption, 681
 passage of silk ligature from, into bladder, 375
 tearing of, during abdominal myomectomy, 525
- Uterine cavity, blood in, in myoma cases, 309
 epithelium lining, atypical changes in, in myoma cases, 332
 obliteration of, partial, in myoma cases, 308
 opening of suppurating interstitial myoma into, 146
 pus in, in myoma cases, 310
 size and shape of, in myoma cases, 305
- Uterine discharge, character of, in myoma, 442
 foul, following abdominal myomectomy, 550
 glands associated with myoma, unusual shapes of, 321
 dilatation of, 323
 hypertrophy of, 325
 running parallel to surface of uterine mucosa, 316
- horn, diffuse adenomyoma of, in bicornate uterus, 157
 dilatation of lymphatics of, 74
 lymphatics, dilatation of, associated with myoma, 72, 76
- Uterine mucosa, blood-vessels of, alterations in, in myoma cases, 317
 condition of, in myoma cases, 297, 310
 in myosarcoma of uterus, 176
 edema of, in myoma cases, 322
 extension of muscle into, in myoma cases, 317
 glands running parallel to surface of, in myoma cases, 316
 small myoma developing in, 333
 thrombosis of veins in, with myoma, 320
 unusual gland shapes associated with myoma in, 321
- Uterine muscle and myoma, line of junction between, 8, 9, 10
 condition of, with myoma, 11
- Uterine polypi associated with myoma, 325, 328, 329
- Uterine stones with myoma, 130
- Uterine vessels, hemorrhage from, during abdominal hysteromyomectomy, 621
- Uterine wall, perforation of, after death of fetus, 470
 sloughing of, after abdominal myomectomy, 551
 after removal of large interstitial myoma, 551
- Utero-ovarian ligaments, adenomyoma of, 360
 changes in, with myoma, 356
 cysts of, with myoma, 356, 357
 myoma of, 358, 360
 secondary sarcomatous nodule in, with myoma, 360
- Uterus, adenocarcinoma of, associated with myoma, 274. See also *Adenocarcinoma of uterus*.
 adenomyoma of, 167, 168, 511
 angiomatoma of, 158-161
- Uterus bicornate, diffuse adenomyoma in one horn of, 157
- Uterus, bisection of, for myoma, 608, 683, 684, 685
 broad ligaments of, abscess of, and myoma, 354, 355, 510
- Uterus, carcinoma of, 485
 associated with myoma, 295, 296, 404, 405-416, 485
 enlargement of, due to retained menstrual flow, 485
 fibroids of, 1. See also *Myoma*.
 fibroma of, 1. See also *Myoma*.
 fibromyoma of, 1. See also *Myoma*.
 hypertrophy of, in myoma cases, 11
 infection of, from carcinoma of uterus, after abdominal myomectomy, 540
 inspection of, in differential diagnosis of myoma and pregnancy, 467
 interstitial myosarcoma of, 171
 intraligamentary myosarcoma of, 171
 inversion of, associated with submucous myoma, 71
 large suppurating myoma opening into cavity of, 151
 lipomyoma of, 162-166
 malformations of, associated with myoma, 155-157
 myoma of, 1. See also *Myoma*.
 myosarcoma of, 169-261
 pain in, with myoma, 448

- Uterus, perforation of, due to suppurating interstitial myoma, 150
 position of, with myoma, 11
 prolapse of, associated with myoma, 460
 recurrent fibroids of, 178, 179
 round ligaments of, with myoma, 361, 362, 363, 364, 603
 rupture of, during vaginal myomectomy, 576
 saddle-bag appearance of, in myoma cases, 5
 sarcoma of, myoma and, 492
 relation of hyaline degeneration of myoma to, 93
 resembling myoma, 216
 submucous myosarcoma of, 171
 subperitoneal myosarcoma of, 171
 suspension of, during abdominal myomectomy, 525
 torsion of, in myoma cases, 77
 with complete severance of body from cervix, with myoma, 79
 tuberculosis of, associated with myoma, 421
 unusual sarcoma on surface of, 184
 with dead fetus resembling myoma, 473
- VAGINA, abscess burrowing along, 196
 alterations in size and shape of, with myoma, 439
 bluish color of, with myoma, 439
 condition of, with myoma, 438
 double, with submucous adenomyoma, 155
 expulsion of large submucous myoma through, 67
 ulceration of, with myoma, 440
 vein stones in, with myoma, 440
 Vaginal cysts with myoma, 439
 discharge with submucous myoma, 67, 571
 drainage after abdominal hysteromyomectomy, 623, 624
 examination, thrill felt on, with myoma, 442
 Vaginal hysteromyomectomy, 629, 670, 672, 685
- Vaginal mucosa, bluish color of, in myoma, 439
 Vaginal myoma, 234, 440
 Vaginal myomectomy, 571. See also *Myomectomy, vaginal*.
 portion of cervix, elongation of, with myoma, 441
 vault, induration of, with myoma, 440
 wall, phleboliths in, with myoma, 440
 Veins, abdominal, enlargement of, with myoma, 437
 iliac, compression of, by tumor, 234
 ovarian, thrombosis of, after hysteromyomectomy, 222
 thrombosis of, in uterine mucosa, with myoma, 320
 Vermicular contraction of ureters during hysteromyomectomy, 385
 Vermiform appendix, removal of, after abdominal myomectomy, 557, 558
 Vertebrae, metastases in, from myosarcoma of uterus, 176
 Vesical adhesions, release of, subsequent to abdominal myomectomy, 556
 rôle played by, in myoma cases, 366
 calculus associated with myoma, 375
 Vicarious menstruation after abdominal hysteromyomectomy, 605
 Vomiting after abdominal hysteromyomectomy, 658
 myomectomy, 548
 associated with myoma, 447
 stercoraceous, after abdominal hysteromyomectomy, 658
 myomectomy, 548
 Vulva, pruritus of, in myoma cases, 444
- WATER-CORE appearance in areas of hyaline degeneration, 95
 Weakness, profound, in myoma cases, 457
 Weather, hot, as cause of postoperative elevation of temperature, 655
 Weight, loss of, in myoma cases, 456, 572
 of myomata, 119, 512
 Worms, intestinal, after abdominal hysteromyomectomy, 659