

Fig. III.

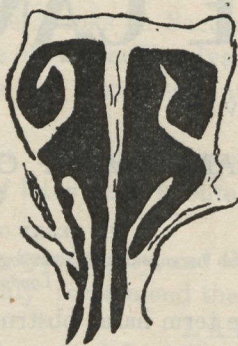

Fig. IV.

to find this condition in a case of atrophic rhinitis, where the inability to clear the nose thoroughly, hinders the proper treatment of the disease. I have, at present, a case of atrophic rhinitis in a patient, with congenitally small anterior nares, who is unable to satisfactorily carry out treatment, owing to this obstruction.

(b) *Collapse of the Alæ Nasi and constriction of the Lumen Vestibuli.*

This condition is readily seen, on inspection of the vestibule, by pushing the tip of the nose backward and slightly upward. If a nasal speculum be used, it should not be inserted far in the vestibule, as it may cover up the pathological condition.

This form of obstruction may be the sole cause of a marked nasal obstruction; or remain, as a cause of failure, after removal of an intranasal, or post-nasal obstruction.

The treatment is simply palliative, and consists in the use of rubber tubing to dilate the passage, and small rubber, or celluloid rings, which may be worn at night to allow of normal respiration.

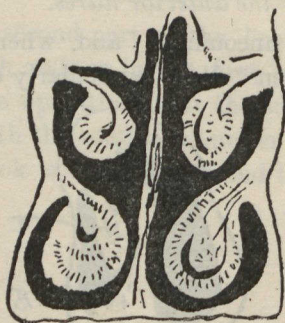


Fig. V.



Fig. VI.