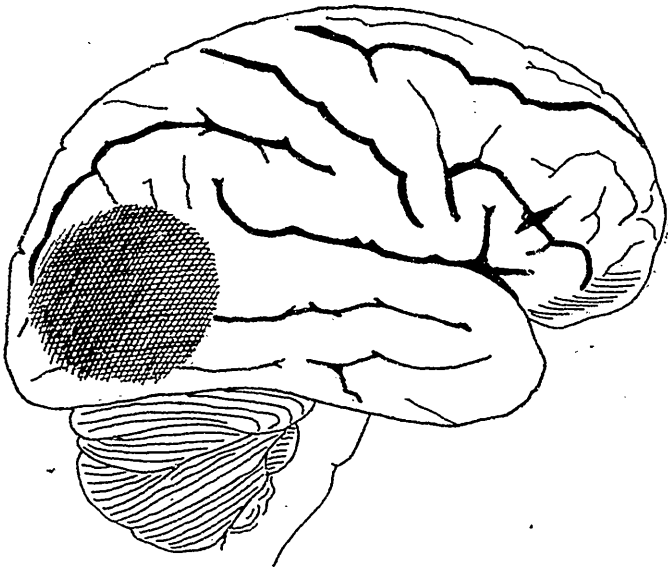


ment well and lost but little in flesh. He had no bed sores, and even up to the time of his death his flesh and skin had all the appearance of being well nourished. There was no headache nor vomiting in the history of the case.

I submit the following as the last notes in the clinical record in the case book: November 1st.—He continues in bed and quite helpless; face at times quite flushed; now totally blind; speaks sometimes with a slight pause after a question as though dull of comprehension, though the answer may be coherent; speech clear and fairly distinct; he is well nourished and quiet. November 12th.—No change except that he is gradually becoming fuller; urinary examination negative; he is quite helpless and dirty in his habits owing to loss



of control of his sphincters. November 20th.—Continues in the same helpless way. November 30th.—No change to record from last note. December 8th.—Temperature this evening was 101.3; face flushed and breathing heavy. December 9th.—Comatose condition more pronounced to-day; face quite flushed; temperature 101.2; pulse full 110; urinary examination negative; right pupil much dilated; left pupil greatly contracted. December 12th.—He did not rally from the coma which gradually became more pronounced since the 9th inst; temperature remained 101.1; pulse gradually becoming weaker and intermittent; he died to-day.

*Notes of Autopsy.*—Autopsy was made twelve hours after