

another operation, to be made two or three or many months later. He does not see fit to operate on both the hard and soft palate at the same time; we leave the lip operation for the last. Why should the surgeon close, to some extent, the opening through which he must make the operation upon the palate? Why should the space be shut off first, and after the door is half closed, so to speak, commence at the inside operation? When you introduce the posterior needle you need all the room you can get to carry it through, so that the operation on the palate should be first done, and then the operation on the lip may be made, because you have easy access to it. The oral specula can be made of different sizes.

15. Showed needles, made strong because we put them through the bone itself and carried out at the opposite side. Just the right form and shape so as to be able to guide them, and watch that they come out just right.

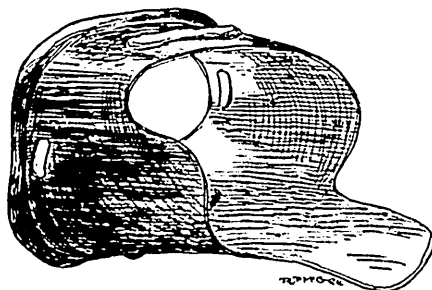


FIG. 14.

16. Casts projected upon the screen which will be rather convincing to any one who may consider the subject as to whether the operations should be made in early infancy for closure of the palate. Shows cast of the mouth of a boy twelve years old, in whom the teeth protruded. All these teeth lap over the lower ones. The lower teeth are not visible in one cast. The superior teeth lap over the inferior ones. The anterior ones are not visible. Succeeded in bringing the teeth so that they occlude with the lower teeth.

17. Shows posterior view of same condition; they lap outside. Had this child been operated on while young his teeth would have occluded quite properly.

18. There is a powerful argument in these two pictures. Proves that this does not lead to deformity in forcing the bones together; from the mouth of a boy five years old. Note the difference in the size of these two squares. Note the difference in the width, and measure the distance between the hemispheres of