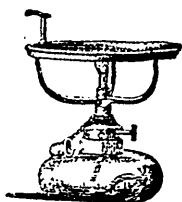


A CORRECTION.—The selected article in the last number, on "The use of Oxy-chloride of Zinc over exposed nerves," bears the name of Dr. I. A. Salmon, and we see by a correction in the *Register*, from which it was copied, that it was written by Dr. T. B. Hitchcock.



THE WHITNEY LAMP.—The accompanying cut represents an annealing lamp, designed by B. T. Whitney, M.D., of Buffalo, N. Y. It is intended for annealing gold, while filling. The arrangement for raising and lowering the wick at the pleasure of the operator is complete, giving the degree of heat required. The gold can be taken from the tray with any *instrument*, without having the temper of the instrument drawn by the heat. Alcohol is the proper material to burn in the lamp.

—The next No. of the Journal will contain the proceedings of the Hamilton meeting of the Dental Association of Ontario.

—Parties having more than one number of No. 1, and others to whom No. 1 was sent and who do not wish to subscribe, would confer a favor by returning them by post.

SELECTED ARTICLES.

NECROSIS OF THE LOWER JAW.

Jacob M., æt. 12. This patient, a stout, hale looking boy, came under Prof. Gross' observation last summer.—He had had a tooth extracted; during that operation the probability is that the alveolar process was broken, leading to inflammation followed by necrosis of the right side of the lower jaw-bone. The parts were scraped, some dead bone removed, and for a while the case was progressing favorably. Afterwards an abscess formed, and the lad presented himself last week with two papillæ, nipple shaped processes, over the right ramus of the lower jaw.

Necrosis is a very common affection not only of the jaw bone, but of various portions of the skeleton. In the jaw bone it may be produced by violence or be the result of ordinary inflammation, or inflammation of a specific character, scrofulous or syphilitic. In this case it was produced by injury inflicted in the extraction of a tooth. The alveolar process was