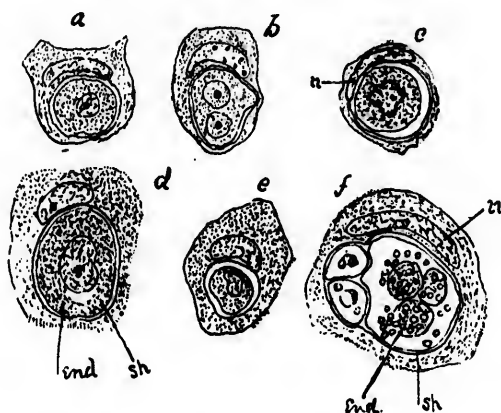


after Darier's method, slightly modified, the disease of the unremoved breast, and found there, as in the first case, the bodies in question. Figures 1 and 2 are drawn from preparations so made from Dr. Primrose's case.



(Fig. 1.)

#### EXPLANATION OF FIGURES.

Fig. 1.—*a, b, c, d, e*, examples of isolated epithelial cells with endocytes; *n*, the pushed-aside nucleus of the epithelial cell; in *b*, the endocyte has two nuclei; *end*, the endocyte, *sh*, its refracting membrane; in *f*, the endocyte has undergone a process of degeneration and disintegration.  $\times 500$ .