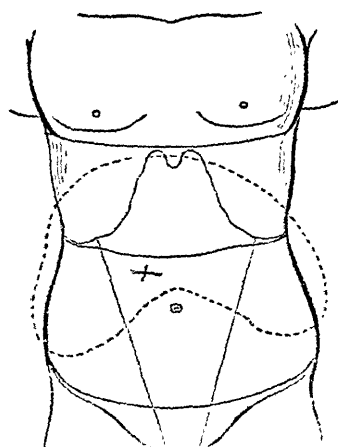


projecting from the epigastric region, extending on either into the hypo-chondriac. It has a firm, hard feel, and presents a knotted surface, with



quite a large sulcus a few inches above and to the right of the navel. Its margin can be distinctly traced, extending from the lower part of right lumbar region obliquely upwards to a point one inch above the umbilicus; thence downwards to lower part of left lumbar region. The abdomen is greatly distended, measuring thirty-six inches in its greatest circumference. There is dulness on percussion over the whole of the upper part of the abdomen, extending as far back as the vertebral column; in the lower part there is evident fluctuation. There is a slight

Dotted line showing limits of tumor. cough but no dyspnœa. She sleeps ill, and is greatly emaciated; complains of great weakness, and has considerable œdema of the lower extremities. Pulse 108, weak and regular; respiration easy and regular; percussion elicits dulness over the anterior portion of the lower half of both lungs: and auscultation elicits mucocrepitant râles in the same region. The intercostal spaces are much contracted from the upward pressure of the tumor. The complexion is sallow, but conjunctiva clear. The tongue is covered by a dirty, white fur, deepening at the centre to a yellowish brown. There is great thirst and little appetite; large quantities of food distending the stomach; and lately she has been troubled with vomiting soon after eating. The bowels are very costive and are moved only by the administration of purgatives. She reports her urine to be scanty and high-colored. She thinks the present attack began on the eighteenth of May last, when she first perceived the tumor; her attention being attracted to it by pain over the liver, accompanied by a swelling in the epigastrium, with œdema of the lower extremities. It has rapidly increased to its present size, accompanied by the emaciation and costiveness above mentioned. She says that she has been troubled by costiveness for the last eight or ten years, always requiring medicine to procure evacuations, and, as she says, has never had the jaundice. She has frequently applied as an out-patient, and was admitted in July, and received several enemata of turpentine and castor oil which afforded her some relief. She was discharged in August, at her own request, with