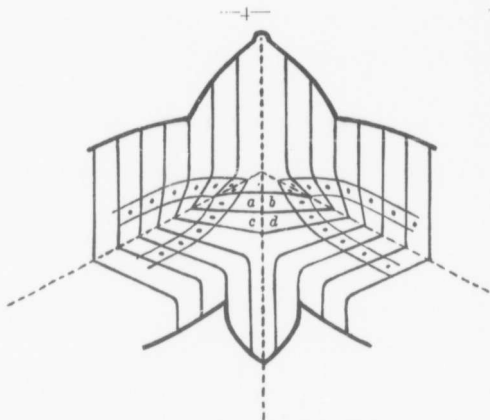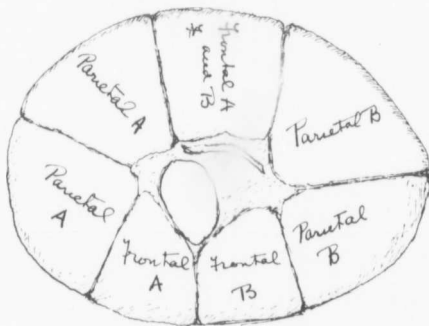


FIG. 2. ASYMMETRICAL JANICEPS MONSTER.

Apicopolar fusion at an angle less (or greater) than 180 degrees, with resultant failure to develop parts of the secondary face on the side of the lesser angle.

From General Pathology. J. G. Adami. Vol. I, p. 231.

## II. INCOMPLETE SIDE.



## I. COMPLETE SIDE.

FIG. 3.

Diagrammatic sketch of calvarium, showing two frontal bones on complete side (I), and single (fused) frontal on incomplete side (II). A and B refer to the foetus to which the various bones belong.