

in the absence of a specialist had been made worse by the use of atropin. Vision was abolished, the pain intense, with the usual objective symptoms of glaucoma, except the ophthalmoscopic ones, as it was impossible to secure even a red reflex from the retina. The patient would not allow the eye to be touched or operated upon, except imperfectly palpated to gain an estimate of the tension which I made out as between + 1 and + 2. By the use of eserin, leeches to the temple, etc., with appropriate general treatment, I

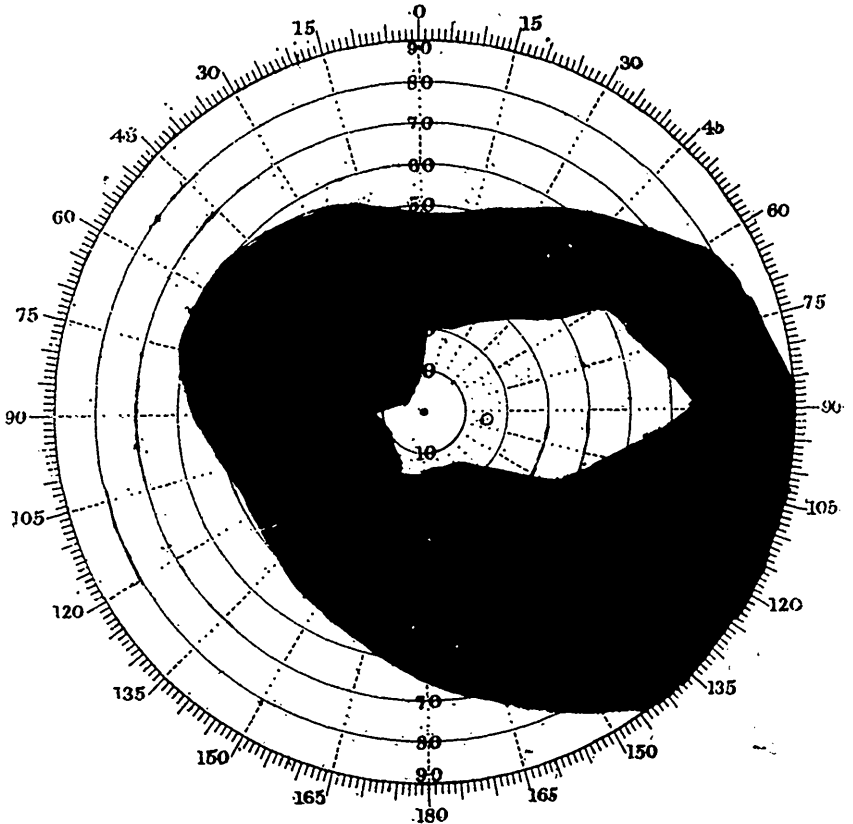


Fig. 2.—Form-field of same (Case 5209) on August 26th, 1898.

succeeded in allaying the pain and sensitiveness, but not the tension, until in about a month after the first visit I was permitted to institute treatment by massage. This soon brought down the tension to normal or occasionally slightly above. All symptoms of pain, etc., have disappeared. The massage is continued every day. The eye is blind and without retinal reflex. As a prophylactic measure I prescribed correcting lenses for the healthy left eye, the distance refractive error being + S. 2.50 D. + C. 0.50, ax. 45°. It would be interesting to know what it was in the ruined eye.