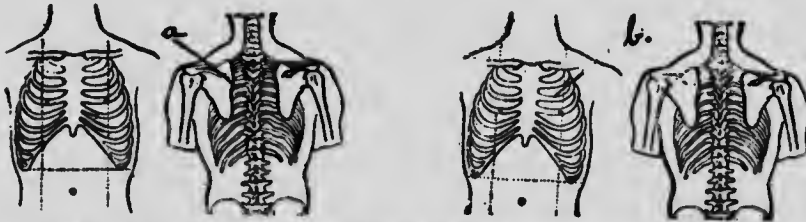
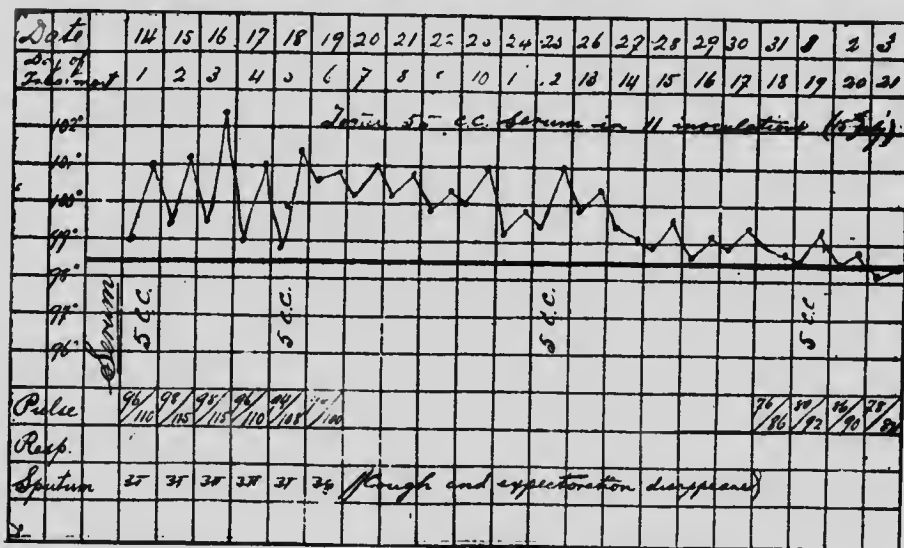


tion and almost an absolute distaste for solid foods. She managed to keep together during the winter, although feeling very miserable, and she came under our observation about the beginning of May, in a very pitiable condition. Pulse 120, temperature 101, chest examination revealed the presence of a focus posteriorly in the upper lobe, shown in the accompanying Fig., cervical glands on the right side standing out like a bunch of grapes, and the left cervical glands, while not



CASE V. FIG. 5.—a. Impaired resonance and sub-crepitant râles; b. cleared. Left figures, May 9th, 1904. Right figures, July 15th, 1904.



CASE V. CHART 5.

distinctly visible, were all quite the size of beans and easily felt. The bronchial glands on both sides were infiltrated. The study of her chart will give a better idea of what was done and what progressively resulted (Fig. and Chart 5). She was examined again on the 13th July, exactly two months after the serum treatment was commenced, and her lungs were then perfectly clear, while the glands had markedly diminished in size, were not at all painful, and