
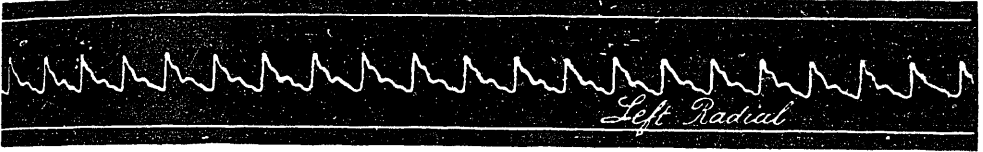


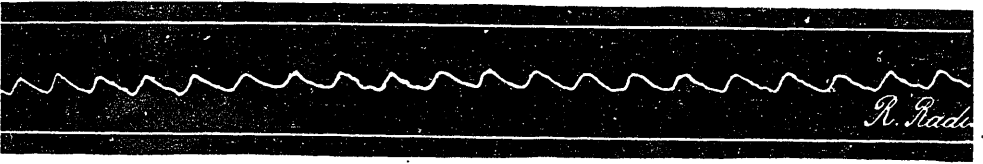
Left Ulnar.




Left Radial.




Right Radial.



Right Ulnar.



Aneurism.



Aneurism of Right Brachial.