

FIG. 3.  
Generalized Blastomycosis.

Low power—showing single military abscess of lymph node. A large giant cell containing two organisms is seen at the upper, righthand border of the abscess, and several other organisms can be seen in the section.




FIG. 4.  
Generalized Blastomycosis.

Higher power than Fig. 3. Peripheral portion of military abscess of lymph node. Several organisms can be seen.

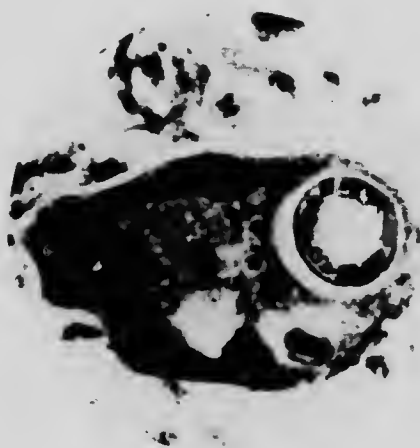


FIG. 5.  
Generalized Blastomycosis.

Giant cell with one organism in it. Stained with Mallory's connective-tissue stain. The narrow, white zone around the central, circular, darker-staining area is the peripheral capsule.