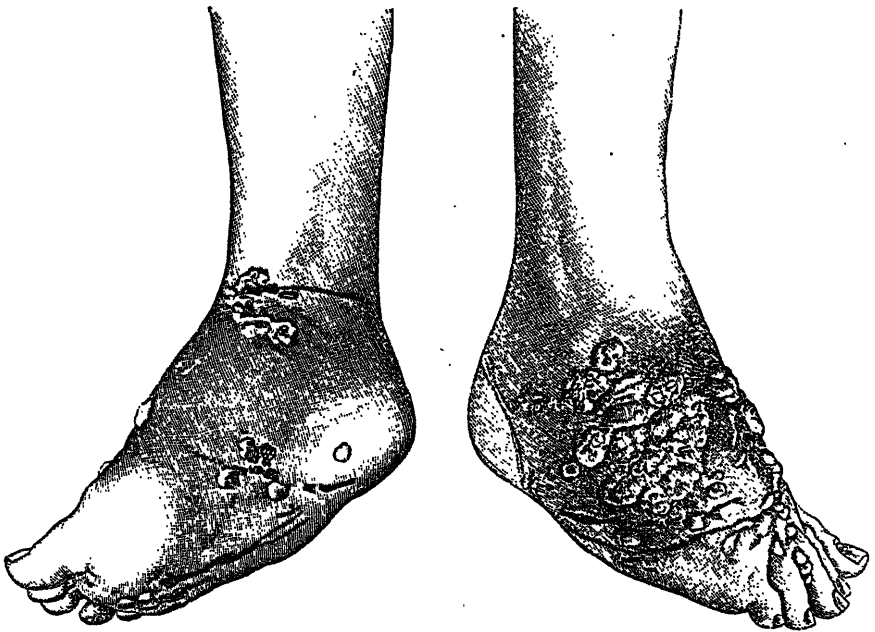


the usual history and appearances that it would seem improbable that he was dealing with a case of the disease proper. Thus, while we do not attach much importance to questions of priority, we think we may say at least that ours is the first indubitable case of mycetoma recorded as occurring upon the American continent in one who had never travelled outside that continent. We stated at Washington that if one case has occurred upon this continent, it is fairly certain that others have, and indeed Dr. Shepherd assures us that some years ago a patient of his at the General Hospital had a diseased foot resembling in all respects our own specimen, in external appearance and in the development of the very characteristic buttons of flesh forming the



From photograph of authors' case, taken by Mr. Patrick at the Montreal General Hospital, June, 1894, prior to operation.

opening of sinuses, and by a curious coincidence, at the nineteenth annual meeting of the American Dermatological Association, held here in September of this year, Dr. J. N. Hyde, of Chicago, exhibited to the Association drawings of a foot, together with prepared sections from the subcutaneous tissue of the same, and in ignorance of our previous publication before this Society and the Association of American Physicians, concluded that the disease did occur in America. Like ourselves he held that Kemper's case was certainly a most doubtful example of the disease; and indeed he went further and felt assured that it could not be the proper Madura foot.