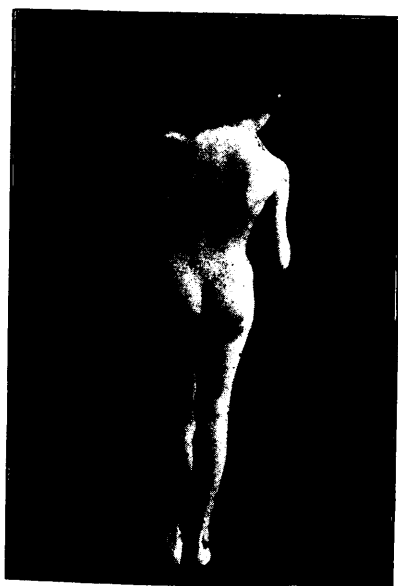


the upward ascent of the head is increased and the capsule is of necessity dragged with it. The shape of the capsule is changed from that of an irregular globe passing from the rim of the acetabulum to its attachment to the neck of the femur, becoming like an empty purse-bag glued to the iliac bone, the lower portion covering the acetabulum, the free portion enclosing the femoral head while there is a constricted portion or neck lying between.

This capsule stretched across the acetabulum and adherent to it becomes one of the chief obstacles in the way of successful reduction.

When the upper end of the femur has thus been allowed to lie upon the dorsum ilii for several years the soft structures become greatly shortened, and thus another obstacle is found to be in the way of satisfac-



tory rectification of the displacement. The pelvi-femoral muscles, especially the adductors are much shortened; so also are the pelvi-crural muscles.

These changes in the soft parts constitute the chief obstacles in the way of successful reduction.

When once a case of this kind has been carefully observed diagnosis, afterward, is comparatively easy in all such cases. In the adult and in larger children the attitude and gait are characteristic. In walking, if the luxation exists on both sides, the patient waddles like a duck; if on one side only, then at each step the body lurches to that side and is lowered as the end of the femur glides upward in its relation to the pelvis. There is marked lordosis if the luxation be double and on the dorsum ilii: if single there is less lordosis but the end of femur may be found as it projects into the soft tissues over the external iliac fossa.