

had no fever and the leucocyte-count was only 10,000. The stools were clay-colored. They were not examined at the time for amebæ, as there was no suspicion of abscess. She remained in the hospital two weeks and improved very much; she was afebrile throughout and was discharged very much better on November 26th.

She returned on December 30th, complaining

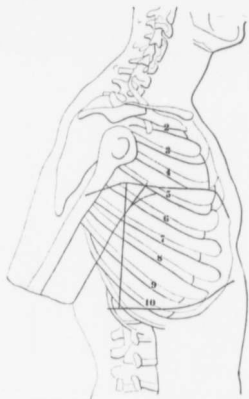


Chart 3. Showing the high limit of liver dulness in Case III.

of a great increase in the pain in the side, particularly on movement. She had a great deal of nausea, vomiting and insomnia. She was sallow, but not jaundiced. The edge of the liver could be felt three finger-breadths below the costal border, and there was irregularity of the