

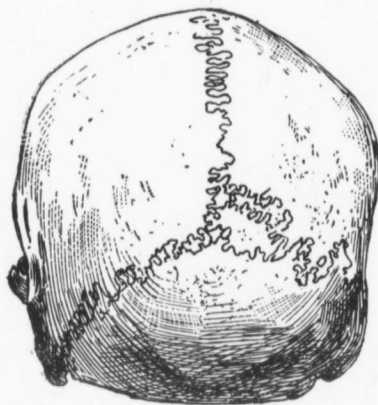Fig. 120. No. 54.

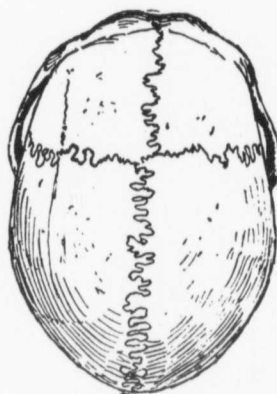


Fig. 121. No. 54.

*Cranioscopy.**Craniometry.*

		Millimetres.
Age, 25.....	1	197
Sex, male.....	2	138
Sutures, frontal suture present, serrations of all	3	132
the sutures complicated, the posterior	4	98
extremity of the frontal suture joins the	5	111
coronal to the right of the junction of the	6	112
sagittal.....	7	11
Pterion, H.....	8	115
Inion, 2.....	9	139
Lateral parietes, moderately full.....	10	73
Artificially lengthened occipital foramen, O..	11	47
Glabella, medium.....	12	298
Superciliary ridges, prominent.....	13	240
Frontal eminences, indistinct.....	14	295
Forehead, straight.....	15	535
Probola, prominent, globular.....	16	76
Sub-iniac curve, extends below condyles.....	17	140
Mastoid process, short, thick.....	18	56
Hollow at root of nose, very shallow.....	19	26
Inferior border nares, grooves shallow.....	20	70
Root of nose, very wide.....	21	70.8
Wormian bones, an os epactal and one also	22	88.3
about middle of lambdoid suture on left side.	23	67.0

See page 60 for Key to Measurements.