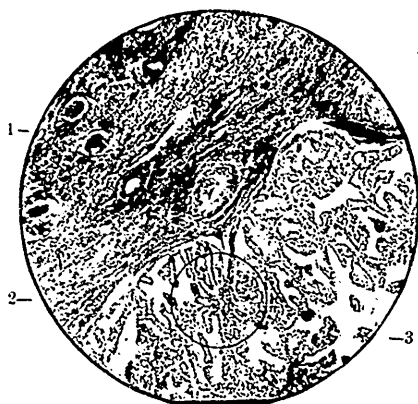


No. 1.

1. Renal Glomeruli. 2. Fibrous Septum.
3. Villous Growth.



No. 2.

High magnification of portion within circle (No. 1).



No. 3.



No. 4.

High power of No. 3.

HYPERNEPHROMA OF KIDNEY.