

(4) Division of the Gubernaculum and Fascial Bands.

The lower attachments of the gubernaculum are now put upon the stretch by pulling on the tunica vaginalis and testicle. The strength and extent of these vary a good deal, but, as a rule, they can be torn through, which has the advantage that it is less likely to be followed by bleeding than when knife or scissors have to be employed. After separation, the gubernaculum is

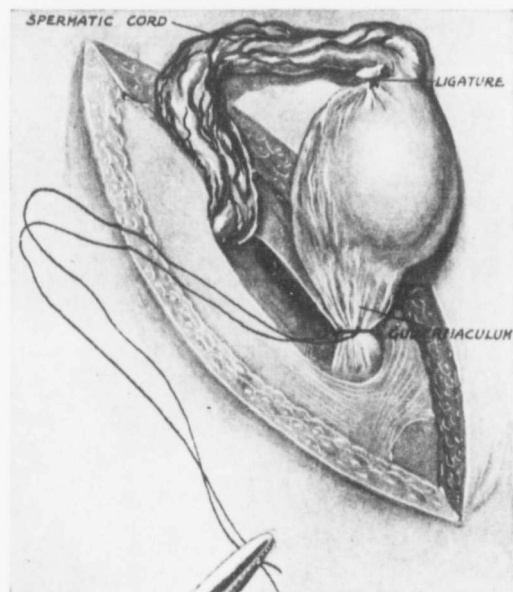


FIG. 15.

transfixed and ligatured by a needle threaded with strong catgut; this, as a rule, should also pass through the lower part of the tunica vaginalis (Fig. 15). The downward prolongation and the size of this structure enable this to be done without fear of injury to the testicle. It is important, however, to remember that the vas often forms a loop which extends in the tunica vaginalis for some distance below the epididymis; this can be detected by inspection and palpation, and, when this is done, it is easy to make sure that it is not included in the ligature.