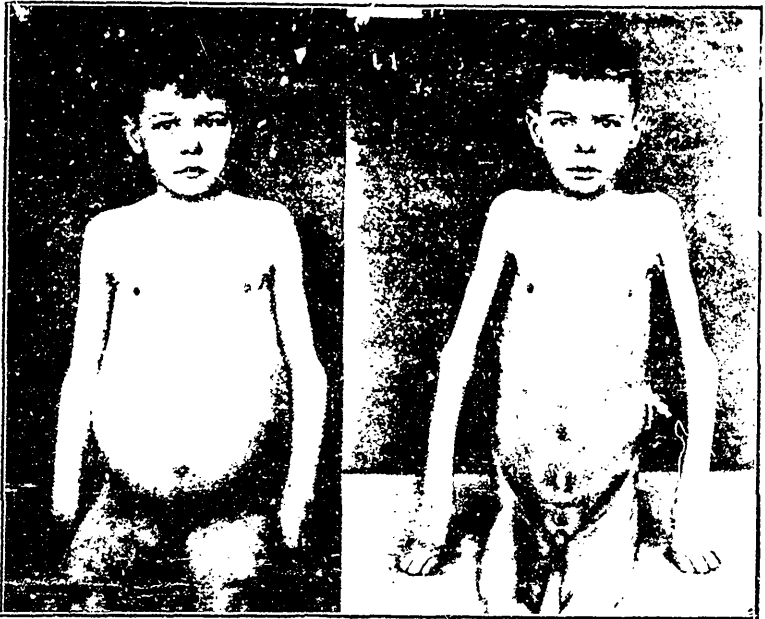


one might describe it as an ashy purple. In consistence I failed to find it abnormally tense. I first of all needled it, but no bleeding of any consequence came from the punctures: in fact, there was hardly any oozing. I then cut into the capsule with a scalpel along the convex border: in order to do so efficiently I cut fully one-quarter of an inch into the cortex of the kidney, and this cut was carried along about one and one-half inches: a drainage tube was placed down to this point, a few sutures were introduced, and a piece of iodoform gauze and dressing applied.

For a few days after the operation his condition was considered critical. During the first twenty-four hours he only passed seven



Photograph of patient on November 19th, 1901, two days before the first operation on the kidney.

Photograph of patient on February 3rd, 1902, forty-five days after the last operation on the kidney.

ounces of urine, and the facial edema greatly increased so that the eyes were almost completely closed up. The breath possessed a peculiar odor like stale urine (uremic), the temperature was normal, but the pulse 120. He soon began to improve, however, so that on the third day after operation he passed twenty-four ounces of urine and the pulse was 96: the patient was quite bright, and expressed himself as feeling much better.

The subsequent history indicated a gradual improvement in his condition, the amount of urine passed in twenty-four hours rose considerably until on December 11th (three weeks after operation) he