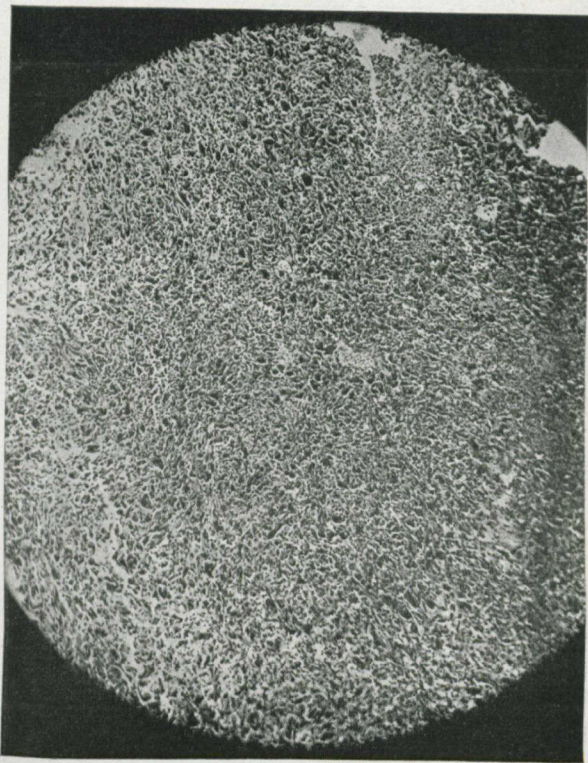


cells smaller as we neared the surface. These cells would also have been destroyed had radiation been continued.

We noticed that some of the carcinomatous cells were markedly hypertrophied, some were monstrous, some vegetative, whilst the protoplasm showed marked eosinophila, proving beginning de-



SECTION III.

Before exposure to Radium.

Low power view of sarcoma, showing large cells, irregular in size, shape and arrangement. Very little leucocytic infiltration is visible anywhere.

generation. The various tissue elements had become broken up and eosinophilic, young fibroblasts had evidently replaced the growth in the parts nearer the surface.

The second case from which we were able to obtain specimens was that of a railway fireman, twenty-eight years of age, referred by Drs. Bruce Riordan and R. A. Thomas. He received a blow over the right tibia in March, 1913. A swelling persisted