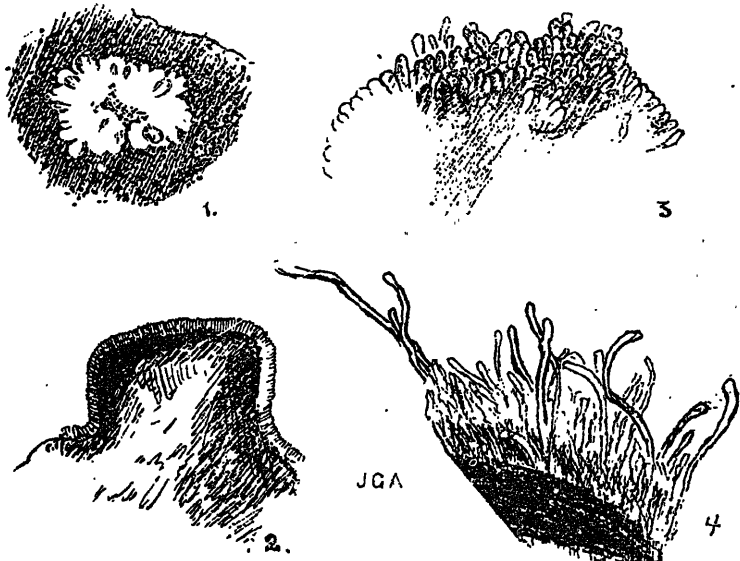


Only this afternoon we have received the information from Dr. Lamb, of the Army Medical Museum at Washington, that there exists in that museum a foot removed some years ago by Dr. Pope, of the U. S. Army Medical Service, from a Mexican in Texas, and presenting all the characters of mycetoma pedis. The condition would seem to have been recognized as such at the time of removal, and the clinical history given is said to bear out the diagnosis. Dr. Lamb believes that the case has not been published.

With great courtesy Dr. Hyde has placed his material at our dis-



1. Reniform fungus mass lying in granuloma of small round cells, Dr. Hyde's case (hæmatoxylin and eosin). Zeiss eye-piece, 4 lens A. Outlined by Zeiss' camera lucida.

2. Portion of fairly large fungus mass higher magnification, author's case (eosin and methylene blue). To show arrangement of peripheral clubs and central mycelium. Zeiss Oc. 4. Apochromatic 4 mm.

3. Portion of another mass, still higher magnification, author's case. Discharge from sinus mounted in glycerine, to show peripheral clubs. Zeiss eyepiece, 4 lens D.

4. Ditto, to show giant clubs.

posal, and indeed has forwarded to us the whole of the removed limb with the exception of the great and second toe, with the solitary stipulation that we should return to him the preparation of the bones. This evening, with his permission, we bring before the Society the mounted preparation of the bones from his case, and for comparison exhibit at the same time our own specimen, which has not yet been shown to the Society. It will be seen that the diseased bones have strongly marked characters. These characters had already been pointed out by Vandyke Carter more than twenty years ago. We do