

CASE 3. Mrs. S., aged 35, with a physique and general appearance much like Case 2. She had recurrent attacks of vomiting for over two years. She was very neurotic. The lesser curvature of the stomach was at the umbilicus. Both kidneys were movable, and could be grasped in the erect position. (Fig. 3.) The right was slightly tender. She improved under treatment with massage, abdominal gymnastics, careful dieting, and out-of-door life. She was given strychnine and antiseptics. In addition, a well-fitting bandage was worn to support the stomach and kidneys. For a time she was quite relieved, then the symptoms returned with their old violence. Nephrorrhaphy was recommended, but

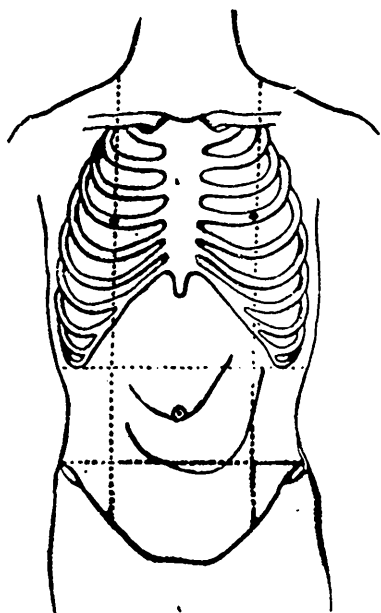


FIG. 1.—By inflation with air.

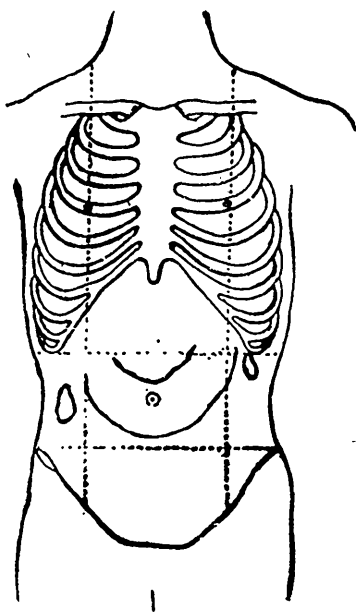


FIG. 2.—By inflation.

not assented to. In this case the symptoms were chiefly due to the hysteric or neurasthenic state, which was probably rather aggravated than caused by the enteroptosis that existed.

CASE 4. In a similar case in a postman, careful treatment resulted in no benefit, nor did a prolonged stay at a well-equipped sanitarium. I advised the fixing of the right kidney, which was freely movable. Later he came into the care of a surgeon who not only did that but also removed an unoffending appendix. He is considerably improved by the operation and able to carry on his work with some degree of comfort.

Suturing the kidney in place even when much dislocated and