

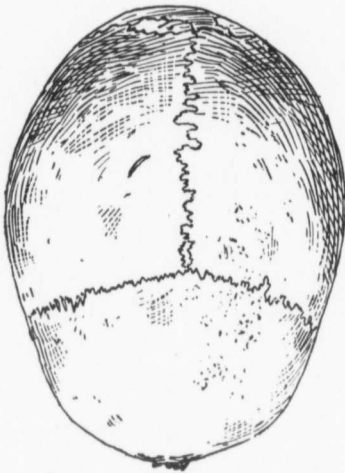Fig. 122. No. 64.

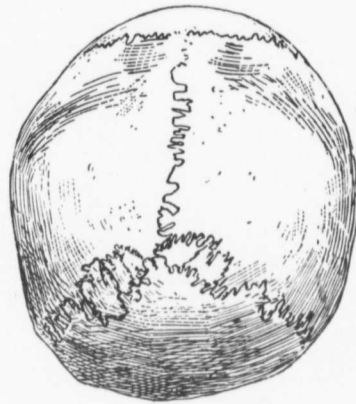


Fig. 123. No. 64.

*Cranioscopy.**Craniometry.*

		Millimetros.
Both zygomatic processes wanting.	1	187
Age, 25.....	2	145
Sex, female .....	3	128
Sutures, serrations small and intricate.....	4	98
Pterion, H .....	5	118
Inion, 2.....	6	120
Artificially lengthened occipital foramen, I....	7	9
Lateral parietes, protuberant. ....	8	117
Glabella, small .....	9	113
Superciliary ridges, absent.....	10	89
Frontal eminences, fairly distinct.....	11	29
Forehead, straight .....	12	294
Probola, prominent, globular.....	13	240
Sub-iniac curve, on level with condyles.....	14	285
Hollow at root of nose, absent, root of nose wide	15	525
and flat.....	16	82 (app.)
Wormian bones, 9 present altogether, 5 in upper	17	
part of lambdoid sutures, 3 to right of	18	52
lambda and 2 to left, also a small one in	19	30
angle between squamous and mastoid	20	77.5
sutures, 2 more in lower end of right limb	21	67.5
of lambdoid suture and a ninth in occipito-	22	83.0
mastoid suture; largest in left lambdoid 27	23	68.4
millimetres long.		