

## 78 The Imperfectly Descended Testis

This ligature is not cut short, but the extremities of the free ends, each of which should be about six inches in length, are secured by a pair of Spencer Wells' forceps (Fig. 16). The cord is next inspected, and any fascial bands remaining from the sheaths of

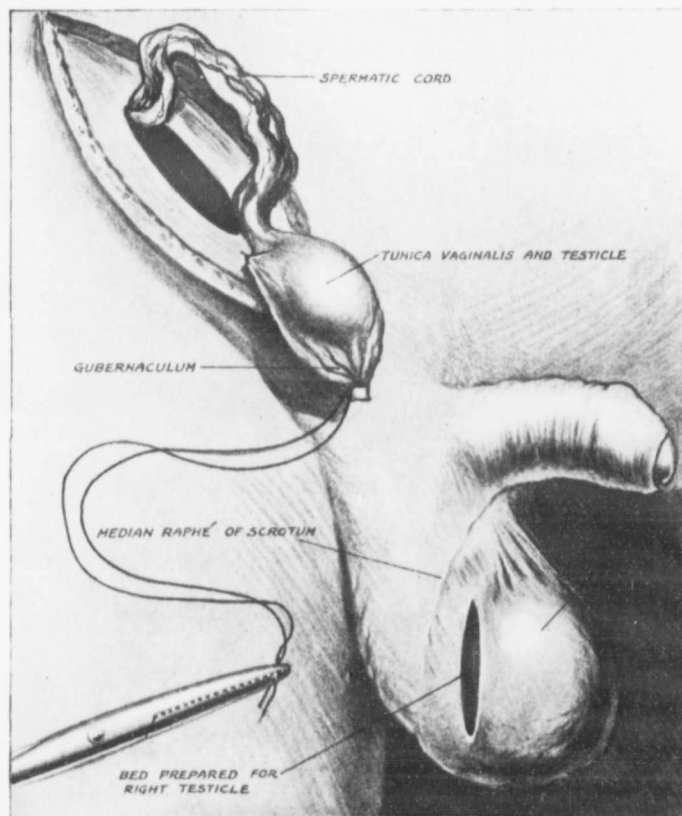


FIG. 16

cremasteric and infundibuliform fasciae, which become tense and prevent the descent of the testis, are torn across or divided. It has already been pointed out that shortness of the veins is an unusual complication, and that insufficient length of the vas is a still rarer condition. When these unusual hindrances to transplantation are present the testicle is usually arrested