

Man, age 25, referred by Dr. R. H. for painful condition of right hip, both knees and feet. The left foot in particular was rigid, swollen, and so painful that walking was difficult, and the knees could not be completely straightened. He had taken ill suddenly with painful feet sixteen months previously, and had not been able to work since. He was treated at a hospital in the city of K. for three or four months, moved to C., his old home, and was under hospital treatment for a similar period. Then came to Toronto and continued treatment being referred at the time I saw him, owing to no improvement, and progress of the disease. During that sixteen months his difficulties had increased, in spite of all the medicines, anti-rheumatic and otherwise, which had been prescribed.

On searching for a cause, which is my custom in all these conditions, the mouth presented sufficient evidence. Twenty-two teeth were diseased and pus was exuding from a considerable portion of the gum margin.

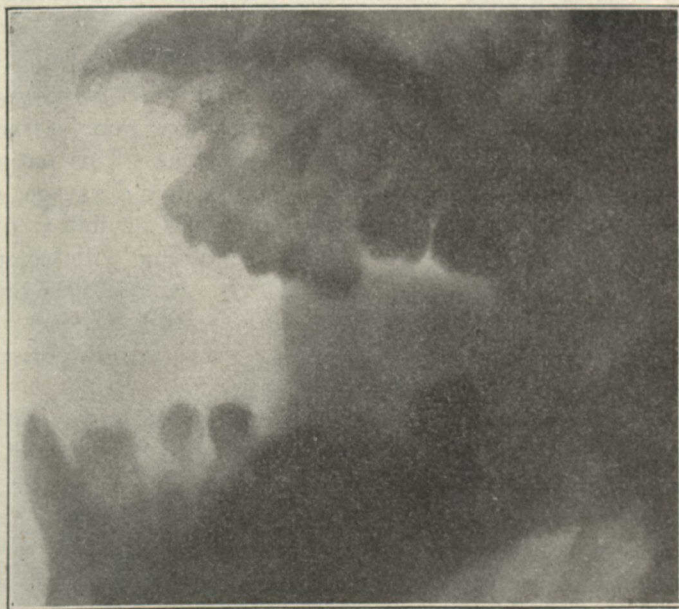


Fig. 5

X Ray of Mouth where 22 Teeth were diseased, 4 with Chronic Abscesses.

*Treatment.*—A vaccine prepared from the pyorrhoea discharge of the gums.

(2) Dental treatment of teeth.