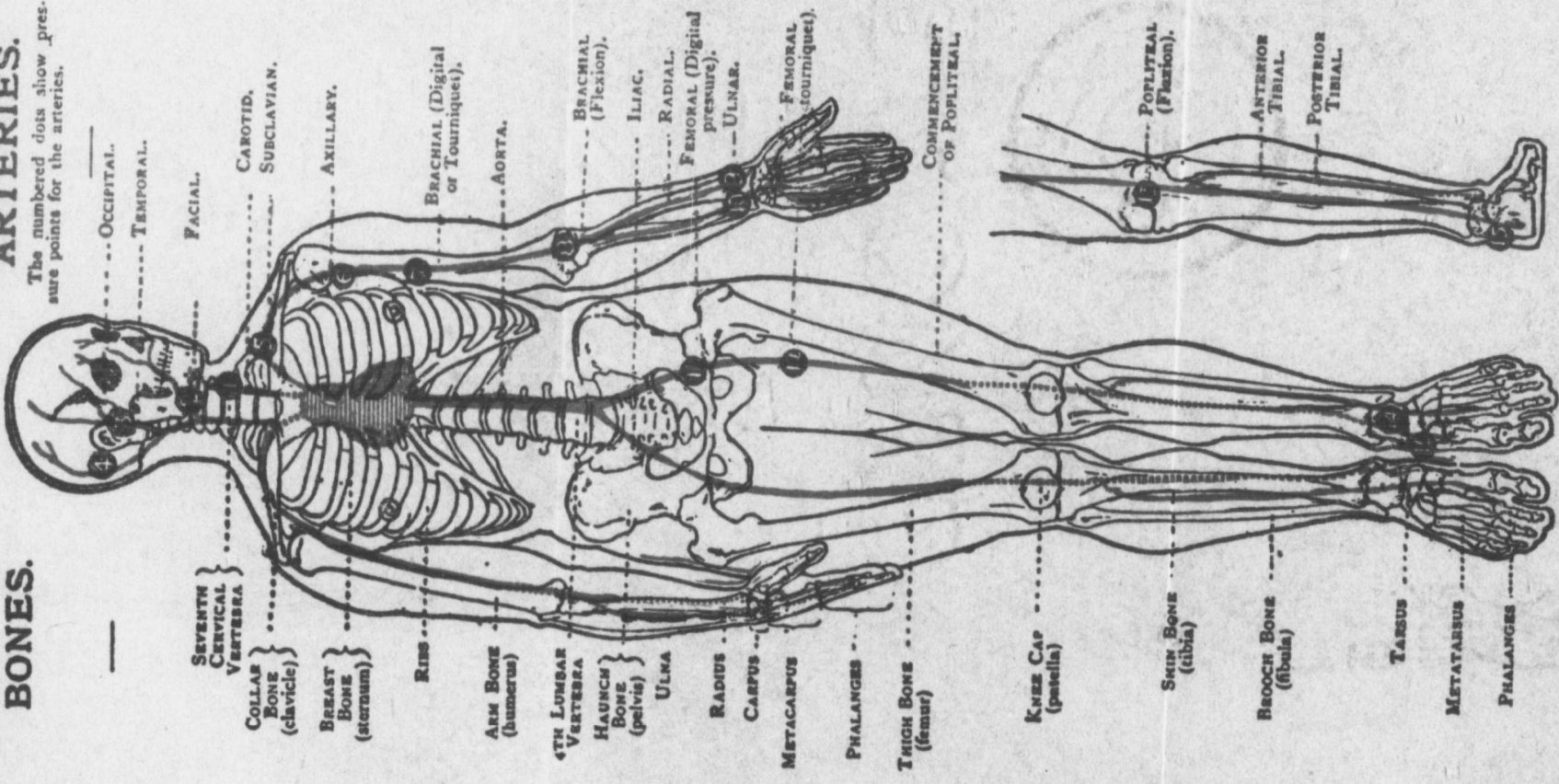


ARTERIES.

The numbered dots show pressure points for the arteries.

BONES.



--- OCCIPITAL.

--- TEMPORAL.

--- FACIAL.

--- CAROTID.
--- SUBCLAVIAN.

--- AXILLARY.

--- BRACHIAL (Digital
or Tourniquet).

--- AORTA.

--- BRACHIAL
(Flexion).

--- ILIAC.

--- RADIAL.

--- FEMORAL (Digital
pressure).

--- ULNAR.

--- FEMORAL
(Tourniquet).

--- COMMENCEMENT
OF P oplITEAL.

--- P oplITEAL
(Flexion).

--- ANTERIOR
TIBIAL.

--- POSTERIOR
TIBIAL.

--- SEVENTH
CERVICAL
VERTEBRA

--- COLLAR
BONE
(clavicle)

--- BREAST
BONE
(sternum)

--- RIBS

--- ARM BONE
(humerus)

--- 4TH LUMBAR
VERTEBRA

--- HAUNCH
BONE
(pelvis)

--- ULNA

--- RADIUS

--- CARPUS

--- METACARPUS

--- PHALANGES

--- THICK BONE
(femur)

--- KNEE CAP
(patella)

--- SHIN BONE
(tibia)

--- BUCKLE BONE
(fibula)

--- TARSUS

--- METATARSUS

--- PHALANGES