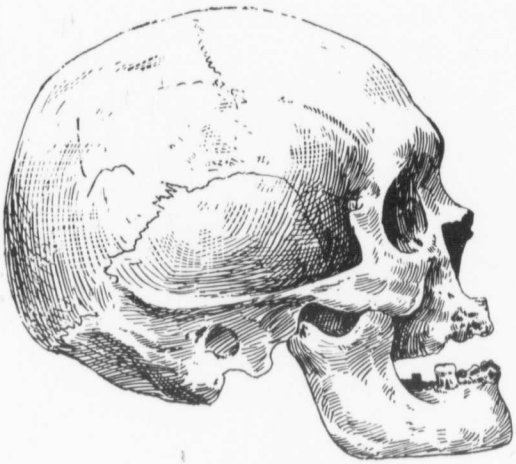

Fig. 112. No. 42.

Cranioscopy.		*Craniometry.*
		Millimetres.
Left zygoma gone.	1	194
Age, 60	2	144
Sex, male	3	152
Sutures, very simple serrations	4	94
Pterion, H.	5	117
Artificially lengthened occipital foramen, below	6	111
A	7	14
Inion, 4	8	120
Lateral parietes, moderately full	9	132
Glabella, very prominent	10	58
Superciliary ridges, very prominent	11	50
Frontal eminences, slightly marked, united	12	318
Forehead, straight	13	238
Probola, slightly protuberant	14	294
Sub-iniac curve, slight	15	532
Mastoid process, thick, rough, of medium length	16	82
Hollow at root of nose, pronounced, deep	17	148
Inferior border nares, grooves shallow and wide	18	53
Muscular attachments on occiput very strongly	19	27
marked	20	74.2
	21	65.2
	22	71.7
	23	78.3

See page 60 for Key to Measurements.