

and raising it to a higher level by shortening the fascial sheath. This operation was described in the *Lancet*, 1917, Vol. I., p. 759, and the following account is founded upon that description :—

#### Exposure of the Spermatic Cord.

The spermatic cord is exposed by a short incision, about an inch in length, just below the external abdominal ring. When superficial bleeding vessels have been secured, the cord, enclosed in its fascial coverings, is raised from its bed, freed and drawn

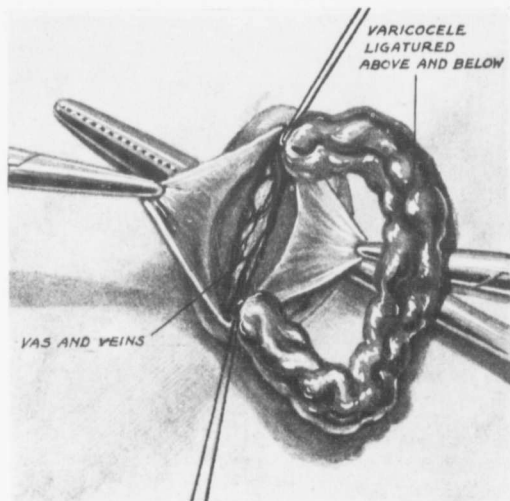


FIG. 20.

out of the wound until the upper end of the tunica vaginalis is brought into view.

#### Incision of the Sheath and Separation of the Varicocele.

With a knife, or a sharp pair of scissors, an incision, an inch and a half or so in length is made through all the fascial coverings in the mid-line in front until the veins are exposed (Fig. 19). The middle of the incision through the sheath is secured on each side by a pair of Spencer-Wells' forceps, which act as retractors. With a blunt dissector the veins are separated on each side until the vas, which, with its artery and