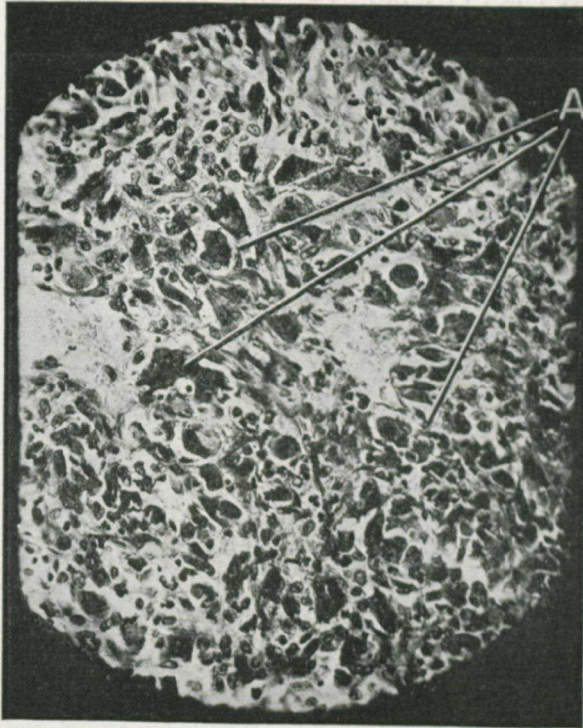


and was incised in January, 1914, under the impression that it was an abscess.

A report of the tissue examined was that it was a myeloid sarcoma, but the development of a secondary mass in the right groin indicated that it was of a more malignant type, and on a



SECTION IV.

Before Radium.

High power view of section of sarcoma. Note the huge cells, mitotic figures everywhere.

A.—Huge cells, vegetative type.

second examination the tumor was found to be a round-celled sarcoma. Dr. Riordan wished him to have the benefit of radium, although the case was most unfavorable owing to metastatic development.

Radiation was accordingly undertaken, and three weeks later a portion of tissue was removed for examination from the primary lesion. The striking changes induced by the radium rays