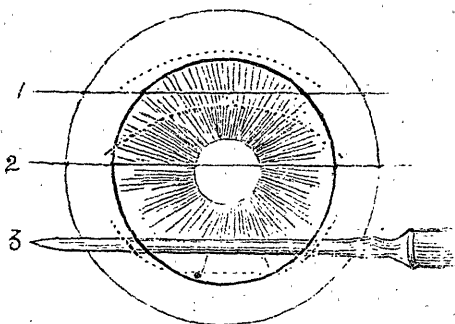


surgeons, that it was often difficult to decide whether in some instances the most appropriate designation would not have been "flap operation with iridectomy;" or in others, whether it should not be named "linear of Von Gräfe." But since the sclero-corneal junction was always to a greater or less extent involved in the incision, which however was never made so far back as in the scleral or linear extraction of Von Gräfe, or so far forward as in the old flap operation, I have determined to adopt the name sclero-corneal for all the operations done at Moorfields, which do not belong distinctly to one of the other classes mentioned.

Under this head then the larger number will be classed. There is a much smaller number of the oblique corneal



section, still less of the flap extraction, and in addition to these are a few in which the incision was made with a keratome, and the lens removed by a scoop. These last, only twelve in all, retain the old name of "scoop extractions," and form accordingly a class by themselves.

Before proceeding any further a few words as to why certain operations for the removal of cataract have fallen into disuse may not be out of place, inasmuch as they may help us to form clearer ideas in regard to the causes of failure or partial failure, which still too often attends each of the three operations now most frequently practised; for it is only by clearly recognizing these causes that we can