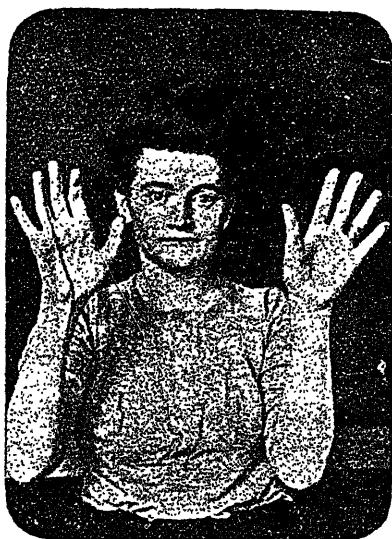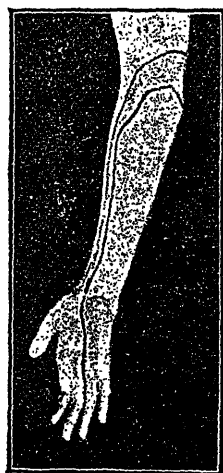

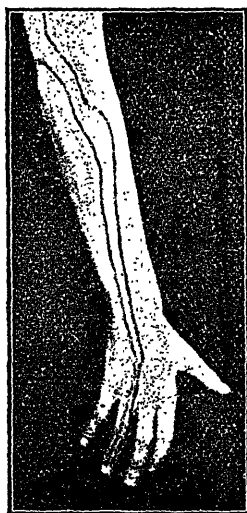
already reported, and second, if there were adhesions with the apical pleura one could not imagine elevation of the arm relieving pain. One would think it would rather increase it by traction.



In this case, as in the others, the paralysis, both motor and sensory, is confined to the distribution of the 8th cervical and 1st dorsal roots.



In my former report other etiological factors have been discussed. In this case I would like to add that loss of weight seems to have been a factor to a large extent.