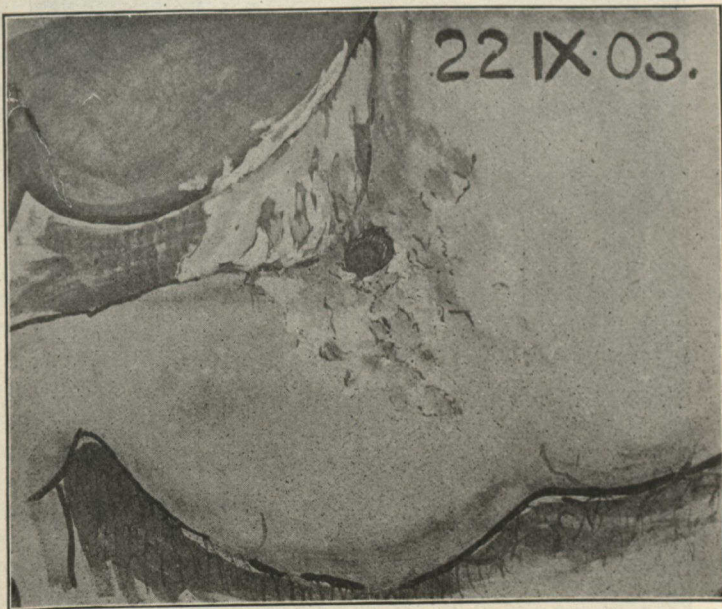


being closed. Excision of the ulcer is not to be recommended. It means loss of time and loss of blood without corresponding gain.

Where there is much perigastritis with unyielding or a friable tissue, a series of interrupted Lembert sutures (silk) may be introduced at some little distance from the margin of the ulcer and tightened up en masse. Over these a second series may be required. Occasionally a preliminary stitch or two may be used to transfix the whole thickness of the ulcer, and so diminish its size.



CASE 4.—Perforation near lesser curvature, early hour glass contraction of stomach.

A trace of iodoform may be rubbed in to favor plastic repair. If a gastro jejunostomy be required it is now performed. The flushing out should be completed by douching every peritoneal recess till the saline returns perfectly clear. Finally the abdominal wound is closed. We have always left a large Keith's tube in the pouch of Douglas, and have generally drained the site of perforation with a Mikulicz tampon and drainage tube.

The head of the patient's bed should be raised about six inches in order to favor the gravitation of any discharge from the dangerous absorptive region of the diaphragm towards the less susceptible pouch of Douglas.