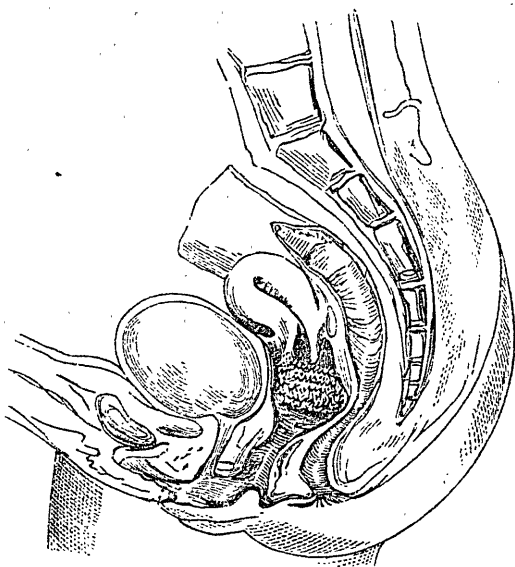


Dec. 20th, 1875. Had always been strong. Never knew what it was to be sick. Had one child four years ago, and never been pregnant since. Had always been regular in menstruation until two months ago when she became unwell and remained so ever since. Hæmorrhage had been so great lately that she felt herself getting weak, and was subject to fits of giddiness. She had never suffered any pain till lately ; she had pain in her back and down her thighs.

On examination with the finger immediately felt a mass as large as a hen's egg, flat in surface, which was rough and



rough, growing from the anterior lip of the cervix, its attachment being broad and sessile, the whole lip being much enlarged and thickened. The posterior lip and os uteri could be felt behind the growth by tilting it forward. The examination caused no pain. Upon introducing Sim's Speculum the growth was brought into view. The surface of it was covered with a bloody and slimy discharge, the removal of which disclosed a rough, ragged-looking surface