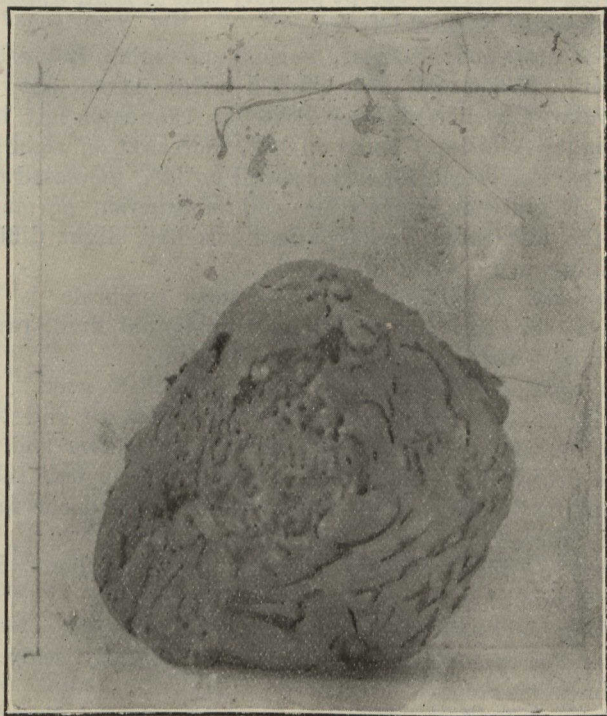


passed involuntarily; Dec. 24, 25, condition about the same. Much vomiting and severe headaches; Dec. 27, condition worse. Cannot move fingers. Slight movement at knee. Patient transferred to surgical ward and prepared for operation. Slight flexion in toes of left foot present; Dec. 28, headache is severe this morning. Urine passed involuntarily. At 11 a.m. patient was operated upon by Dr. George A. Bingham.

*The Operation.*—An osteoplastic flap, including scalp and cranium, was turned down exposing the motor area on the right



side. After incising the dura a tumor as large as a hen's egg presents itself, in the upper part of the ascending frontal convolution and encroaching upon the superior and middle frontal convolutions. This was rapidly dissected out of its bed; and the hemorrhage, which was free, was readily controlled by pressure. Some gauze packing was left in situ. The flap was restored to its position and the wound dressed in the usual manner. At 12.30 the patient