

It was quite a task to make reduction, and it was only accomplished by using a very heavy bone elevator as a sort of pinch bar, over the astragalus and under the os calcis, thus throwing the margins of these bones free. After a long siege the wound was entirely healed. The ankle was ankylosed, but otherwise the foot is quite useful.

I might remark at this time that the ankle motion is not necessary to graceful locomotion.

Case 5. J. L., aged 24, a brakeman, suffered a compound dislocation of the second joint of the left middle finger, the joint surface being plainly visible. This wound was closed under antiseptic precautions and healed promptly without infection. In two months motion was perfect.

Case 6. M. B., aged 50, was walking along the railroad, and a train backed up and knocked him down between the rails, the entire train passing over him. The arm being flexed, the elbow was caught under a wheel and the entire joint crushed, except the head of the radius. I saw the case in a few hours in consultation with Dr. Grove. As the circulation appeared good, I decided to remove the detached pieces of bone and trim up the lower end of the humerus and upper end of the ulna, drain and close the wound. The injury occurred on Monday, and on Friday the drainage tube was removed, and on Saturday, the eighth day, the next dressing was made, and this was renewed once per week. The skin that was destroyed by the wheel, came off as a dry slough. The wound healed promptly without subsequent complication. One year after the accident, the arm is almost as useful as before the bones were removed. With the arm hanging down, the forearm can be fixed to a right angle. He is now working at his former occupation as a trackman, and suffers little inconvenience. The exact drawings of the bones removed are shown in Figs. 1 and 2.—*Int. Jour. of Surgery.*

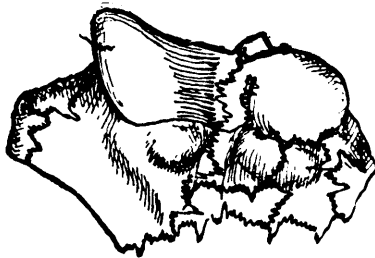

Figure 2.

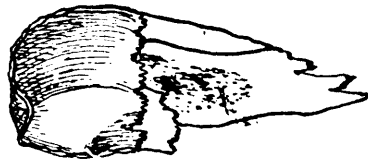


Figure 1.

A heaping tablespoonful of washing soda to a quart of water, is the proper proportion for the solution in which instruments should be boiled for sterilization. *Do not* boil non-metallic sutures in this liquid, for it will very greatly weaken them. *Do not* boil an aluminum instrument in this liquid, for it will be corroded and completely ruined. Silk sutures and aluminum instruments may be sterilized by boiling in five per cent. carbolic.