

finds pus in the hiatus draining from the frontal sinus, he should not be in too great a hurry to do any radical intra-nasal or external operation. Not infrequently one finds in elderly people, who are on the downward path, evidences of chronic antral trouble which is only of real distress in the winter time. I think we are too eager to do some

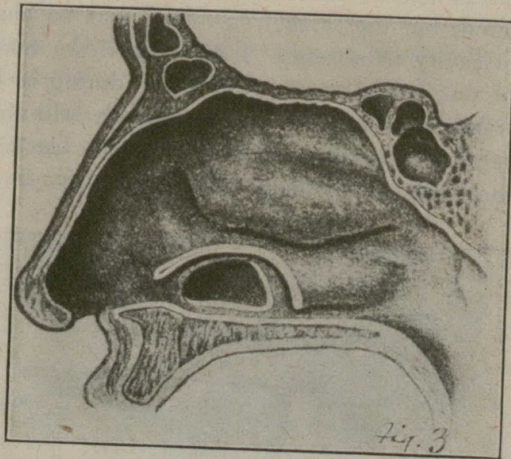


FIG. 3.—Perforation completed for radical antrum operation through inferior meatus.

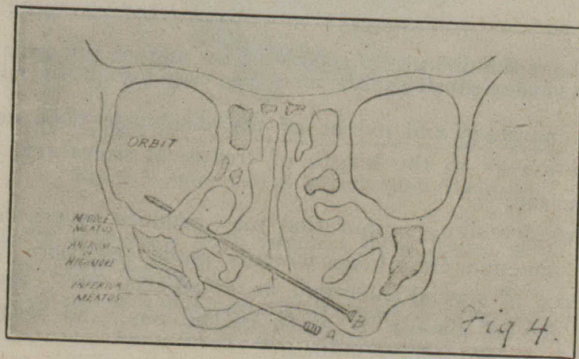


FIG. 4.—Section through the nose, showing trocar entering the orbital cavity through the middle meatus, when the lateral wall slopes outward. A second needle enters the antrum through the inferior meatus.

operation when we might better temporize and tide them over their bad season. In fact, they generally demand this course.

(8) What do we mean by cure of sinus disease? Strictly speaking, a cure would mean a return of the mucous membrane to the normal. In acute cases one can expect such to take place, and frequently it does without any help to nature. In chronic cases, however, when there has