

sphincters are, after the liberating cut about the anus, exposed by a rapid dissection, and the mucous membrane and attached hæmorrhoids, thus separated from the submucous bed upon which they rested, are pulled bodily down, and divided points of resistance being snipped across, until they are brought below the margin of the skin at the anus. The mucous membrane above the hæmorrhoids is now divided transversely in successive stages, and the free margin of the severed membrane above is attached, as soon as divided, to the free margin of the skin below by a suitable number of sutures. The complete ring of pile-bearing mucous membrane is thus removed in successive snips. The bleeding vessels throughout the operation are twisted when divided. The operation is done as is usual in the lithotomy position. Before the wound is closed iodoform is blown in between the raw surfaces. For the stitches carbolized silk is used. These are not taken out. They are allowed to come away of themselves without further interference. In the three hundred cases reported by Mr. Whitehead not a single death or instance of secondary hæmorrhage, or any complication, such as ulceration, abscess, stricture, or incontinence of fæces has occurred.

Since last October I have had occasion to resort to this operation in six severe cases of hæmorrhoids. The first occurred in a man, aged thirty-two, who had had hæmorrhage from the rectum, to a greater or less extent, for nearly ten years, with occasional intervals of freedom from the loss of blood. On October 28th, an operation according to Whitehead's method (see Figs. 1 and 2) was done, with the removal of nearly three-quarters of an inch of the entire circumference of the rectum, which contained throughout evidences of hæmorrhoidal changes, marked in four places by swellings, which, prior to the removal, were as large as a hickory-nut, and in other parts by numerous varicose veins of varying size. At first there was some difficulty in dissecting up the mucous membrane from the protruding pile, and, in fact, this cannot be done, as the hæmorrhoid involves the mucous and submucous tissues. It is necessary to go somewhat through the pile, looking out carefully for muscular tissue, and keeping to the inside of this until the mucous membrane, recognized by its lighter color, is reached above the pile region. After this latter membrane has been found its separation from the muscular tissues is very easy, only an occasional snip of the scissors being required to detach adhesions, muscular or otherwise. Much less pain was experienced after this operation than is often observed after the operation of ligating piles.

On the eighth day the line of suture was entirely healed. The stitches were not removed, but were allowed to come away of themselves. A week later he was discharged from the hospital perfectly well, with a clean and well-shaped anus, only one

or two stitches being still found attached to the skin. These, however, were not troubling the patient. He was seen several months later, and the anus presented a perfectly satisfactory appearance.

The second case was met with in a man, aged, thirty, whose hæmorrhoidal protrusions occurred

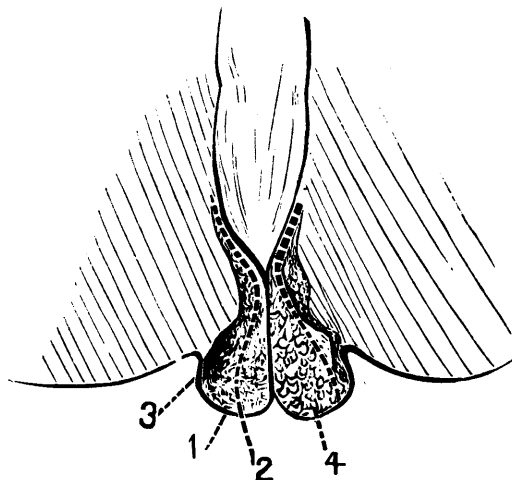


Fig. 1.—1, Muco-cutaneous junction, exaggerated; 2, line of incision, a short distance from muco-cutaneous junction; 3, external sphincter muscle; 4, protruding pile.

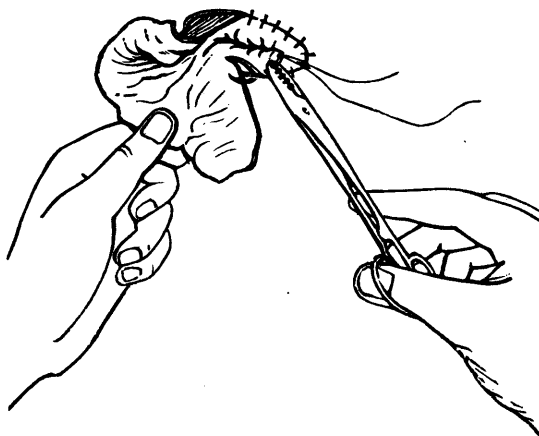


Fig. 2.—Mode of cutting off pile-bearing mucous membrane and stitching it in repeated sections.

one year ago after straining at stool. They have continued at times to bleed. Associated with these was a painful sensation in the rectum. By examination a circle of moderate-sized hæmorrhoids was seen extending all around the lower edge of the rectum, two of which were ulcerated.

On November 5th, Whitehead's operation was performed according to the manner above described. Nearly an inch of the rectal mucous membrane was removed. Bleeding vessels to the number of