

renders radical operation futile. Other authorities—notably Roux of Lausanne—have shown that it is possible to remove the testicle, vas deferens in its entirety, and the seminal vesicles at one sitting, and have thus very much enlarged the number of cases capable of cure by operation.

In recent years various operations have been advised to reach

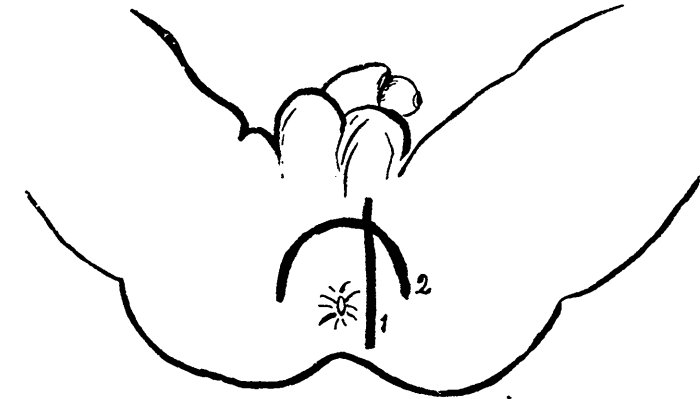


Fig. 1. 1. Incision of skin.  
2. Incision of vas deferens.

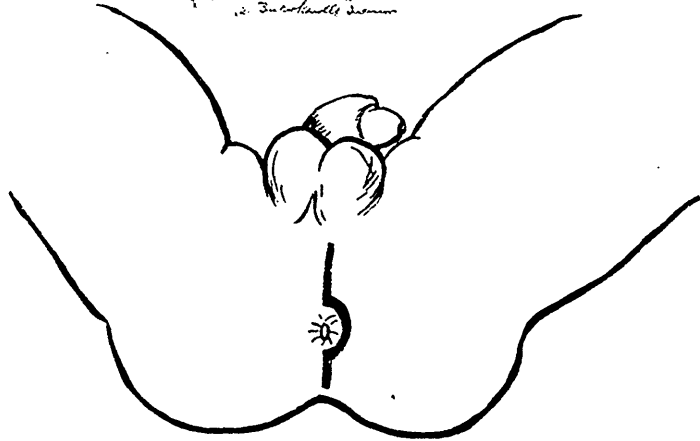


Fig. 2. Incision of scrotum.

the vesiculæ. The route by the inguinal region involves an, exceedingly deep dissection with great danger to the bladder and peritoneum, and is so manifestly inferior to other methods as to be unworthy of further consideration.

The sacral route, with removal of part of the sacral mass, as in Kraske's or Rydygier's operation for excision of the rectum seems to me unnecessarily severe, and can seldom be required