

the first day for one minute and a half, and for the same time on the following day. A fortnight later the mother wrote us that her baby was completely well."

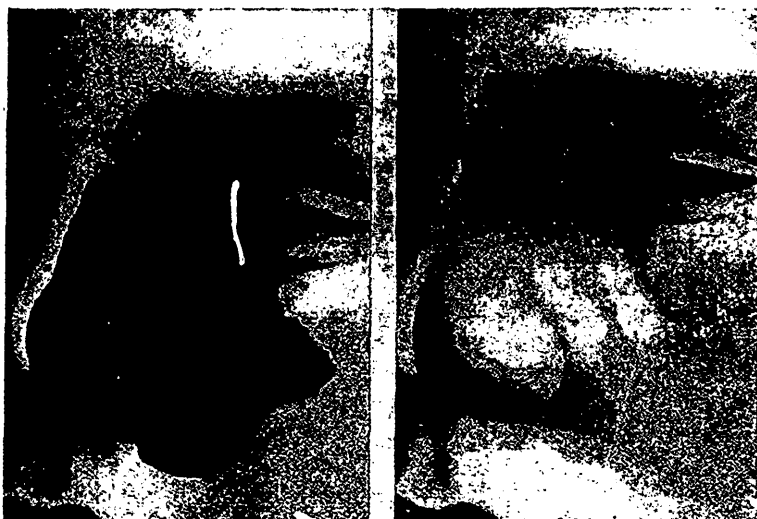


FIGURE 2.

Fig. 2.<sup>5</sup> This represents a large pigmentary tumor on the face of a child 11 years old. Its surface was ridged and of a yellowish brown color; it gave to the face a repulsive appearance. Application of radium was made for five hours on each place during three days. This produced an ulcerative reaction, which was followed by cicatrization. In two months the tumor had diminished fully one-half in size. Other applications were made for several hours on three consecutive days. Reaction was severe, but terminated rapidly. Additional applications had to be made from time to time. Three months after the completion of the treatment the tumor had entirely disappeared. The surface is now level and smooth, but there is some coloration of the tint of *café au lait*, and at two points the tissue is somewhat blanched.

Fournier<sup>6</sup> has been investigating the claims of Wickham and Degrais in regard to the complete cure of vascular naevi under the action of radium, and found that their claims are substantiated. He says that the cure of extensive naevi without a trace of disfiguring scars renders the method destined to supplant all other technics where the cosmetic effect is of importance. A slight ulcerative action seems to be required for flat superficial