

Cleft palate, for example, is a failure of the right and left halves of the upper jaw bones to unite in the median line; this leaves an opening between the mouth and the nasal cavity, and makes articulate speech and swallowing almost impossible. If the cleft is in the anterior portion of the bone, it may prevent the union of the tissues of the lip, a condition known as hare-lip, which is most disfiguring. Cleft palate is easily corrected in childhood by the

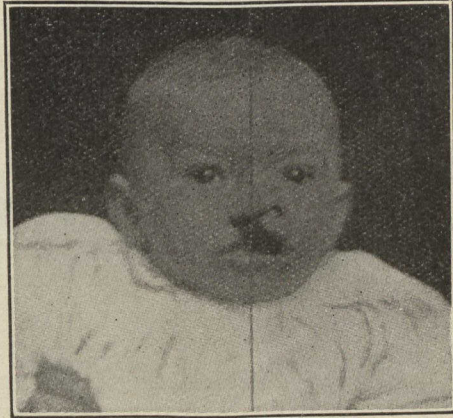


Fig. 5.—Cleft palate, before operation.

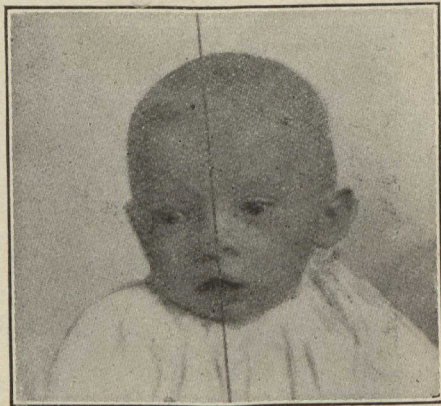

Fig. 6.—After operation.

surgeon, but may be remedied in some cases even in the adult. Where for any reason an operation to close the cleft cannot be performed, it is possible to have inserted by a dentist an appliance