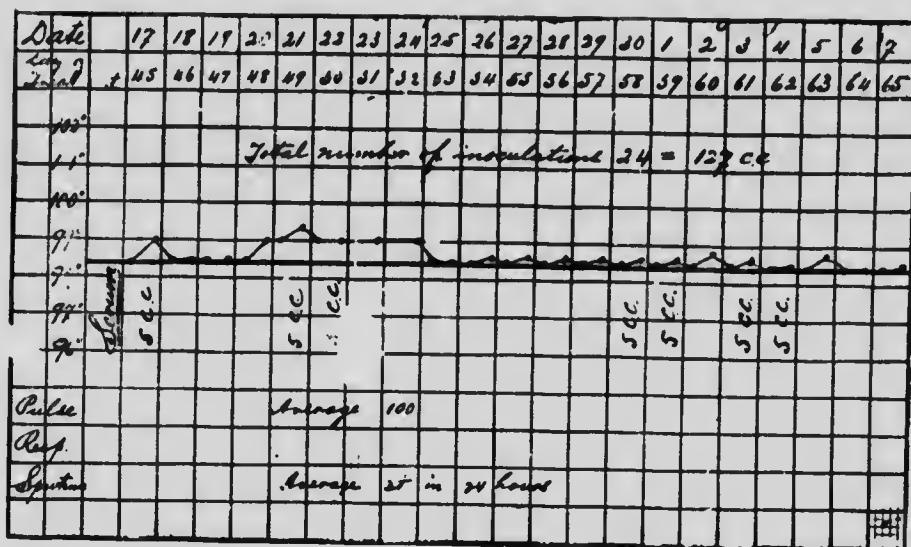


country, where she lived with relatives during the whole winter, and was examined on the 2nd May this year, the extent of the disease being noted on the accompanying Fig. No. 1. The condition at this time was distinctly *caseous*, and the amount of expectoration sometimes



CASE I. FIG. 2 -a. Impaired resonance; no rales. July 16th, 1901.



CASE I. CHART No. 2.

exceeded one ounce in the twenty-four hours. Temperature and pulse may be noted on the chart. This patient, who had during the previous six months been steadily losing in weight, in spite of the fact that she was living in the best surroundings, has in addition to the improvement in her symptoms since serum treatment, added nearly three pounds to her weight. Chart and Fig. No. 2 illustrating this case, give her condition at the time of writing (July 20th).

#### CASE No. II.

A single woman twenty-one years of age. Family history negative. This patient's illness dates back five years, when it started as a