

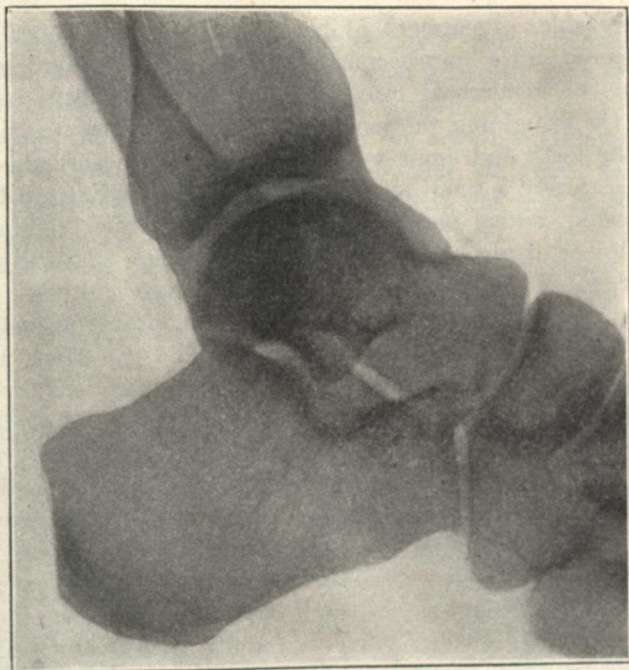Fig. 3.
Normal Joint surfaces of healthy foot.

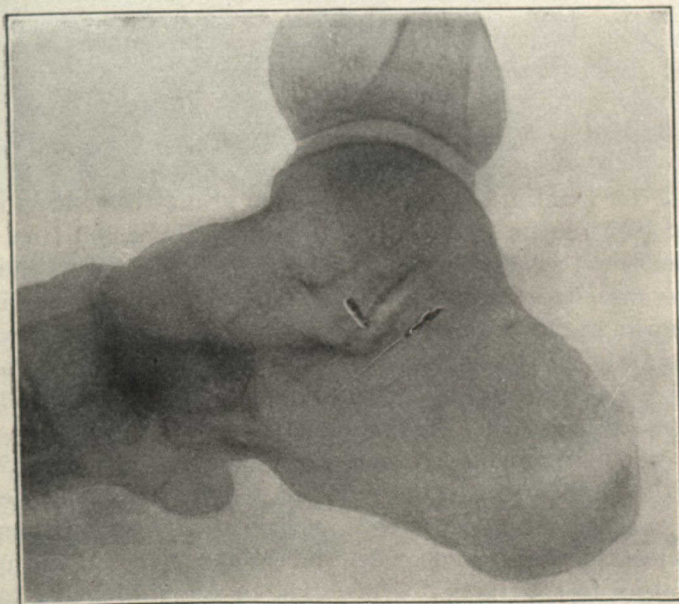


Fig. 4.
Arthritic Adhesions in diseased foot. Same patient as Fig. 3.