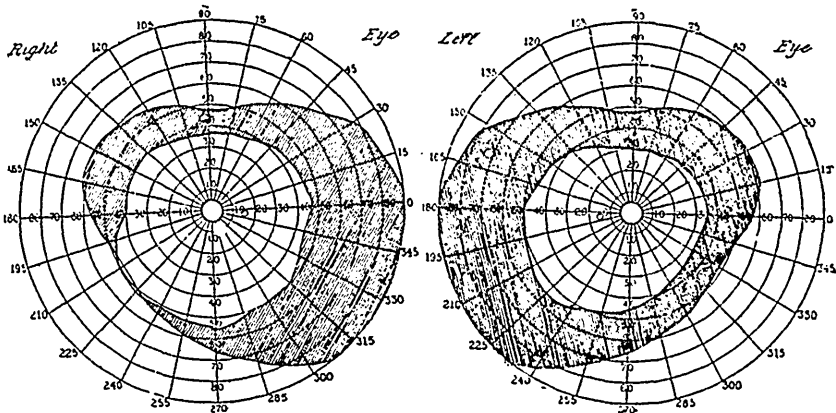


about six weeks after the attack, and here you will notice that the field has nearly doubled in its dimensions since first taken. Chart No. III. Interesting in this connection is that the ward notes taken at this time show a corresponding improvement in the cutaneous sensibility. The patient gradually improved and on March 1st notes are as follows: Fields of vision almost normal and anæsthetic areas have disappeared. She is up and about the ward all day. Yesterday she was about the hospital grounds for exercise and did not seem to be depressed afterwards. She could run up and down stairs as well as anyone, could dust and clean about the ward, and help in various ways.



No. III.—Fields for white. February 11th, 1908.

March 5, 1908. Patient complained of none of her former symptoms, appeared to be quite well, and was discharged.

In conclusion, I would like to point out that when at all pronounced a contracted field of vision can be readily detected at the bedside by the simple means of the finger test and without the aid of any special apparatus such as a perimeter. Its importance is so great in the differential diagnosis, which is often most perplexing, between an obscure organic disease and hysteria, that I am confident you will frequently be repaid for the slight trouble in searching for it. Should these few remarks serve to direct attention more closely to certain eye symptoms in relation to general medicine or prove of any assistance to you in the elucidation of a doubtful case, the pleasure to me will be sincere.