

Some cases of Deformed Feet treated at the Hospital.

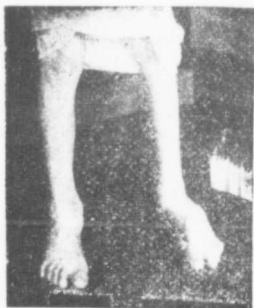

Fig. 1.—Before.



Fig. 1.—After.

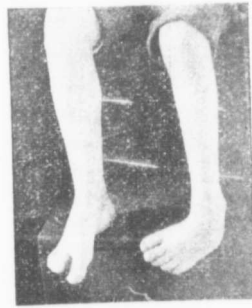

Fig. 2.—Before.

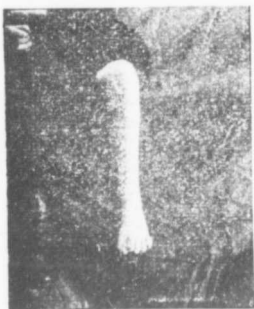


Fig. 2.—After.



Fig. 3.—After. Fig. 3.—Before.

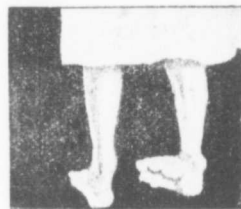

Fig. 4.—Before.



Fig. 4.—Before.

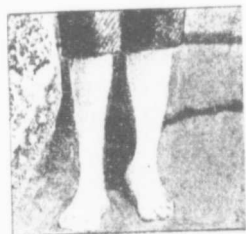

Fig. 4.—After.

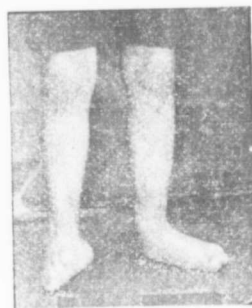

Fig. 5.—Before.



Fig. 5.—After.

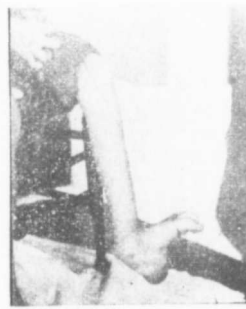

Fig. 6.—Before.

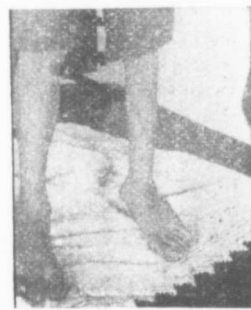

Fig. 6.—After.