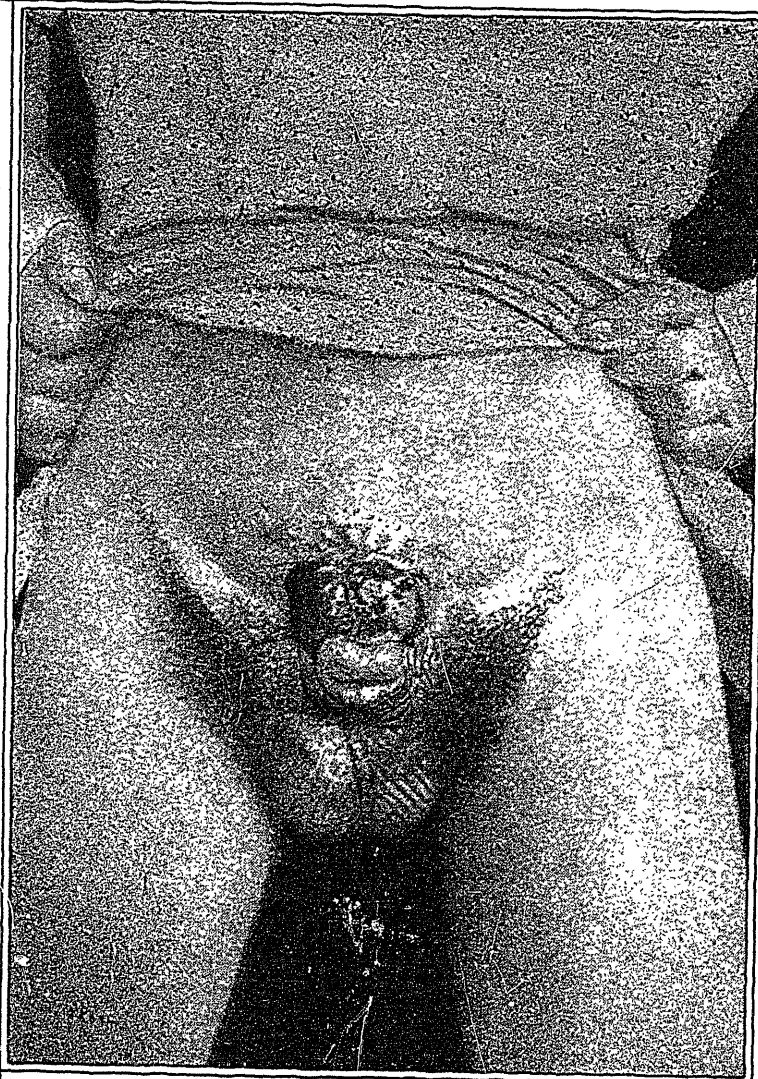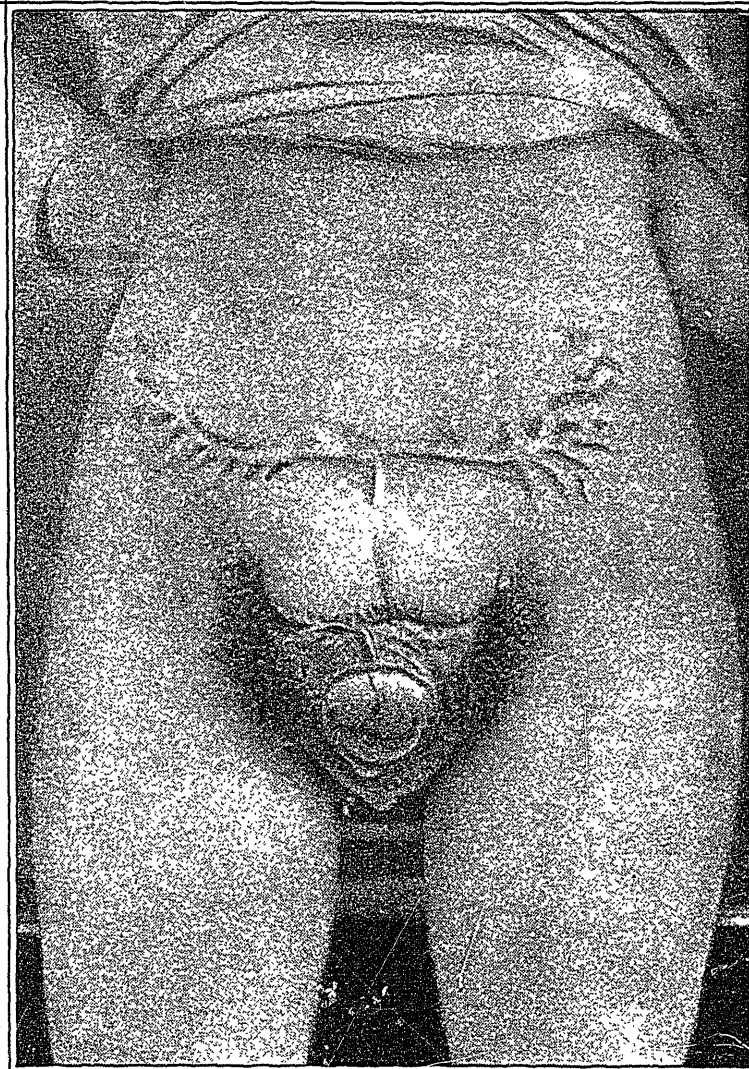


DR. WILKINS' CASE OF EXTROVERSION OF BLADDER AND EPISPADIAS.



From photograph taken two days before first operation.



From photograph taken six months after second and last operation.