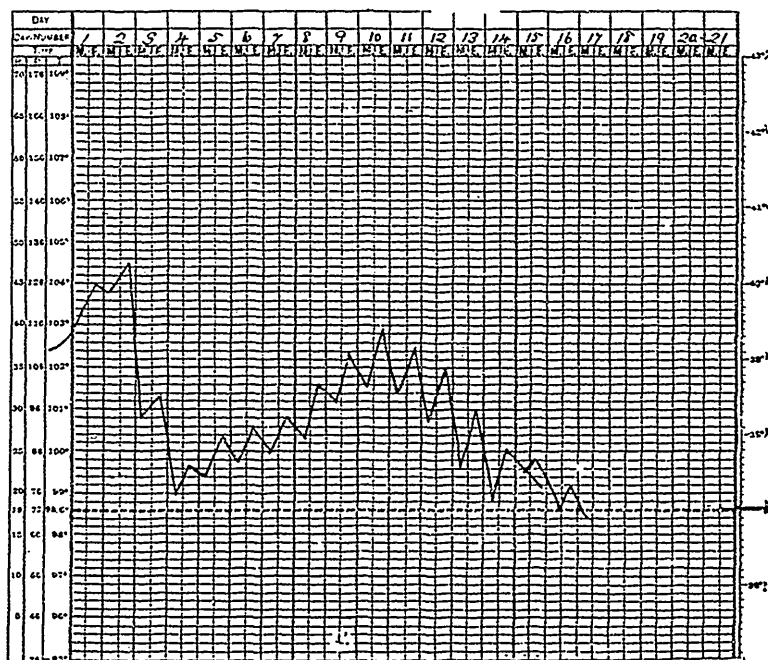


2nd day.—Temperature very high, 105.8; pulse, 140; respirations, 50.

4th day.—Temperature falling rapidly, and patient becoming delirious.

6th day.—Patient very delirious; papular shotty rash present on face and arms; temperature commencing secondary rise, having been normal on fifth day, as per chart; eruption discrete.

8th day.—Patient quieter; pulse, 136; eruption vesicular on face and hands; papular on body; eye-lids swollen; few vesicles on conjunctiva; not many in mouth.



10th day.—Eruption in late pustular stage on face; early pustular on body; eyes much better; still quite delirious; suppurative fever well marked.

12th day.—Scabs drying on face; pustules breaking on body; patient becoming rational.

16th day.—Patient feeling well; desquamation proceeding on face and body; temperature normal.

CASE II.—Variola viris, discrete form, but more severe than the preceding case, was marked by the following features:—exceptionally long incubation period with such mild prodromes as slight headaches, general pains and malaise during the last