

of the bowels should take place under normal conditions, namely, once or twice a day. This feature also occurred, and

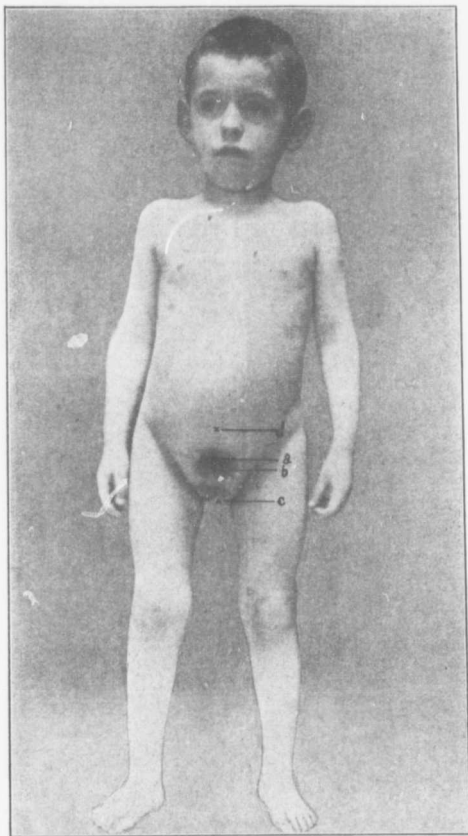


Fig. 3.—B. S. G., aged 6 years 10 months. Four years after operation for procidentia recti, and eighteen months after transplantation of the ureters into the rectum by extraperitoneal method. *a*, scar of transplantation operation; *b*, glans penis; *c*, cleft scrotum; *d*, scar of operation for procidentia. The attitude, with the legs separated, is characteristic of the imperfect and insecure pelvis. He walks well, but with a slightly waddling gait.