

# AN OVARIAN CYST PROTRUDING INTO THE INGUINAL CANAL

Baldy<sup>o</sup> in 1898 reported an interesting case of this character. Two years before coming under Baldy's observation the patient had noticed a small pedunculated tumor in the right inguinal region. This had continued to grow until it was as large as an egg and had then been removed. A year later a larger and similar growth had been present and had also been removed.

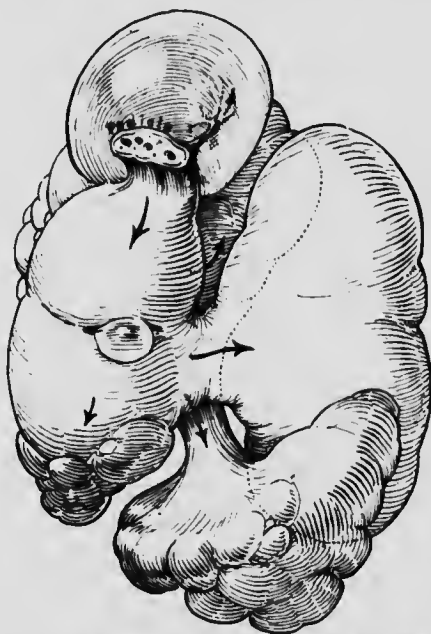


FIG. 3.—AN EXTRA-ABDOMINAL MULTILOCULAR FIBROCYSTOMA. A schematic representation of the manner in which the tumor tended to develop when relieved from its surrounding pressure. It in reality consisted of four lobes similar in character and joined together by broad or narrow pedicles.

When Baldy saw the patient the growth was as large as a fist. A pelvic examination revealed a mass filling the right side of the pelvis.

At operation, an incision was made directly over the growth and the tumor freed down to a thick, broad.

<sup>o</sup> Baldy, J. M.: Ovarian Cyst Protruding Through the Inguinal Canal, *Am. Jour. Obst.*, 1898, xxxviii, 827.