

grenous ragged edge of the diverticulum was removed and the edge was then invaginated by a double row of Lembert sutures (silk). The parts were swabbed with carbolic solution 1 to 20, followed by a 1 to 40 solution, and the intestine returned to the abdominal cavity. A considerable quantity of pus was found in pelvis and lower abdomen. A drainage tube and iodoform gauze were inserted, the divided portion of the transversalis was sutured, and the internal abdominal ring and the inguinal canal obliterated by suturing the conjoined tendon to Poupart's ligament with an interrupted cat-gut suture. The external oblique was sutured with a continuous cat-gut suture and the skin incision closed with silk-worm gut. As each layer of the abdominal wall was sutured the parts were swabbed with 1 to 40 carbolic solution. The wound was then dressed with boracic acid and dry dressings, and a pad of absorbent cotton affixed by adhesive plaster.

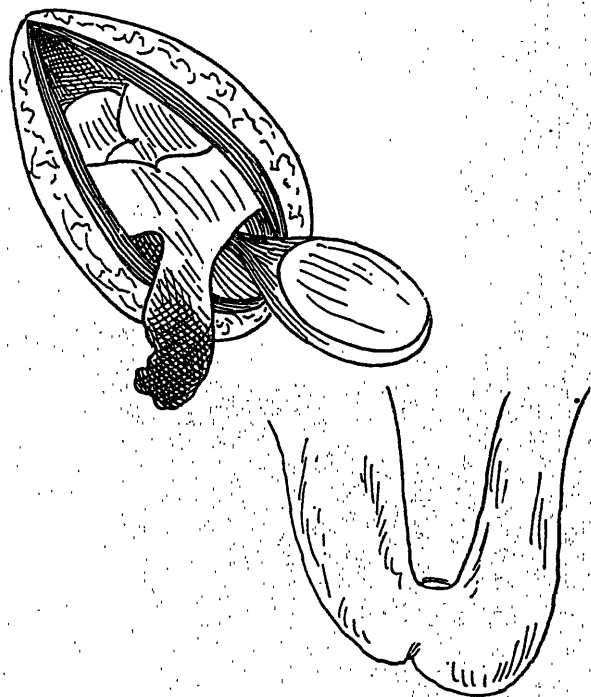


FIG. II. Shows the strangulated gut, freed and drawn down, to be a Meckel's diverticulum.

*After-Treatment.* The patient came out of ether quietly, with no vomiting. Champagne  $\mathfrak{z}$ ss., and strychnine gr.  $\frac{1}{60}$ , were given every four hours. At 2 a.m. a saline enema of one pint containing ten minims of tincture of digitalis was administered; the temperature was then  $100^{\circ}\text{F}$ .