

in telling him there was no precedent for his operation. He considered that Hainsby's truss had been invented for the purpose,

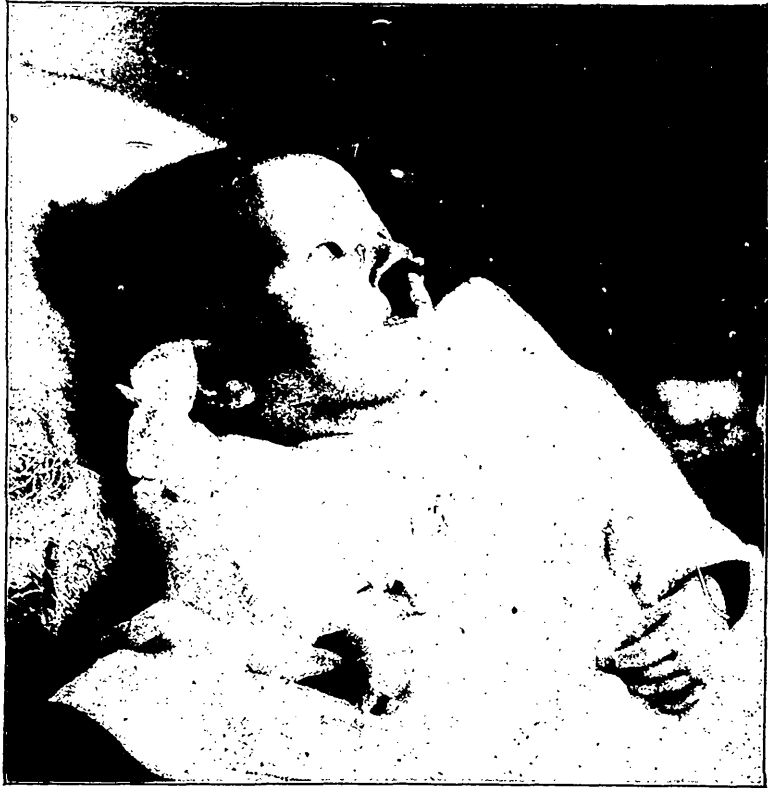

FIG. 22.

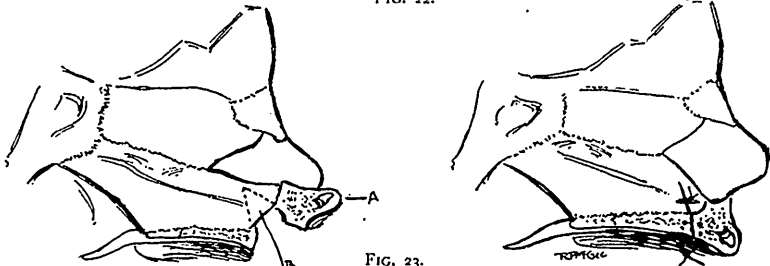


FIG. 23.

A. Protruding intermaxillary bones containing germs of the temporary central incisors. B. V-shaped incision in the vomer, indicated by dotted lines.

and it was found that this truss brought the bones together and approximated the edges of the cleft. He thought there were lots